

Clinical, biochemical, and molecular overview of transaldolase deficiency and evaluation of the endocrine function: Update of 34 patients

Monique Williams¹ | Vassili Valayannopoulos^{2,3} | Ruqaiyah Altassan⁴ | Wendy K. Chung⁵ | Annemieke C. Heijboer^{6,7} | Wei Teik Keng⁸ | Risto Lapatto⁹ | Patricia McClean¹⁰ | Margot F. Mulder¹¹ | Anna Tylki-Szymańska¹² | Marie-Jose E. Walenkamp¹¹ | Majid Alfadhel⁴ | Hajar Alakeel⁴ | Gajja S. Salomons¹ | Wafaa Eyaid⁴ | Mirjam M. C. Wamelink¹

¹Metabolic Laboratory, Department of Clinical Chemistry, Amsterdam Neuroscience, VU University Medical Center, Amsterdam, The Netherlands

²Sanofi Genzyme, Cambridge, Massachusetts, USA

³Reference Center for Inherited Metabolic Disease, Institut IMAGINE, Hopital Universitaire Necker - Enfants Malades, Paris, France

⁴King Abdulaziz Medical City-Riyadh, National Guard Health Affairs, King Abdullah International Medical Research Center (KAIMRC), King Saud Bin Abdulaziz University for Health Sciences, Riyadh, Saudi Arabia

⁵Departments of Pediatrics and Medicine, Columbia University, New York, New York, USA

⁶Endocrine Laboratory, Department of Clinical Chemistry, VU University Medical Center, Amsterdam, The Netherlands

⁷Laboratory of Endocrinology, Academic Medical Center, Amsterdam, the Netherlands

⁸Genetic Department, Hospital Kuala Lumpur, Kuala Lumpur, Malaysia

⁹Children's Hospital, University of Helsinki and Helsinki University Central Hospital, Helsinki, Finland

¹⁰Children's Liver Unit, Leeds Teaching Hospitals NHS Trust, Leeds, UK

Abstract

Background: Transaldolase deficiency (TALDO-D) is a rare autosomal recessive inborn error of the pentose phosphate pathway. Since its first description in 2001, several case reports have been published, but there has been no comprehensive overview of phenotype, genotype, and phenotype–genotype correlation.

Methods: We performed a retrospective questionnaire and literature study of clinical, biochemical, and molecular data of 34 patients from 25 families with proven TALDO-D. In some patients, endocrine abnormalities have been found. To further evaluate these abnormalities, we performed biochemical investigations on blood of 14 patients.

Results and conclusions: Most patients ($n = 22$) had an early-onset presentation (prenatally or before 1 month of age); 12 patients had a late-onset presentation (3 months to 9 years). Main presenting symptoms were intrauterine growth restriction, dysmorphic facial features, congenital heart disease, anemia, thrombocytopenia, and hepato(spleno)megaly. An older sib of two affected patients was asymptomatic until the age of 9 years, and only after molecular diagnosis was hepatomegaly noted. In some patients, there was gonadal dysfunction with low levels of testosterone and secondary luteinizing hormone (LH) and follicle-stimulating hormone (FSH) abnormalities later in life. This overview provides information that can be helpful for managing patients and counseling families regarding prognosis. Diagnostic guidelines, possible genotype–phenotype correlations, treatment options, and pathophysiological disease mechanisms are proposed.

KEYWORDS

Transaldolase, Pentose phosphate pathway, Endocrine, Polyols, Diagnostic guideline

M. Williams and V. Valayannopoulos contributed equally and W. Eyaid and M. M. C. Wamelink contributed equally.

V. Valayannopoulos, W. Eyaid, and M. M. C. Wamelink shared corresponding author.

This is an open access article under the terms of the Creative Commons Attribution License, which permits use, distribution and reproduction in any medium, provided the original work is properly cited.

© 2018 The Authors. *Journal of Inherited Metabolic Disease* published by John Wiley & Sons Ltd on behalf of SSIEM

¹¹Department of Pediatrics, VU University Medical Center, Amsterdam, The Netherlands

¹²Department of Pediatric, Nutrition and Metabolic Disease, The Children's Memorial Health Institute, Warsaw, Poland

Correspondence

M. M. C. Wamelink, Metabolic Laboratory, Department of Clinical Chemistry, Amsterdam UMC, Vrije Universiteit Amsterdam, Amsterdam, The Netherlands.
Email: m.wamelink@vumc.nl

V. Valayannopoulos, Sanofi Genzyme, Cambridge, MA, USA.
Email: vassili.valayannopoulos@sanofi.com

W. Eyaid, King Abdulaziz Medical City-Riyadh, National Guard Health Affairs, King Abdullah International Medical Research Center (KAIMRC), King Saud bin Abdulaziz University for Health Sciences, Riyadh, Saudi Arabia.
Email: EyaidW@NGHA.MED.SA

Communicated by: Jean-arie Saudubray

1 | INTRODUCTION

Transaldolase deficiency (TALDO-D, Eyaid syndrome, OMIM 606003) is a rare autosomal recessive inborn error of the pentose phosphate pathway first described in 2001.¹ Patients can present either prenatally, with intrauterine growth restriction (IUGR) and/or oligohydramnios; in the neonatal period, with dysmorphic facial features, cardiovascular defects, and hepato(spleno)megaly; or later in life, with a milder phenotype or even no symptoms (one patient described so far). To perform a systematic review of clinical and biochemical findings in patients with TALDO-D, questionnaires were sent to nine physicians of patients with proven TALDO-D, and a literature review was performed. In some patients, endocrine abnormalities (e.g., abnormal genitalia, vitamin D deficiency, hypergonadotrophic hypogonadism) have been reported,¹⁻³ (M.F. Mulder, personal communication). To further evaluate endocrine characteristics, we performed endocrine investigations in blood samples from 14 living patients. Here we present an overview of the clinical spectrum of TALDO-D with clinical, biochemical, and molecular genetic data of a cohort of 34 patients from 25 families.

2 | METHODS

2.1 | Collection of clinical and biochemical data

The VU University Medical Center (VUMC), Amsterdam, was the first center to diagnose a patient with TALDO-D. Since then, diagnoses have been made on patients from all over the world using biochemical and molecular diagnostics. Until 2015, a pathogenic mutation or an enzymatic deficiency was identified in 19 patients, and comprehensive questionnaires evaluating clinical and laboratory findings in TALDO-D were sent to physicians of these patients and their affected siblings. Additionally, all patients with published case reports until 2015 were included. This study was approved by the ethics committee of the VU University Medical Center, Amsterdam, The Netherlands, No 2012/426.

2.2 | Biochemical studies

Sugars and polyols were measured in urine and/or plasma by gas chromatography (GC)⁴; the seven-carbon sugars were measured using liquid chromatography tandem mass spectrometry (LC-MS/MS).⁵

2.3 | TALDO enzyme analysis

In cell extracts (fibroblasts, lymphoblasts, liver) from 13 patients, TALDO activity was measured either using LC-MS/MS¹ or spectrophotometrically.⁶

2.4 | Analysis of the *TALDO1* gene

Mutation analysis of the *TALDO1* gene (GenBank Accession No. L1943.2) was performed by direct sequence analysis of genomic DNA from blood.¹

2.5 | Analysis of endocrine function

To obtain information about endocrine manifestations in TALDO-D patients, measurements were performed on fasting serum and ethylenediaminetetraacetate (EDTA) plasma of 14 patients (11 male/3 female, median age 7 years, range 2–16 years) with TALDO-D. Fasting serum insulin and cortisol were measured using an automated immunoassay (Centaur, Siemens Diagnostics). Follicle-stimulating hormone (FSH), luteinizing hormone (LH), and testosterone were measured using another automated immunoassay (Architect, Abbott Diagnostics). Testosterone was measured using the second-generation assay.⁷ Thyroid stimulating hormone (TSH) and free T4 were measured in serum using an automated immunoassay (Cobas, Roche Diagnostics). Cholesterol, glucose, and anti-Müllerian hormone (AMH) were measured in serum using the Cobas (Roche Diagnostics). In EDTA plasma, adrenocorticotrophic hormone (ACTH) was measured using an automated immunoassay (Liaison, Diasorin). Estradiol and 17-hydroxyprogesterone were measured in serum using manual competitive immunoassays (Delfia, Perkin Elmer and DRG Instruments, respectively). In serum, using an in-house LC-MS/MS method, androstenedione,^{8,9} 25-OH vitamin D¹⁰ and dehydroepiandrosterone sulphate (DHEAS)¹¹ were measured.

3 | RESULTS

3.1 | Patients

Completed questionnaires on 25 patients from 15 families were received. For nine additional patients from whom no questionnaire data were available, data were collected from publications.^{2,3,12–14} Thirty-four patients from 21 families were included [23 male and 11 female, median age at last visit or at death 6 years (varying from 0 to 25 years, $n = 33$ (one unknown))] Only one patient reached adulthood; she was 25 years old at her last clinical evaluation, when questionnaires were completed.

TABLE 1 Clinical features transaldolase deficient patients

Clinical features	Early onset % ($n = 22$)	Late onset % ($n = 12$)	Total % ($n = 34$)
Anemia ^a	77	75	76
Thrombocytopenia ^a	77	67	74
Hepatomegaly ^a	77	100	85
Splenomegaly ^a	45	25	38
Pancytopenia	5	33	15
Impaired coagulation ^a	41	25	35
Hepatocellular carcinoma	0	8	3
Cardiac abnormalities ^a	68	50	62
Abnormal skin ^a	68	67	68
Cutis laxa/wrinkled skin ^a	59	42	53
Triangular facies ^a	41	33	38
Tubulopathy	32	25	29
Renal stones	14	8	12
Hypergonadotropic hypogonadism	27	0	18
Abnormal genitalia ^a	36	25	32
Decreased growth-height	36	8	26
IUGR ^a	32	17	26
Mild intellectual disability or motor delay ^b	43 ($n = 14$)	9 ($n = 11$)	28 ($n = 25$)
Hearing/vision abnormal	5	8	6
Hypotonia ^a	27	8	21

IUGR, intrauterine growth restriction.

^aFeature of presentation.

^bNot able to determine in the younger children.

3.1.1 | Phenotype

Family history

Patients came from 21 different families of Middle Eastern [Saudi Arabia, belonging to two tribes that claim a common ancestor⁶ ($n = 6$)], Asian ($n = 5$), western Asian/southeast European (Turkey) ($n = 4$), European ($n = 4$), West African ($n = 1$), and unknown ($n = 1$) origin. In six families, more than one child had TALDO-D. In 16 families, there were one to ten unaffected children ($n = 55$): 38% of children born in these families were affected with TALDO-D; 81% of parents were consanguineous (17 of 21 families).

Age at presentation

Patients came for medical attention prenatally or between birth and 9 years of age ($n = 33$; one was unknown; mean

0.44 year). Twenty-two (64.7%) patients presented prenatally or up to 1 month after birth (early presentation). Late presentation (> 3 months of age) was seen in 12. One asymptomatic patient was diagnosed at the age of 9 years due to family screening (F13-P1). Clinical symptoms are shown in Table 1.

Prenatal manifestations

In two cases the mother of the affected children presented with excessive weight gain during pregnancy, hydropic placenta, and oligohydramnios ($n = 2$; F05-P1 and F05-P2). One of these children showed generalized edema. IUGR was seen in seven early-onset patients (32%) and reported in another two cases of late presentation (17%). Fetal hydrops was seen in four patients and neonatal edema in seven.

Physical examination (dysmorphic features, growth)

Dysmorphic features were observed in 50% of patients with TALDO-D. The most prominent features were skin abnormalities (68%), triangular-shaped face (38%), low-set ears (35%), wide mouth (26%), and thin lips (24%) ($n = 32$; 2 unknown). Postnatal growth was reported normal in 14/22 patients with early presentation. In late-onset presentation, growth was within the normal range in 10/12 patients (1 unknown). In total, at least 24/34 (71%) had a normal growth. Head circumference was normal in 15 and not reported in 19. Reports of low body mass index (BMI) and/or short stature in the course of the disease were mentioned in the other nine (26%) patients.

Skin

Cutis laxa/wrinkled skin was seen in more than half of the patients ($n = 18$, 53%), and capillary hemangioma in six (18%). This feature may attenuate and disappear as patients grow older. In 12 patients from six families, thin pigmented skin was seen on distal metacarpal joints (knuckles).

Cardiac abnormalities

Congenital heart defects, such as ventricular septal defect (VSD) and/or atrium septal defect (ASD), occurred in 12 (35%) cases. Bicuspid aortic valve ($n = 2$; F01-P1; F21-P1), aortic coarctation ($n = 1$; F01P1), and dextrocardia ($n = 1$; F09P2) were observed. Patent foramen ovale and persistent ductus arteriosus were seen in 11 patients (32%). Cardiac abnormalities were found in similar numbers in early- and late-onset cases. Cardiomyopathy was present in three (F02-P1; F18-P1; F21-P1) patients (9%), hypertrophy of the left and or right ventricle occurred in four (F02-P1; F03-P4; F18-P1; F17-P1) (12%), and possible secondary abnormalities [tricuspid regurgitation (TR), valve prolapse] were found in two (6%).

Hepatic evaluation

Hepatomegaly was observed in 77% of patients when presentation was early and 100% when presentation was late. In 50% of cases, hepatomegaly coincided with splenomegaly in both early and late presentation. Hepatic dysfunction was found in 17 of the 22 cases (77%) who presented early and was associated with fibrosis and cirrhosis in 23% and 18%, respectively. Decreased hepatic synthetic function was notable (decreased serum albumin and abnormal clotting factors) in 53% patients; aspartate aminotransferase (AST) and/or alanine aminotransferase (ALT) were elevated in 10/22 (59%) and bilirubin in 8/22 (36%). In 9/22 patients (41%), hepatic dysfunction was progressive ($n = 2$ stable, 11 unknown); hepatic dysfunction was present in 10/12 cases (83%) when presentation was late [AST and/or ALT elevated in 7/12 (58%) and bilirubin elevated in 3/12 (25%)] and was associated with cirrhosis in 25%. Liver biopsy was done in 16/34 patients; fibrosis and/or cirrhosis were seen in 14. Mild steatosis was observed in 4/16 patients. No signs of inflammation or storage of copper, iron, or glycogen were reported. Two patients received liver transplants for progressive liver dysfunction or development of hepatocellular carcinoma.

Alpha fetoprotein (AFP) levels were determined in 20 patients; levels were within the normal range in three patients (<3.9 to <8 ng/ml). In the 17 patients with increased levels, these ranged from 4 to 64,959 ng/ml (mean 8075 ng/ml; median 198 ng/ml). Follow-up of AFP levels was done in 15 patients; most showed a decrease, normalization occurred in three (one after liver transplantation), and stabilization was seen in three.

Hematological features: blood cell count

Anemia was seen in 17/22 (77%) of early-presentation cases. The range of lowest hemoglobin levels reported was 52–112 g/L, with a median of 80 g/L (3.2–6.9 mmol/L, median 4.9 mmol/L). Values were normal in four patients. In late-onset presentation, anemia occurred in a similar percentage (75%). Mean corpuscular volume ranged from 66.6 to 103 fl, with a median of 89.6 fl (normal: newborn: 95–120, child: 70–95; adult: 82–98); two patients were below the normal range. Ferritin levels were measured in 14 cases, seven of which showed normal levels. In three patients, levels were elevated up to 2347 $\mu\text{g/L}$ (ref 21.8–274.6): in two of these patients, levels were only above normal in a period of hemolytic anemia, and a mild decrease was seen in four patients. Thrombocytopenia was a prominent feature and was seen in 77% and 67% of patients in early and late presentation, respectively. Median platelet count was 48 (early onset) and 53 (late onset) $\times 10^9/\text{L}$. Follow-up of thrombocyte count was known in 26 and values were given in 11. Thrombocyte values were

fluctuating or stable in most patients. In 3/26 patients (with information given with respect to thrombocytopenia), thrombocytopenia resolved; in one of these patients, this occurred after liver transplantation. Thrombocyte values decreased in two patients. White blood cell number was depressed in 5/34 patients (15%) (pancytopenia was mentioned in 5 patients). This was observed later in the disease course in all five cases.

Renal manifestations

Proximal and distal tubular dysfunction (aminoaciduria, proteinuria, and loss of electrolytes) was the most prominent renal feature in TALDO-D (10/34, 29%). Glomerular problems occurred but were not frequently reported. Renal stones developed in 4/34 (12%) cases. Renal ultrasound (US) was abnormal in eight patients: hydronephrosis in six, nephromegaly in one, echogenic foci at the tips of the renal pyramids in one, and hypoplastic right kidney in another. In 16 patients, no abnormalities were detected on ultrasound (US). For the other ten patients, renal US was either not performed or no information was given.

Additional, less-frequently observed, features

Additional unique observations in single patients were ichthyosis, gallstones, and high iron content in hepatocytes and thyroid cells on histology associated with elevated iron and serum and liver ferritin (F03-P2). One sibling also had high iron levels (F03-P4), but no information on tissue iron was available. Nystagmus and pituitary microadenoma were observed in a single patient.

Development and neurological symptoms

Development was normal in most (18/25, 72%) patients. Some experienced (mild) motor delay ($n = 7$). No information on development was given for nine patients. Normal visual and auditory development was noted in 29 patients, with no information in three. Abnormalities were seen in two patients [horizontal nystagmus (F16-P2) and sensorineural deafness (F04-P1)]. Six of 34 patients displayed muscular hypotonia at disease onset (18%).

3.1.2 | Endocrine evaluation

Gonadal function

In 11/34 patients (32%), abnormal external genitalia were present at birth (3 males with small phallus, 3 females with clitoromegaly, 6 males with cryptorchidism). In six patients, hypergonadotropic hypogonadism was reported, including in a 16-year-old male patient with elevated LH and FSH levels and normal serum testosterone. Al-Shamsi et al. described a 25-year-old female patient with secondary

amenorrhea from the age of 23, high prolactin levels, and a pituitary microadenoma.¹²

Gonadotrophin levels were assessed in 14 patients. Tanner stage was not available in most patients; however, eight were <7 years and presumed prepubertal. In two patients [girl 9 years (Tanner stage unknown) and boy 14 years (Tanner stage 4–5)] elevated gonadotrophin levels with low serum testosterone were found; this was not reported in the questionnaire of the 9-year-old girl. In the 16-year-old patient reported to have elevated gonadotrophins, we measured mildly elevated FSH (16.7 U/L) and normal LH (7.2 U/L) and testosterone (13.4 nmol/L), indicating a normal Leydig cell function and a compromised Sertoli cell function. A female patient of 2.5 years had increased LH and FSH levels and a low serum AMH, indicating ovarian failure.

Adrenal function

DHEAS, the sulfonated product of DHEA, is mainly produced in the adrenals and was measured in 14 patients. It was decreased in a 16-year-old male patient who also had low androstenedione (a DHEA product). In one patient (female 2.3 years), we measured a mildly elevated 17-hydroxyprogesterone (17-OHP) (10 nmol/L; n 1.5–6.4). ACTH and basic cortisol levels were normal in all 14 patients. In 5/14 (36%) patients, there were abnormalities concerning development and function of adrenals and gonads.

Thyroid function

TSH and free T4 were normal in 11/13 investigated patients. One patient was diagnosed with primary hypothyroidism [free T4 7.1 pmol/L (9–19 mol/L); TSH 327 mU/L (0.35–4.94 mU/L)]. She was treated with levothyroxine. When we measured her thyroid function, free T4 was normalized (15.3 pmol/L; controls 12–22 pmol/L), although TSH level remained elevated (112 mU/L; controls 0.6–4.8 mU/L). A recent assessment showed a normal thyroid function with levothyroxine: free T4 18.3 pmol/L (9–19 mol/L); TSH 5.26 mU/L (0.35–4.94 mU/L). One patient had a mildly increased TSH value (8.3 mU/L; controls 0.7–6.0 mU/L) with a normal free T4 (14.9 pmol/L; ref. 12.3–22.8 pmol/L), which was considered as subclinical hypothyroidism. One patient was known to have transient hypothyroidism.

Growth

Abnormalities concerning growth and bone features that were described in a minority of patients were: (1) Short stature, with a concomitant insulin-like growth factor-1 (IGF-1) deficiency, was identified in 2/34 patients. One patient received growth hormone treatment with poor

growth response; no further information was given or analysis performed on the remaining patients. (2) Bone abnormalities were seen in 4/34 patients: In three decreased bone density (osteopenia) of a varying degree was observed. One patient presented with rickets caused by vitamin D deficiency, possibly related to tubulopathy. In the fourth patient, increased densities of long-bone metaphyses and skull and histological findings on bone biopsy suggested osteopetrosis.

3.1.3 | Other endocrine functions

Glucose homeostasis

In this cohort of 34 patients, one was known to experience neonatal hyperinsulinism. Insulin was elevated in 2/14 blood samples taken during fasting and was not associated with hypoglycemia. Presumably, the patient had not fasted completely. Fasting glucose was normal in all but one patient (2.2 mmol/L), who was not known to have clinical hypoglycemia and had normal insulin levels.

Vitamin D measurement

25-OH vitamin D was >40 nmol/L in all 14 patients and >50 nmol/L (target value) in 12/14 patients. Five of 13 patients received vitamin D supplementation; supplementation in one patient was unknown.

3.1.4 | Clinical course

Survival

Of the 34 patients, eight (24%) died at a median age of 2.3 (0–17) years. One pregnancy was terminated because of multiple malformations (heart, liver, kidney) at 28 weeks of gestation. Six patients had a neonatal onset, with presentation in the first week. One patient had his first symptoms at 3 months. Of these seven patients, six died within 6 months due to liver failure; the other patient died at 17 years from acute massive intra-abdominal bleeding during decompensated liver cirrhosis with portal hypertension and oesophageal varices.

Main features during the clinical course

were hepatomegaly with increased ALT/AST, increased bilirubin levels, cholestasis, and liver dysfunction resulting in coagulopathy and/or bleeding. Development of hepatocellular carcinoma was observed in one patient, leading to liver transplantation. Susceptibility to infections was also reported ($n = 5$). Renal findings included tubulopathy in three and renal failure in two. Hematological abnormalities reported were thrombocytopenia ($n = 11$) with associated anemia in seven. Pancytopenia was observed in five patients during follow-up.

3.1.5 | Laboratory diagnosis

Patients were detected by urinary, plasma, enzymatic, or DNA investigations. The diagnosis was confirmed by DNA analysis of the *TALDO1* gene in all 34 patients.

Biochemical analysis

Polyol analysis was performed in urine, plasma, and cerebral spinal fluid (CSF) in 27, 11, and one patient, respectively. In all 27 patients, abnormal polyols and/or seven-carbon sugars were detected in urine: increased excretion of erythritol, arabitol, ribitol, sedoheptitol, perseitol, sedoheptulose, mannoheptulose, and sedoheptulose-7P. In older patients (>9 years), erythritol and arabitol are sometimes within the reference range. In 11 patients, plasma investigations were performed and showed mild elevations of erythritol, arabitol, and ribitol. In one patient, polyols in CSF were measured and showed a mild elevation of ribitol (19 $\mu\text{mol/L}$; reference values <6), while concentrations of erythritol and arabitol were normal. Erythronic acid was elevated in three patients and not mentioned in the others. Erythronic acid has been previously detected as a biomarker in TALDO-D.¹⁵

Other biochemical abnormalities included reduced activities of complex I–IV in muscle and liver in one and increased excretion of 2-ketoglutaric acid and fumaric acid in three patients. Lactate was normal in 11 patients, while elevated initially after birth in one, during exercise in one, and during the terminal phase in one. Amino acid analysis in urine and plasma was normal in one and eight patients, respectively. Aminoaciduria was seen in six patients; four patients had a typical amino acid pattern in plasma associated with liver dysfunction with high glutamine, methionine, and ethanolamine levels. For the other patients no information was given on amino acids in urine and plasma.

Enzymatic analysis

TALDO enzyme deficiencies were measured in 13 patients (38%, 8 in fibroblasts, 4 in lymphoblasts, 1 in fetal liver). Residual activity when measured by spectrophotometry was <6% of controls.

Genotype

Most patients (94%) were homozygous for a mutation in *TALDO1* (Genbank # NM_006755; gi5803186), which is in line with the high frequency of consanguinity. Different types of mutations have been detected, including missense mutations, in frame deletions, and frameshift mutations. In our group, 11 different mutations were identified (see Supplemental Table 1). The most frequent mutations were c.793delC; p.Gln265ArgfsX56, present in 12 patients (35%) from the same ethnic background (Middle East); c.512-514delCCT; p.Ser171del in five patients (15%); and c.574C > T; p.Arg192Cys in five patients (15%).

Genotype–phenotype correlation

There is no clear genotype–phenotype correlation. All five patients from two families with the homozygous c.512_514delCCT; p.Ser171del mutation presented intra-uterine or neonatally, while all three patients from one family with the homozygous c.512C > T; p.Ser171Phe mutation had a late-onset presentation.

3.1.6 | Treatment

In general, patients should receive standard symptomatic care, e.g., optimal nutrition and vitamin supplementation for the presenting symptoms (liver and renal) and transfusion support and monitoring for bleeding and thrombocytopenia. A single specific experimental therapy for TALDO-D patients has been recently reported using an oral glutathione precursor, N-acetylcysteine (NAC), over a 6-month period, which was well tolerated and was associated with a sustained normalization of alpha fetoprotein (AFP) levels and stable clinical course.

Two patients from our group of 34 (F13-P3; F17-P1) and one additional patient (V. Valayannopoulos, personal communication) underwent liver transplantation. The first two patients presented progressive liver dysfunction, and patient F13P3 had cirrhosis and hepatocellular carcinoma. Both were successfully transplanted at the age of 1 year, before the diagnosis was known. Both patients were stable at the age of 7 and 3 years, respectively, with normal blood count and normal or mildly elevated liver enzymes the other patient (V. Valayannopoulos, personal communication) died in the course of a liver transplantation. This patient received an orthotopic liver transplant from a cadaveric donor at 5 months of age. Transplantation was marked by portal thrombosis at day 3 posttransplant that required a new surgical procedure and was associated with a partial splenectomy. The postsurgical course was marked by pulmonary infection leading to respiratory distress and eventually death in the second week posttransplant. This patient had received antioxidant therapies (N-acetyl-cysteine, selenium, vitamins C and E).

4 | DISCUSSION

4.1 | Phenotype

We report the largest series to date of TALDO-D patients: 34 patients from 25 families. Core clinical features in this patient group include developmental abnormalities of the heart, skin, kidney, and abnormal external genitalia at birth, with the two most important findings being liver and hematological involvement. TALDO-D is mainly a nonneurological disease, and cognition was normal in most patients.

Delay in motor development, observed in some patients, was thought to be due to hypotonia (21%) and hyperlaxity (6%). Patients with a neonatal presentation within the first week of life seemed to have a worse prognosis, with 27% mortality within the first 6 months of life, most likely due to severe liver failure. Most of these patients showed the typical dysmorphic and congenital abnormalities of TALDO-D, as described in Table 1.

4.1.1 | Hepatic abnormalities

The liver is the most frequently affected organ, seen in >85% of patients, and is where TALDO enzyme activity is highest and thus where the greatest impact can be expected. This results in liver dysfunction and damage, leading to life-compromising complications (cirrhosis, liver failure, development of malignancy).

4.1.2 | Hematology–splenomegaly

Splenomegaly is a frequent finding (45%) in patients with early disease onset. Of these patients, about half (23%) also show thrombocytopenia. An enlarged spleen could be caused by extramedullary (fetal) hematopoiesis, portal hypertension, and cirrhosis and can result in severe thrombocytopenia. Thrombocytopenia, however, is a prominent feature of TALDO-D throughout life but can also be present in patients without splenomegaly ($n = 1$). This indicates splenomegaly might be secondary to splenic tissue hyperplasia, liver cirrhosis, and portal hypertension.¹⁶

Anemia was seen even more frequently, presenting in 77% of patients in the neonatal period and late presentation in 75%. Mean corpuscular volume (MCV) did not seem to change with time, and there was no indication of iron, folic acid, or vitamin B12 deficiency. Possible causes for anemia can be hemolysis [as is seen in glucose-6-phosphate dehydrogenase (G6PDH) deficiency due to low reduced nicotinamide adenine dinucleotide phosphate (NADPH)], decreased hematopoiesis in fetal liver and/or spleen, bleedings, failure to regenerate, or renal dysfunction (no information on markers for decreased bone marrow activity, lack of erythropoietin or function, on lactate dehydrogenase (LDH) levels or haptoglobin were available). As there were no data on reticulocyte counts, we were unable to determine whether the anemia was regenerative or not.

Fetal hydrops and placental edema might be related to anemia or could be caused by accumulating polyols during fetal development, which may lead to an osmotic disequilibrium, which is responsible for water movements through the different fetal fluid compartments.^{17,18}

Abnormal skin, described as cutis laxa/wrinkled skin, which is seen in more than half of the patients, might be

caused by fetal edema of the skin, which disappears toward the end of pregnancy when fetal renal function increases.

Cardiac abnormalities, i.e., developmental disorders, were seen in about a third of patients. This high percentage must be at least partly due to TALDO-D; however, pathogenic etiology remains unclear. Dextrocardia, seen in one patient, could indicate the importance of the *TALDO1* gene in early fetal development. Cardiomyopathy and/or ventricular hypertrophy could be secondary problems (ASD, VSD). Prolapse and valvular insufficiency could be secondary to cardiac malformations; this needs further study and can be pursued at the occasion of cardiac surgery.

4.1.3 | Endocrine

Hypergonadotropic hypogonadism is a relatively frequent finding present in 7/34 patients (21%). This reflects gonadal dysfunction and in some cases infertility. Measurement of LH and FSH is indicated in children in the pubertal age. If hypergonadotropic hypogonadism is found, treatment with sex hormones is indicated to induce puberty. Because of the observed microphallus, cryptorchidism, and clitoromegaly in some patients, a developmental or hormonal abnormality with developmental consequences cannot be ruled out. No pregnancies have been reported in patients with TALDO-D, but the patient group is also young, with only one adult patient of 25 years old. Possibly, secondary effects resulting in further endocrine symptoms, such as effects on bone and mineral metabolism, could be due to renal loss of proteins or minerals. Decreased production of DHEAS and hormone-binding proteins could be due to reduced protein synthesis from a damaged liver and could lead to ongoing hormonal disturbances. The NADPH/NADP ratio that plays a role in most hormone biosynthetic pathways, and the decreased NADPH in TALDO-D could be a cause for the abnormal steroid hormone production.¹⁹ Single TALDO-D cases have been associated with hyperinsulinism, transient hypothyroidism, or vitamin D deficiency, and other causes outside TALDO-D may be considered.

Short stature and or decreased body mass index (BMI) was described in nine patients in our cohort, of whom two had IGF-1 deficiency. We speculate that the IGF-1 deficiency in one patient was related to delayed puberty due to hypergonadotropic hypogonadism. In the other patient, poor nutrition might have caused the decreased IGF-I. Cardiac or renal problems and the effect of a chronic disease can further contribute to poor growth in some patients. Clinical course ranges from asymptomatic to very severe, with hepatic failure leading to early death. In some patients, clinical symptoms have been reported to improve over time, including liver manifestations.²

4.2 | Diagnosis

Any patient presenting with hepato(spleno)megaly and dysmorphic features associated with skin abnormalities (cutis laxa/wrinkled skin), liver dysfunction (cholestasis, elevated transaminases, coagulopathy), anemia, and/or thrombocytopenia should be investigated for TALDO-D. As not all patients have cutis laxa or splenomegaly—and probably only the most severely affected patients are currently recognized—patients without a diagnosis and a less complete clinical picture should also be considered for testing and will likely be identified with genomic strategies, such as exome sequencing. This might lead to an even greater range of TALDO-D phenotypes. We suggest including TALDO-D in the differential diagnosis of the following diseases: congenital infections: TORCH [acronym for toxoplasmosis, other (*T. pallidum*, varicella-zoster virus, parvovirus), rubella virus, cytomegalovirus, herpes simplex virus]; galactosemia; neonatal hemochromatosis; tyrosinemia type 1; respiratory chain defects; lysosomal storage disorders affecting the liver, such as Niemann-Pick type C disease; congenital disorders of glycosylation (CDG) or hematological malignancies, for which a diagnosis cannot be confirmed. TALDO-D could be considered in patients with septal cardiac defects, cryptorchidism, microphallus, or hypergonadotropic hypogonadism if other symptoms, such as liver impairment and/or hepatomegaly, are present.

All TALDO-D patients had elevated levels of polyols (erythritol, arabitol, ribitol, sedoheptitol, and perseitol) and C7 sugars (sedoheptulose, mannoheptulose, and sedoheptulose-7P) in urine and/or plasma, although in older patients, erythritol or arabitol can be within normal range. Liver transplantation does not appear to change urine polyols,²⁰ probably due to extrahepatic production of polyols in other organs, such as the kidneys. Elevation of polyols are also found in other defects of the pentose phosphate pathway (PPP)—ribose-5-phosphate isomerase deficiency, transketolase deficiency, and sedoheptulokinase deficiency²¹—or in children with chronic kidney disease.²² The diagnosis can therefore be made by combined investigations of polyols and C7 sugars in urine, polyols in plasma, or enzyme analysis on fibroblasts, lymphoblasts, or even fetal liver. Genetic analysis of the *TALDO1* gene can confirm this diagnosis and can be of value for prenatal diagnoses and counseling of families. Prenatal diagnosis might also be possible by measuring polyols and C7 sugars in amniotic fluid.¹⁸ In all patients (100%), two deleterious TALDO alleles were detected, 94% of patients were homozygous for a mutation in the *TALDO1* gene. With exome/genome sequencing, molecular diagnosis of TALDO-D will become more common. In case of a novel unclassified variant, the diagnosis should be confirmed by metabolite measurements in urine and enzymatic analysis in patient fibroblasts or lymphoblasts, or by proving the pathogenicity of the variant. After confirmation of the diagnosis,

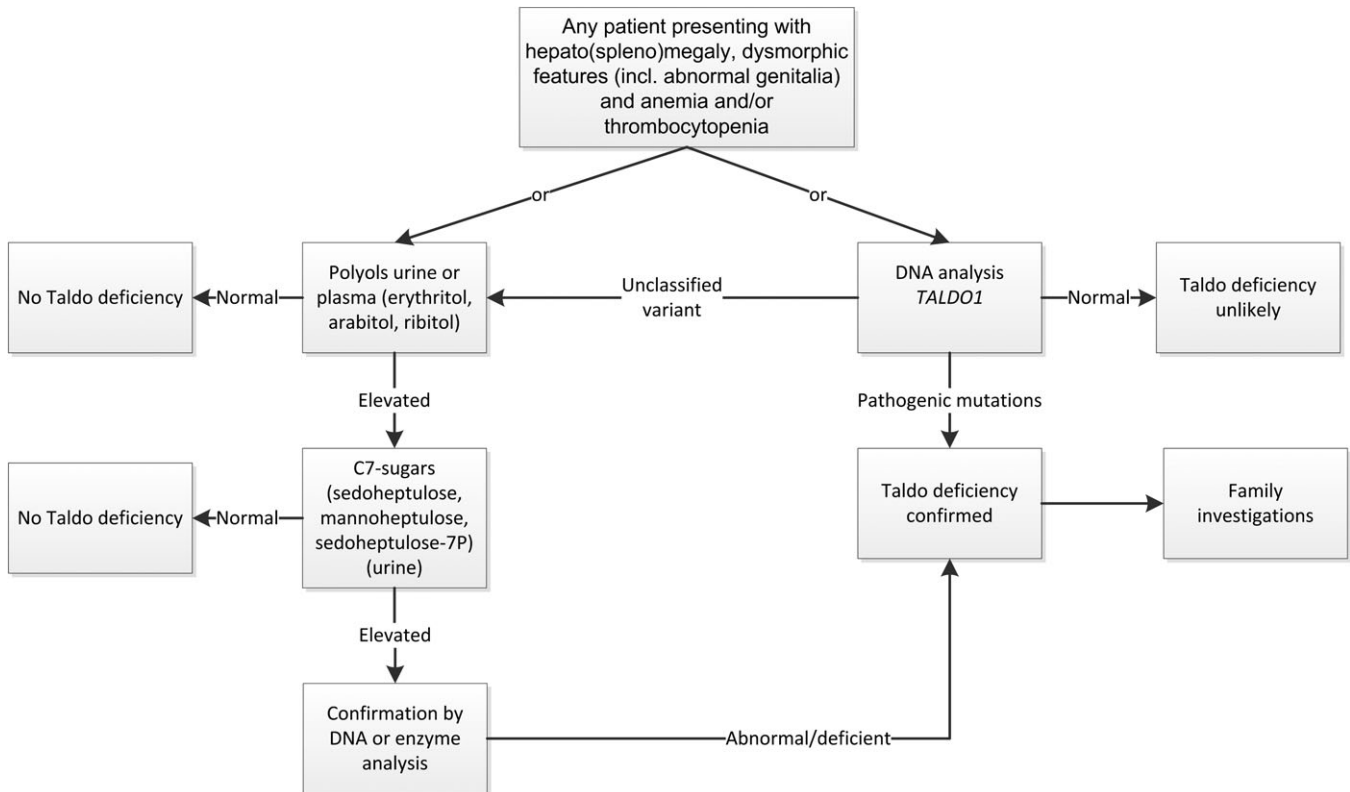


FIGURE 1 Diagnostic flowchart

family screening should be performed in siblings using urine or DNA analysis, even when they are asymptomatic. The recommended diagnostic flowchart is shown in Figure 1.

4.3 | Genotype–phenotype correlation

There is no clear genotype–phenotype correlation, which is hampered by the small number of affected individuals and small number of mutations. In one family (F13), there was a variable presentation among their three sibs: two presented around the age of 7 months with hepatomegaly and developed liver cirrhosis; one of them also developed hepatocellular carcinoma. The third sibling was asymptomatic at the age of 9 years. This family was not known to be consanguineous. Some mutations could be suggestive of late presentation (e.g., the *c.512C > T*; p.Ser171Phe), or early presentation (e.g., *c.512_514delCCT*; p.Ser171del), but this remains to be confirmed.

4.4 | Pathophysiological mechanisms

A defect of TALDO in the pentose phosphate pathway not only has an effect on organogenesis but also on the function of organ systems after birth. Transaldolase is an important enzyme in the PPP, and its deficiency has been shown to deplete NADPH, glutathione (GSH), and diminish nitric oxide (NO) production, lead to decreased mitochondrial transmembrane potential and mitochondrial mass and

reduced adenosine triphosphate/adenosine diphosphate (ATP/ADP) ratio in the liver of *TALDO1*–/– mice.²³ In fibroblast and lymphoblast cell lines from a TALDO-D patient, the nucleotides NADPH and NAD⁺ were also depleted, while ADP-ribose had accumulated. A diminished mitochondrial transmembrane potential was also present, but there was an increased mitochondrial mass, which was associated with increased NO, ATP, and Ca²⁺. Also, enhanced apoptosis was detected.¹⁹ The differences found might be related to difference in organ systems or between species. Failure to recycle ribose-5P through the nonoxidative branch, and conversion of C5 sugar phosphates to C5 sugars to C5 polyols converting NADPH to NADH⁺ results in decreased NADPH necessary for reductive biosynthesis (such as lipid synthesis, cholesterol synthesis, and fatty acid chain elongation) and leads to secondary depletion of GSH and increased oxidative stress. It thus seems expected that the liver (detoxification and synthesis) and bone marrow (hematopoiesis) are the organs most affected. Oxidative stress due to dysfunction of the PPP could account not only for defects in organogenesis but also for chronic liver disease with fibrosis and cirrhosis, hepatocellular carcinoma, and hematological abnormalities.

Accumulation of the potentially toxic sugar-phosphate (sedoheptulose-7P) and/or polyols (erythritol, arabinol, ribitol, sedoheptitol, perseitol) and C7 sugars (mannoheptulose and sedoheptulose) might result in liver damage, as has been

shown in patients with galactosemia in whom galactose-1P and galactitol accumulate. In a mouse model, Perl et al. show that mitochondrial damage resulted in abnormal fertility in *TAL*^{-/-} mice. Treatment with NAC improved glutathione production and fertility in *TAL*^{-/+} mice, but failed to improve fertility in *TAL*^{-/-} mice.²⁴

Demand for the PPP is highest in the liver, and the liver is the organ with the highest enzyme activity next to the kidney.²⁵ Kidney involvement is also one of the most common abnormalities in this patient cohort. Kidney problems reported are mainly tubular dysfunction (high energy demand), where loss of calcium is one of the main features (tubulopathy), possibly even leading to nephrocalcinosis or kidney stones. Although symptoms occur in organs with the highest TALDO enzyme activity, there seems to be no correlation between residual enzymatic activity and clinical outcome.

4.5 | Treatment

To date there is no cure for TALDO-D, and therapy consists of supportive symptomatic treatment: e.g., surgical correction of cardiac abnormalities, supplementation in calcium and vitamin D (when loss is due to tubular dysfunction, taking care to prevent renal stones), and red blood cell and platelet transfusions, when indicated. Preventive measures aim to control the risk of increased bleeding and liver dysfunction, such as vitamin K supplementation, and hormone replacement treatment in hypergonadotropic hypogonadism to induce puberty. Experimental therapies have used NAC—as suggested by preclinical experiments, either alone or in combination with other antioxidants—with limited success. The clinical significance of normalized serum AFP in a patient treated with NAC is uncertain, although it may reflect decreased hepatocyte injury and reduced hepatocarcinogenesis, as suggested in the mouse disease model.^{23,26} A decrease of AFP was also observed in most TALDO-D patients without NAC treatment.²⁷ Further treatment experiences are needed to determine the role of these therapies in TALDO-D.

To date, etiology of hematological abnormalities remains unclear but could be due to liver damage that leads to splenomegaly and sequestration of platelets; decreased cell production; oxidative damage due to limited NADPH; and anemia due to chronic disease. Besides NAC, vitamins C and E have been suggested¹² as antioxidants. Ultimately, liver transplantation should be considered in patients with chronic progressive liver disease and promptly in neonates with liver failure before the age of 6 months, as these patients have shown the highest mortality rates.

4.6 | Markers for follow-up

We recommend following hematological parameters (blood count, including reticulocyte, LDH, haptoglobin and

erythropoietin to better evaluate anemia), liver (clotting factors, transaminases, bilirubin, conjugated bilirubin, gamma-glutamyl transpeptidase (GTP), alkaline phosphatase, and kidney function (glomerular and tubular), and AFP for evaluation of liver carcinogenesis every 3–6 months. Regular visceral imaging studies (US, computed tomography, magnetic resonance imaging) should be performed according to local protocols for patients with chronic liver disease with risk of cirrhosis.

Follow-up of height, weight, and puberty, including Tanner staging, is important. Gonadal function should be assessed based on clinical symptoms such as cryptorchidism, microphallus, delayed puberty, or infertility. No abnormalities were found in the hypothalamic–pituitary–adrenal axis, so routine screening for these issues is not advocated. In our cohort, one patient had primary hypothyroidism of unknown etiology and one patient had subclinical hypothyroidism. We advise low-threshold assessment of thyroid function. The clinician should be aware that in some patients bone mineral content is decreased and should be assessed using dual-energy X-ray absorptiometry (DEXA) scans to monitor the risk for developing osteopenia.

5 | CONCLUSIONS

TALDO-D is a rare metabolic disorder. By combining the information of patients with TALDO-D, we have provided a comprehensive clinical overview with comprehensive clinical information, including endocrine symptoms and a broad clinical phenotype.

ACKNOWLEDGMENTS

This study was sponsored by a stimulation grant of the Dutch Association for the Promotion of Research into Inborn Errors of Metabolism (ESN) 2012. Support to WKC is provided by a grant from the JPB Foundation.

COMPLIANCE WITH ETHICAL STANDARDS

CONFLICTS OF INTEREST

M. Williams, V. Valayannopoulos, R. Al-Tassan, W. Chung, A. Heijboer, W.T. Keng, R. Lapatto, P. McClean, M. Mulder, A. Tyłki-Szymańska, M.J. Walenkamp, M. Alfadhel, H. Alakeel, G. Salomons, W. Eyaid and M. Wameling declare that they have no conflict of interest.

OPEN ACCESS

This article is distributed under the terms of the Creative Commons Attribution 4.0 International License (<http://>

creativecommons.org/licenses/by/4.0/), which permits unrestricted use, distribution, and reproduction in any medium, provided you give appropriate credit to the original author(s) and the source, provide a link to the Creative Commons license, and indicate if changes were made.

REFERENCES

- Verhoeven NM, Huck JH, Roos B, et al. Transaldolase deficiency: liver cirrhosis associated with a new inborn error in the pentose phosphate pathway. *Am J Hum Genet.* 2001;68:1086-1092. <https://doi.org/10.1086/3201081226089>.
- Valayannopoulos V, Verhoeven NM, Mention K, et al. Transaldolase deficiency: a new cause of hydrops fetalis and neonatal multi-organ disease. *J Pediatr.* 2006;149:713-717. <https://doi.org/10.1016/j.jpeds.2006.08.016>.
- Wamelink MM, Struys EA, Salomons GS, Fowler D, Jakobs C, Clayton PT. Transaldolase deficiency in a two-year-old boy with cirrhosis. *Mol Genet Metab.* 2008a;94:255-258. <https://doi.org/10.1016/j.ymgme.2008.01.011>.
- Jansen G, Muskiet FA, Schierbeek H, Berger R, van der Slik W. Capillary gas chromatographic profiling of urinary, plasma and erythrocyte sugars and polyols as their trimethylsilyl derivatives, preceded by a simple and rapid prepurification method. *Clin Chim Acta.* 1986;157:277-293. [https://doi.org/10.1016/0009-8981\(86\)90303-7](https://doi.org/10.1016/0009-8981(86)90303-7).
- Wamelink MM, Smith DE, Jansen EE, Verhoeven NM, Struys EA, Jakobs C. Detection of transaldolase deficiency by quantification of novel seven-carbon chain carbohydrate biomarkers in urine. *J Inherit Metab Dis.* 2007;30:735-742. <https://doi.org/10.1007/s10545-007-0590-2>.
- Eyaid W, Al Harbi T, Anazi S, et al. Transaldolase deficiency: report of 12 new cases and further delineation of the phenotype. *J Inherit Metab Dis.* 2013;36:997-1004. <https://doi.org/10.1007/s10545-012-9577-8>.
- Bui HN, Sluss PM, Blincko S, Knol DL, Blankenstein MA, Heijboer AC. Dynamics of serum testosterone during the menstrual cycle evaluated by daily measurements with an ID-LC-MS/MS method and a 2nd generation automated immunoassay. *Steroids.* 2013;78:96-101. <https://doi.org/10.1016/j.steroids.2012.10.010>.
- Büttler RM, Martens F, Kushnir MM, Ackermans MT, Blankenstein MA, Heijboer AC. Simultaneous measurement of testosterone, androstenedione and dehydroepiandrosterone (DHEA) in serum and plasma using isotope-dilution 2-dimension ultra high performance liquid-chromatography tandem mass spectrometry (ID-LC-MS/MS). *Clin Chim Acta.* 2015a;438:157-159. <https://doi.org/10.1016/j.cca.2014.08.023>.
- Büttler RM, Martens F, Fanelli F, et al. Comparison of 7 published LC-MS/MS methods for the simultaneous measurement of testosterone, androstenedione, and Dehydroepiandrosterone in serum. *Clin Chem.* 2015b;61:1475-1483. <https://doi.org/10.1373/clinchem.2015.242859>.
- Heijboer AC, Blankenstein MA, Kema IP, Buijs MM. Accuracy of 6 routine 25-hydroxyvitamin D assays: influence of vitamin D binding protein concentration. *Clin Chem.* 2012;58:543-548. <https://doi.org/10.1373/clinchem.2011.176545>.
- Büttler RM, Struys EA, Addie R, Blankenstein MA, Heijboer AC. Measurement of dehydroepiandrosterone sulfate (DHEAS) in serum and cerebrospinal fluid by isotope-dilution liquid chromatography tandem mass spectrometry. *Clin Chim Acta.* 2012;414:246-247. <https://doi.org/10.1016/j.cca.2012.09.024>.
- Al-Shamsi AM, Ben-Salem S, Hertecant J, Al-Jasmi F. Transaldolase deficiency caused by the homozygous p.R192C mutation of the TALDO1 gene in four Emirati patients with considerable phenotypic variability. *Eur J Pediatr.* 2015;174:661-668. <https://doi.org/10.1007/s00431-014-2449-5>.
- Tsiakas K, Hempel M, Wamelink MMC, et al. Exercise-induced lactic acidosis and abnormal phagocytosis in a patient with transaldolase deficiency. *J Inherit Metab Dis.* 2015;38(Suppl 1):S184.
- Verhoeven NM, Wallot M, Huck JH, et al. A newborn with severe liver failure, cardiomyopathy and transaldolase deficiency. *J Inherit Metab Dis.* 2005;28:169-179. <https://doi.org/10.1007/s10545-005-5261-6>.
- Engelke UF, Zijlstra FS, Mochel F, et al. Mitochondrial involvement and erythronic acid as a novel biomarker in transaldolase deficiency. *Biochim Biophys Acta.* 2010;1802:1028-1035. <https://doi.org/10.1016/j.bbdis.2010.06.0073117462>.
- Bolognesi M, Merkel C, Sacerdoti D, Nava V, Gatta A. Role of spleen enlargement in cirrhosis with portal hypertension. *Dig Liver Dis.* 2002;34:144-150. [https://doi.org/10.1016/S1590-8658\(02\)80246-8](https://doi.org/10.1016/S1590-8658(02)80246-8).
- Jauniaux E, Hempstock J, Teng C, Battaglia FC, Burton GJ. Polyol concentrations in the fluid compartments of the human conceptus during the first trimester of pregnancy: maintenance of redox potential in a low oxygen environment. *J Clin Endocrinol Metab.* 2005;90:1171-1175. <https://doi.org/10.1210/jc.2004-1513>.
- Wamelink MM, Struys EA, Valayannopoulos V, Gonzales M, Saudubray JM, Jakobs C. Retrospective detection of transaldolase deficiency in amniotic fluid: implications for prenatal diagnosis. *Prenat Diagn.* 2008b;28:460-462. <https://doi.org/10.1002/pd.2002>.
- Qian Y, Banerjee S, Grossman CE, et al. Transaldolase deficiency influences the pentose phosphate pathway, mitochondrial homeostasis and apoptosis signal processing. *Biochem J.* 2008;415:123-134. <https://doi.org/10.1042/BJ20080722>.
- Leduc CA, Crouch EE, Wilson A, et al. Novel association of early onset hepatocellular carcinoma with transaldolase deficiency. *JIMD Rep.* 2014;12:121-127. https://doi.org/10.1007/8904_2013_254.
- Wamelink MMC, Valayannopoulos V, Garavaglia B. Disorders of glycolysis and the pentose phosphate pathway. In: Saudubray JM, Baumgartner M, Waler JM, eds. *Inborn Metabolic Diseases, Diagnosis and Treatment.* 6th ed. Berlin, Heidelberg: Springer; 2016.
- Vanlede K, Kluijtmans LA, Monnens L, Levchenko E. Urinary excretion of polyols and sugars in children with chronic kidney disease. *Pediatr Nephrol.* 2015;30:1537-1540. <https://doi.org/10.1007/s00467-015-3135-1>.
- Hanczko R, Fernandez DR, Doherty E, et al. Prevention of hepatocarcinogenesis and increased susceptibility to acetaminophen-induced liver failure in transaldolase-deficient mice by acetylcysteine. *J Clin Invest.* 2009;119:1546-1557. <https://doi.org/10.1172/JCI357222689120>.
- Perl A, Qian Y, Chohan KR, et al. Transaldolase is essential for maintenance of the mitochondrial transmembrane potential and fertility of spermatozoa. *Proc Natl Acad Sci U S A.* 2006;103:14813-14818. <https://doi.org/10.1073/pnas.06026781031595434>.
- James HM, Williams SG, Bais R, Rofe AM, Edwards JB, Conyers RA. The metabolic production of oxalate from xylitol:

- activities of transketolase, transaldolase, fructokinase and aldolase in liver, kidney, brain, heart and muscle in the rat, mouse, Guinea pig, rabbit and human. *Int J Vitam Nutr Res Suppl.* 1985;28:29-46.
26. Rodan LH, Berry GT. N-acetylcysteine therapy in an infant with Transaldolase deficiency is well tolerated and associated with normalization of alpha fetoprotein levels. *JIMD Rep.* 2017;31:73-77. https://doi.org/10.1007/8904_2016_555.
27. Lipiński P, Pawłowska J, Stradomska T, et al. Long-term systematic monitoring of four polish Transaldolase deficient patients. *JIMD Rep.* 2018. https://doi.org/10.1007/8904_2017_83.

SUPPORTING INFORMATION

Additional supporting information may be found online in the Supporting Information section at the end of the article.

How to cite this article: Williams M, Valayannopoulos V, Altassan R, et al. Clinical, biochemical, and molecular overview of transaldolase deficiency and evaluation of the endocrine function: Update of 34 patients. *J Inherit Metab Dis.* 2019;42: 147–158. <https://doi.org/10.1002/jimd.12036>