

## CASE REPORT

### Prenatal diagnosis of diaphanospondylodysostosis (DSD): a case report

Cornelia Hofstaetter<sup>1</sup> , Carolina Courage<sup>2,3</sup>, Deborah Bartholdi<sup>2</sup>, Saskia Biskup<sup>4</sup> & Luigi Raio<sup>1</sup>

<sup>1</sup>Department of Obstetrics & Gynecology, Inselspital, University of Bern, Switzerland

<sup>2</sup>Division of Human Genetics, Department of Pediatrics, Inselspital, University of Bern, Switzerland

<sup>3</sup>The Folkhälsan Institute of Genetics, University of Helsinki, Helsinki, Finland

<sup>4</sup>Praxis für Humangenetik, Paul-Ehrlich-Strasse 22, DE 72076, Tübingen, Germany

#### Correspondence

Cornelia Hofstaetter, Department of Obstetrics and Gynecology and of Human Genetics, Inselspital, University of Bern, Effingerstrasse 102, Bern CH 3010, Switzerland. Tel: 0041 31 632 1010; Fax: 0041 31 632 16 46; E-mail: cornelia.hofstaetter@insel.ch

#### Funding Information

Dr. C. Courage was funded by the SNSF Early Postdoc Fellowship.

Received: 31 January 2017; Revised: 17 July 2017; Accepted: 25 August 2017

*Clinical Case Reports* 2018; 6(2): 420–425

doi: 10.1002/ccr3.1368

## Introduction

Diaphanospondylodysostosis (DSD) is a rare, perinatal often lethal, autosomal recessively inherited skeletal dysplasia. It is characterized by an abnormal ossification of the spine, a small thorax, and posterior rib gaps and commonly associated with nephroblastomatosis or cystic kidneys. Associated dysmorphic features include ocular hypertelorism, epicanthal folds, depressed nasal bridge with a short nose and low set ears. DSD is caused by homozygous or compound heterozygous mutations in the bone morphogenetic protein-binding endothelial regulator protein (BMPER) gene on chromosome 7p14. There are only case reports in genetic and pediatric literature published since 2003 and few reports on prenatal diagnosis so far [1–5]. We present a first case with prenatal diagnosis of DSD in which molecular genetic analysis was performed, and a mutation was found which to our knowledge had not been published in the literature yet.

## Key Clinical Message

We present a case of diaphanospondylodysostosis (DSD) which showed increased nuchal translucency at 1st trimester and missing ossification of the lower spine, short ribs with posterior gaps, and absent nasal bone in midtrimester. Autopsy revealed additionally bilateral nephroblastomatosis. Molecular genetic analysis showed a new mutation in the BMPER gene.

## Keywords

BMPER gene, diaphanospondylodysostosis, increased nuchal translucency, missing ossification of spine, prenatal diagnosis, ultrasound

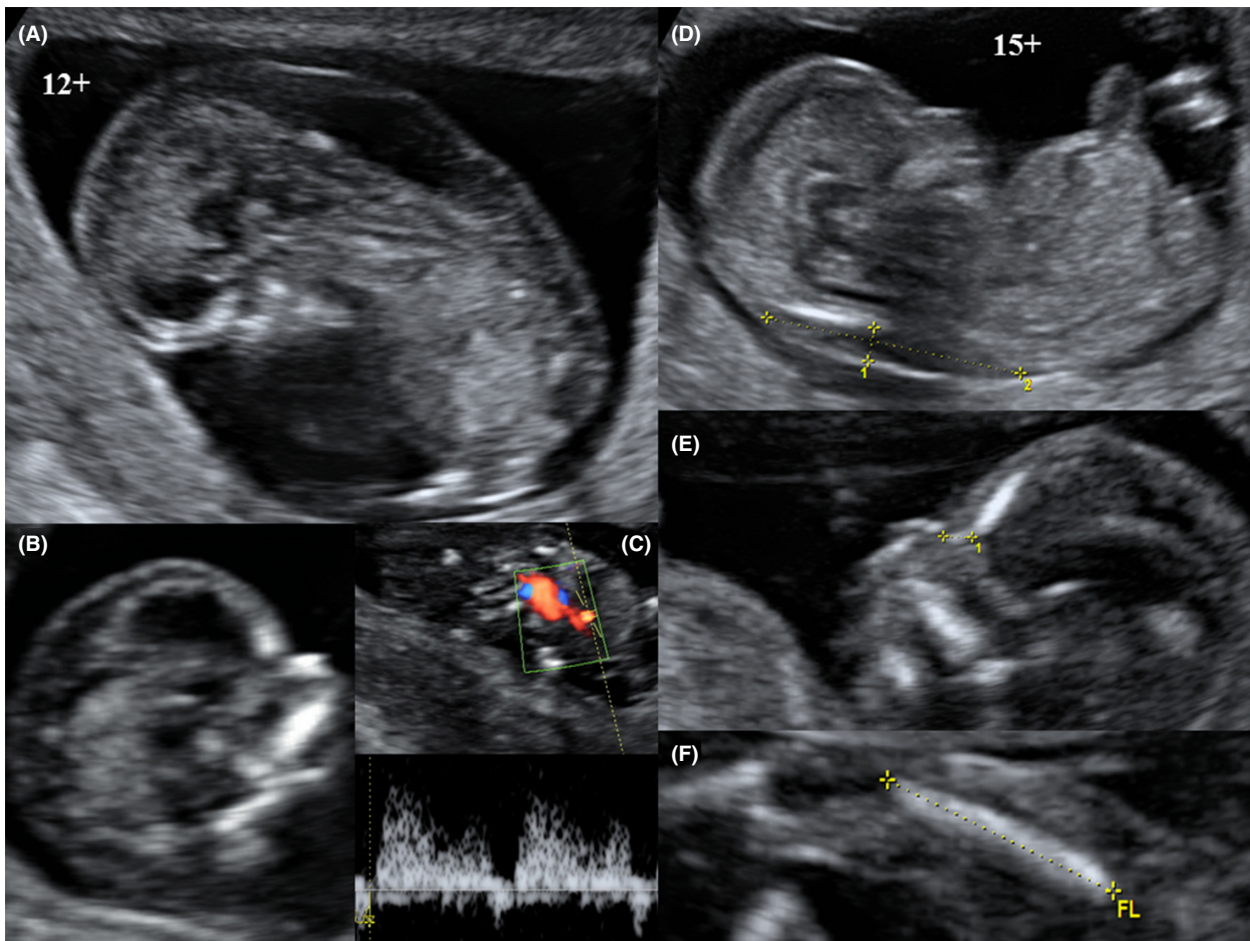
## Case History

We report on a 25-year-old primigravida who was seen for a second opinion at 12 + 4 weeks of gestation because of increased nuchal translucency of 6.4 mm and increased risk for trisomy 21 of 1:2. The conception and the initial course of the pregnancy had been normal. The patient's past history and the family history were uneventful on both sides. There was no consanguinity between the parents. The ultrasonography showed a fetus with an adequate growth, but a cystic hygroma of 7.3 × 22 × 38 mm (deep x with x length) and generalized skin edema of 2.8 mm. The fetal anatomy, especially the spine, appeared normal at this time. A small nasal bone was visible and the profile looked normal. There was a normal blood flow over tricuspid valve (TV) but reverse flow in the ductus venosus (DV). Chorion villi sampling was performed and showed a normal male karyotype: 46,XY and subsequent microarray analysis did not reveal any disease-causing submicroscopic aberrations. Ultrasonography at

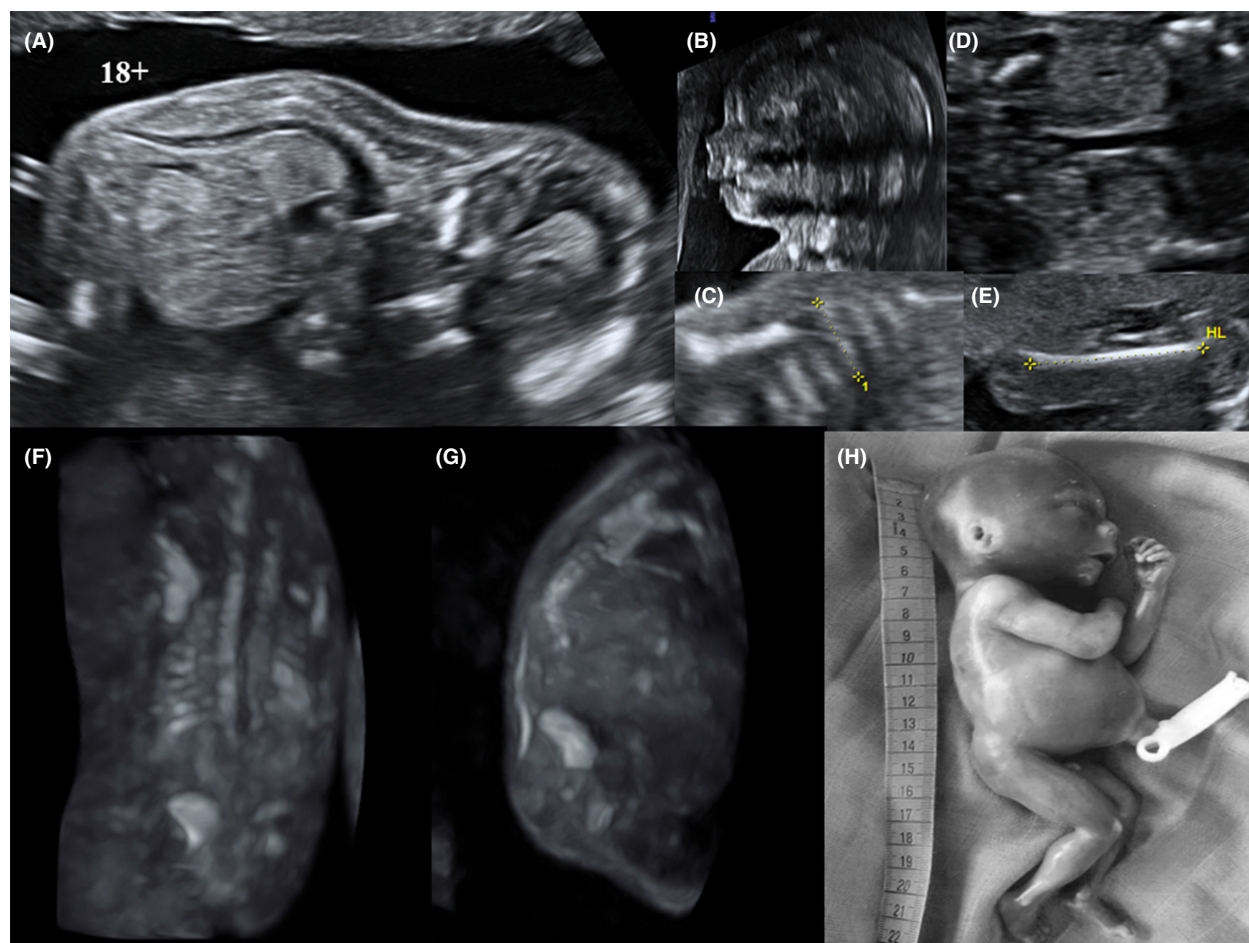
15 + 2 weeks showed a normal fetal growth but persistence of cystic hygroma of 5.4 mm and generalized skin edema. The nasal bone seemed to be hypoplastic, whereas the aspects of the fetal heart, both kidneys, and the Doppler sonography of TV and DV were normal. The fetal spine was incompletely visible due to dorso-posterior position (Fig. 1). At 18 + 4, the fetus showed a normal growth, a partial regression of the cystic hygroma to 4.3 mm, and no skin edema. The nasal bone was no more visible, and the fetal body length appeared too short. The vertebral bodies were ossified only in the cervical and thoracic but not in the lumbar and sacral part of the spine. The thoracic spine showed pronounced kyphosis. However, the neural tube was clearly visible also in the lower parts. The fetal ribs were short and showed a dorsal gap. All diaphyses had a normal length and form. The kidneys appeared normal (Fig. 2). A fetal MRI confirmed the sonographic findings of agenesis of the lumbar and

sacral spine and dysplastic ribs but showed normal abdominal organs. The prognosis was considered to be lethal because of the incomplete ossification of the lower spine and the small thorax. The parents decided to terminate the pregnancy after interdisciplinary counseling. Postmortem examination confirmed the ultrasonographic findings such as agenesis of the spine below the 10th thoracic vertebra and the small thorax. It also revealed bilateral nephroblastomatosis.

We suspected diaphanospondylodysostosis as the putative diagnosis and initiated molecular analysis of the BMPER gene in a DNA sample of the CVS, which was delayed because of finding an adequate genetic institute and of financial reasons. It showed a homozygous nonsense mutation c.[496T>A; 501\_502delGT]; p.[Cys166Ser; Phe168\*] in the BMPER gene which had not been reported in the literature so far but is considered to be pathogenic, in particular the mutation c.501\_502delGT;



**Figure 1.** On the left side: ultrasonographic images of the fetus at 12+ weeks of gestation with increased nuchal translucency (NT) and hygroma colli (A), present nasal bone (B), and reversed blood flow in the Ductus venosus (C) and on the right side at 15+ weeks with hygroma colli (D), hypoplastic nasal bone (E), and normal femur length (F).



**Figure 2.** Ultrasonographic images of the fetus at 18+ weeks of gestation with missing ossification of the lumbar and sacral spine and clearly visible spinal cord (A), absent nasal bone (B), short ribs (C), both kidneys (D), and humerus (E) in the upper half. 3D ultrasound of the fetal spine and ribs in a frontal (F) and sagittal view (G) with missing ossification of the lower spine and the dorsal rib gaps (†) and an image of the born fetus (H) in the lower half.

p.Phe168\*. Segregation analysis confirmed that the parents carry this mutation in the compound heterozygous state (Table 1). The couple was counseled of the recurrence risk of 25% and the option of genetic prenatal diagnostic in further pregnancies. In the meantime, the mother gave birth to a healthy child.

### Discussion

Diaphanospondylodysostosis (DSD) is a rare (<1/1,000,000 pregnancies) and severe skeletal dysplasia, which leads to intra-uterine or neonatal death due to respiratory failure in most of the cases. The characteristic

**Table 1.** New found mutation in the BMPER.

Gene	Mutation			
BMPER	c.[496T>A; 501_502delGT]; [496T>A; 501_502delGT], p.[Cys166Ser; <b>Phe 168*</b> ]; [Cys166Ser; <b>Phe168*</b> ]			
Gene	Variant	Fetus symptomatic	Mother asymptomatic	Father asymptomatic
BMPER	c.[496T>A; 501_502delGT], p.[Cys166Ser; <b>Phe168*</b> ]	Homozygous	Heterozygous	Heterozygous

Method: amplification of the coded areas and the adjacent Exon-Intron regions of the gene with PCR method and bidirectional direct sequencing of PCR products with flanking and internal primers (LDT, laboratory developed test).

**Table 2.** Previous published cases of DSD.

Author	Case	Dx at week	Sonography	Outcome
Prefumo <i>et al.</i> [1]	1	20+	No ossification of lumbar + sacral spine, abnormal ribs, small thorax	TOP; X-Ray: no ossification of lower spine, postrrib gaps; Histology: nephrogenic rests
	2, sib of 1	17+	NT 7.2 mm at 12+, no ossification of lumbosacral spine, short ribs, narrow thorax, bilateral hydronephrosis	TOP; no ossification of lower spine, multiple cysts and nephrogenic rests in both kidneys
	3, sib of 1 + 2	12+	NT 6.1 mm, CRL < GA, no ossification of thoracic and lumbar spine	TOP; no autopsy
Gonzales <i>et al.</i> [2]	1	36+	Lumbosacral MMC, large cystic kidneys, oligohydramnios	Stillbirth at 39+, boy, 3460 g, lumbosacral spina bifida, X-Ray: no ossification of lumbosacral spine, reduced ribs; histology: tubular and glomerular cysts
	2, sib of 1	37+	IUGR, cystic kidneys	Birth at 39+, girl, 2840 g, PND of respiratory insufficiency; autopsy: no ossification of lower spine, bilateral nephroblastomatosis
	3	41+	Oligohydramnios	Birth at 41+, boy, PND of respiratory insufficiency, X-Ray: no ossification of lower spine; autopsy: normal kidneys
	4	40+		Birth at term, boy 3100 g, PND of respiratory insufficiency; X-Ray: no ossification of lower spine; no autopsy
Vatanavicharn <i>et al.</i> [3]	1	38+		Birth at 38+, boy, 3870 g, NND of respiratory insufficiency; X-Ray: no ossification of thoracic, lumbar + sacral spine, posterior rib gaps; autopsy: nephroblastomatosis
	2	40+		Birth at 40+, boy, 2300 g(3rd centile), PND of respiratory insufficiency; X-Ray: no ossification of lumbosacral spine, posterior rib gaps; autopsy: normal kidneys
	3, sib of 2	17+	No ossification of thoracic and lumbar spine	TOP; X-Ray: no ossification of lower spine, posterior rib gaps
	4, sib of 2 + 3	12+	Cystic hygroma, incomplete developed spine and ribs	TOP; X-Ray: no ossification of spine
	5	23+	Caudal regression syndrome, cystic kidneys	Birth at 38+, female 3050 g, PND of respiratory insufficiency; US: renal cyst, no ossification of sacral spine; autopsy: cortical cysts in kidneys
	6	40+		Birth at 40+, boy, intubation; CT: no ossification of lumbosacral spine, abnormal ribs; US: multiple kidney cysts. Delayed development at 9 months

malformations occur early in embryonic development during blastogenesis and are caused by abnormal development and differentiation of the paraxial mesoderm. Additionally, nephrogenic rests persist in the kidneys, which develop later to cystic dysplasia of the kidneys. The typical manifestations of affected fetuses are absent ossification of the spine, rib malformation with posterior gaps, thoracic hypoplasia, and cystic malformation of the kidneys, all present in the fetus described herein. Depressed nasal bridge, ocular hypertelorism, epicanthal folds, and low set ears are frequent findings. An increased nuchal translucency at first-trimester ultrasound also is often present, as in the presented case.

There had been only case reports in pediatric and genetic literature since 2003, describing mainly siblings of both sexes (Table 2). In 2003, Prefumo *et al.* [1] described three siblings of nonconsanguineous parents. An absent ossification of the lower spine, rib

abnormalities with posterior gaps, small chest and normal limb bones were seen at 20 weeks of gestation in the first affected pregnancy. Postmortem examination showed also islands of intralobular nephrogenic rests. In the second case, an increased NT of 7.2 mm was seen at 12 + 6 weeks and CVS showed a normal karyotype. At 17 weeks, a small narrow chest, broad and shortened ribs, absent lumbosacral spinal structures, and bilateral hydronephrosis were detected by ultrasound. The pregnancy was terminated, and the findings were confirmed in autopsy. In the following pregnancy, the NT was 6.1 mm, the CRL was <5th centile, and there was no ossification of the thoracic and lumbar spine visible at 12 + 6 weeks. The pregnancy was terminated. These observations led the authors to conclude that the fetuses might suffer from a novel autosomal recessive syndrome. Gonzales *et al.* [2] reported four patients from three families with similar findings of the skeletal system and

nephroblastomatosis in 2005. The babies were stillborn or died shortly after birth of respiratory insufficiency. The authors named this lethal autosomal recessive syndrome diaphanospondylodysostosis (DSD). In 2007, Vatanavicharn et al. [3] reported six more cases from four families. Most of the infants died in the neonatal period of respiratory insufficiency. One child survived up to 9 months and had severe development delay and generalized hypotonia. Molecular analysis of PAX1 (167411) and MEOX1 (600147) showed normal results (Table 1). Finally, in 2010, Funari et al. [4] identified mutation in the BMPER gene as underlying cause of DSD, which was confirmed by Ben-Neriah et al. [5] in 2011. Two papers from 2012 [6, 7] report of two infants with DSD, who survived longer and developed anaplastic Wilms tumor of both kidneys at the age of 18 and 20 months and died at the age 4 and 5 years, respectively.

Increased nuchal translucency is a leading ultrasonographic sign of chromosomal disorder but is also observed in skeletal dysplasias such as osteogenesis imperfecta, achondrogenesis, thanatophoric dwarfism, and asphyxiating thoracic dystrophy. These disorders present with short limb bones and small thorax, but a normal ossified spine, already in early gestation. [8]. In our case, the ossification defects of the spine and ribs were detected later in pregnancy, and the nephroblastomatosis was only seen in postnatal histology as in some of the previous case reports [1]. Therefore, it is advisable to follow pregnancies with enlarged NT and check the skeletal system carefully. If the lower spine is not visible, DSD should be considered, but the following syndromes with similar abnormalities must be excluded: Caudal regression syndrome, which also has agenesis of the lower spine, hypoplasia of the pelvis, and cystic dysplasia of the kidneys. However, it is sporadic and present in about 28% of pregnancies with insufficiently controlled diabetes. In Currarino syndrome, the sacroccoccygeal defect is associated with a sickle-shaped sacrum, an anterior sacral meningocele, a presacral mass as a lipoma, teratoma or hamartoma, and anorectal malformations. It displays an autosomal dominant inheritance pattern. Meckel–Gruber syndrome is characterized by encephalocele and polycystic kidneys, already visible in early pregnancy. And typical features of Sirenomelia are the fusion of the lower limbs and the malrotation of the feet. It is also associated with insufficiently controlled diabetes [9].

In conclusion, in cases with increased nuchal translucency at the first-trimester screening and normal karyotyping, we recommend a careful examination of the fetal anatomy, including the spine, to exclude skeletal malformations. DSD must be considered in fetuses with missing ossification of the spine and short ribs, abnormal nasal

bone, and kidney alterations. Molecular genetic analysis allows to distinguish DSD from other disorders.

## Acknowledgment

Dr. C. Courage was funded by the SNSF Early Postdoc Fellowship.

## Authorship

CH: docent and head consultant in obstetrics and fetal medicine specialist, has done the ultrasound examinations and the chorion villi sampling, also had the major role in writing the case report. CC: consultant and research fellow in human genetics, did the genetic counseling of the parents at the ultrasound examinations. DB: docent and consultant in human genetics, arranged the molecular genetic analysis of the CVS sampling, and did the final counseling. SB: human genetic specialist did the molecular genetic analysis at her institute. LR: professor and head consultant in obstetrics and fetal medicine specialist, also did ultrasound examination of the fetus. All authors had access to the data and a role in writing the manuscript.

## Conflict of Interest

None declared.

## References

- Prefumo, F., T. Homfray, I. Jeffrey, I. Moore, and B. Thilaganathan. 2003. A newly recognized autosomal recessive syndrome with abnormal vertebral ossification, rib abnormalities and nephrogenic rests. *Am. J. Med. Genet.* 120A:386–388.
- Gonzales, M., A. Verloes, M. H. Frison, C. Perrotez, O. Bourdet, F. Encha-Razavi, et al. 2005. Diaphanospondylodysostosis (DSD): confirmation of a recessive disorder with abnormal vertebral ossification and nephroblastomatosis. *Am. J. Med. Genet.* 136A:373–378.
- Vatanavicharn, N., J. M. Graham Jr, C. J. Curry, S. Pepkowitz, R. S. Lachman, D. L. Rimoin, et al. 2007. Diaphanospondylodysostosis. Six new cases and exclusion of the candidate genes, PAX1 and MEOX1. *Am. J. Med. Genet. Part A* 143A:2292–2302.
- Funari, V. A., D. Krakow, L. Nevarez, Z. Chen, T. I. Funari, et al. 2010. BMPER mutation in diaphanospondylodysostosis identified by ancestral autozygosity mapping and targeted high-throughput sequencing. *Am. J. Human Genet.* 87:532–537.
- Ben-Neriah, Z., R. Michaelson-Cohen, M. Inbar-Feigenberg, M. Nadjari, S. Zeligson, et al. 2011. A deleterious founder mutation in the BMPER gene causes

- diaphanospondylodysostosis (DSD). *Am. J. Med. Genet. Part A* 155A:2801–2806.
6. Tasian, S. K., G. E. Kim, D. N. Miniati, and S. G. DuBois. 2012. Development of anaplastic wilms tumor and subsequent relapse in a child with diaphanospondylodysostosis. *J. Pediatr. Hematol. Oncol.* 34:548–551.
  7. Scottoline, B., S. Rosenthal, R. Keisari, and R. Kirpekar. 2012. Long-term survival with diaphanospondylodysostosis (DSD): survival to 5 years and further phenotypic characteristics. *Am. J. Med. Genet. Part A* 158A:1447–1451.
  8. Makrydimas, G., A. Souka, H. Skentou, D. Lolis, and K. Nicolaidis. 2001. Osteogenesis imperfecta and other skeletal dysplasias presenting with increased nuchal translucency in the first trimester. *Am. J. Med. Genet.* 98:117–120.
  9. Wiedemann, H. R., and J. Kunze. 1995. *Atlas der Klinischen Syndrome für Klinik und Praxis*. Schattauer Verlag; 4. Auflage,:90-91, 92-93,344-345,638-639.