

Arthroscopic Coracoclavicular Ligament Reconstruction Using Graft Augmentation and Titanium Implants



Juha O. Ranne, M.D., Terho U. Kainonen, M.D., Jussi A. Kosola, M.D.,
Lasse L. Lempainen, M.D., Kari J. Kanto, M.D., and Janne T. Lehtinen, M.D.

Abstract: Several techniques have been introduced to treat acromioclavicular separation with coracoclavicular ligament reconstruction using graft augmentation. A modified arthroscopic technique for coracoclavicular ligament reconstruction was used based on a previous technique where the supportive device and tendon graft share the clavicular and coracoid drill holes. A notable problem with the previous technique was large protruding suture knots on the washer and clavicle, which could predispose to wound infection. In this modified technique, titanium implants were introduced. The implants hid the suture knot on the clavicle, and less foreign material was needed between the clavicular and coracoid implants.

Few skeletal traumas are associated with as many operative techniques as acromioclavicular (AC) joint separation. Controversy exists regarding the indications for surgery, but a common consensus is that grade I-II AC separations should be treated conservatively, whereas grade III-V dislocations may need surgery. Many recent techniques include coracoclavicular (CC) tendon reconstruction using tendon grafts and are either arthroscopic or arthroscopy-assisted.¹⁻⁶

A modified version of the arthroscopic CC reconstruction technique described by Ranne et al.⁷ was used in this study where the anterior tendon graft limb was fixed to

the middle of the clavicle, recreating the trapezoid ligament. The posterior graft limb was wrapped around the posterior edge of the clavicle, recreating the conoid ligament (Fig 1A). Furthermore, the posterior limb prevented posterior instability of the distal clavicle. Reconstruction of both ligaments stabilized the distal clavicle and was anatomically accurate. The technique specifies one 6-mm and one 4.5-mm drill hole in the clavicle and coracoid, respectively. Essentially, in this technique, the graft and the interconnecting sutures share the same drill holes to minimize clavicular fracture risk.

Although practical, the washer on the clavicle in the previous technique had significant problems: the fixation sutures left large protruding knots on the washer and clavicle. In several cases, irritation or infection of the clavicular wound was noted. Large palpable knots also remained underneath the healed skin wound occasionally, making the patients uncomfortable. An interference screw was used to fix the graft limbs in the clavicular drill holes, which increased the amount of foreign material underneath the clavicular skin wound. The washer also spread the interconnecting sutures into a funnel shape, gradually up to 8 mm × 10 mm, inside the clavicular drill hole. These led to increased tunnel widening of the clavicular drill hole.⁸

The Technical Note aims to introduce the modified CC reconstruction technique using knot hiding clavicular and subcoracoid titanium implants. The implants hide the protruding knots on the clavicle and allow less foreign material in the reconstruction, especially focusing on early-phase wound healing.

From the Sports Trauma Research Unit, Neo Hospital (J.O.R., T.U.K., L.L.L.); the Paavo Nurmi Centre, Department of Physical Activity and Health, the University of Turku (J.O.R., L.L.L.), Turku; Department of Orthopedics, The Hatanpää City Hospital (K.J.K., J.T.L.), Tampere; and Department of Orthopaedics and Traumatology, Helsinki University Hospital (J.A.K.), Helsinki, Finland.

The authors report the following potential conflicts of interest or sources of funding: J.O.R. is a shareholder of the CC-Clip company, which has the rights to the CE mark and the US patent. Full ICMJE author disclosure forms are available for this article online, as [supplementary material](#).

Received October 15, 2017; accepted November 27, 2017.

Address correspondence to Juha O. Ranne, M.D., Neo Hospital, Joukahaisenkatu 6, 20520 Turku, Finland. E-mail: juha.ranne@sairaalaneof.fi or rannejuha@gmail.com

© 2017 by the Arthroscopy Association of North America. Published by Elsevier. This is an open access article under the CC BY-NC-ND license (<http://creativecommons.org/licenses/by-nc-nd/4.0/>).

2212-6287/171283

<https://doi.org/10.1016/j.eats.2017.11.005>

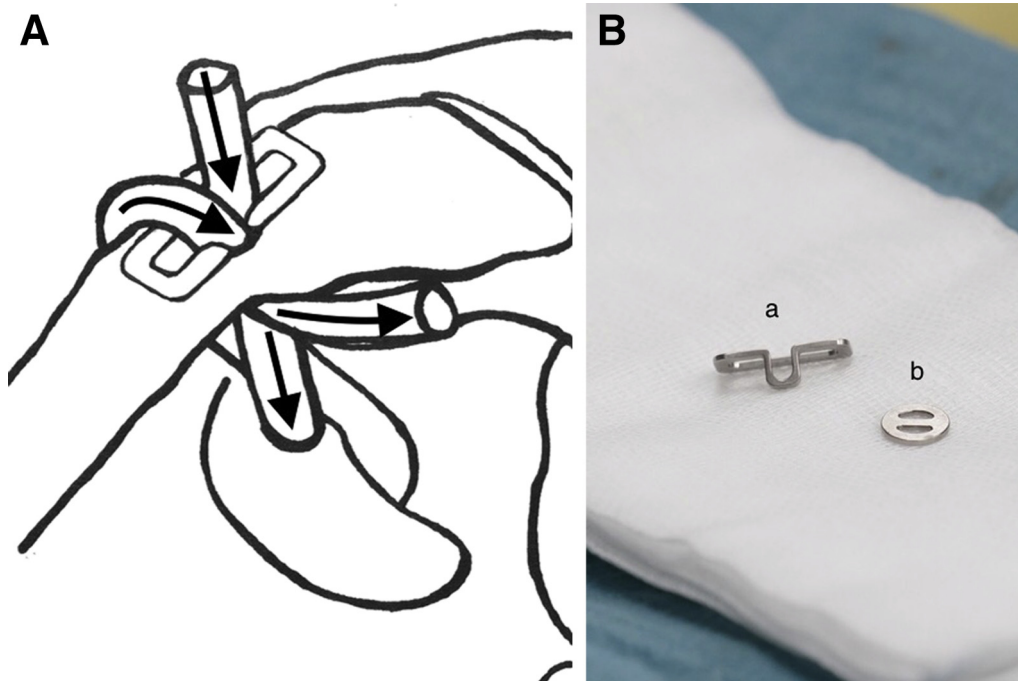


Fig 1. (A) In this technique, the anterior tendon graft limb is fixed to the middle of the clavicle, recreating the trapezoid ligament. The posterior graft limb is wrapped around the posterior edge of the clavicle, recreating the conoid ligament (arrows). Left shoulder, anteromedial view. (B) The Clavicular Clip (a) and Subcoracoid Clip (b). The length of the Clavicular Clip is 14 mm, 16 mm, or 20 mm.

The Technique

The Implants

The Clavicular Clip (CC-Clip, Turku, Finland), made of medical titanium, is designed to sit flush on the

clavicular surface without leaving a protruding knot. The loop of the clip hides the connecting suture knot in the clavicular drill hole. The 5-mm Clavicular Clip loop and the knot located in the 6-mm drill hole, at the same time, squeeze the tendon graft limbs against the

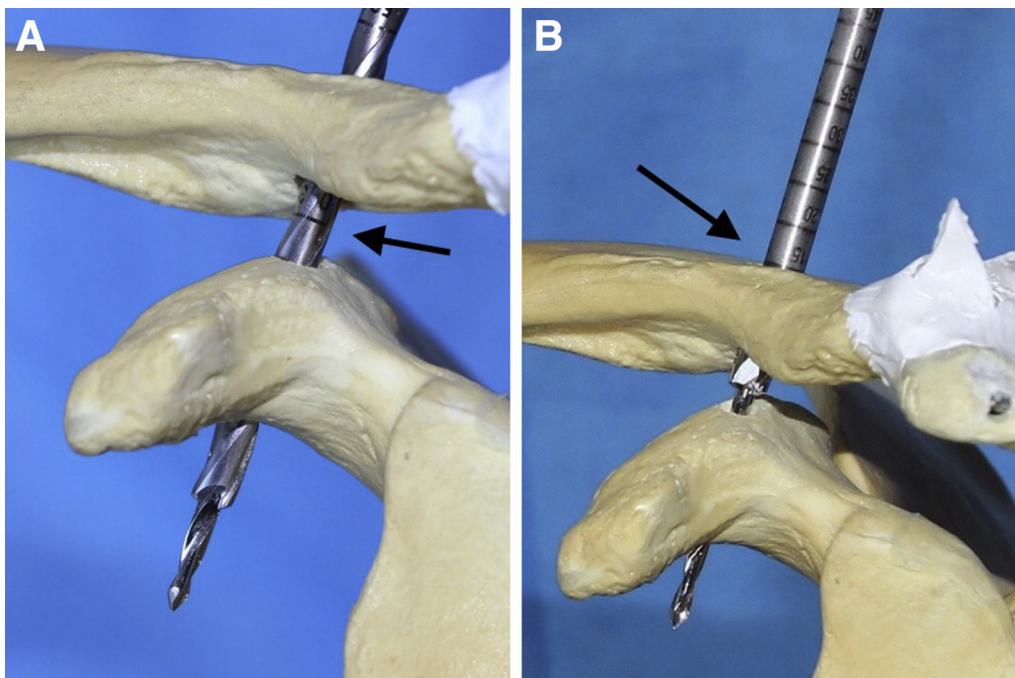


Fig 2. (A) Using the conventional drill guide technique, a 4.5-mm drill hole is made through the clavicle and coracoid. Left shoulder, anterolateral view. (B) The clavicular drill hole is widened to 6 mm (arrow). Left shoulder, anterolateral view.

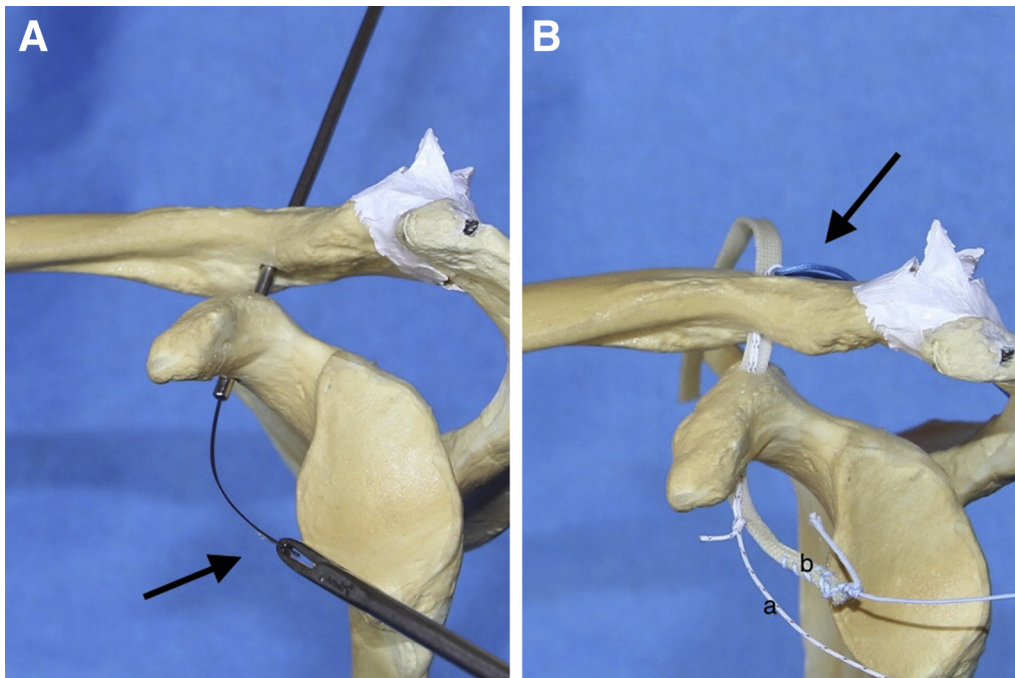


Fig 3. (A) The passing sutures are pulled through the drill holes using the Blunt Lasso Guide. In this technique, it is important that the welded end of the lasso loop always come first (arrow). Otherwise the welding easily splits leaving the passing suture loose. Left shoulder, anterior view. (B) The No. 2 passing suture (a) for the interconnecting No. 5 suture (arrow). It is important that the tendon graft (b) is always pulled first through the drill holes to avoid entanglement. Left shoulder, anterior view.

clavicular drill-hole wall. Hence an interference screw is unnecessary decreasing the amount of foreign material required. The Subcoracoid Clip (CC-Clip) is designed to be a simple ring with a smooth crossbar (Fig 1B). The interconnecting suture is attached to the Subcoracoid Clip with a loop knot, which reduces friction on the suture. The clips allow the use of a single double-folded No. 5 braided nonresorbable suture. The line between the Clavicular Clip loop and the Subcoracoid Clip is straight through the drill holes; therefore, a No. 5 braided nonresorbable interconnecting suture is sufficiently strong. In cyclical load stress tests, forces up to 400 N per >100 cycles can be applied to suture knots without their snapping depending on the suture material (Mectalent, Oulu, Finland; Design Verification Report 2017; No. MEC-157). The implants are to be left in place and subsequent implant removal is unneeded.

The Operative Technique

The patient is placed in the beach chair position. A semitendinosus autograft or allograft, as well as artificial tendon grafts, may be used as the tendon graft, which is prepared by fixing a No. 2 passing suture at one end of the graft. A No. 2 passing suture is also attached to a double-folded No. 5 braided nonresorbable interconnecting suture. Four portals (posterior, lateral, anterolateral, and clavicular) are made. A standard 30° arthroscope is used. A longitudinal clavicular incision (2.5 cm in length) is made over the clavicle, 2.5 cm medially from the AC joint.




Fig 4. The Subcoracoid Clip in its place underneath the coracoid. Note the loop fixation (arrow). Left shoulder, medial view.

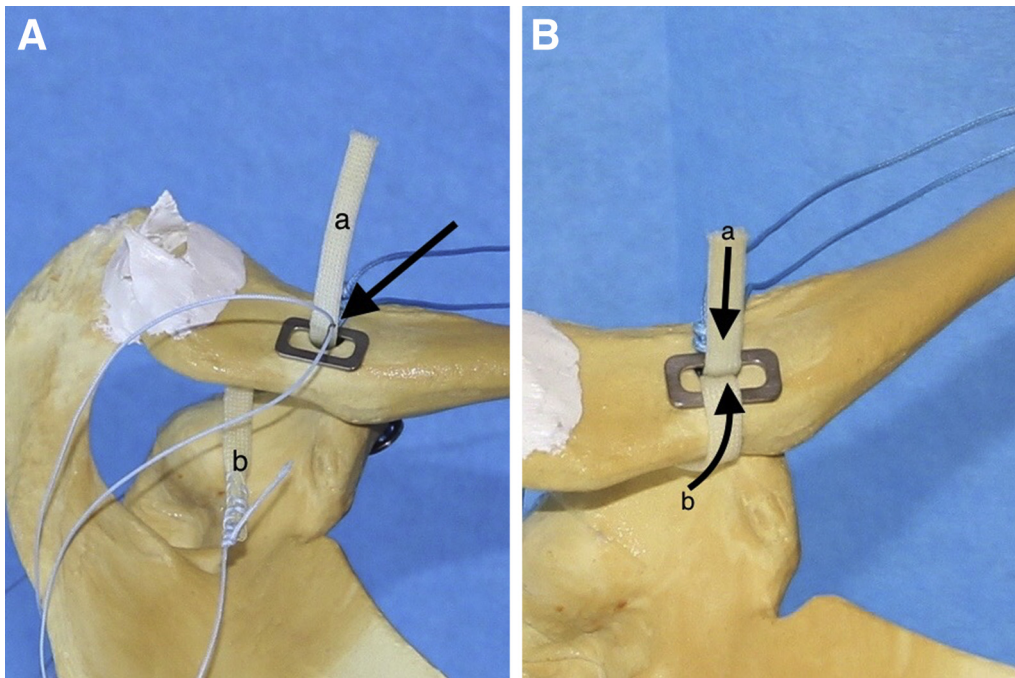


Fig 5. (A) The anterior graft limb (a). The Blunt Lasso Guide is used once again to pull the passing suture for the dorsal graft limb (b) through the clavicular drill hole. Again, it is important that the welded end of the lasso loop comes first (arrow). Left shoulder, posterosuperior view. (B) The anterior graft limb (a) runs through the clavicular and coracoid drill holes. The end of the dorsal graft limb (b) is wrapped around the dorsal edge of the clavicle and dorsal rim of the Clavicular Clip. Then it is pulled through the clavicular drill hole adjacent to the anterior graft limb (a). Left shoulder, posterosuperior view.

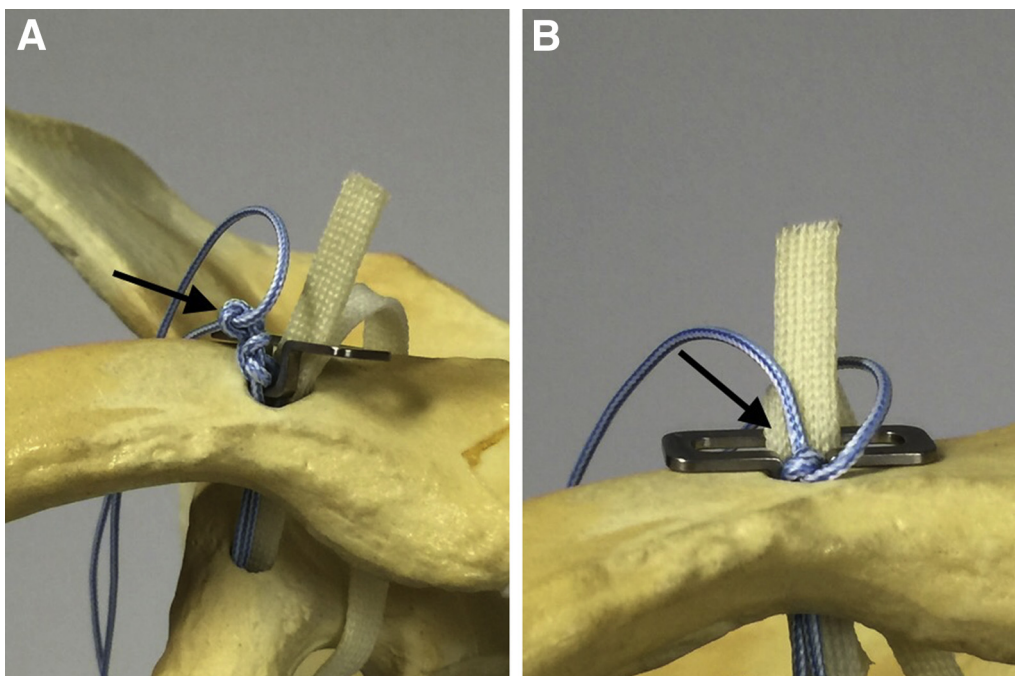


Fig 6. (A) The Clavicular Clip on the edge of the clavicular drill hole. Note the No. 5 suture knot (arrow). Left shoulder, anterior view. (B) The Clavicular Clip loop is slipped into the clavicular drill hole hiding the knot (arrow). The 5-mm Clavicular Clip loop and the knot compress the graft limbs against the 6-mm drill-hole walls. Therefore, there is no need for an interference screw. Left shoulder, anterior view.

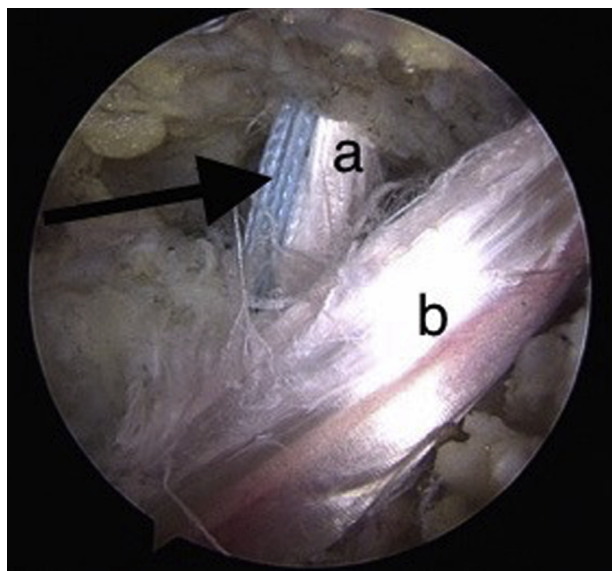


Fig 7. The arthroscopic photograph showing the complete double-bundle reconstruction. The anterior graft limb (a), dorsal graft limb (b), and interconnecting suture (arrow).

Using the conventional drill guide technique, a 4.5-mm drill hole is made through the clavicle and coracoid (Fig 2A). The clavicular drill hole is centrally located on the clavicle, approximately 2.5 cm proximal to the AC joint. The coracoid drill hole is located centrally and as proximally as possible. The clavicular drill hole is then widened to 6 mm (Fig 2B). The passing sutures are passed through the drill holes using the Blunt Lasso Guide (CC-Clip) (Fig 3A). The tendon graft is pulled first through the clavicular and coracoid drill holes (Fig 3B). The distal limb end is then pulled to the clavicular portal behind the clavicle. Thereafter, the interconnecting sutures are passed through the drill holes and pulled out through the anterolateral portal. The Subcoracoid Clip is attached to the No. 5 suture loop and then pulled back into its position underneath the coracoid (Fig 4). The end of the dorsal graft limb is taken over the dorsal edge of the clavicle, slipped through the Clavicular Clip, and then pulled through the clavicular drill hole beside the anterior graft limb using the Blunt Lasso Guide (Fig 5A). With the entire reconstruction in place, the clavicle is repositioned (Fig 5B). The repositioning is checked arthroscopically under visual control. The interconnecting suture and tendon graft are tensioned, and the sutures are tied using a knot pusher (Fig 6A). Once the sutures are tied, the Clavicular Clip loop is allowed to sink into the clavicular drill hole hiding the suture knot (Fig 6B). Finally, the anterior graft limb end is fixed onto the dorsal limb behind the clavicle with No. 2 non-resorbable sutures (Fig 7, Video 1).

In chronic cases, once the CC ligament reconstruction is completed, the clavicular wound may be extended

laterally to expose the AC joint. If the AC joint capsule is addressed, it is done openly making the operation arthroscopy-assisted. The AC joint may be debrided and the clavicular end may be resected if necessary. Thereafter, the AC joint capsule can be sutured and plicated with interrupted sutures to enhance the anterior-posterior stability of the distal clavicle (Figs 8 and 9).

Postoperative Treatment

A padded dressing is applied with a sling. The patients are discharged from the hospital on the same day and each wears a sling for 4 weeks. They are allowed light rotatory movements and passive lifting of the arm within the limits of pain. The sling is removed after 4 weeks, and active rehabilitation is initiated 8 weeks after surgery. The patients are allowed to resume heavy labor and sports at postoperative 3 and 4-6 months, respectively.

Discussion

The strong interconnecting suture applied between the CC Clip and Subcoracoid Clip is considered semitemporary; the authors believe that it will eventually snap. Therefore, a tendon graft is necessary for the reconstruction, especially in chronic cases.

The Clavicular Clip was particularly designed for the 2-tunnel solution and to address the problems related to earlier techniques. The Clavicular Clip has a simple design; it worked as expected and was easy to handle. The Subcoracoid Clip was equally practical and the amount of wire or suture needed was minimal due to the straight direction of the suture material between the implants. The loop attachment of the Subcoracoid Clip is strong with minimal movement in the loop knot, thus, reducing friction. The first 2 months postoperatively

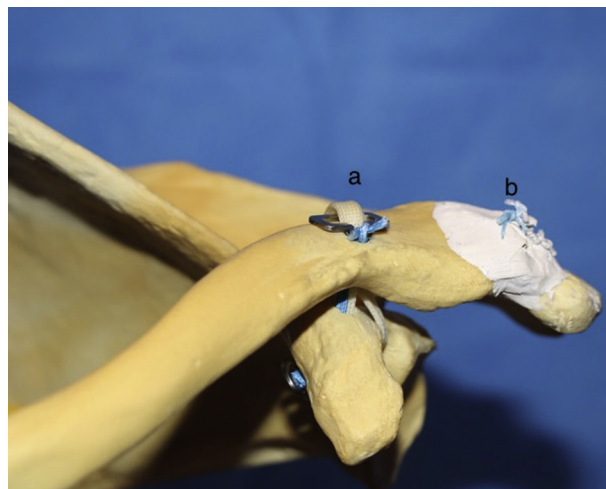


Fig 8. The complete coracoclavicular reconstruction (a). Note the optional plication of the acromioclavicular joint capsule (b). Left shoulder, anterior view.

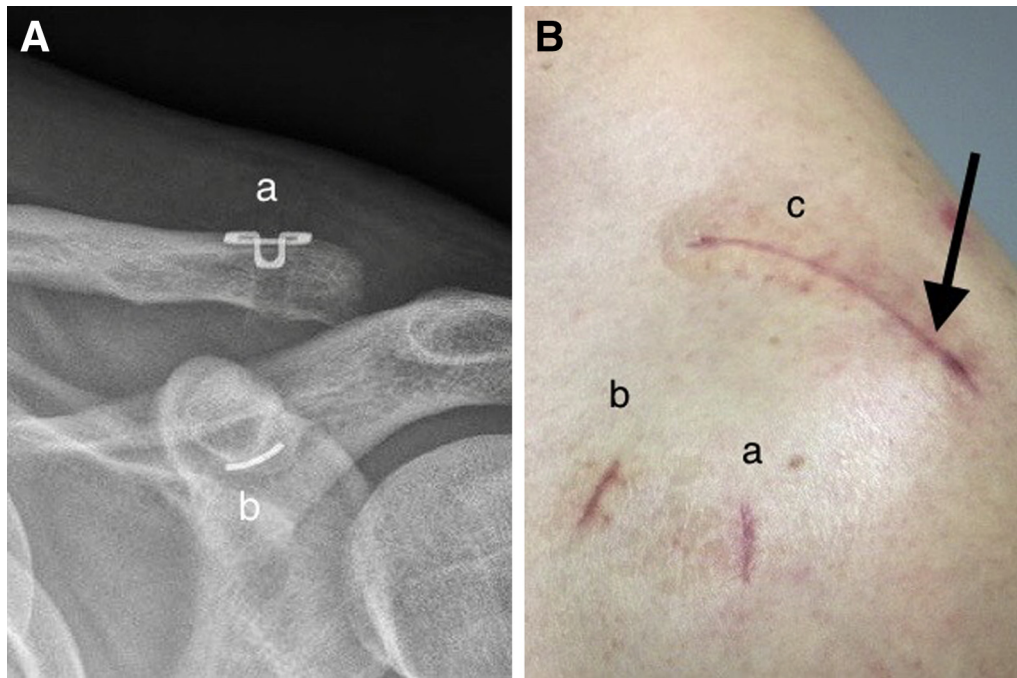


Fig 9. (A) The postoperative radiograph of a reduced clavicle. The superior part of the Clavicular Clip (16 mm) lies flush on the clavicular surface (a). The Subcoracoid Clip is in its position underneath the coracoid process (b). Left shoulder. (B) The skin wounds after 2 weeks from surgery. The lateral portal (a), anterolateral portal (b), and clavicular skin wound (c). Note that the clavicular opening is extended laterally to address also the acromioclavicular joint capsule (arrow). The initial dorsal portal is not visible in this projection. Left shoulder, anterolateral view.

Table 1. Tips and Tricks

	Pearls	Pitfalls	Risks
Portals	It is essential to have the portals in the right places—always use needles	A displaced portal—a notable problem	Mishandling the arthroscopic procedure
Posterior portal P	The surgery is initiated through the standard posterior portal	Check additional trauma: labrum, supraspinatus tendon	Missing the whole picture
Lateral portal L	Place a needle in front of the biceps tendon and place the L portal there	Make sure the needle reaches the proximal coracoid	Missing the whole picture
Anterolateral portal AL	L+AL portals: good access to the proximal coracoid		Missing the whole picture
Clavicular portal C	Clavicular portal behind the clavicle. Direct the needle to the coracoid neck	Make sure the needle reaches the proximal coracoid	Missing the whole picture
Clavicular portal C	Create a soft-tissue channel underneath the clavicle to the coracoid neck bluntly, with scissors	Otherwise it is difficult to get the suture passer into the right position	
Operative technique	Meticulous hemostasis using electrocautery throughout the surgery	Bleeding may hamper vision	Mishandling the arthroscopic procedure
Passing the graft	Always pull the graft before the supportive suture	The sutures and graft may tangle	The graft gets stuck
Passing the graft	Pull the passing suture of the graft first to the clavicular portal and then pull the graft	The graft does not usually slide well in the suture passer eyelet	The graft gets stuck
Passing the graft	When pulling the graft through the drill holes assist with a suture passer placed underneath the coracoid	To avoid the dead man angle	The graft gets stuck
Passing the graft	All of the graft must be in its place before snapping the coracoid clip into the clavicular drill hole	The clip fits tightly, and it is difficult to pass anything through it once it is in place	Problems, repeating it is time consuming
Tensioning the graft and the supportive device	Before the sutures are tied the assistant presses the clavicular head down	It helps to tension the interconnecting suture sufficiently	The interconnecting suture remains too loose
Knot tying	Use the knot pusher. It fits into the clip loop	It is easier to make the knots sufficiently tight enough	The interconnecting suture knots remain too loose

are critical. The tendon graft must heal properly before physiotherapy is initiated. Subsequently, it is very unlikely for the reconstruction to fail excluding new external trauma. The technique is simple enough for any experienced shoulder surgeon to perform. However, the technique does include its pitfalls (Table 1).

References

1. Pühringer N, Agneskirchner J. Arthroscopic technique for stabilization of chronic acromioclavicular joint instability with coracoclavicular and acromioclavicular ligament reconstruction using gracilis tendon graft. *Arthrosc Tech* 2017;6:e175-e181.
2. Banca C, Prashant P. Surgical technique for arthroscopy-assisted anatomical reconstruction of acromioclavicular and coracoclavicular ligaments using autologous hamstring graft in chronic acromioclavicular joint dislocations. *Arthrosc Tech* 2017;6:e641-e648.
3. Natera L, Reiriz J, Abat F. Anatomic reconstruction of chronic coracoclavicular ligament tears: Arthroscopic-assisted approach with nonrigid mechanical fixation and graft augmentation. *Arthrosc Tech* 2014;3:e538-e588.
4. Millett PJ, Warth RJ, Greenspoon JA, Horan MP. Arthroscopically assisted anatomic coracoclavicular ligament reconstruction technique using coracoclavicular fixation and soft-tissue grafts. *Arthrosc Tech* 2015;4:e583-e587.
5. Martetshläger F, Tauber M, Habermeyer P, Hawi N. Arthroscopically assisted acromioclavicular and coracoclavicular ligament reconstruction for chronic acromioclavicular joint instability. *Arthrosc Tech* 2016;5:e1239-e1246.
6. Pan Z, Zhang H, Sun C, Qu L, Cui Y. Arthroscopy-assisted reconstruction of coracoclavicular ligament by Endobutton fixation for treatment of acromioclavicular joint dislocation. *Arch Orthop Trauma Surg* 2015;135:9-16.
7. Ranne J, Sarimo J, Rawlins M, Heinonen O, Orava S. All-arthroscopic double-bundle coracoclavicular ligament reconstruction using autogenous semitendinosus graft: A new technique. *Arthrosc Tech* 2012;1:e11-e14.
8. Woodmass J, Esposito J, Ono Y, et al. Complications following arthroscopic fixation of acromioclavicular separations: A systematic review of the literature. *Open Access J Sports Med* 2015;6:97-107.