



Contents lists available at ScienceDirect

Journal of Cranio-Maxillo-Facial Surgery

journal homepage: www.jcmfs.com

The use of patient-specific implants in orthognathic surgery: A series of 30 mandible sagittal split osteotomy patients



Juho Suojanen ^{a, *}, Junnu Leikola ^b, Patricia Stoor ^a

^a Departments of Oral and Maxillo-Facial Diseases (Head: Risto Kontio, MD, DDS, PhD), University of Helsinki and Helsinki University Hospital, Haartmaninkatu 4E, 00029 HUS, Helsinki, Finland

^b Cleft Lip and Palate and Craniofacial Centre (Head: Hannu Kuokkanen, MD, PhD), Helsinki University Hospital, Sibeliuksenkatu 10, 00029 HUS, Finland

ARTICLE INFO

Article history:

Paper received 29 September 2016

Accepted 17 February 2017

Available online 3 March 2017

Keywords:

Sagittal split osteotomy

BSSO

Sagittal ramus osteotomy

Orthognathic surgery

Patient specific implants

CAD/CAM

ABSTRACT

Purpose: Virtual surgery combined with patient-specific saw and drill guides and osteosynthesis materials are rapidly spreading from reconstructive surgery to orthognathic surgery. Most commercial partners are already providing computer-aided design and computer-aided manufacture (CAD/CAM) wafers and patient-specific saw guides. Clear benefits have been demonstrated for custom-made drill guides combined with individually designed three-dimensional (3D) printed patient-specific implants (PSI) as a reposition and fixation system in Le Fort I osteotomy.

Materials and methods: We treated 30 patients who underwent bilateral sagittal split osteotomy (BSSO) due to class II dento-skeletal deformities with the additional use of drill guides combined with PSI as a fixation and positioning system.

Results: The PSIs fitted bilaterally with total precision in 11 of the 30 patients. In 17 patients, the PSIs were used with some modifications. In 2 of 30 patients, the PSIs could not be used as a fixation due to misfit.

Conclusion: Due to unpredictable fitting, the use of PSIs with drill guides alone in BSSO without wafers cannot be recommended. Further studies are needed to evaluate the interfering parts, which seem to be related to condylar positioning and bony interferences at the osteotomy sites.

© 2017 European Association for Cranio-Maxillo-Facial Surgery. Published by Elsevier Ltd. All rights reserved.

1. Introduction

The use of computer aided design and computer-aided manufacturing (CAD/CAM) is becoming an increasingly more common treatment option when surgery is planned. Patient-specific implants (PSI) are used in cranio-maxillo-facial surgery, especially in reconstructive surgery. Reconstruction of complex three-dimensional (3D) structures clearly benefits from this technique (Stoor et al., 2014). Conventional surgical materials such as titanium or poly(methyl methacrylate (PMMA) as well as several newer composites have been successfully used in reconstruction of the cranium and the facial skeleton (Piitulainen et al., 2014; Stoor et al., 2014; Ridwan-Pramana et al., 2015). We have previously reported the use of a wafer-free technique for Le

Fort I osteotomy with repositioning and fixation by CAD-CAM saw and drill guides combined with PSI (Suojanen et al., 2016). The benefits of 3D surgical planning and individually designed implants are clear when dealing with facial deformity cases.

CAD/CAM-generated wafers have earlier been proved to be accurate for orthognathic surgery (Schouman et al., 2015; Kraeima et al., 2016). Most commercial partners are providing surgical models and 3D design with virtual planning for orthognathic and reconstructive surgery. The pre-bent osteosynthesis materials provided through 3D planning, however, usually differ very little from the conventional mini-plates used before the CAD/CAM era. PSIs are ideal solutions to maximize the potentials of 3D design as well as precise repositioning and fixation of the maxilla in Le Fort I osteotomy (Suojanen et al., 2016). In this study, we report the use of CAD/CAM osteotomy and drill guides combined with individually milled implants for reposition and fixation in mandibular sagittal split osteotomy (BSSO).

* Corresponding author. Helsinki University Central Hospital, Oral and Maxillo-facial Surgery, P.O. Box 220, 00029 HUS, Finland.

E-mail address: juho.suojanen@helsinki.fi (J. Suojanen).

2. Materials and methods

The study data derive from a retrospective cohort of mandible osteotomy patients. A total of 30 patients with dento-skeletal class II malocclusion were treated with bilateral sagittal split osteotomy for mandibular advancement with the additional use of drill guides combined with PSI as a fixation and positioning system. The patients were underwent operation at the Helsinki University Hospital from December 2013 to December 2015.

For 3D planning, preoperative computed tomography (CT) scans and dental casts were taken of each patient. During CT scanning, the condylar head was positioned into the glenoid fossa with a wax bite index made by the orthodontist. The wax bite index was made manually by the orthodontist by manipulating the condyle gently into the glenoid fossa and pressing the teeth together at the same time with the wax index placed between the upper and lower teeth. No touch-free electronic recorder was used. Osteotomies, PSIs and guides were virtually designed with the engineer, chief surgeon and orthodontist using the Planmeca ProModel™ system (Planmeca Ltd, Helsinki, Finland).

The osteotomies were virtually designed according to Epker (1977) to cut straight through the mandibular bodies at the caudal part of the inferior mandibular border. The location of the inferior alveolar nerve was identified in association with the osteotomy line in the 3D virtual model. The virtual sagittal osteotomy was generated as a plane connecting the proximal and distal osteotomies.

The osteotomy and drill guides, as well as the PSI, were manufactured for each patient by Planmeca Ltd, Helsinki, Finland (Fig. 1). Dentition-based CAD/CAM wafers were preordered to ensure perioperative occlusal stability in each case. The wafers and drill guides are made of plastic that is approved for medical use. The PSIs

were milled from titanium alloy blocks. The PSIs and the osteotomy and drill guides were heat sterilized. The wafers were cold disinfected in alcohol prior to use.

Intraoperatively, the osteotomy and drill guides were fitted into the right position on the lateral surface of the mandible using the occlusal surface of the first and second molars as reference points (Fig. 1). The inferior bone cut was made into the caudal inferior border of the mandible. The PSI was fixed primarily to predesigned drill holes. The bone segments were kept in close contact, however, avoiding compression at the inferior alveolar nerve. The bony segments were finally contoured with a burr to avoid compression and to eliminate visible interfering bony parts at the osteotomy line.

During osteosynthesis, the occlusion was stabilized and maintained with an interocclusal wafer, and maxillo-mandibular fixation was performed with tight elastics. The osteotomy was carried out as planned, and the implants were fixed with 6–8 mm/1.85-mm monocortical screws (DePuy Synthes, Oberdorf, Switzerland). Ideally the PSI, which is designed to perfectly fit the anatomical contours of the repositioned mandible (Fig. 2) fits only in one position when correctly placed on the repositioned mandible with the predrilled screw holes. Condylar lateral rotation up to a maximum of 4° in the X- Y- and Z-axes was allowed and predesigned in the PSIs. If overlapping of the condylar and dental segments still occurred after a 4-degree rotation in the virtual treatment plan, or if the angle and body of the mandible appeared asymmetric due to flaring, a lingual osteotomy of the dental segment was designed vertically posterior to the second molars. The osteotomy was performed with a Piezo device (Synthes). The cut lingual segments were left, without further stabilization, attached to the periosteum. The CAD/CAM wafer was used to ensure the stability of the determined occlusion when performing the osteosynthesis.

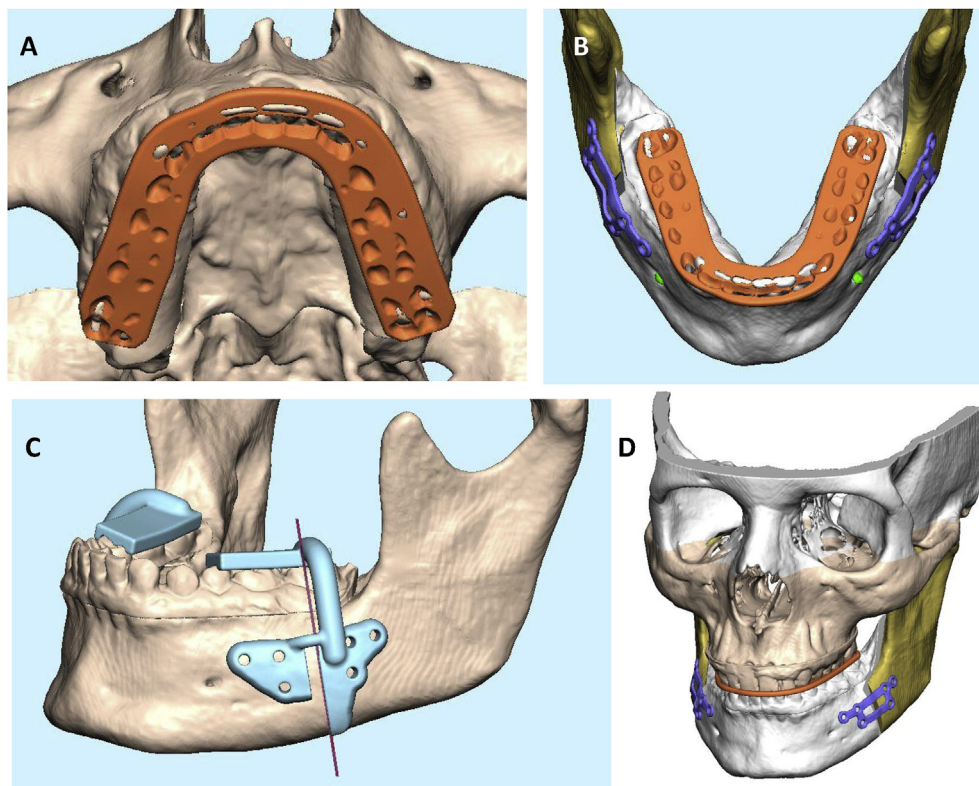


Fig. 1. Virtual planning of the osteotomy and design of wafer, drill guides and patient-specific implants (PSI). Fitting of the wafer and desired contact points can be evaluated independently on the maxilla (A) and mandible (B). Note that PSI is designed following the bone contours of the repositioned mandible (B). The drill and osteotomy guide (C) is designed for precise and safe osteotomy and screw positioning to avoid root or nerve damage. The guide obtains its support for positioning from the occlusal surfaces of molars and premolars. The plate positioning and desired mandible advancement is evaluated from the three-dimensional skull model (D).

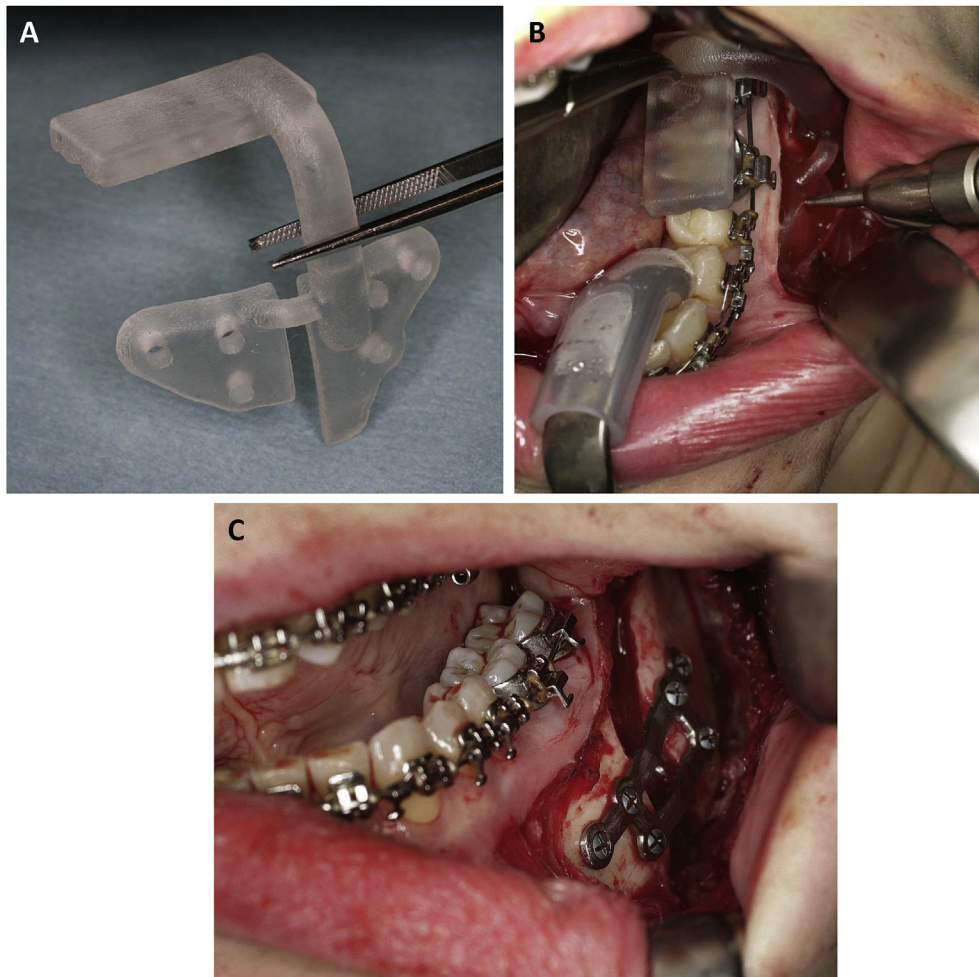


Fig. 2. Use of osteotomy and drill guide for repositioning the mandible with patient-specific implants (PSI). Plastic drill and osteotomy guide (A) obtains its support from dental occlusal surfaces and pre-designed drill holes, and osteotomy line is pre-designed by virtual surgery to avoid roots and lower alveolar nerve channel. Guide is used for marking drill holes and osteotomy line prior to splitting (B). PSI follows bony contours of the mandible, and screws fit pre-designed places (C).

3. Results

The fitting of the implants in individual patients and patient demographics can be seen in detail in [Table 1](#). The PSIs fitted on both sides with total precision in 11 of the 30 patients. In 17 patients, the PSIs could be used with some modifications to the plate contour or screw positioning. In 7 of these 17 patients, one or more pre-designed drill holes could not be used for the final osteosynthesis, or the PSI needed significant modification before it could be used. Of these seven poor-fitting plates, five resulted perioperatively in a too-retrognathic bite, and the distance between the proximal and distal segments needed to be increased. In 2 of 30 patients, the PSI could not be used. In these cases, the PSI appeared not to fit onto the lateral surfaces of the proximal and distal segments after repositioning of the condylar head into the glenoid fossa.

4. Discussion

The use of 3D design and CAD/CAM wafers combined with prebent plates is already a common protocol in orthognathic surgery. Rapid prototyping and the use of 3D-printed or milled PSIs have been a success in reconstructive and trauma surgery ([Stoor et al., 2014](#); [Suomalainen et al., 2015](#); [Zimmerer et al., 2016](#); [Stoor et al., 2017](#)). Also in orthognathic surgery, the benefits of

contouring and 3D locking properties of the CAD/CAM PSI are clear ([Gander et al., 2015](#); [Mazzoni et al., 2015](#); [Suojanen et al., 2016](#)). In BSSO, perioperative handling of the proximal segment predictably, especially in patients with temporomandibular joint disorders, is known to be challenging. Prebent plates and a virtual treatment plan can be of help only to some extent ([Lee et al., 2015](#)). However, a pre-designed osteotomy together with a CAD/CAM PSI could be an ideal solution for accurately obtaining the movements of the jaws as planned virtually three-dimensionally. This would be especially important in cases with significant asymmetry or transversal problems and in patients with TMJ problems with regard to obtaining the right condylar position perioperatively.

Interestingly, in BSSO, the fitting of the PSI in the repositioned mandible was considerably poorer as compared to earlier results described in a study on the use of PSI in Le Fort I osteotomies ([Suojanen et al., 2016](#)). Thin bone structures and areas with low opacity can cause error in design ([Huotilainen et al., 2014](#)), but in general the method can be considered reliable ([Kraeima et al., 2016](#)). Clinical applications using CAD/CAM PSI can give excellent results ([Stoor et al., 2014, 2017](#); [Suojanen et al., 2016](#); [Stoor et al., 2017](#)). However, in this study, our results are not as convincing, since only one-third of PSIs fitted bilaterally with total precision.

The most probable reasons for the misfit of the PSIs are related to the placement of the condylar segment and unidentified bony interferences at the osteotomy site. The repositioning of the condyles

Table 1
Characteristics of the patients.

| Patient | Sex | Age | Diagnosis 1 | Diagnosis 2 | PSI fitting | Jaw movement |
|---------|-----|-----|--------------------|--------------------|----------------------|--------------|
| 1 | F | 43 | Deep bite | Retrognathia mnd. | Acceptable | CW |
| 2 | F | 30 | Retrognathia mnd. | Anterio open bite | Acceptable | CCW |
| 3 | F | 33 | Retrognathia mnd. | Large over jet | Excellent | CW |
| 4 | M | 51 | Retrognathia mnd. | Deep bite | Acceptable | CW |
| 5 | M | 26 | Apertognathia | Retrognathia mnd. | Acceptable | CCW |
| 6 | M | 42 | Deep bite | Retrognathia mnd. | Excellent | CW |
| 7 | M | 27 | Retrognathia mnd. | | Poor | CW |
| 8 | M | 40 | Deep bite | Retrognathia mnd. | Excellent | CW |
| 9 | F | 41 | Deep bite | Retrognathia mnd. | Poor | CW |
| 10 | F | 42 | Deep bite | Large over jet | Excellent | CW |
| 11 | F | 25 | Anterior open bite | Retrognathia mnd. | Excellent | CCW |
| 12 | F | 37 | Deep bite | Retrognathia mnd. | Poor | CW |
| 13 | F | 42 | Retrognathia mnd. | | Excellent | CW |
| 14 | F | 36 | Retrognathia mnd. | Deep bite | Excellent | CW |
| 15 | M | 37 | Retrognathia mnd. | Anterior open bite | Acceptable | CCW |
| 16 | F | 26 | Retrognathia mnd. | | Acceptable/excellent | CW |
| 17 | F | 53 | Deep bite | Retrognathia mnd. | Excellent | CW |
| 18 | F | 46 | Retrognathia mnd. | Deep bite | Excellent/acceptable | CW |
| 19 | M | 46 | Deep bite | Large over jet | Excellent | CW |
| 20 | F | 47 | Deep bite | Retrognathia mnd. | Excellent | CW |
| 21 | F | 38 | Retrognathia mnd. | Deep bite | Excellent | CW |
| 22 | F | 29 | Retrognathia mnd. | Deep bite | Poor | CW |
| 23 | M | 25 | Retrognathia mnd. | Deep bite | Acceptable | CW |
| 24 | M | 37 | Deep bite | Retrognathia mnd. | Not usable | CW |
| 25 | M | 54 | Deep bite | Retrognathia mnd. | Excellent/acceptable | CW |
| 26 | F | 45 | Retrognathia mnd. | Large over jet | Poor | CW |
| 27 | M | 53 | Deep bite | Tooth attrition | Not usable | CW |
| 28 | F | 32 | Retrognathia mnd. | Deep bite | Poor | CW |
| 29 | F | 32 | Retrognathia mnd. | Deep bite | Acceptable | CW |
| 30 | F | 46 | Retrognathia mnd. | Large over jet | Poor | CW |
| | F | 46 | Retrognathia mnd. | Large over jet | Poor | CW |

Series of 30 patients with bilateral mandible ramus sagittal split osteotomy including main diagnoses. The most clinically relevant diagnosis is placed first. All the patients were having mandible advancements. Plate fitting was considered excellent if all predesigned holes were usable and plate passively sat on top of the bone fragments; acceptable if there was only minor discrepancy between the plate and bone fragments; and poor if one or more of the predesigned holes was not usable or major plate bending was needed. If only one fitting parameter is mentioned, both plates fitted equally. In the jaw movement section, the patients with performed distal segment lingual cut are noted in boldface type. CCW, counterclockwise rotation; CW, clockwise rotation; F, female; M, male; Mnd., mandible.

in to the glenoid fossa both preoperatively during the CT scan as well as during surgery is not fully predictable. Despite that the preoperative CT was taken with a bite registration index, which positions the condyles into the glenoid fossa, small movements are still possible, which potentially leads to a mismatch between the virtual treatment plan and the real-life condyle position. If the PSI-based positioning of the segments failed, the proper seating of the condylar segment was performed by a senior surgeon to obtain the position where the condylar head was positioned into the glenoid fossa. However, the exact rotation of the condyle according to the 3D surgical plan may be demanding to perform perioperatively, since there is no clear available method to measure the rotation of the condyle during surgery. Even a minor excess rotation of the condylar segment may provoke unexpected changes to TMJ biomechanics, which may further lead to a mismatch of the PSI and predrilled holes. Minor errors in the pivot point determination may thus lead to significant changes in the distal part of the condylar segment.

In the virtual treatment plan, the connecting sagittal osteotomy between the proximal horizontal and distal vertical osteotomies are designed in a straight plane. However, the sagittal ramus osteotomy of the mandible consists of a rather long fracture line with possible interfering surfaces that varies in reality as compared to the situation in virtual surgery. Furthermore, the osteotomy cut at the inferior mandibular border is shown to be less predictable as though leading to unfavourable bony interferences at the osteotomy site (Houppermans et al., 2016). We performed the inferior border cut only to the caudal cortex of the inferior mandibular border. According to the literature, it might be beneficial to extend the osteotomy to the lingual cortex. However, there is no clear evidence that this will make the lingual fracture line more

predictable (Houppermans et al., 2016). Despite performing additional fine tuning of the lingual part of the dental segment, which was performed in some of the patients, there might have been unidentified postero-caudal bony interferences interfering with the final positioning of the condylar segments (Ellis, 2007).

The rationale for producing wafers is dual. Beside the stabilizing function of the occlusion during the immediate postoperative period, it also provides safety in cases of poor fitting of the PSIs or malpositioning of virtually designed drill holes. The wafer can thus be used for positioning of the jaw in conventional osteosynthesis as well. According to a previous study on CAD/CAM-based PSIs, it was found that the maxilla could be repositioned and fixated predictably without wafers (Suojanen et al., 2016). In this study, however, we found that osteosynthesis could not be safely performed in all cases without wafers.

The reasons for poorer fitting of the PSI in BSSO as compared to that in Le Fort I osteotomy must be sought in the cumulative errors in preoperative design and unpredictable condylar segment behaviour after osteotomy rather than from the CAD/CAM process itself. As the mandible consists of high-density bone errors in the STL conversion must be considered more unlike in the maxilla as compared to the maxilla (Huotilainen et al., 2014; Suojanen et al., 2016). According to a recent study on PSIs designed for reconstruction of the mandible in continuity resections, with a defined caudal border, promising results without problems related to misfit of the PSIs was shown (Stoor et al., 2017). On the other hand, the three-dimensional bone contours of the maxilla are beneficial for exact implant positioning (Suojanen et al., 2016). With regard to implant positioning in BSSO, the mandible with a flat lateral surface provides a more demanding area.

Additionally, one possible error may be generated by the heat sterilization of the osteotomy and drill guides, since the material becomes soft during the process. It is possible that the exact shape of the guides might have been distorted in some cases during the process due to forces from the rough handling or pressure generated by the sterilization packages. There might thus have been an unfavourable effect on the exact fitting of the guides being hardly noticeable during surgery and leading to a minor mismatch in the final position of the screw holes of the PSIs compared to the pre-drilled screw holes.

5. Conclusion

The clinical benefits from using osteotomy and drill guides in combination to PSIs in BSSO are considerably more limited as compared to the use of PSIs in Le Fort I osteotomy (Suojanen et al., 2016). Due to unpredictable fitting, the use of PSIs with osteotomy and drill guides alone in BSSO without wafers cannot be recommended. Further studies are needed to evaluate the interfering parts, which seem to be related to condylar positioning and bony interferences at the osteotomy sites.

Conflict of interest

All authors have participated in congresses at which attendance fees were in part or in total supported by DePuy-Synthes or KLS-Martin. Juho Suojanen is working on a research project for which part of the costs is sponsored by Amgen Ltd. The only financial support for the present work comes from Emil Aaltonen Foundation, Tampere, Finland and Helsinki University Hospital Funds.

Notification

Written informed consent was obtained from the patient presented in the manuscript figures.

Acknowledgements

This work is supported by Emil Aaltonen Foundation and Helsinki University Hospital Funds (Y1014SUL07).

References

- Ellis III E: A method to passively align the sagittal ramus osteotomy segments. *J Oral Maxillofac Surg* 65: 2125–2130, 2007
- Epker B: Modifications in the sagittal osteotomy of the mandible. *J Oral Surg* 35: 157–159, 1977
- Gander T, Bredell M, Eliades T, Rucker M, Essig H: Splintless orthognathic surgery: a novel technique using patient-specific implants (PSI). *J Cranio Maxillo Fac Surg* 43: 319–322, 2015
- Houppermans PN, Verweij JP, Mensink G, Gooris PJ, van Merkesteyn JP: Influence of inferior border cut on lingual fracture pattern during bilateral sagittal split osteotomy with splitter and separators: a prospective observational study. *J Craniomaxillofac Surg* 44(10): 1592–1598, 2016
- Huotilainen E, Jaanimets R, Valásek J, Marcián P, Salmi M, Tuomi J, et al. *J Craniomaxillofac Surg* 42(5): e259–e265, 2014
- Kraeima J, Jansma J, Schepers RF: Splintless surgery: does patient-specific CAD-CAM osteosynthesis improve accuracy of the Le Fort I osteotomy? *Br J Oral Maxillofac Surg*. <http://dx.doi.org/10.1016/j.bjoms.2016.07.007>, 2016
- Lee Y-C, Sohm H-b, Kim S-K, Bae O-Y, Lee J-H: A novel method for the management of proximal segment using computer assisted simulation surgery: correct condyle head positioning and better proximal segment placement. *Maxillofac Plast Reconstr Surg* 37(21): 1–8, 2015
- Mazzoni S, Bianchi A, Schiariti G, Badiali G, Marchetti C: Computer-aided design and computer-aided manufacturing cutting guides and customized titanium plates are useful in upper maxilla waferless repositioning. *J Oral Maxillofac Surg* 73: 701–707, 2015
- Piitulainen JM, Posti JP, Aitasalo KM, Vuorinen V, Vallittu PK, Serlo W: Craniofacial bone reconstruction with bioactive fiber-reinforced composite implant. *Head Neck* 36(5): 722–728, 2014
- Ridwan-Pramana A, Marcián P, Borak L, Narra N, Forouzanfar T, Wolff J: Structural and mechanical implications of PMMA implant shape and interface geometry in cranioplasty—a finite element study. *J Craniomaxillofac Surg* 44(1): 34–44, 2015
- Schouman T, Rouch P, Imholz B, Fasel J, Courvoisier D, Scolozzi P: Accuracy evaluation of CAD/CAM generated splints in orthognathic surgery: a cadaveric study. *Head Face Med*. <http://dx.doi.org/10.1186/s13005-015-0082-9>, 2015
- Stoor P, Suomalainen A, Lindqvist C, Mesimäki K, Danielsson D, Westermark A, et al: Rapid prototyped patient specific implants for reconstruction of orbital wall defects. *J Craniomaxillofac Surg* 42(8): 1644–1649, 2014
- Stoor P, Suomalainen A, Mesimäki K, Kontio R: Rapid prototyped patient specific guiding implants in critical mandibular reconstruction. *J Craniomaxillofac Surg* 45(1): 63–70, 2017
- Suojanen J, Leikola J, Stoor P: The use of patient-specific implants in orthognathic surgery: a series of 32 maxillary osteotomy patients. *J Craniomaxillofac Surg* 44(12): 1913–1916, 2016
- Suomalainen A, Stoor P, Mesimäki K, Kontio RK: Rapid prototyping modelling in oral and maxillofacial surgery. A two year retrospective study. *J Clin Exp Dent* 7(5): e605–e612, 2015
- Zimmerer RM, Ellis III E, Aniceto GS, Schramm A, Wagner MEH, Grant MP, et al: A prospective multicenter study to compare the precision of posttraumatic internal orbital reconstruction with standard performed and individualized orbital implants. *J Craniomaxillofac Surg* 44: 1485–1497, 2016