



Original Article

Cardiopulmonary effects of vatinoxan in sevoflurane-anaesthetised sheep receiving dexmedetomidine

M. Adam^{a,b,*}, V. Huuskonen^{a,c}, M.R. Raekallio^a, D. Casoni^d, A.K. Mykkänen^a,
A.K. Lappalainen^a, M. Kajula^e, I.J. Kallio-Kujala^a, O.M. Vainio^a

^a Department of Equine and Small Animal Medicine, Faculty of Veterinary Medicine, University of Helsinki, 00014 Helsinki, Finland

^b Pharmacology Department, Faculty of Veterinary Medicine, Beni-Suef University, 62511 Beni-Suef, Egypt

^c University College Dublin, School of Veterinary Medicine, Belfield, Dublin 4, Ireland

^d Department for BioMedical Research, Faculty of Medicine, University of Bern, Murtenstrasse 35, 3008 Bern, Switzerland

^e Admescope, Typpitie 1, 90620 Oulu, Finland

ARTICLE INFO

Article history:

Accepted 16 July 2018

Keywords:

Anaesthesia
Computed tomography
Dexmedetomidine
Sheep
Vatinoxan

ABSTRACT

The effects of pre-treatment with vatinoxan (MK-467) on dexmedetomidine-induced cardiopulmonary alterations were investigated in sheep. In a crossover study design with a 20-day washout, seven sheep were anaesthetised with sevoflurane in oxygen and air. The sheep were ventilated with the pressure-limited volume-controlled mode and a positive end-expiratory pressure of 5 cmH₂O. Peak inspiratory pressure (PIP) was set at 25 cmH₂O. The sheep received either 150 µg/kg vatinoxan HCl (VAT + DEX) or saline intravenously (IV) 10 min before IV dexmedetomidine HCl (3 µg/kg, DEX). Cardiopulmonary variables were measured before treatments (baseline), 3 min after vatinoxan or saline, and 5, 15 and 25 min after dexmedetomidine. Computed tomography (CT) of lung parenchyma was performed at baseline, 2 min before dexmedetomidine, and 10, 20 and 30 min after DEX. Bronchoalveolar lavage (BAL) was performed after the last CT scan and shortly before sheep recovered from anaesthesia. After VAT, cardiac output significantly increased from baseline. DEX alone significantly decreased partial arterial oxygen tension, total dynamic compliance and tidal volume, whereas PIP was significantly increased. With VAT + DEX, these changes were minimal. No significant changes were detected in haemodynamics from baseline after DEX. With VAT + DEX, mean arterial pressure and systemic vascular resistance were significantly decreased from baseline, although hypotension was not detected. On CT, lung density was significantly increased with DEX as compared to baseline. No visual abnormalities were detected in bronchoscopy and no differences were detected in the BAL fluid after either treatment. The pre-administration of vatinoxan alleviates dexmedetomidine-induced bronchoconstriction, oedema and hypoxaemia in sevoflurane-anaesthetised sheep.

© 2018 The Author(s). Published by Elsevier Ltd. This is an open access article under the CC BY license (<http://creativecommons.org/licenses/by/4.0/>).

Introduction

In veterinary clinical practice, α_2 -adrenoceptor agonists are used as sedatives, anxiolytics and analgesics, and to reduce general anaesthetic requirements. However, in all species, their use is associated with a number of side effects, most notably bradycardia, vasoconstriction and a reduction in cardiac output. These negative side effects are mainly mediated via peripherally located α_2 -adrenoceptors (Bryant et al., 1998).

In small ruminants, particularly sheep, α_2 -agonists are known for the induction of arterial hypoxaemia. The intensity of hypoxaemia depends on a number of factors, such as the dose of the agonist, route of administration, age of the animal and inter-individual variation. However, the hypoxaemic effect of α_2 -agonists in sheep is primarily mediated via the peripheral α_2 -adrenoceptors (Celly et al., 1997). The exact underlying mechanism(s) remain debated among researchers, although several theories have been proposed. Xylazine caused the contraction of isolated sheep tracheal strips (Papazoglou et al., 1995) and increased airway pressure in halothane-anaesthetised sheep (Nolan et al., 1986; Papazoglou et al., 1994). The authors hypothesised that the increased airway pressure was either due to decreased dynamic compliance or increased airway resistance (Nolan et al., 1986; Papazoglou et al., 1994). In addition, pulmonary

* Corresponding author at: Department of Equine and Small Animal Medicine, Faculty of Veterinary Medicine, Koetilantie 2, P.O. Box 57, 00014 University of Helsinki, Helsinki, Finland.

E-mail address: magdy.adam@helsinki.fi (M. Adam).

oedema formation as a result of platelet aggregation and pulmonary microembolism (Eisenach, 1988), pulmonary venomotor spasm (Bacon et al., 1998), the release of inflammatory mediators due to the activation of intravascular pulmonary macrophages (Celly et al., 1999a) and increased hydrostatic pressure (Kästner et al., 2007) have also been suggested as the cause of hypoxaemia.

In sevoflurane-anaesthetised sheep, dexmedetomidine induced marked vasoconstriction, with increases in systemic and pulmonary arterial blood pressure, pulmonary occlusion pressure and capillary wedge pressure (Kästner et al., 2005, 2007; Kutter et al., 2006). Furthermore, decreased dynamic compliance, increased airway resistance and an increased pulmonary shunt fraction and dead space ratio were also reported (Kästner et al., 2005, 2007; Kutter et al., 2006).

Vatinoxan (previously named MK-467 and L-659,066) is a peripheral α_2 -adrenoceptor antagonist that poorly penetrates the mammalian central nervous system due to its low lipophilicity (Clineschmidt et al., 1988). Vatinoxan has demonstrated an ability to alleviate the adverse cardiopulmonary effects associated with dexmedetomidine in various species, whilst preserving the desired, centrally mediated actions (Raekallio et al., 2010; Honkavaara et al., 2008, 2011, 2017). The aim of the present study was to investigate the ability of vatinoxan to alleviate the adverse cardiopulmonary alterations induced by dexmedetomidine in sevoflurane-anaesthetised sheep. Our hypothesis was that pre-treatment with vatinoxan would prevent the increase in airway resistance and pulmonary oedema formation, and consequently reduce the degree of induced hypoxaemia following dexmedetomidine administration.

Materials and methods

Animals

A prospective, randomised, cross-over design was used with a minimum washout period of 20 days between treatments. Seven Texel and Crossbred sheep, 1–3 years of age, with previously exteriorised right carotid arteries and a mean \pm standard deviation (SD) body weight of 55 ± 4 kg were used in this study. The animals were deemed healthy based on physical examination, haematology and blood chemistry results. Food was withheld for 24 h prior to each phase of anaesthesia. The study was approved by the national Animal Experiment Board of Finland (license number ESAVI/9394/04.10.07/2015; date of approval 12th January 2016).

Induction and maintenance of anaesthesia

Following the placement of an 18 G cephalic catheter (Terumo), anaesthesia was induced with propofol (Vetofol 10 mg/mL; Norbrook Laboratories) until effect. After endotracheal intubation with a silicone endotracheal tube (9–11 mm internal diameter, MILA International), anaesthesia was maintained at 3.0% end-tidal sevoflurane (SevoFlo; Abbott Laboratories) in 50% oxygen and air (0.5 fraction of inspired oxygen (FiO_2)). The sheep were positioned in sternal recumbency and intermittent positive pressure ventilation (IPPV) was started immediately following intubation with the pressure-regulated volume-controlled (PRVC) mode (Perseus A 500, Dräger); the positive end-expiratory pressure (PEEP) was set at 5 cmH₂O and maintained at a constant level throughout the anaesthesia. Peak inspiratory

pressure (PIP) was set initially at 25 cmH₂O and, if required due to a decrease in pulmonary compliance, increased to 30 cmH₂O to achieve a tidal volume (V_T) of 12 mL/kg and an end-tidal carbon dioxide concentration (ETCO₂) of 40 mmHg. At the beginning of anaesthesia, an inspiratory-expiratory ratio (I:E) of 1:2 and respiratory rate (f_R) of 11–13 breaths per min were set, but they were adapted as necessary during the anaesthetic to maintain normocapnia. Parameters monitored and recorded every 5 min were rectal temperature, haemoglobin oxygen saturation (SpO_2), pulse rate (Nonin PalmSAT 2500 series), f_R , FiO_2 , ETCO₂, end-tidal sevoflurane, V_T , minute volume (M_V), total dynamic compliance (C_{dyn} mL/cmH₂O) and PIP. Airway gas concentrations were measured from the proximal end of the endotracheal tube.

Instrumentation

The animals were instrumented with a right carotid arterial catheter (20 G; B. Braun Melsungen AG), a right jugular catheter (16 G; MILA International) and a pulmonary artery catheter (7 Fr, 110 cm, triple-lumen Swan-Ganz monitoring catheter; Edwards Lifesciences) via the left jugular vein. The correct placement of the pulmonary artery catheter was confirmed by the shape of pressure waves and subsequently confirmed with CT. All catheters were secured in position with skin sutures. Following instrumentation, a stomach tube was passed into the rumen. Invasive arterial blood pressure (IBP), central venous pressure (CVP) and pulmonary arterial pressure (PAP) were measured (Datex Engstrom S/5 monitor, Datex Ohmeda) using pre-calibrated pressure transducers (Gabarith PMSET; Becton Dickinson). The height at the shoulder joint was used as the zero reference point for all blood pressure measurements. Cardiac output (CO) was measured using the lithium dilution method (LiDCO plus Haemodynamic Monitor; LiDCO). Anaerobic blood samples were obtained in pre-heparinised syringes (Pico50; Radiometer) for arterial and mixed venous blood gas analysis and were placed in iced water for immediate analysis (ABL 855; Radiometer). The blood gases were corrected for rectal temperature. Blood samples for the determination of plasma dexmedetomidine and vatinoxan concentrations were collected from the carotid artery catheter, centrifuged at 3000 g for 15 min, and frozen at -20°C until analysed.

Study protocol

Immediately after instrumentation, the animals were moved to the CT suite. After baseline cardiopulmonary measurements and a baseline thoracic CT scan, an intravenous (IV) bolus of either 150 $\mu\text{g}/\text{kg}$ vatinoxan hydrochloride (vatinoxan HCl; Vetcare), diluted in saline to achieve a concentration of 0.5%, or a similar volume of saline was injected (T-10; VAT+DEX; DEX). All cardiopulmonary measurements were repeated 3 min later (T-7), followed by a CT scan (T-2). After the second CT scan, 3 $\mu\text{g}/\text{kg}$ dexmedetomidine HCl (Dexdomitor 0.1 mg/mL, Orion Pharma) diluted in 20 mL saline was injected IV over 30 s 10 min after vatinoxan or saline (T0), and all cardiopulmonary measurements were repeated 5, 15 and 25 min after dexmedetomidine (T5, T15 and T25). The CT scan was repeated at 10, 20 and 30 min (T10, T20 and T30) after dexmedetomidine administration (Fig. 1).

The CT scan of the lungs (GE Lightspeed VCT 64, GE Healthcare) was performed at 140 kV, mA noise index 18.0 (min 120 mA/max 710 mA), slice thickness 0.625 mm, time/rotation 0.4 sec and pitch 0.984. A lung algorithm was used and all images were evaluated with a window level of -500 and window width of 1500. The CT scanner was calibrated daily according to the hospital's procedure. The cross-sectional areas of the right caudal pulmonary artery and vein were measured at the level of the proximal dorsocaudal branch of the vein according to Kästner et al. (2007). Two regions of interest (ROI) of 0.5 cm² were drawn on this same image: one positioned dorsally (ROI 1), close to the periphery of the lung parenchyma, and the other ventrolateral (ROI 2) to the main bronchus as shown in Fig. 3A, and the CT values of each ROI were calculated as Hounsfield units (HU). The measurements were conducted three times with an interval of at least 1 week by an investigator blinded to the treatments and time points, and the mean values were used.

Bronchoscopy and bronchoalveolar lavage (BAL) were performed via the endotracheal tube approximately 5 min after the last CT scan. Fifty millilitres of saline was infused through the work channel of the bronchoscope (Olympus

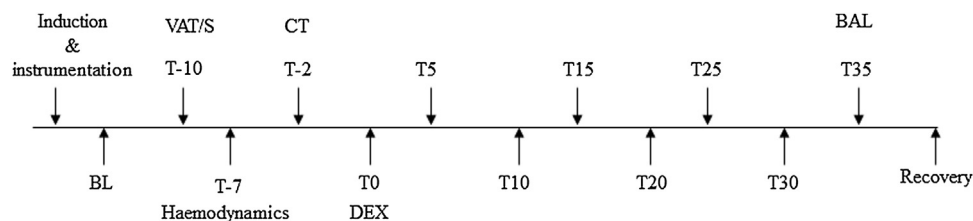


Fig. 1. Experimental timeline. BAL, bronchoalveolar lavage; BL, baseline measurements; CT, computed tomography; DEX, dexmedetomidine; S, saline; T-10, 10 min before dexmedetomidine administration; VAT, vatinoxan.

GIF-N180, Olympus Europa GmbH) into the right dorsal and right accessory lung lobes, and the fluid was immediately withdrawn and placed on ice. The BAL fluid was filtered through a gauze, after which the quantity of white blood cells was calculated and differential counts were made from cytocentrifuge smears stained with May-Grünwald Giemsa.

At the end of the study, anaesthesia was discontinued and the sheep received 0.5 mg/kg meloxicam (Metacam 20 mg/mL, Boehringer Ingelheim Vetmedica) IV and 0.03 mg/kg atipamezole HCl (Alzane 5 mg/mL, Syva Laboratoires SA) IM prior to the removal of the instrumentation and tracheal extubation. Supplemental oxygen at a rate of 10 L/min was provided by face mask until the sheep had fully recovered.

Dexmedetomidine and vatinoxan plasma concentrations were analysed as described previously (Adam et al., 2018); 50 µL of plasma were precipitated on a Sirocco plate with 250 µL of internal standard solution in acetonitrile (containing 100 ng/mL of propranolol and 20 ng/mL of chlorpromazine). After vigorous mixing for 5 min at 1350 revolutions per min, the samples were centrifuged for 20 min at 2952 g. Then, 50 µL were transferred to a UPLC 96-well plate, diluted with 450 µL of 20% acetonitrile and analysed. The standard samples were prepared in blank sheep plasma by spiking into concentrations of 0.02–20,000 ng/mL of the analytes, while the quality control samples were prepared by spiking the blank sheep plasma into concentrations of 0.2, 2, 20, 200 and 2000 ng/mL. Analyses were carried out with liquid chromatography-mass spectrometry (Waters Acquity UPLC, Waters TQ-S triple-quadrupole MS, Waters Corporation) using a C18 column (2.1 × 50 mm, 1.7 µm) with a guard filter (Waters Corporation). The quantification ranges (ng/mL), accuracy (%) and precision (%) for vatinoxan and dexmedetomidine were 2–2000, 96–105, 6.8–13 and 0.2–200, 92–102 and 4.1–9.7, respectively.

Statistical analysis

Statistical analysis was performed using IBM SPSS Statistics Version 24.0 for Windows. The assumption of normality was evaluated with the Shapiro–Wilk test. Cardiopulmonary variables were analysed using a generalised linear mixed model with time, treatment and their interactions as fixed effects, and animal, time-by-animal and treatment-by-animal as random effects. Sequential Bonferroni corrections were used to adjust for multiple comparisons where appropriate. The CT measurements were compared against their baselines and between treatments with the Wilcoxon Signed-Rank test. *P* values < 0.05 were considered to be significant.

Results

Cardiopulmonary variables are presented as the mean ± SD (Tables 1 and 2; Fig. 2A–D). There were no significant differences between treatments in heart rate (HR), mean pulmonary artery pressure (MPAP) or mean central venous pressure (MCVP). However, with VAT + DEX, the mean arterial pressure (MAP) and systemic vascular resistance (SVR) were significantly decreased at T15 and T25 compared to the baseline and to DEX. With DEX, the partial pressure of arterial oxygen (PaO₂), partial pressure of venous oxygen (PvO₂) and total dynamic compliance (C_{dyn}) were significantly decreased from the baseline at T5 and T15. At the

same time, PIP, partial pressures of arterial (PaCO₂) and venous (PvCO₂) CO₂, and ETCO₂ were significantly higher than the baseline after DEX. No significant changes from the baseline were observed in these variables after VAT + DEX.

No abnormal patterns were detected in the pulmonary parenchyma in baseline CT scans. No significant changes compared to the baseline were detected in the cross-sectional area of the caudal pulmonary vein throughout the observation period after either treatment. However, the caudal pulmonary vein area was significantly larger at T-2 and T10 with VAT + DEX compared to DEX. With VAT + DEX, the cross-sectional area of the caudal pulmonary artery was significantly smaller compared to baseline measurements at T30, and compared to DEX, it was smaller at T20 and T30. The CT values for ROI 1 remained within the baseline values after both treatments, whereas the values for ROI 2 were significantly increased with DEX at T20 and T30, and significantly decreased with VAT + DEX at T30, compared to baseline measurements (Table 3; Fig. 3).

No excessive bronchial mucus or oedema was seen in the bronchi (Fig. 4), and no visual abnormalities were detected in the BAL fluid after either treatment. The amount and differential analysis of white blood cells in the BAL fluid did not significantly differ between the treatments.

The plasma concentrations of dexmedetomidine and vatinoxan are presented in Fig. 5A–B. There were no significant differences in dexmedetomidine concentrations between treatments.

Discussion

After DEX alone, PaO₂, V_T and C_{dyn} were significantly lower, whereas PIP, PaCO₂ and lung density were significantly increased, compared to baseline. Pre-treatment with vatinoxan prevented these negative changes.

In the present study, the role of the vascular component and pulmonary congestion appears to have been minimal in the development of the unwanted changes in airway dynamics. No changes were observed in systemic or pulmonary circulation after DEX, consistent with the earlier findings in sheep (Celly et al., 1999b; Talke et al., 2000). However, C_{dyn} decreased, and we suggest that the increased airway resistance, indicated by the reduced V_T and the increased pressure required to deliver the V_T, was a reflection of bronchoconstriction mediated by α₂-adrenoceptors. In sheep, xylazine at a dose of 200 µg/kg IV induced a significant

Table 1

Mean ± standard deviation (SD) of cardiopulmonary haemodynamics in seven sheep that were pre-treated with 150 µg/kg vatinoxan (VAT + DEX) or saline and 10 min later received 3 µg/kg dexmedetomidine (DEX).

	Treatment	Time (min)				
		BL	T-7	T5	T15	T25
HR (bpm)	DEX	84 ± 16	84 ± 16	74 ± 9	75 ± 11	76 ± 11
	VAT + DEX	82 ± 8	85 ± 6	76 ± 9	73 ± 8	73 ± 9
MAP (mmHg)	DEX	92 ± 17	95 ± 13	100 ± 8	97 ± 10 [†]	81 ± 6 [†]
	VAT + DEX	94 ± 10	90 ± 8	96 ± 4	75 ± 4 [†]	69 ± 5 [†]
MPAP (mmHg)	DEX	18 ± 3	18 ± 3	21 ± 4	20 ± 3	18 ± 5
	VAT + DEX	20 ± 2	19 ± 3	19 ± 2	20 ± 5	17 ± 2
MCVP (mmHg)	DEX	10 ± 3	9 ± 2	13 ± 2	11 ± 2	10 ± 3
	VAT + DEX	13 ± 4	11 ± 3	12 ± 4	11 ± 3	11 ± 3
CO (L/min)	DEX	2.87 ± 0.78	3.15 ± 0.72	2.82 ± 0.52	3.05 ± 0.31	3.37 ± 0.25
	VAT + DEX	2.77 ± 0.26	3.63 ± 0.69 [†]	3.25 ± 0.68	3.04 ± 0.41	3.15 ± 0.44
SVR (dynes/s/cm ⁵)	DEX	2328 ± 440	2279 ± 260 [†]	2547 ± 550	2256 ± 262 [†]	1676 ± 203 [*]
	VAT + DEX	2363 ± 442	1784 ± 306 [†]	2121 ± 396	1678 ± 180 [†]	1480 ± 119 [*]
SV (mL/kg)	DEX	34.1 ± 4.1	37.3 ± 4.3	37.3 ± 8.0	41.5 ± 8.1	45.2 ± 7.7
	VAT + DEX	34.2 ± 3.9	42.9 ± 9.9	43.1 ± 8.5	41.6 ± 3.7	43.2 ± 4.0

BL, baseline; bpm, beats per min; HR, heart rate; MAP, mean arterial pressure; MPAP, mean pulmonary arterial pressure; MCVP, mean central venous pressure; CO, cardiac output; SVR, systemic vascular resistance; SV, stroke volume.

[†] Significant difference between treatments.

^{*} Significantly different from BL (*P* < 0.05).

Table 2
Mean \pm standard deviation (SD) of blood gas analyses in seven sheep that were pre-treated with 150 $\mu\text{g}/\text{kg}$ vatinoxan (VAT + DEX) or saline and 10 min later received 3 $\mu\text{g}/\text{kg}$ dexmedetomidine (DEX).

Treatment		Time (min)				
		BL	T-7	T5	T15	T25
PaO ₂ (mmHg)	DEX	289 \pm 23	280 \pm 30	195 \pm 85 [*]	213 \pm 78 [*]	259 \pm 37
	VAT + DEX	280 \pm 36	288 \pm 23	289 \pm 23 [†]	289 \pm 19 [†]	291 \pm 16 [†]
PaCO ₂ (mmHg)	DEX	37 \pm 2	37 \pm 1	44 \pm 8 [*]	43 \pm 5 [*]	41 \pm 3
	VAT + DEX	36 \pm 3	37 \pm 1	37 \pm 2 [†]	38 \pm 2 [†]	37 \pm 1
pHa	DEX	7.53 \pm 0.03	7.54 \pm 0.02	7.48 \pm 0.08	7.50 \pm 0.05	7.51 \pm 0.03
	VAT + DEX	7.53 \pm 0.02	7.54 \pm 0.03	7.54 \pm 0.03	7.54 \pm 0.03	7.55 \pm 0.03
SpO ₂ (%)	DEX	99.9 \pm 0.4	99.7 \pm 0.5	98 \pm 3.3	99.6 \pm 0.5	99.6 \pm 0.5
	VAT + DEX	99.7 \pm 0.5	99.7 \pm 0.5	99.7 \pm 0.5	99.7 \pm 0.5	99.6 \pm 0.8
PvO ₂ (mmHg)	DEX	43 \pm 11	42 \pm 10	35 \pm 7 [*]	37 \pm 5 [*]	39 \pm 5
	VAT + DEX	41 \pm 7	48 \pm 9	41 \pm 7 [†]	42 \pm 7 [†]	42 \pm 7
PvCO ₂ (mmHg)	DEX	45 \pm 4	45 \pm 2	48 \pm 5	50 \pm 4 [*]	50 \pm 3 [*]
	VAT + DEX	43 \pm 5	43 \pm 2	44 \pm 2	45 \pm 5 [†]	45 \pm 2 [†]
Hb (g/dL)	DEX	7.7 \pm 0.8	7.4 \pm 0.8	7.5 \pm 0.8	7.6 \pm 0.8	7.5 \pm 0.8
	VAT + DEX	7.9 \pm 0.7	7.8 \pm 0.9	7.6 \pm 0.8	7.5 \pm 0.8	7.3 \pm 0.8

BL, baseline; PaO₂, partial oxygen pressure in arterial blood; PaCO₂, partial carbon dioxide pressure in arterial blood; pHa, arterial pH; SpO₂, haemoglobin oxygen saturation; PvO₂, partial oxygen pressure in mixed venous blood; PvCO₂, partial carbon dioxide pressure in mixed venous blood; Hb, haemoglobin.

[†] Significant difference between treatments.

^{*} Significantly different from BL ($P < 0.05$).

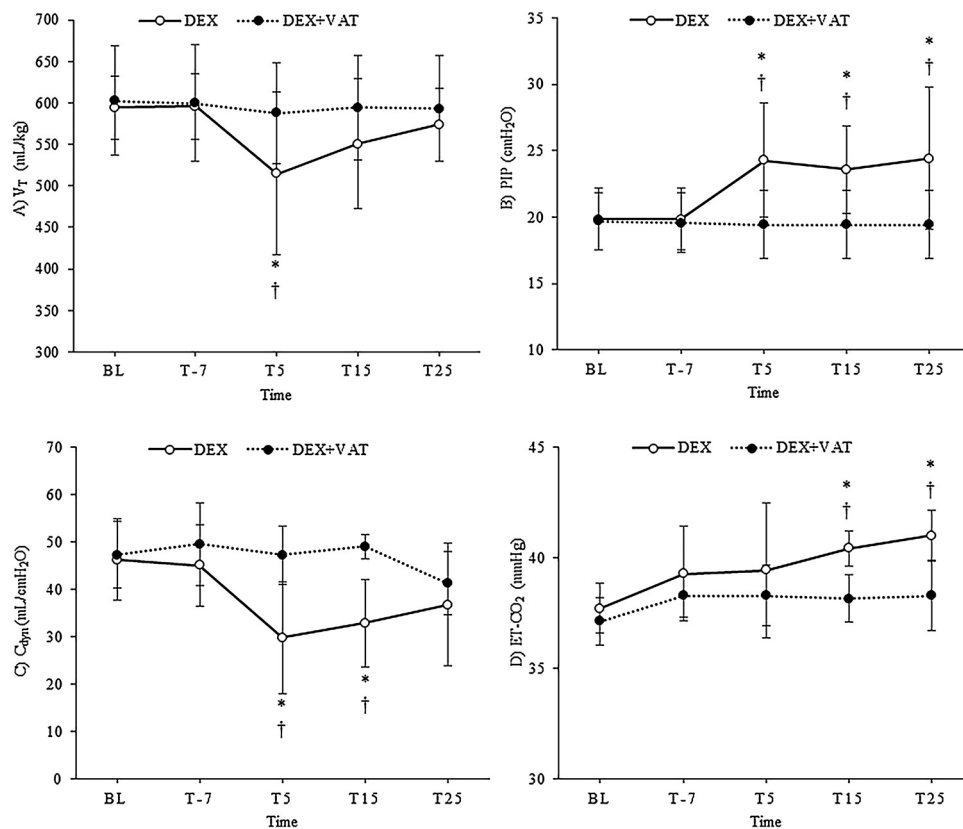


Fig. 2. Mean \pm standard deviation (SD) of (A) tidal volume (V_T), (B) peak inspiratory pressure (PIP), (C) total dynamic compliance (C_{dyn}) and (D) end-tidal carbon dioxide ($ET\text{-CO}_2$) in sheep that were pre-treated with 150 $\mu\text{g}/\text{kg}$ vatinoxan (VAT + DEX) or saline and 10 min later received 3 $\mu\text{g}/\text{kg}$ dexmedetomidine (DEX). [†] Significant difference between treatments. ^{*} Significantly different from baseline (BL; $P < 0.05$).

rise in airway pressure, which was abolished by the administration of α_2 -adrenoceptor antagonists idazoxan (Nolan et al., 1986) and atipamezole (Papazoglou et al., 1994), but did not respond to α_1 -adrenoceptor antagonism with prazosin (Nolan et al., 1986). Furthermore, xylazine caused a concentration-dependent contraction of isolated sheep tracheal strips, which was inhibited by atipamezole but not by atropine (Papazoglou et al., 1995).

In our study, an increased density of ROI 2 was observed in thoracic CT images after DEX, but not after VAT + DEX. However, our findings appeared to be less pronounced and they appeared more slowly than those reported by Kästner et al. (2007). The changes in vessel cross-sectional areas were also less than previously described, despite the fact that we used a slightly higher dose of dexmedetomidine (3 $\mu\text{g}/\text{kg}$ IV) than Kästner et al.

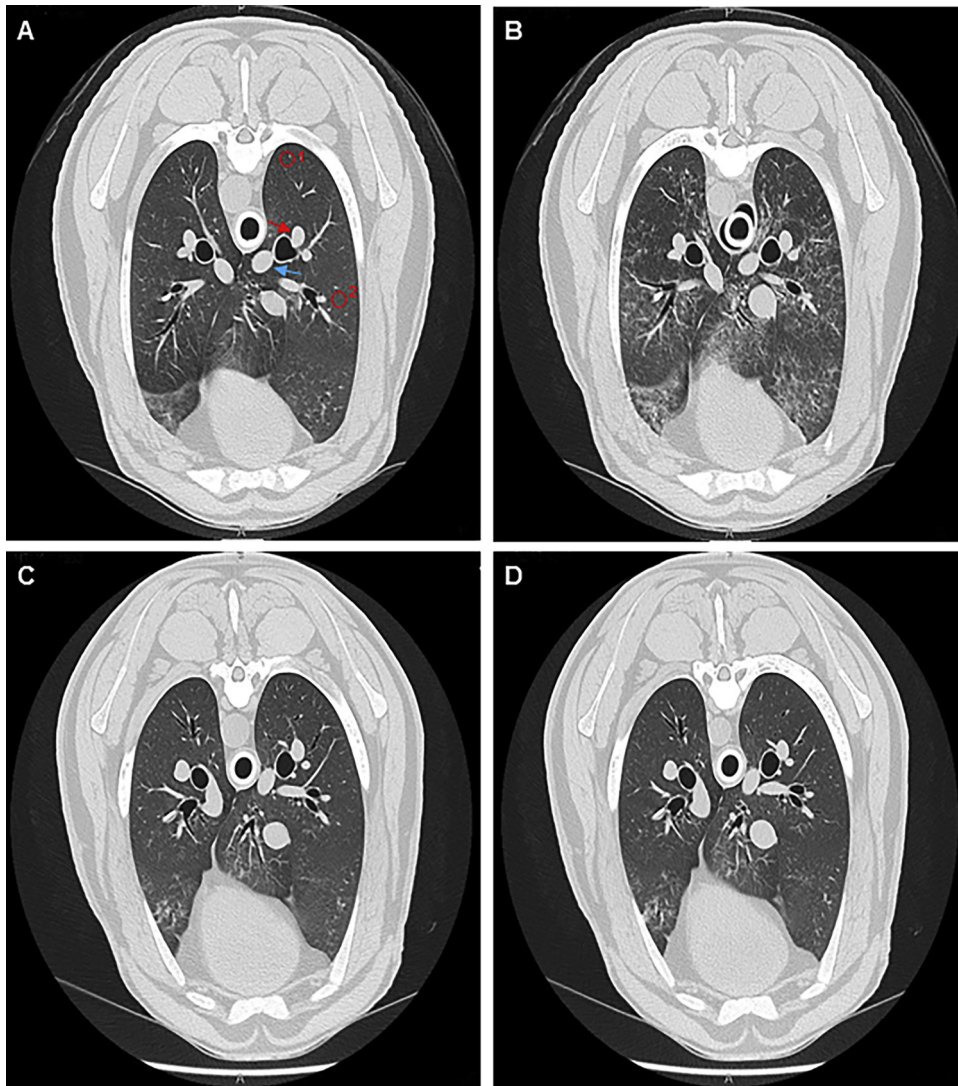

Fig. 3. Transverse computed tomography images at the level of the mid-caudal lung lobes in a sheep that was pre-treated with 150 $\mu\text{g}/\text{kg}$ vatinoxan (VAT + DEX) or saline and 10 min later received 3 $\mu\text{g}/\text{kg}$ dexmedetomidine (DEX): at baseline (BL) and at 20 min (T20) (A, B; DEX), and at 2 min before (T-2) and at 20 min after (T20) dexmedetomidine (C, D; VAT + DEX). Note that, in image (A), the arrows point to the caudal pulmonary vein (blue) and artery (red), whereas the circles 1 and 2 indicate the regions of interest (ROI).

Table 3

Median (range) of computed tomography measurements cross-sectional area (cm^2) of the caudal pulmonary artery and vein, and computed tomography values for two regions on interest (ROI 1 and 2) in sevoflurane-anaesthetised sheep that were pre-treated with 150 $\mu\text{g}/\text{kg}$ vatinoxan (VAT + DEX) or saline and 10 min later received 3 $\mu\text{g}/\text{kg}$ dexmedetomidine (DEX).

	Treatment	Time (min)				
		BL	T-2	T10	T20	T30
Artery area (cm^2)	DEX	0.65 (0.57–0.95)	0.79 (0.61–1.00)	0.82 (0.61–1.10)	0.80 (0.76–1.03) [†]	0.78 (0.74–1.02) [†]
	VAT + DEX	0.77 (0.61–0.99)	0.81 (0.58–0.96)	0.73 (0.64–0.94)	0.68 (0.59–0.93)	0.69 (0.57–0.90) [†]
Vein area (cm^2)	DEX	0.89 (0.63–1.25)	1.09 (0.63–1.33) [†]	1.05 (0.62–1.42) [†]	1.03 (0.70–1.47)	1.09 (0.66–1.38)
	VAT + DEX	1.05 (0.67–1.46)	1.17 (0.67–1.58)	1.12 (0.65–1.56)	1.22 (0.67–1.68)	1.12 (0.69–1.44)
ROI 1 (HU)	DEX	–700 (–755 to –650)	–711 (–753 to –632)	–710 (–758 to –651)	–700 (–761 to –641)	–716 (–771 to –651)
	VAT + DEX	–716 (–761 to –646)	–697 (–728 to –660)	–707 (–755 to –666)	–711 (–759 to –684)	–723 (–771 to –685)
ROI 2 (HU)	DEX	–660 (–681 to –515)	–666 (–689 to –532)	–560 (–680 to –493)	–604 (–651 to –468) ^{†*}	–621 (–659 to –460) ^{†*}
	VAT + DEX	–617 (–698 to –527)	–609 (–700 to –506)	–638 (–708 to –543)	–641 (–712 to –533)	–640 (–716 to –543) [*]

BL, baseline; HU, Hounsfield units.

[†] Significant difference between treatments.

^{*} Significantly different from BL ($P < 0.05$).

(2007) (2 $\mu\text{g}/\text{kg}$ IV). Moreover, we did not detect any foamy fluid during the bronchoscopy. Conversely, in the study of Kästner et al. (2007), the post-mortem examination of sheep lungs with

pulmonary oedema revealed that the trachea was filled with foamy fluid. Thus, Kästner et al. (2007) observed more severe changes indicative of vascular congestion and pulmonary oedema

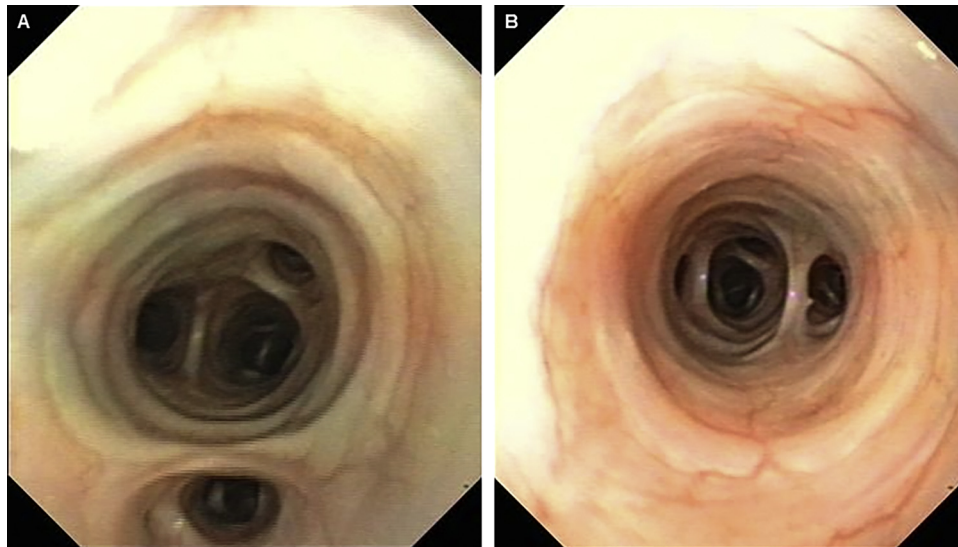


Fig. 4. Bronchoscopic views shortly before sheep recovered from anaesthesia. (A) 3 µg/kg dexmedetomidine at 10 min (DEX). (B) 150 µg/kg vatinoxan at baseline and 3 µg/kg dexmedetomidine at 10 min (VAT + DEX). No excessive mucus, foam or oedema were observed in bronchi.

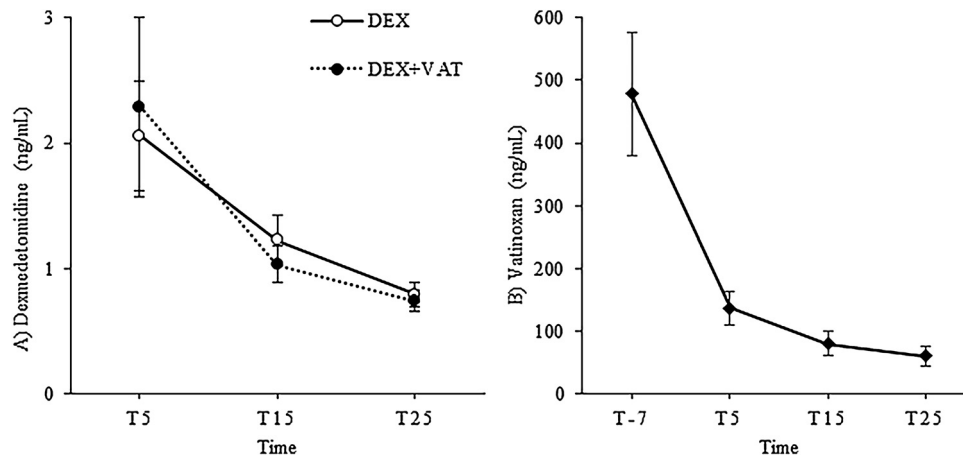


Fig. 5. Mean \pm standard deviation (SD) of (A) dexmedetomidine and (B) vatinoxan plasma concentrations in sheep that were pre-treated with 150 µg/kg vatinoxan (VAT + DEX) or saline and 10 min later received 3 µg/kg dexmedetomidine (DEX).

than we did. This inconsistency between the previous results and ours might be due to high individual variation, not only between sheep breeds, but also between individuals within the same breed.

In addition, we used PEEP during mechanical ventilation. In experimental canine and porcine models of induced pulmonary oedema, the use of moderate PEEP (10–20 cmH₂O) limited the increase in pulmonary extravascular fluid (Fernández-Mondéjar et al., 1996; Ruiz-Bailén et al., 1999), and significantly improved the gas exchange and decreased the shunt fraction as compared to zero end-expiratory pressure (Wickerts et al., 1992). Although the PEEP used in our study was only 5 mmH₂O, it might have prevented detectable vascular changes and limited the formation of pulmonary oedema. Conversely, since the CT changes were in the ventral part of lungs, this could partially explain the lack of changes in BAL, which was performed from the dorsal and accessory lung lobes. Additionally, the changes in CT could be due mainly to the formation of interstitial rather than alveolar oedema. Overall, in the present study, it seemed that the dexmedetomidine-induced significant reduction in PaO₂ was probably caused by the combination of bronchospasm and subsequent subclinical pulmonary oedema. Pre-treatment with vatinoxan prevented both unwanted effects.

In the present study, MAP and SVR were significantly lower after VAT + DEX compared to the baseline and to DEX, whereas no other systemic or pulmonary haemodynamic values differed significantly between treatments or from the baseline; however, it is important to note that the administration of VAT + DEX did not induce clinical hypotension. Our haemodynamic results more or less agree with the findings reported after IV administration of medetomidine in conscious (Talke et al., 2000) and halothane-anaesthetised sheep (Celly et al., 1999b). In contrast, other groups have reported a significant increase from baseline in MPAP, pulmonary artery occlusion pressure and capillary wedge pressure after dexmedetomidine (2 µg/kg IV) administration in sevoflurane-anaesthetised sheep (Kästner et al., 2005, 2007; Kutter et al., 2006). One could suggest that hypoxic pulmonary vasoconstriction played a role in the increased pulmonary vascular resistance observed in previous studies; however, it is unlikely, since this response is generally weak and variable in conscious sheep (Ahmed et al., 1982, 1983), and would be expected to be blunted in a dose-dependent manner in sevoflurane-anaesthetised sheep.

Individual variability in the response to α_2 -adrenoceptor agonists is common amongst sheep. Wide individual variation in the hypoxaemic response to medetomidine has been reported

within a single ovine breed (Tulamo et al., 1995). Moreover, Kästner et al. (2007) reported that, out of seven sevoflurane-anaesthetised and mechanically ventilated sheep that received IV dexmedetomidine, one showed minimal pulmonary vasoconstriction and only a transient and mild decrease in PaO₂ during the study, whereas the other six sheep responded to dexmedetomidine with hypoxaemia and a significant increase in pulmonary pressure. In the present study, we also noticed substantial individual variability, although none of our sheep became clinically hypoxaemic. Specifically, in two individuals (both of the Texel breed), PaO₂ was more than halved from baseline with DEX alone, whereas the other sheep (crossbred with Texel, Dorset and Gotland sheep) showed only minor responses to the same treatment. The administration of vatinoxan before dexmedetomidine prevented the decrease in arterial oxygen tension in all individuals.

Conclusions

The pre-administration of vatinoxan alleviated dexmedetomidine-induced bronchoconstriction and prevented the formation of subclinical pulmonary oedema, a decrease in pulmonary dynamic compliance and an increase in airway resistance in sevoflurane-anaesthetised sheep. The cardiovascular effects of dexmedetomidine were minimal and thus they did not appear to be responsible for the decrease in PaO₂ caused by dexmedetomidine.

Conflict of interest statement

Vetcare, Finland, funded the study. However, this company played no role in the study design or in the collection, analysis and interpretation of data, nor in the decision to submit the manuscript for publication. None of the authors of this paper has a financial or personal relationship with other people or organisations that could inappropriately influence or bias the content of the paper.

Acknowledgements

Preliminary results were presented as an abstract at the Autumn Meeting of the Association of Veterinary Anaesthetists, Berlin, Germany, 9th–11th November 2017. This study was financially supported by Vetcare, Finland. We would like to thank Merja Ranta for the analysis of BAL fluid.

References

- Adam, M., Raekallio, M.R., Keskitalo, T., Honkavaara, J.M., Kajula, M., Scheinin, M., Mölsä, S., Vainio, O.M., 2018. The impact of MK-467 on plasma drug concentrations, sedation and cardiopulmonary changes in sheep treated with intramuscular medetomidine and atipamezole for reversal. *Journal of Veterinary Pharmacology and Therapeutics* 41, 447–456.
- Ahmed, T., Oliver Jr., W., Frank, B.L., Robinson, M.J., Wanner, A., 1982. Hypoxic pulmonary vasoconstriction in sheep: role of mast-cell degranulation. *The American Review of Respiratory Disease* 126, 291–297.
- Ahmed, T., Oliver Jr., W., Wanner, A., 1983. Variability of hypoxic pulmonary vasoconstriction in sheep. Role of prostaglandins. *American Review of Respiratory Disease* 127, 59–62.
- Bacon, P.J., Jones, J.G., Taylor, P., Stewart, S., Wilson-Nunn, D., Kerr, M., 1998. Impairment of gas exchange due to alveolar oedema during xylazine sedation in sheep; absence of a free radical mediated inflammatory mechanism. *Research in Veterinary Science* 65, 71–75.
- Bryant, C.E., Thompson, J., Clarke, K.W., 1998. Characterisation of the cardiovascular pharmacology of medetomidine in the horse and sheep. *Research in Veterinary Science* 65, 149–154.
- Celly, C.S., McDonell, W.N., Black, W.D., Young, S.S., 1997. Cardiopulmonary effects of clonidine, diazepam and the peripheral α_2 adrenoceptor agonists ST-91 in conscious sheep. *Journal of Veterinary Pharmacology and Therapeutics* 20, 472–478.
- Celly, C.S., Atwal, O.S., McDonell, W.N., Black, W.D., 1999a. Histopathologic alterations induced in the lungs of sheep by use of alpha2-adrenergic receptor agonists. *American Journal of Veterinary Research* 60, 154–161.
- Celly, C.S., McDonell, W.N., Black, W.D., 1999b. Cardiopulmonary effects of the α_2 -adrenoceptor agonists medetomidine and ST-91 in anesthetized sheep. *Journal of Pharmacology and Experimental Therapeutics* 289, 712–720.
- Clineschmidt, B.V., Pettibone, D.J., Lotti, V.J., Hucker, H.B., Sweeney, B.M., Reiss, D.R., Lis, E.V., Huff, J.R., Vacca, J., 1988. A peripherally acting alpha-2 adrenoceptor antagonist – L-659,066. *Journal of Pharmacology and Experimental Therapeutics* 245, 32–40.
- Eisenach, J.C., 1988. Intravenous clonidine produces hypoxemia by a peripheral alpha-2 adrenergic mechanism. *Journal of Pharmacology and Experimental Therapeutics* 244, 247–252.
- Fernández-Mondéjar, E., Vazquez-Mata, G., Cárdenas, A., Mansilla, A., Cantalejo, F., Rivera, R., 1996. Ventilation with positive end-expiratory pressure reduces extravascular lung water and increases lymphatic flow in hydrostatic pulmonary edema. *Critical Care Medicine* 24, 1562–1567.
- Honkavaara, J.M., Raekallio, M.R., Kuusela, E.K., Vainio, O.M., 2008. The effects of L-659,066, a peripheral α_2 -adrenoceptor antagonist, on dexmedetomidine-induced sedation and bradycardia in dogs. *Veterinary Anaesthesia and Analgesia* 35, 409–413.
- Honkavaara, J.M., Restitutti, F., Raekallio, M.R., Kuusela, E.K., Vainio, O.M., 2011. The effects of increasing doses of MK-467, a peripheral alpha₂-adrenergic receptor antagonist, on the cardiopulmonary effects of intravenous dexmedetomidine in conscious dogs. *Journal of Veterinary Pharmacology and Therapeutics* 34, 332–337.
- Honkavaara, J., Pypendop, B.H., Ilkiw, J.E., 2017. The impact of MK-467 on sedation, heart rate and arterial blood pressure after intramuscular co-administration with dexmedetomidine in conscious cats. *Veterinary Anaesthesia and Analgesia* 44, 811–822.
- Kästner, S.B.R., Ohlerth, S., Pospischil, A., Boller, J., Huhtinen, M.K., 2007. Dexmedetomidine-induced pulmonary alterations in sheep. *Research in Veterinary Science* 83, 217–226.
- Kästner, S., Kull, S., Kutter, A., Boller, J., Bettschart-Wolfensberger, R., Huhtinen, M.K., 2005. Cardiopulmonary effects of dexmedetomidine in sevoflurane-anesthetized sheep with and without nitric oxide inhalation. *American Journal of Veterinary Research* 66, 1496–1502.
- Kutter, A.P.N., Kästner, S.B.R., Bettschart-Wolfensberger, R., Huhtinen, M., 2006. Cardiopulmonary effects of dexmedetomidine in goats and sheep anesthetized with sevoflurane. *Veterinary Record* 159, 624–629.
- Nolan, A., Livingston, A., Waterman, A., 1986. The effects of alpha2 adrenoceptor agonists on airway pressure in anesthetized sheep. *Journal of Veterinary Pharmacology and Therapeutics* 9, 157–163.
- Papazoglou, L., Raptopoulos, D., Kokolis, N., 1994. Increased airway pressure in response to xylazine is inhibited by both atipamezole and atropine in sheep. *Journal of Veterinary Medicine* 41, 568–572.
- Papazoglou, L., Raptopoulos, D., Kounenis, G., 1995. The effect of xylazine on the isolated sheep trachea. *Journal of Veterinary Pharmacology and Therapeutics* 18, 216–219.
- Raekallio, M.R., Honkavaara, J.M., Vainio, O.M., 2010. The effects of L-659,066, a peripheral α_2 -adrenoceptor antagonist, and verapamil on the cardiovascular influences of dexmedetomidine in conscious sheep. *Journal of Veterinary Pharmacology and Therapeutics* 33, 434–438.
- Ruiz-Bailén, M., Fernández-Mondéjar, E., Hurtado-Ruiz, B., Colmenero-Ruiz, M., Rivera-Fernández, R., Guerrero-López, F., Vázquez-Mata, G., 1999. Immediate application of positive-end expiratory pressure is more effective than delayed positive-end expiratory pressure to reduce extravascular lung water. *Critical Care Medicine* 27, 380–384.
- Talke, P.O., Traber, D.L., Richardson, C.A., Harper, D.D., Traber, L.D., 2000. The effect of α_2 agonist-induced sedation and its reversal with an α_2 antagonist on organ blood flow in sheep. *Anesthesia and Analgesia* 90, 1060–1066.
- Tulamo, R.M., Raekallio, M., Ekblad, A., 1995. Cardiovascular effects of medetomidine-ketamine anaesthesia in sheep, with and without 100% oxygen, and its reversal with atipamezole. *Journal of Veterinary Anaesthesia* 22, 9–14.
- Wickerts, C.J., Berg, B., Blomqvist, H., 1992. Influence of positive end-expiratory pressure on extravascular lung water during the formation of experimental hydrostatic pulmonary oedema. *Acta Anaesthesiologica Scandinavica* 36, 309–317.