

Tinea nigra palmaris: a clinical case in a rural Ethiopian hospital

Ramón Perez-Tanoira^{1,2,3}, Carlos Zarco Olivo^{1,4}, José Fortes Alen^{1,5},
Laura Prieto-Pérez^{1,2}, Alfonso Cabello^{1,2}, Jose Manuel Ramos Rincón⁶,
Juan Cuadros⁷, Miguel Górgolas^{1,2}

ABSTRACT

Tinea nigra is an infrequent, superficial fungal infection, mainly caused by *Hortaea werneckii*, which is still underreported in Ethiopia. An asymptomatic 62-year-old male patient sought a rural hospital of Ethiopia, showing dark plaques on the palms of both hands. A superficial mycosis was suspected and a direct light microscopic mycological examination from skin scrapings revealed short brownish hyphae. To our knowledge, this is the first case of tinea nigra from the Ethiopian highlands. This may be due to the actual rarity of the condition or to underreporting.

KEYWORDS: Tinea nigra. Ethiopia. *Hortaea werneckii*.

INTRODUCTION

Superficial mycoses are frequent causes of dermatological medical appointments in Ethiopia. These are fungal infections, limited to the stratum corneum and its adnexal structures affecting superficial layers of the skin, hair, and nails. The most frequent types are dermatophytoses or tineas. They are divided into actual superficial mycoses, superficial cutaneous mycoses, and superficial cutaneous-mucosal mycoses¹⁻³. In actual superficial mycoses, the host's cell-mediated immune response is minimal or absent. The presence of fungus is rarely symptomatic, which makes infection chronic. They comprise white piedra, black piedra, tinea nigra, and pityriasis versicolor. Diagnosis of these mycoses is made through mycological studies, direct examination, stains, and isolation, and identification of the fungi. Treatment includes systemic antifungals, topical antifungals, and keratolytics¹⁻³. However, topical treatment is normally effective, and systemic treatment is not systematically necessary in tinea nigra. Tinea nigra is an infrequent, superficial fungal infection which is generally asymptomatic. It occurs most commonly in female children in tropical and subtropical zones manifesting clinically as a single macula on the palms of the hands. It is produced mainly by the yeast-like fungus *Hortaea werneckii* (formerly *Exophiala werneckii*) but may also be due to *Stenella araguata*^{4,5}. Regarding its phenotypic appearance (macroscopic and microscopic morphologies) and appearance in tissue (histology), *Hortaea werneckii* is considered to be melanized.

Gambo General Hospital (GGH) is located in West Arsi province, 245 km Southeast of the capital city Addis Ababa, at an altitude of 2,250 m above sea level (7°18'22.4"N+38°48'54.7"E). The catchment area of GGH comprises

¹Gambo Rural General Hospital, Department of Medicine and Laboratory, Gambo, Ethiopia

²IIS-Fundación Jiménez Díaz, Division of Infectious Diseases, Madrid, Spain

³University of Helsinki, Helsinki University Hospital, Department of Otorhinolaryngology - Head and Neck Surgery, Helsinki, Finland

⁴Hospital 12 de Octubre, Department of Dermatology, Madrid, Spain

⁵Hospital Universitario Fundación Jiménez Díaz, Department of Anatomical Pathology, Madrid, Spain

⁶Universidad Miguel Hernández, Hospital General Universitario de Alicante, Department of Internal Medicine Alicante, Spain

⁷Hospital Príncipe de Asturias, Department of Clinical Microbiology, Alcalá de Henares, Spain

Correspondence to: Ramón Perez-Tanoira
IIS-Fundación Jiménez Díaz, Division of Infectious Diseases, Isaac Peral, 42, 28040, Madrid, Spain
Tel: +34 645 486 619

E-mail: ramontanoira@hotmail.com

Received: 4 June 2018

Accepted: 6 August 2018

approximately 100,000 inhabitants. Most of the population lives in a rural setting and works in agriculture and farming.

CASE REPORT

A 62-year-old male patient attended the Gambo Rural General Hospital (Ethiopia) in June 2015 with a two-year history of slowly enlarging, otherwise asymptomatic, superficial black spots on the palms of both hands, light brown with sharp borders, near the wrist of the right hand and a more intense black spot on the center of the palm of the left hand (Figure 1A). The patient also reported excessive hand sweating. There was no family history of a similar condition. The physician on call suspected of tinea nigra. A microbiologist performed 10% potassium hydroxide (KOH) examination of scrapings from the lesion, which revealed short septate dematiaceous hyphae (Figure 1B), later confirmed with Papanicolau staining performed by a pathologist with more experience in this type of infections. Sabouraud agar cultivation was performed, however it could not be examined because we had to leave the area before the fungus could grow and no specialist remained who could identify the fungus. Treatment with topical isoconazole twice a day for 20 days was effective, with complete resolution of the palmar lesions, and no relapses during a one-year follow-up.

DISCUSSION

Tinea nigra produces typical hyperpigmented macules resulting from the accumulation of a melanin-like substance in the fungus⁶. Typical macules are deeply pigmented and

non-scaly with well-defined borders. These macules may be single or a few may coalesce and may have rounded or irregular shapes. The palms are most often affected, although lesions may occur on plantar skin and the edges of the fingers⁷. No keratolysis is observable.

The adhesion to human hands can be explained by the hydrophobic character of the yeast cells. The natural habitats of *Hortaea werneckii* are hypersaline environments due to its halophilic behavior. The fungus is, however, naturally adapted to fluctuating salt concentrations and can grow without salt⁸.

The typical dermatoscopic findings of fine, homogenous spicules that do not follow the dermatoglyphs characterize the diagnosis of this dermatomycosis, and the mycological exam may not be performed. Routine mycological and mycopathological investigations can also help diagnosis. As these are mycoses, the gold standard for their diagnosis is the identification of fungal agents by means of direct mycological examination (DME), viewed under an optical microscope. In tinea nigra, DME reveals dematiaceous septate hyphae. However, not all dermatologists have access to laboratories in which mycological examinations can be performed. Therefore, knowing the most accessible propaedeutic and complementary methods to confirm the diagnosis is of great assistance¹.

It is important to differentiate this from other skin pathologies such as malignant melanoma, “athlete’s purpura”, post-inflammatory pigmentation, junctional melanocytic nevus or melanosis of syphilis, palmar lichen planus, injuries caused by arthropods of the Diplopoda Class, and pinta^{9,10}. If the condition is not recognized, unnecessary biopsies may result⁵. Dermoscopy is a fast

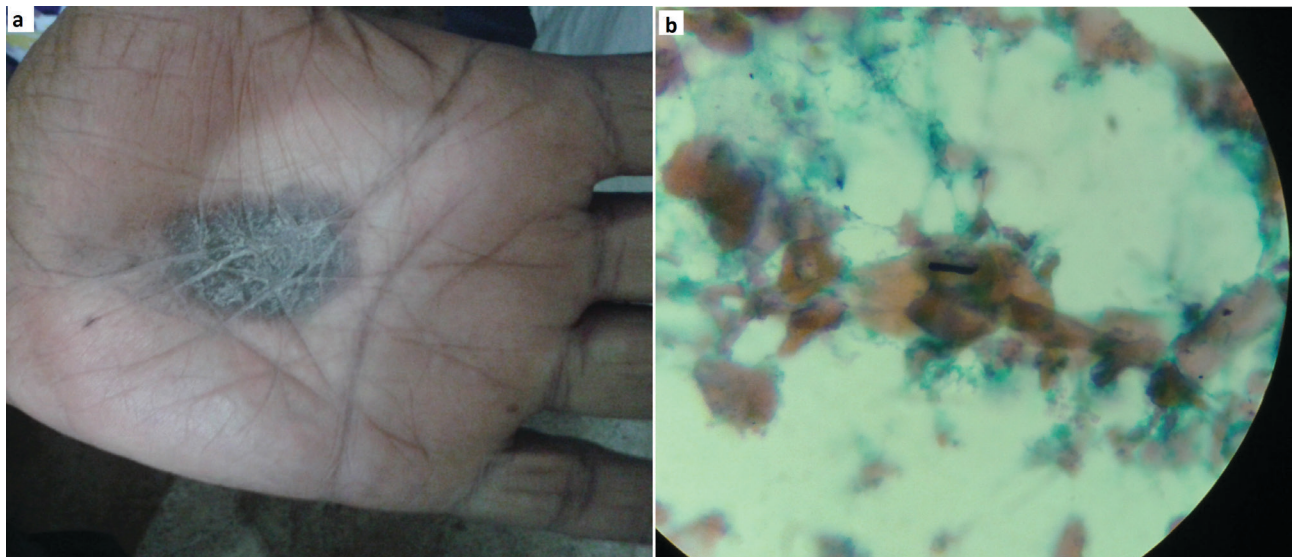


Figure 1 - A) Hyperpigmented macules on the palm; B) Magnification of dematiaceous (melanized) hyphae in scrapings from the lesion (Papanicolau staining)

and useful clinical tool in differentiating tinea nigra from melanocytic lesions⁸.

In some cases, lesions may be removed by strong friction when washing the hands, and they usually disappear. Macules may also be removed with a dermatological curette or scalpel blade, when scraping the scales for the mycological exam. Topical application of effective antifungal agents, such as imidazoles and also keratolytics usually clear the lesions within two to four weeks^{5,8}.

We conclude that this case, besides being a bilateral clinical form and affecting an uncommon age group, may be the first report of tinea nigra in the Ethiopian highlands. This might be due to the actual rarity of the condition or to underreporting. Superficial mycoses are dermatoses that commonly appear in tropical or subtropical areas around the world. Knowledge of their clinical aspects, mycological examinations, and complementary methods aid dermatologists in their routine practice.

CONFLICT OF INTERESTS

The authors declare that they have no competing interests.

ACKNOWLEDGMENTS

We want to thank Carolyn Brimley Norris, from University of Helsinki Language Services, for her support and tireless work. Dr. Francisco Reyes, who was the medical director of the Gambo Rural General Hospital when this clinical case was studied, for his warm welcome and providing the necessary infrastructure for our stay and work. Dr. Abraham Tesfamarian and Dr. Seble Balcha for their invaluable help. Also, we want to thank the staff of the Gambo Rural General Hospital. Thanks to the Master of Tropical Medicine and International Health at the Autonomous University of Madrid (Spain).

AUTHORS' CONTRIBUTIONS

RPT, CZO and JFA performed the diagnosis. RPT, LPP, AC, JMR and MG conducted the literature review and wrote the manuscript. RPT, CZO, JFA, LPP, AC, JC, JMR and MG read and approved the final manuscript. All authors read and approved the final manuscript.

REFERENCES

1. Veasey JV, Avila RB, Miguel BA, Muramatu LH. White piedra, black piedra, tinea versicolor, and tinea nigra: contribution to the diagnosis of superficial mycosis. *An Bras Dermatol*. 2017;92:413-6.
2. Schwartz RA. Superficial fungal infections. *Lancet*. 2004;364:1173-82.
3. Bonifaz A, Gómez-Daza F, Paredes V, Ponce RM. Tinea versicolor, tinea nigra, white piedra, and black piedra. *Clin Dermatol*. 2010;28:140-5.
4. Bonifaz A, Badali H, de Hoog GS, Cruz M, Araiza J, Cruz MA, et al. Tinea nigra by *Hortaea werneckii*, a report of 22 cases from Mexico. *Stud Mycol*. 2008;61:77-82.
5. Dias MF, Quaresma-Santos MV, Bernardes-Filho F, Amorim AG, Schechtman RC, Azulay DR. Update on therapy for superficial mycoses: review article part I. *An Bras Dermatol*. 2013;88:764-74.
6. Revankar SG, Sutton DA. Melanized fungi in human disease. *Clin Microbiol Rev*. 2010;23:884-928.
7. Maldonado I, Fernández Canigia L, Leitner R, Vitale RG. Tinea nigra palmaris: presentación de un caso clínico en la República Argentina. *Rev Argent Microbiol*. 2007;39:218-20.
8. Plemenitaš A, Lenassi M, Konte T, Kejžar A, Zajc J, Gostinčar C, et al. Adaptation to high salt concentrations in halotolerant/halophilic fungi: a molecular perspective. *Front Microbiol*. 2014;5:199.
9. Madke B, Doshi B, Wankhede P, Nayak C. Palmar lichen planus mimicking tinea nigra. *Indian J Dermatol*. 2013;58:407.
10. Rossetto AL, Cruz RC, Haddad Junior V. Double-blind study with topical Isoconazole and Terbinafine for the treatment of one patient with bilateral Tinea nigra plantaris and suggestions for new differential diagnosis. *Rev Inst Med Trop Sao Paulo*. 2013;55:125-8.