



# Targeted Treatment With Radio Frequency Ablation for Lingual Tonsil

Suvi Renkonen<sup>1,2</sup>, Antti A Mäkitie<sup>1,3</sup> and Leif Bäck<sup>1</sup>

<sup>1</sup>Department of Otorhinolaryngology – Head and Neck Surgery, University of Helsinki and Helsinki University Central Hospital, Helsinki, Finland. <sup>2</sup>Department of Biosciences and Nutrition, Karolinska Institutet, Stockholm, Sweden. <sup>3</sup>Division of Ear, Nose and Throat Diseases, Department of Clinical Science, Intervention and Technology, Karolinska Institutet and Karolinska University Hospital, Stockholm, Sweden.

Clinical Medicine Insights:

Ear, Nose and Throat

Volume 11: 1–4

© The Author(s) 2018

Reprints and permissions:

sagepub.co.uk/journalsPermissions.nav

DOI: 10.1177/1179550617749857



## ABSTRACT:

**OBJECTIVES:** Benign enlargement of the lingual tonsils due to various causes may cause symptoms that warrant treatment. Conventional lingual tonsillectomy remains a challenging procedure, and there is no established standard procedure. We aimed to review the patients receiving different methods of lingual tonsil surgery for various indications at our institute.

**METHODS:** Retrospective clinical data on all patients with an ablative operation of the tongue base during the 8-year period between 2007 and 2014 at the Helsinki University Hospital, Helsinki, Finland, were reviewed. The larger cohort comprised 35 patients, of whom 26 were men (74%). Ten patients had undergone solely lingual tonsil radio frequency ablation (LTRFA). The minimum follow-up time for all patients was 2 years.

**RESULTS:** Of the 10 patients, 5 patients with LTRFA had been operated on because of symptomatic lingual tonsil hypertrophy and 5 because of periodic fever associated with possible lingual tonsil involvement. In 2 of the 5 patients with periodic fever, the fever cycles ended after the operation. Of the 5 patients, 3 patients with symptomatic lingual tonsil hypertrophy have been non-symptomatic after 1 to 3 treatment sessions. The last 2 patients continue to have persistent symptoms. There were no major complications.

**CONCLUSIONS:** Development of new approaches for the management of various lingual tonsil conditions is warranted. Lingual tonsil volume reduction by LTRFA seems to be a treatment alternative with low morbidity but with limited curative effect only.

**KEYWORDS:** Hypertrophy, lingual tonsil, management, periodic fever, radio frequency ablation

**RECEIVED:** September 4, 2017. **ACCEPTED:** November 27, 2017.

**TYPE:** Original Research

**FUNDING:** The authors disclosed receipt of the following financial support for the research, authorship, and/or publication of this article: This study was supported by the Helsinki University Hospital Research Fund, Jane ja Aatos Erkko Foundation, and Korvatauti tutkimussäätiö.

**DECLARATION OF CONFLICTING INTERESTS:** The author(s) declared no potential conflicts of interest with respect to the research, authorship, and/or publication of this article.

**CORRESPONDING AUTHOR:** Suvi Renkonen, Department of Otorhinolaryngology – Head and Neck Surgery, University of Helsinki and Helsinki University Central Hospital, PO Box 220, Helsinki FI-00029 HUS, Finland. Email: suvi.renkonen@helsinki.fi

## Introduction

Together with the palatine tonsils, adenoids, tubal tonsils, and lateral pharyngeal bands, the lingual tonsils are a section of lymphoid tissue that makes up the Waldeyer ring.<sup>1,2</sup> Lingual tonsils are present at some stage during life in most individuals. They are thought to acquire greater functional activity in the fourth and fifth decades of life, differing from other lymphoid tissues in the Waldeyer ring.<sup>3</sup> In some patients, they become pathologically enlarged and consequently symptomatic. Several factors have been suggested to contribute to lingual tonsil hypertrophy (LTH), such as reactive lymphoid hyperplasia caused by tonsillectomy, laryngopharyngeal reflux, and obesity.<sup>2,4,5</sup> Lingual tonsil hypertrophy causes symptoms such as a globus sensation, dysphagia, and upper-airway obstruction, the latter being a significant cause of snoring and obstructive sleep apnoea-hypopnoea syndrome.<sup>3,6</sup> Other more infrequently described symptoms are sore throat, lethargy, change of speech, and choking on food.<sup>7</sup> To evaluate possible LTH, endoscopic examination, magnetic resonance imaging (MRI), and computed tomographic imaging have been used.<sup>2</sup> The grading systems used to assess the LTH have been inconsistent, making

the interpretation of different studies challenging. Friedman et al<sup>1</sup> have proposed a new standardized clinical grading system for LTH, for both causal studies and clinical decision making.

The most common reason for periodic fever in an otherwise healthy child is a syndrome called PFAPA, an acronym from the words periodic fever, aphthous stomatitis, pharyngitis, and cervical adenitis. The cause of this syndrome is unclear, and it presents with repeated periods of fever together with one or more of the other symptoms.<sup>8,9</sup> Antibiotics are not useful; however, corticosteroids can be administered. Tonsillectomy has been reported as an option in the treatment of these patients, although results have been controversial. Recently, PFAPA has been reported also in young adults, and several of the presented cases have had a tonsillectomy performed in their youth.<sup>8</sup> Thus, one hypothesis is that the initial benefit of removing the tonsils is linked with the removal of active lymphatic tissue, and later a compensatory hypertrophy in other parts of the Waldeyer ring, for example, lingual tonsil, can lead to secondary failure and recurrence of symptoms.<sup>8</sup> On the one hand, in patients with periodic fever without a specific cause, together with the history



of tonsillectomy or adenotonsillectomy, a lingual tonsillectomy could be considered as one treatment option. On the other hand, PFAPA has been considered as a self-resolving disease and the role of surgery is controversial.<sup>10,11</sup>

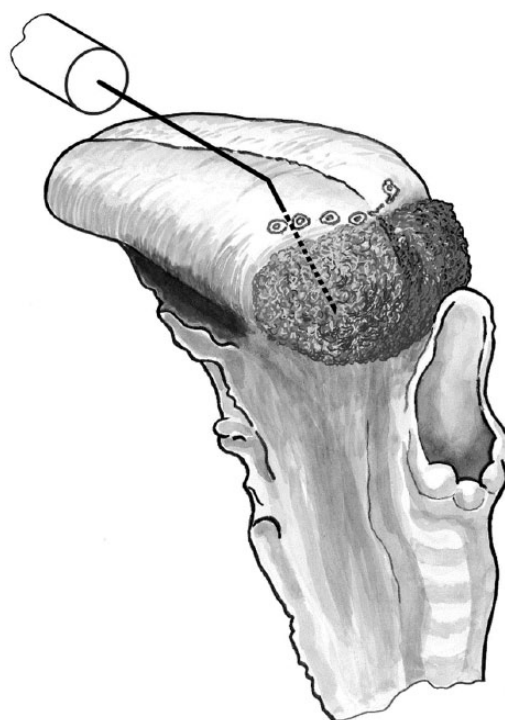
Lingual tonsillectomy remains a challenging procedure, with poor exposure and visualization, together with difficult haemostasis and risk of airway oedema.<sup>12</sup> There is no established standard procedure, and numerous approaches have been used, such as open surgical tongue base resection, coblation, radio frequency ablation (RFA) of the tongue base, and most recently transoral robotic surgery.<sup>13–15</sup> It is noteworthy that procedures involving partial resection of the tongue base, in addition to the removal of lingual tonsils, tend to carry high morbidity with possible complications such as bleeding, hypoglossal nerve paralysis, risk of airway compromise, and infections, such as lingual or submental abscess.<sup>7</sup>

The purpose of this study was to review the patients at our institute who have had lingual tonsil surgery for various indications. We also aimed to revisit the techniques used and their outcome. As low complication rates have earlier been reported to associate with RFA treatment given into lingual tonsil as a part of multi-level treatment for sleep apnoea, we were interested to see whether this technique would be feasible also for other indications.<sup>16</sup>

## Patients and Methods

Retrospective clinical data on all patients who had undergone an ablative operation of the tongue base during the 8-year period between January 1, 2007 and December 31, 2014 at the Helsinki University Hospital (HUU), Helsinki, Finland, were reviewed. This health care district covers approximately 1.6 million inhabitants. There were altogether 35 patients of whom 26 were men (74%) and 9 women (26%). Patients for whom the operation was done as part of multi-level surgery, due to obstructive sleep apnoea syndrome, were excluded, as we wanted to only include patients with problems specifically in lingual tonsil area. There were altogether 10 patients (age range: 16–53 years) treated with lingual tonsil radio frequency ablation (LTRFA) only. In all, 5 patients (50%, all women) had been operated because of symptomatic LTH and 5 (50%, 3 men) because of periodic fever with possible lingual tonsil involvement. No systematic classification of the lingual tonsils was used at our department during this period. According to the hospital charts, lingual tonsils were either normal or markedly hypertrophic.

All patients were treated with a bipolar RFA device (Celon AG Medical Instruments, Teltow/Berlin, Germany). The bipolar power control unit (CelonLab ENT) was used with an applicator (CelonProSleep) specifically designed for the base of the tongue. The diameter of the applicator needle is 1.3 mm and the length of the free electrode is 14 mm. The oropharynx was sprayed with lidocaine 10 mg/dose (Xylocaine, AstraZeneca, Sweden) as a topical anaesthetic. In addition, a 24-gauge needle



**Figure 1.** RFA treatment of the hypertrophic lingual tonsil. In this series, RFA treatment was applied by inserting the electrode into 6 spots at the base of the tongue – dorsally to the circumvallate papillae region. RFA indicates radio frequency ablation.

was used to inject lidocaine hydrochloride 10 mg/mL and epinephrine (Lidocaine, Orion, Finland) into the base of the tongue. The RFA treatment was applied by inserting the electrode into 6 spots at the base of the tongue in the circumvallate papillae region dorsally (Figure 1). The power setting was 6 W. With this power setting, the expected extent of coagulation would be 5.0 to 10.0 mm in the base of the tongue (as provided by the manufacturer).

## Results

The average age of the 10 patients treated with LTRFA only was 23.8 (range: 16–36) years for the periodic fever group and 36.3 (range: 20–53) years for the patients with symptomatic LTH. All 5 patients with periodic fever had a history of fever episodes for at least 2 years. For 2 patients, tonsillectomy or adenotonsillectomy had been performed in their childhood due to recurrent tonsillitis. All patients were primarily treated at the Department of Infectious Diseases and were referred to our department for consideration of operative treatment. Corticosteroids had been administered for all patients, and none of them had any abnormal laboratory findings. Of the 5 patients, 3 had not undergone a tonsillectomy in their childhood, so had had a tonsillectomy as the first intervention but with no effect on their symptoms. In 2 patients, the fever cycles ended after the operation. In one of these patients, the lingual tonsil was markedly hypertrophic, but in the other, it was of normal size. In 3 patients, the symptoms continued postopera-

tively and they all had their lingual tonsil preoperatively classified as normal.

The 5 patients with symptomatic LTH all had a globus sensation together with dysphagia and 4 also had dyspnoea, especially in the supine position. In clinical evaluation, all patients had a markedly hypertrophic lingual tonsil and in 1 patient, this was also verified with MRI. Histologically, all cases showed tonsillar hypertrophy without dysplasia. Three patients were treated with between 1 and 3 lingual tonsil radio frequency (RF)-reduction sessions and have been symptom free since. During the study period, we did not have any standard follow-up protocol, but the patients were advised to contact the department in case of any concerns. One patient continues to have severe symptoms after 1 laser operation and 7 RF-reduction sessions to the area of hypertrophic lingual tonsil. The possibility of radiotherapy has been discussed, but due to the patient's age (55 years), this has not been administered yet; however, he is under continuous follow-up. Our last patient is a 66-year-old woman with severe LTH. In addition to the repeated RF reductions to the affected area, she has also been administered with radiotherapy (20/2 Gy). She continued to have symptoms during a 4-year follow-up but have not consented to any new treatment alternatives. The volume of her lingual tonsil remained constant, which was verified with MRI after radiotherapy. No major complications were encountered after RFA treatment in this series.

## Discussion

There are numerous treatment options for LTH or periodic fever thought to be putatively caused by chronic infection in the area of lingual tonsils. The technique used for treatment is usually selected according to surgeon or hospital preference and based on the available instruments. Of our 10 patients, 5 responded well to RFA and have been symptom free since – 2 patients with periodic fever and 3 patients with symptomatic hypertrophy. There were no postoperative complications in this series. In our previous work, reporting the complications of all upper-airway RFA treatments at our institution during 1 year, there were altogether 23 patients who received LTRFA.<sup>16</sup> Of these, 1 patient (4.3%) experienced a minor postoperative bleeding, which was managed conservatively.<sup>16</sup>

There have been recent reports on novel classification systems evaluating the severity of LTH.<sup>1</sup> In the present series, no clinical classification was used, which makes it impossible to retrospectively evaluate the relationship between disease stage, given treatment, and its outcome. In the future, use of a classification system will be essential to be able to better choose between the different treatment options. Another clear limitation of this study is the low number of patients, although not many significantly larger studies exist in the literature.<sup>17</sup>

In our opinion, the treatment options for LTH can be divided into either tissue volume reduction by RFA or

techniques aimed at removal of excessive tissue. Radiofrequency ablation is an electrosurgical treatment modality that has been used in a variety of procedures in the area of head and neck for almost 2 decades.<sup>18,19</sup> Using thermal ablation, a precise controllable lesion can be created in the treatment area without any removal of tissue. The idea of using radio frequency volume reduction in the treatment of LTH was based on the finding by us and others that RFA was effective in treating palatine tonsil hypertrophy.<sup>20–22</sup> In patients with palatine tonsil hypertrophy, the results have been promising and have resulted in reduced tonsillar volume, seen with MRI images.<sup>20</sup> For some reasons, this phenomenon was not seen in our patients with LTH, as most of the patients did have recurrent symptoms after several lingual tonsil RF-reduction treatments. The underlying reason remains unknown, although we hypothesize that the severity of the hypertrophy and dosage/frequency of the given treatment might have been possible interfering factors. In the case of a patient with PFAPA, use of RFA as a minimally invasive technique might be feasible, if any treatment at all is warranted, as the disease might also resolve by itself by time. Compared with lingual tonsillectomy, the morbidity associated with RFA is lower.

For patients with severe hypertrophy, treatment techniques aiming to completely remove the lingual tonsils instead of volume reduction could be more efficient. Traditional open techniques are less used because of their high morbidity. On the contrary, minimally invasive robotic surgery has become popular during the past decade in the treatment of both benign and malignant tumours of the tongue base and could serve as one possibility in the future. From 2012 onwards, there have been a few studies<sup>13,15,23</sup> reporting good results on transoral robotic surgery in the treatment of lingual hypertrophy, although the average follow-up time in these studies is rather limited. This technique has many advantages, such as good visualization with a magnified view allowing good exposure to the tongue base and the possibility of better preservation of critical neurovascular structures. Also, complications are sparser when compared with open techniques, and there is no need for perioperative tracheotomy.<sup>15</sup> Thus far, we have not treated any patients with LTH with robotic surgery, but our experience of using this technique for partial tongue base resection in patients with an unknown primary tumour, and those with a base of the tongue tumour, have been promising.

## Conclusions

We conclude that the introduction of a clinical classification for the severity of LTH would be mandatory to be able to better target appropriate therapy for the right patients. Lingual tonsil radio frequency ablation seems to be a low-morbidity technique to address various tongue base conditions, and its effectiveness should be evaluated in a prospective study setting.

## Author Contributions

SR: collecting the data, writing of the manuscript. AM: participated in writing, illustration. LB: design of the study, participated in writing.

## REFERENCES

1. Friedman M, Yalamanchali S, Gorelick G, Joseph NJ, Hwang MS. A standardized lingual tonsil grading system: interexaminer agreement. *Otolaryngol Head Neck Surg.* 2015;152:667–672.
2. Sung MW, Lee WH, Wee JH, Lee CH, Kim E, Kim JW. Factors associated with hypertrophy of the lingual tonsils in adults with sleep-disordered breathing. *JAMA Otolaryngol Head Neck Surg.* 2013;139:598–603.
3. DeGaudio JM, Naseri I, Wise JC. Proximal pharyngeal reflux correlates with increasing severity of lingual tonsil hypertrophy. *Otolaryngol Head Neck Surg.* 2008;138:473–478.
4. Acar GO, Cansz H, Duman C, Oz B, Cigerciogullar E. Excessive reactive lymphoid hyperplasia in a child with persistent obstructive sleep apnea despite previous tonsillectomy and adenoidectomy. *J Craniofac Surg.* 2011;22:1413–1415.
5. Guimaraes CV, Kalra M, Donnelly LF, et al. The frequency of lingual tonsil enlargement in obese children. *AJR Am J Roentgenol.* 2008;190:973–975.
6. Friedman M, Wilson MN, Pulver TM, et al. Measurements of adult lingual tonsil tissue in health and disease. *Otolaryngol Head Neck Surg.* 2010;142:520–525.
7. Leitzbach SU, Bodlaj R, Maurer JT, Hormann K, Stuck BA. Safety of cold ablation (coblation) in the treatment of tonsillar hypertrophy of the tongue base. *Eur Arch Otorhinolaryngol.* 2014;271:1635–1639.
8. Colotto M, Maranghi M, Durante C, Rossetti M, Renzi A, Anatra MG. PFAPA syndrome in a young adult with a history of tonsillectomy. *Intern Med.* 2011;50:223–225.
9. Hernandez Vidal MJ, Trasancos Escura C, Meseguer Noguera R, Gil Ortega MDM. PFAPA syndrome: diagnosis in adulthood. *Rev Clin Esp.* 2015;215:192–193.
10. Burton MJ, Pollard AJ, Ramsden JD, Chong LY, Venekamp RP. Tonsillectomy for periodic fever, aphthous stomatitis, pharyngitis and cervical adenitis syndrome (PFAPA). *Cochrane Database Syst Rev.* 2014;11:CD008669.
11. DeMarcantonio MA, Senser E, Meinen-Derr J, Roetting N, Shott S, Ishman SL. The safety and efficacy of pediatric lingual tonsillectomy. *Int J Pediatr Otorhinolaryngol.* 2016;91:6–10.
12. Maturo SC, Mair EA. Coblation lingual tonsillectomy. *Otolaryngol Head Neck Surg.* 2006;135:487–488.
13. Hoff PT, D'Agostino MA, Thaler ER. Transoral robotic surgery in benign diseases including obstructive sleep apnea: safety and feasibility. *Laryngoscope.* 2015;125:1249–1253.
14. MacKay SG, Jefferson N, Grundy L, Lewis R. Coblation-assisted Lewis and MacKay operation (CobLAMO): new technique for tongue reduction in sleep apnoea surgery. *J Laryngol Otol.* 2013;127:1222–1225.
15. Muderris T, Sevil E, Bercin S, Gul F, Kiris M. Transoral robotic lingual tonsillectomy in adults: preliminary results. *Acta Otolaryngol.* 2015;135:64–69.
16. Back LJ, Liukko T, Sinkkonen ST, Ylikoski J, Makitie AA. Complication rates of radiofrequency surgery in the upper airways: a single institution experience. *Acta Otolaryngol.* 2009;129:1469–1473.
17. Mowry SE, Ament M, Shapiro NL. Lingual tonsil hypertrophy causing severe dysphagia: treatment with plasma-mediated radiofrequency-based ablation (coblation). *Ear Nose Throat J.* 2010;89:134–136.
18. Chhabra N, Houser SM. The surgical management of allergic rhinitis. *Otolaryngol Clin North Am.* 2011;44:779–795, xi.
19. Fuller CW, Nguyen SA, Lohia S, Gillespie MB. Radiofrequency ablation for treatment of benign thyroid nodules: systematic review. *Laryngoscope.* 2014;124:346–353.
20. Back L, Tervahartiala P, Piilonen A, Makitie A, Ylikoski J. Assessment of submucosal radiofrequency tonsil reduction by magnetic resonance imaging. *J Otolaryngol Head Neck Surg.* 2009;38:537–544.
21. Nelson LM. Radiofrequency treatment for obstructive tonsillar hypertrophy. *Arch Otolaryngol Head Neck Surg.* 2000;126:736–740.
22. Terk AR, Levine SB. Radiofrequency volume tissue reduction of the tonsils: case report and histopathologic findings. *Ear Nose Throat J.* 2004;83:572, 574, 576–578.
23. Leonardi RL, Duvvuri U, Mehta D. Transoral robotic-assisted lingual tonsillectomy in the pediatric population. *JAMA Otolaryngol Head Neck Surg.* 2013;139:1032–1036.