

<https://helda.helsinki.fi>

A tall rostral hook in a medieval horse premolar tooth

Viranta, Suvi

2017-06

Viranta , S & Mannermaa , K 2017 , ' A tall rostral hook in a medieval horse premolar tooth ' ,
International journal of paleopathology , vol. 17 , pp. 79-81 . <https://doi.org/10.1016/j.ijpp.2017.02.005>

<http://hdl.handle.net/10138/237013>

<https://doi.org/10.1016/j.ijpp.2017.02.005>

publishedVersion

Downloaded from Helda, University of Helsinki institutional repository.

This is an electronic reprint of the original article.

This reprint may differ from the original in pagination and typographic detail.

Please cite the original version.



Brief communication

A tall rostral hook in a medieval horse premolar tooth

Suvi Viranta^{a,*}, Kristiina Mannermaa^b^a Faculty of Medicine, Anatomy, PO Box 63 (Haartmaninkatu 8), 00014 University of Helsinki, Finland^b Department of Philosophy, History, Culture and Art Studies/Archaeology, PO Box 59, 00014 University of Helsinki, Finland

ARTICLE INFO

Article history:

Received 7 August 2015

Received in revised form 17 February 2017

Accepted 20 February 2017

Available online 6 March 2017

Keywords:

Dental disease

Equine

Focal overgrowth

Occlusal wear

Premolar teeth

ABSTRACT

Development of dental abnormalities due to improper occlusal wear is common among modern domestic horses. This phenomenon often is attributed to jaw conformation. Rostral mandibular hooks may develop in horses with underjet or mandibular prognathism, a condition where the lower jaw protrudes forward, beyond the upper jaw. Less abrasive diet, free of phytoliths and matrix-like plant fibers, also may promote enamel and focal overgrowths of equine dentition. Here we report a rostral mandibular hook in a lower premolar tooth of a medieval horse, found in a spring deposit in Levänluhta, Ostrobothnia, Finland. To our knowledge, this is the first such report from a medieval horse.

© 2017 Elsevier Inc. All rights reserved.

1. Introduction

All modern equids have hypsodont teeth. Hypsodont teeth are high-crowned teeth. Unlike brachydont teeth, part of the hypsodont crown remains in the jaw after eruption, and hypsodont teeth continue to erupt into old age.

Hypsodonty probably is an adaptation to provide sufficient dental material to buffer against tooth wear during a long life that required voluminous intake of plant material (Janis and Fortelius, 1988). Climatic cooling and increasing predominance of grasslands occurred during the Miocene. Tooth evolution toward hypsodonty was gradual among the Miocene subfamily Equinae, while other equids maintained low-crowned teeth as grasslands spread in North America (Damuth and Janis, 2011). Climate-driven re-development of natural forage would have required adaptation to more abrasive diet content and larger amounts of daily food intake (Damuth and Janis, 2011). At the same time, the equine digestive tract appears to have adapted to facilitate digestion of increasingly large amounts of forage having poorer nutritional content (Janis, 1976). By the end of the Miocene, all brachydont forms were extinct and hypsodonts flourished (Mihlbachler et al., 2011).

Evolution of hypsodonty also was associated with increasing occlusal surface complexity. As dental wear depends on the occluding teeth, disorders of dental alignment are not unexpected

with hypsodonty. Dental overgrowths can result from lack of an occluding counterpart during mastication, which can be due to malocclusion, uneven length of tooth rows, or mechanical problems with the mastication cycle. Overgrowths such as lateral ridges on maxillary teeth, medial ridges on mandibular teeth, or sharp focal points at the mesial and distal ends of tooth rows, are examples of such alignments of the dental arcades. Here we present a medieval horse second mandibular premolar with rostral focal overgrowth (dental hook).

2. Materials and methods

Levänluhta is an Iron Age human water burial site in western Finland (Ostrobothnia) (Fig. 1). The site has yielded animal bones and a few artifacts. According to pollen analyses, humans were buried in an aquatic ecosystem, possibly a small lake. The human remains and artifacts date to the Merovingian period (AD 550/600–800) (Wessman, 2009). Most non-human bones are from horses (*Equus caballus*) (Formisto, 1993).

Until very recently, horse remains from this site were assumed to have accumulated around the same time as the human-related material. However, AMS (accelerator mass spectrometry) radiocarbon analysis reveals that the horses were buried later than the humans, with the horses dating to the late medieval period AD 1300–1500 (Finnish medieval chronology). At the Iron Age site was a small lake, but in medieval times, it most likely was a meadow with a concentration of springs. During the late 19th century, the meadow was drained to arable land (Wessman, 2009).

* Corresponding author.

E-mail addresses: suvi.viranta-kovanen@helsinki.fi (S. Viranta), kristiina.mannermaa@helsinki.fi (K. Mannermaa).

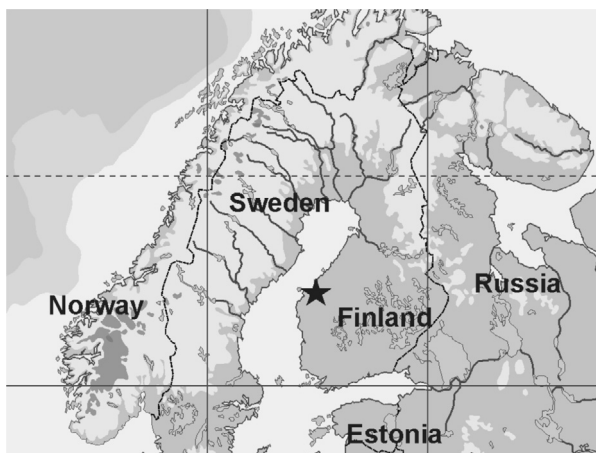

Fig. 1. Location of Levänluhta in Ostrobothnia, western Finland (black star).

KM21814:525 Levänluhta equine lower right premolar




Fig. 2. KM21814:525 Equine pm2 dex (406) with a marked rostral overgrowth from Levänluhta, Finland. The tooth was found intact but the anterior root was sampled for the AMS dating. Photo Suvi Viranta@ Finnish National Board of Antiquities.

During the late medieval period, the climate probably was similar to the modern climate. Ostrobothnia has boreal vegetation and a boreal climate with snow cover during the winter.

The distribution of the horse material in Levänluhta is fragmentary and disassociated. The material consists of cranial and postcranial bone fragments and isolated teeth. At least five horses are represented. All of the osteological material was analyzed by Formisto (1993), and non-human osteological material was re-analyzed and catalogued by Mannermaa (2013). The bone material from Levänluhta is curated at the Finnish National Museum (NM) in Helsinki.

For this report, we examined a first lower cheek tooth (pm2 dex or 406, NM catalog number KM21814:525, Fig. 2) with a peculiar rostral focal overgrowth. We confirmed the identification of the tooth as pm2 dex, using the methods described in Hillson (1990), along with comparative material in the equine collection

of the Finnish Museum of Natural History. The tooth dimensions and height of the focal overgrowth were measured. The time taken for the overgrowth to develop was calculated using the estimate of 2.0–2.5 mm annual dental wear, as given by Baker (1999). The height of the focal overgrowth was compared with data provided by Simhofer et al. (2008). The rate of wear of the height dimension depends on the diet (Karme et al., 2016), but a rough estimate of the horse's age at the time of death can be developed using the height of a post-canine tooth. We used the wear curve provided by Levine (1982) to estimate the age of KM21814:525 horse at the time of death.

3. Results

KM21814:525 is a relatively tall equine premolar tooth (ca. 40 mm without the root). Using the graph provided by Levine (1982; Fig. 10), we estimated the age of death for KM21814:525 to be 7 years. The mesiodistal dimension of the crown is 32 mm. This is in the expected range of mesiodistal length, as indicated for New Forest pony pm2 teeth (Levine, 1982). KM21814:525 reveals a typical wear pattern of a mandibular post-canine tooth with linguo-lateral inclination. The lingual margin is higher than the lateral margin. A focal growth with a length one third of the total tooth length arises rostrally, having peak height 9 mm (Fig. 2). Based on annual wear estimate (Baker, 1999), it had taken 4.5 years for the hook to develop.

4. Discussion

We describe a focal, moderate overgrowth of a mandibular rostral tooth from a medieval horse. A study of 300 modern horses revealed usually-bilateral focal overgrowths and rare mandibular rostral overgrowths (involving just 2% of horses that were examined) (Simhofer et al., 2008). In another study of 400 horses, Dixon et al. (1999) reported no mandibular rostral overgrowths.

We are not aware of previous reports of focal overgrowths on teeth of medieval horses. Taylor et al. (2015) studied dental wear and pathologies in modern captive and free ranging equids, including Przewalski's horse, a close relative of the domestic horse. Only maxillary teeth were included in the analysis. Focal overgrowths were more common among captive equids (20.8% in captives vs. 6.6% in free-ranging).

Dental overgrowths can result from lack of an occluding counterpart during mastication. Causes can include malocclusion, uneven length of tooth rows, or mechanical problems with the mastication cycle. Horse mastication includes both lateral and vertical movements. Dietary forage encourages a full movement cycle of the mandible (Dixon, 2000). Modern horses fed on pellets have smaller mandibular excursion than horses eating roughage (Bonin et al., 2007). However, the latter mainly affects vertical movement, and is unlikely to be the cause of rostral hooks.

Rostral mandibular hooks are likely to develop in horses with underjet or mandibular prognathism, a condition where the lower jaw protrudes beyond the upper jaw. Mandibular teeth become located more rostral than maxillary counterparts, causing malocclusion (Dixon and Dacre, 2005). The event is rare in modern horses, but occurs in some miniature ponies and donkeys; heritable cause has been proposed in the latter instances (Rodrigues et al., 2013).

Cavalry documents from the 17th century indicate that the horses in Finland were small, the size of modern ponies. The documented height was measured behind the saddle and is reported to fall between 120 and 132 cm (Bläuer, 2015). The horses were used for riding and draught work. Riding was, in addition to cavalry, a mean of transportation. Ostrobothnia did not have sufficient roads for carriages at this time.

Documents from the royal demesnes (feudal manors owned by the King) from the late 16th century indicate the following winter-feeding for horses: Stallions—over 5 kg of hay per day; mares—3 kg/day; and working horses—over 4 kg/day. All were supplemented with straw. Horses also were fed oats and barley. Quantities varied according to the use of horse and location. For example, Ulvila royal demesne offered 25.5 L of oats and 22.9 L barley in a week (Bläuer, 2015). Horses owned by peasants may have had to do with less, although apparently they were provided more abundant winter-fodder than other domestic livestock (e.g., Kivikero, 2010; Bläuer, 2015).

Historical documents from the 16th century indicate that horses were let to graze free during the summer, when they were not used for work (Bläuer, 2015). It has been suggested that some horses may have been left to forage on their own throughout the year (Sundkvist, 2004).

Our earlier study (Viranta and Mannermaa, 2014) suggested that the Levänluhta horses were maintained on a non-abrasive diet, at least for a part of the year. According to experimental studies, grass is the most abrasive food item, consisting of phytoliths and external grit such as silicates from the soil (Karme et al., 2016). Masey O'Neill et al. (2010) describe evidence that focal dental overgrowths (modern horses) are more common in those that are stabled and pellet-fed, compared with free-grazing horses. It is possible that a less abrasive diet, free of phytoliths and matrix-like plant fibers, may have promoted the rostral hook in this medieval horse. Many modern domestic horses have their teeth floated (have the excess dental material rasped off) annually to prevent pronounced enamel ridges or overgrowths on post-canine teeth (Dixon, 2000). Little is known with certainty about medieval horse husbandry in Finland or in neighboring countries, and further research seems appropriate.

5. Conclusions

A medieval horse premolar tooth, excavated from Levänluhta archaeological site in western Finland, reveals a rare dental pathology, a focal rostral overgrowth. In modern horses, the condition is caused most frequently by mandibular prognathism. Unfortunately, no other cranial remains of this horse were found. Thus, further studies of dental occlusal wear should be done to acquire additional knowledge of animal husbandry during pre-historical and historical times.

Contributorship

KM performed the original analyzes on the Levänluhta equine teeth. SV measured and analyzed the condition in KM21814:525. SV drafted the manuscript. Both authors contributed to the final version and approved the manuscript.

Funding

This research is a part of the Levänluhta-Project funded by Emil Aaltonen Foundation (granted for Dr. Anna Wessman, University of Helsinki).

Competing interest

None.

Ethical concern

None.

Acknowledgments

We are grateful for Dr. Jukka Holopainen (Equivet) for discussion on modern equine dental problems and care. Finnish National Board of Antiquities is thanked for allowing work with the material from Levänluhta. Ella Kovanen helped with the photos. We also are very grateful to the two anonymous reviewers and the editor Dr. Dennis F. Lawler for comments and suggestions that improved the manuscript.

References

- Baker, J.G., 1999. Abnormalities of development and eruption. In: Baker, G., Easley, J. (Eds.), *Equine Dentistry*. W.B. Saunders, London, pp. 49–59.
- Bläuer, A., 2015. Voita, villaa ja vetoeläimiä. Karjan ja karjanhoidon varhainen historia Suomessa. Karhunhammas 17. University of Turku, Kurikka, 224 pp.
- Bonin, S.J., Clayton, H.M., Lanovaz, J.L., Johnston, T., 2007. Comparison of mandibular motion in horses chewing hay and pellets. *Equine Vet. J.* 39 (3), 258–262.
- Damuth, J., Janis, C.M., 2011. The relationship between hypsodonty and feeding ecology in ungulate mammals, and its utility in palaeoecology. *Biol. Rev.* 86, 733–758.
- Dixon, P.M., Tremaine, W.H., Pickles, K., Kuhns, L., Hawe, C., McCann, J., McGorum, B.C., Raiton, D.I., Brammer, S., 1999. *Equine dental disease. Part 2: a long-term study of 400 cases: disorders of development and eruption and variations in position of the cheek teeth*. *Equine Vet. J.* 31 (6), 519–528.
- Dixon, P.M., 2000. Removal of equine dental overgrowths. *Equine Vet. Educ.* 12, 68–81.
- Dixon, P.M., Dacre, I., 2005. A review of equine dental disorders. *Vet. J.* 169 (2), 165–187.
- Formisto, T., 1993. An osteological analysis of human and animal bones from Levänluhta. Ph.D. Thesis. Stockholm University.
- Hillson, S., 1990. *Teeth*. Cambridge University Press, Cambridge, pp. 379.
- Janis, C., 1976. The evolutionary strategy of the Equidae and the origins of rumen and cecal digestion. *Evolution* 30 (4), 757–774.
- Janis, C.M., Fortelius, M., 1988. On the means whereby mammals achieve increased functional durability of their dentitions with special reference to limiting factors. *Biol. Rev.* 63, 197–230.
- Karme, A., Rannikko, J., Kallonen, A., Clauss, M., Fortelius, M., 2016. Mechanical modelling of tooth wear. *J. R. Soc. Interface* 13 (120), 20160399.
- Kivikero, H., 2010. Benfynden och djurens betydelse för ett bysamhälle. In: Koivisto, A., Koivisto, R., Hako, J. (Eds.), *Gubbacka. Medeltida vardag i Vanda*. pp. 160–171.
- Levine, M.A., 1982. The use of crown height measurements and eruption-wear sequences to age horse teeth. In: Wilson, B., Grigson, C., Payne, S. (Eds.), *Ageing and Sexing Animal Bones from Archaeological Sites: 223–50*. BAR British Series 109, Oxford, British Archaeological Reports.
- Mannermaa, K., 2013. Unpublished Analysis Report at the Topographic Archives of the Finnish National Board of Antiquities.
- Masey O'Neill, H.M., Keen, J., Dumbell, L., 2010. A comparison of the occurrence of common dental abnormalities in stabled and free-grazing horses. *Animal* 4, 1697–1701.
- Mihlbachler, M.C., Rivals, F., Solounias, N., Semperebon, G.M., 2011. Dietary change and evolution of horses in North America. *Science* 331 (6021), 1178–1181.
- Rodrigues, J.B., Araújo, S., Guedes-Pinto, H., San Roman, F., Viegas, C., Bastos, E., 2013. Analysis of new Matrillin-1 gene variants in a case-control study related to dental malocclusions in *Equus asinus*. *Gene* 522 (1), 70–74.
- Simhofer, H., Griss, R., Zetner, K., 2008. The use of oral endoscopy for detection of cheek teeth abnormalities in 300 horses. *Vet. J.* 178 (3), 396–404.
- Sundkvist, A., 2004. Herding horses: a model of prehistoric horsemanship in Scandinavia – and elsewhere? In: Santillo Frizell, B. (Ed.), *Man and Animal in Antiquity*. Proc. Conf. Swedish Ins., Rome, pp. 241–249.
- Taylor, L.A., Müller, D.W.H., Schwitzer, C., Kaiser, T.M., Castell, J.C., Clauss, M., Schulz-Kornas, E., 2015. Comparative analyses of tooth wear in free-ranging and captive wild equids. *Equine Vet. J.*, <http://dx.doi.org/10.1111/evj.12408>.
- Viranta, S., Mannermaa, K., 2014. Mesowear analysis on Finnish medieval horses. *Annales Zoologici Fennici* 51 (1), 119–122.
- Wessman, A., 2009. Levänluhta – a place of punishment, sacrifice or just a cemetery? *Fennoscandia archaeologica* 16, 81–105.