

UC Davis

Dermatology Online Journal

Title

Malacoplakia of the skin: overview of a rare clinical entity

Permalink

<https://escholarship.org/uc/item/3dc495vk>

Journal

Dermatology Online Journal, 25(6)

Authors

Kyriakou, Georgia
Gialeli, Efthymia
Vryzaki, Eleftheria
et al.

Publication Date

2019

License

[CC BY-NC-ND 4.0](#)

Peer reviewed

Malacoplakia of the skin: overview of a rare clinical entity

Georgia Kyriakou¹ MD MsC PhD, Efthymia Gialeli¹ MD, Eleftheria Vryzaki¹ MD PhD, Dimitra Koumoundourou² MD MsC PhD, Apostolos Glentis³ MD, Sophia Georgiou¹ MD PhD

Affiliations: ¹Department of Dermatology, University General Hospital of Patras, Greece, ²Department of Pathology, University General Hospital of Patras, Greece, ³Department of General Medicine, University General Hospital of Patras, Greece

Corresponding Author: Georgia Kyriakou MD, MsC, PhD, University General Hospital of Patras, Rio 265 04, Greece, Tel: 30-6936873936, Email: geo_kyr@yahoo.gr

Abstract

Background: Malacoplakia is a rare acquired, infection-related granulomatous disorder, that may affect many systems, but typically occurs in the urinary tract. Cutaneous involvement is less prevalent, and most commonly presents with a perianal or genital region localization. Cutaneous malacoplakia is believed to be caused by an acquired bactericidal defect of macrophages in the setting of chronic infections and immunocompromised states. A diagnosis of cutaneous malacoplakia should be considered when encountering non-specific granulomatous lesions that are refractory to treatment. Histologic findings are marked by the presence of foamy macrophages containing the pathognomonic Michaelis-Gutman bodies.

Objectives: The aim of this review is to discuss the current perspectives on the pathophysiology, clinical features, diagnosis, and treatment of this disease. We would also like to emphasize that the integration of clinical information, microscopic findings, and exclusion of other cutaneous granulomatous processes is necessary to accurately diagnose this exceedingly rare disease and provide opportunity for therapeutic intervention.

Patients/Methods: Data for this work were collected from the published literature and textbooks.

Results: Combined surgical excision and protracted antibiotic courses appear to have the highest success rate. Antibiotics should be culture specific, but drugs that easily permeate the macrophages appear to be the best choice.

Keywords: cutaneous malacoplakia, Michaelis-Gutman bodies, von Hansemann cells, granulomatous disorder, review

Introduction

Malacoplakia is a rare non-malignant inflammatory granulomatous disease of infectious etiology that is usually reported in the setting of deficient immune responsiveness such as in HIV infection [1-3]. It was first described by Michaelis and Gutmann in 1902 [2, 4] and one year later by von Hansemann who named the lesion malacoplakia from the Greek malakos (soft), and plaka (plaque), [5]. The first case of cutaneous malacoplakia was not reported until 1972 by Leclerc and Bernier [6].

This literature search was conducted according to the Preferred Reporting Items for Systematic Reviews, or PRISMA, guidelines. Three databases, EMBASE, SCOPUS and MEDLINE (PubMed) were thoroughly searched using the following MESH key terms: "cutaneous" and "malacoplakia" or "malakoplakia." Additional papers were also identified from the reference lists of the above retrieved papers and citations, as identified by Web of Science. The selection process was done through an initial screening of titles and abstracts, followed by evaluation of full text articles. According to the results, about 500 cases have been described in numerous anatomic locations. The most common site of occurrence is the genitourinary tract, but other locations have also been encountered, including the gastrointestinal tract, lungs, central nervous system, eyes, retroperitoneum, thyroid gland, lymph nodes, oropharynx, bones, joints, skin, and subcutaneous tissue [2, 7]; the cutaneous form is a less prevalent presentation of the disease and,

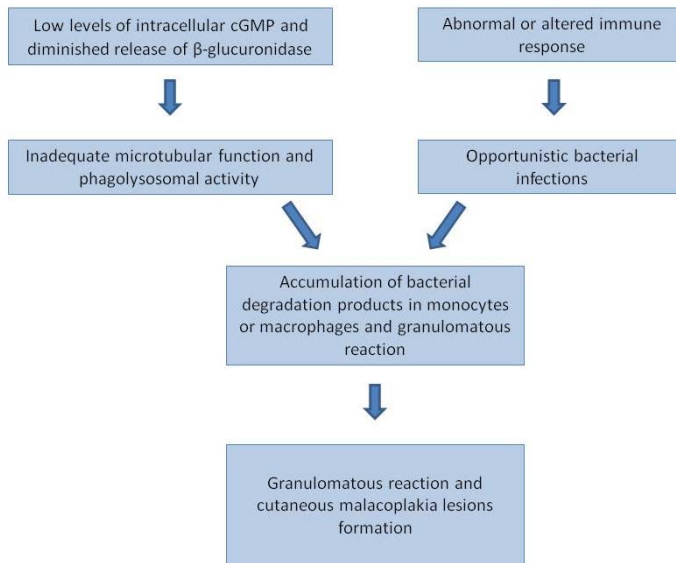


Figure 1. Etiopathogenesis of cutaneous malacoplakia.

most commonly occurs in the anogenital region [3, 8]. Since its initial description, only 52 cases of primary cutaneous malacoplakia have been reported in the literature [9].

Etiology and pathogenesis

The etiopathogenesis of malacoplakia has not been fully elucidated. However, it is believed to be secondary to a defect of the bactericidal capacity of macrophages after endocytosis [3, 10]. Inadequate microtubular function and phagolysosomal activity is related to deficiencies of beta-glucuronidase and intracellular cyclic guanosine monophosphate (cGMP) and leads to accumulation of partially digested bacteria in monocytes or macrophages [9, 11]. The pathognomonic Michaelis-Gutman bodies are believed to represent the subsequent deposition of calcium and iron on non-exocytosed phagolysosomes [2, 10].

Additionally, there is a well-documented association between malacoplakia and immunosuppression (**Figure 1**). The majority of subjects are immunodeficient and include HIV-infected patients, patients with malignancy, patients with diabetes mellitus, and organ transplant recipients [3, 8].

In this setting of immunodeficiency, as many as 90% of patients have coliform bacteria detected in blood, urine or tissue, suggesting an opportunistic bacterial infection as the central event [3, 12]. The most

commonly involved microorganisms include *Escherichia coli* (more than 2/3 of cases), *Klebsiella*, *Proteus* [2, 9], *Mycobacterium tuberculosis*, *Mycobacterium avium*, *Staphylococcus aureus*, *Shigella*, *Rhodococcus equi* and *Enterococcus spp* [3, 9]. Malacoplakia with negative culture results have also been reported, but is presumably secondary to antibiotic therapy administration prior to diagnosis [5].

Epidemiology

Cutaneous malacoplakia tends to occur in an older age group, most commonly affecting the age group of sixth to seventh decade, with the median age at the time of presentation being 53 years [2, 9]. Pediatric cases are exceptionally rare [3, 13].

Of the 52 cases of cutaneous malacoplakia reported so far, reports show a prevalence among men, with a male-to-female ratio of 2.3:1. There does not seem to be any racial predilection [2, 5]. The most common site of involvement is the anogenital area (41%),

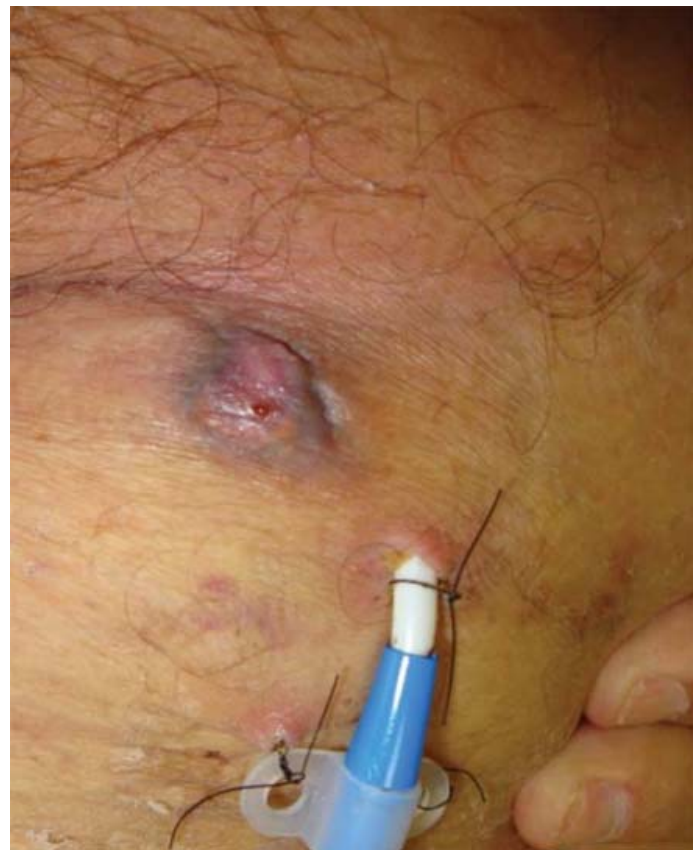

Figure 2. A yellow-erythematous-purple plaque at a site of frequent catheterization on a patient with chronic renal failure [3].

trunk (20%), head and neck (20%), extremities (10%), and axillae (10%), [5, 14]. However, there have been reports of lesions that were distributed in more than one cutaneous site [5, 15-16].

Clinical features

Clinically, cutaneous malacoplakia may present with a wide variety of findings; tissue biopsy is required for definitive diagnosis. Although the name describes its common clinical presentation as friable, yellow soft plaques, lesions may also arise as yellow, skin-colored or erythematous papules, ulcerations [14, 17-18], draining abscesses and fistulas, subcutaneous nodules, nonhealing surgical wounds, or polypoid masses (**Figure 2**), [3, 5]. The most common clinical presentation in reported cases of cutaneous malacoplakia are mass-like lesions or nodules (**Figure 1**), (45%), occasionally complicated

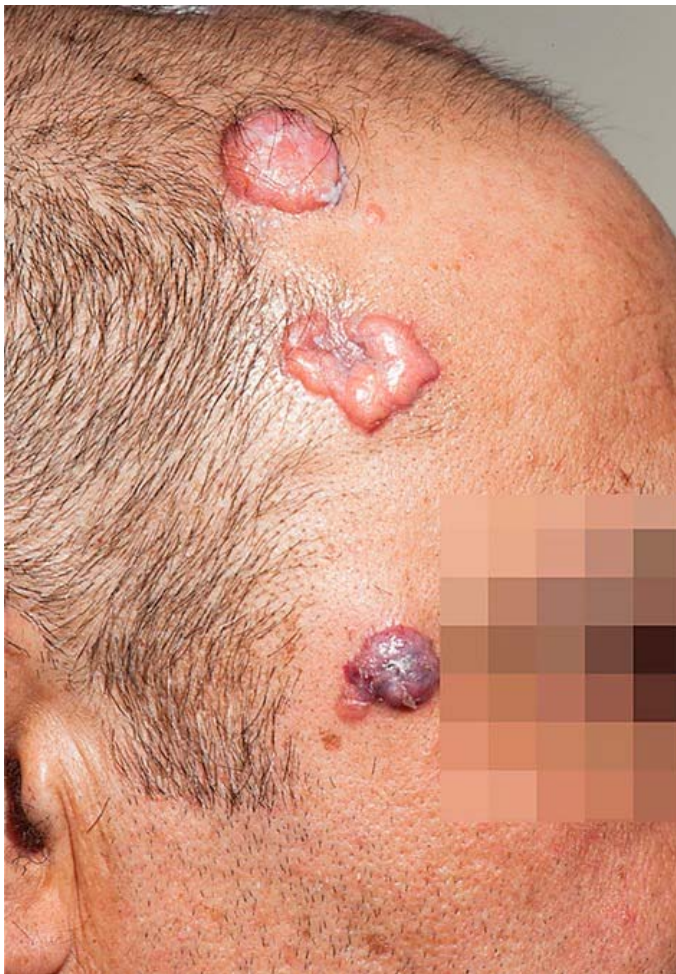

Figure 3. Typical lesions on the face of an immunocompromised patient [19]. Reprinted with permission from the Massachusetts Medical Society.

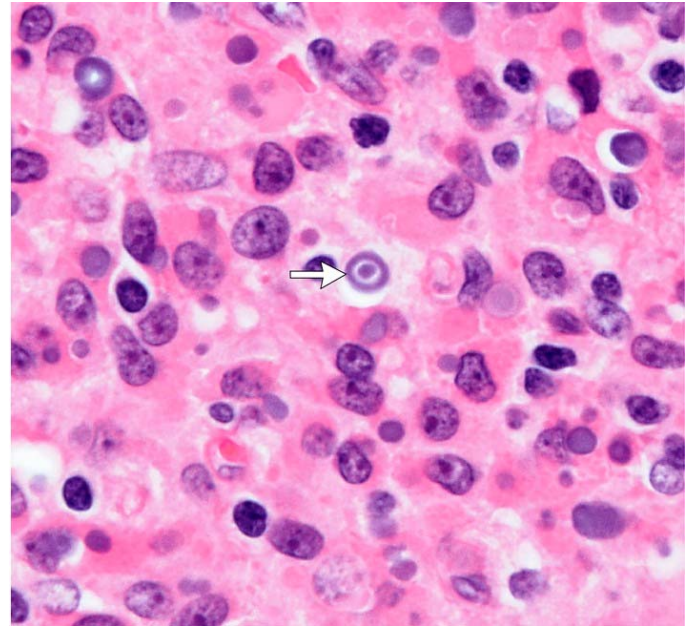


Figure 4. Pathognomonic Michaelis-Gutmann body (arrow), [19]. H&E, 400x. Reprinted with permission from the Massachusetts Medical Society.

by abscess and ulceration formation in 18% and 23% of the cases, respectively [5, 10].

Histopathology

The diagnosis of cutaneous malacoplakia is never made clinically but on specific histologic grounds, owing to its rarity and non-specific appearance, and also to exclude other important diseases in the differential diagnosis, such as malignancy [8, 20].

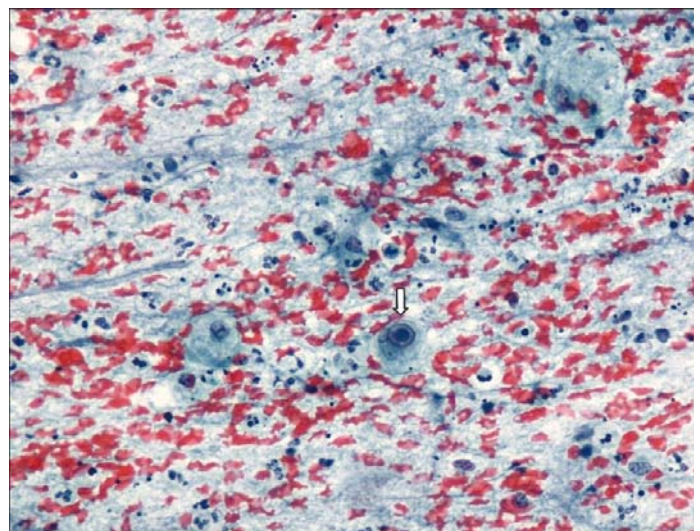


Figure 5. Papanicolaou stain, 200x. Concentrically lamellated, darkly staining, calcified inclusion bodies (Michaelis-Gutmann bodies) inside the macrophages [22].

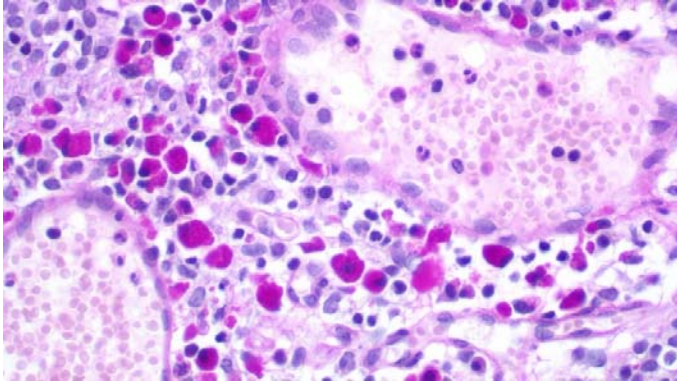


Figure 6. Periodic acid-Schiff stain, 400x. Dr. Koumoundourou, personal collection.

Histopathologically, the disease is characterized by the presence of dermal sheets of enlarged foamy histiocytic cells containing an eccentric, hyperchromatic, round nucleus as well as fine eosinophilic granules (von Hansemann cells), [3]. There is a variable associated inflammatory infiltrate consisting mainly of scattered lymphocytes, immunoblasts, and neutrophils in the dermis [4-5]. However, this challenging diagnosis can only be made by identifying the pathognomonic Michaelis-Gutmann bodies, first described in 1902 as targetoid, calcified, intracytoplasmic inclusion bodies (**Figure 4**), [21]. These Michaelis-Gutmann bodies are believed to represent partially degraded remnants of bacterial organisms and stain positively with periodic acid Schiff, Von Kossa (calcium), Perl (iron) stains [3, 8], alizarin red, and Prussian blue stains (**Figures 5, 6**), [5, 14].

Discussion

Differential diagnosis

The differential diagnosis of cutaneous malacoplakia commonly includes infectious diseases and malignant processes [8]. Infections to consider are deep fungal infections, actinomycosis, leishmaniasis, Whipple disease, as well as granulomatous infections such as tuberculosis and lepromatous leprosy [3, 5]. Neoplastic and reactive/reparative processes include eosinophilic granuloma (histiocytosis X), lymphoma, granular cell tumors, sarcoidosis, xanthomas, hidradenitis suppurativa, and foreign body granuloma [5, 23].

Treatment

Successful treatment of malacoplakia largely depends on the extent of disease as well as the underlying condition of the patient. Owing to the lack of prospective comparative studies, many treatments have been reported, which vary from antibiotic therapy to surgical excision [3, 14]. However, protracted antibiotic courses directed against gram-negative bacteria, especially *E. coli*, combined with surgical excision appear to be the most common and successful approach [8, 10].

Administration of culture specific antibiotic therapy, antibiotics that reach high intracellular concentration within macrophages (e.g. quinolones and trimethoprim-sulfamethoxazole) as well as penicillins and clofazimine are associated with a high cure rate and appear to be the best empirical choice [8, 10, 24-25].

Alternative reported treatment options include muscarinic receptor agonists such as bethanechol chloride as well as ascorbic acid, both of which act to correct the decreased intracellular cGMP levels that are believed to interfere with inefficient microtubule functioning and bacterial killing [19, 26]. Discontinuation of immunosuppressive therapy, and treatment of any underlying medical conditions causing immunosuppression (e.g. HIV) are usually required for effective treatment of malacoplakia [3, 27].

Prognosis

Cutaneous malacoplakia usually presents as a benign self-limited condition that can undergo spontaneous regression, with a mean duration of skin lesions of 4-6 months [3, 10, 28]. Occasionally, the course of the disease may also be variable with frequent recurrences, local disfigurement, internal organ involvement, and significant morbidity associated with the chronicity of the condition and resistance to topical and systemic therapy [3, 10].

Conclusion

Cutaneous malacoplakia is a rare entity, with as many as 52 cases reported in the literature, and poorly

understood pathogenesis. Its rarity and non-specific appearance make it a challenging diagnosis. This chronic granulomatous disorder should be considered in the differential diagnosis of nodules, ulcers, and draining ulcers that are refractory to

treatment, particularly in immunocompromised patients.

Potential conflicts of interest

The authors declare no conflicts of interests.

References

1. Savant SR, Amladi ST, Kangle SD, Wadhwa SL, Nayak CS. Cutaneous malakoplakia in an HIV-positive patient. *Int J STD AIDS*. 2007; 18:435-6.[PMID: 17609043].
2. Yousef GM, Naghibi B, Hamodat MM. Malakoplakia outside the urinary tract. *Arch Pathol Lab Med*. 2007;131:297-300. [PMID:17284117].
3. Afonso JP, Ando PN, Padilha MH, Michalany NS, Porro AM. Cutaneous malakoplakia: case report and review. *An Bras Dermatol*. 2013;88:432-7. [PMID: 23793204].
4. James WD, Elston D, Berger T, Neuhaus I. Andrews' Diseases of the Skin, International Edition: Clinical Dermatology. 12th Edition.
5. Kohl SK, Hans CP. Cutaneous malakoplakia. *Arch Pathol Lab Med*. 2008;132:113-7.[PMID: 18181662].
6. Leclerc JL, Bernier L. Cutaneous malacoplakia. *Union Med Can*. 1972;101:471-3. [PMID: 5013466].
7. Rémond B, Dompmartin A, Moreau A, et al. Cutaneous malacoplakia. *Int J Dermatol*. 1994;33:538-42.[PMID: 7960344].
8. Coates M, Del Pero MM, Nassif R. A Case of Cutaneous Malakoplakia in the Head and Neck Region and Review of the Literature. *Head Neck Pathol*. 2016;10:444–450. [PMID:27154024].
9. Tulpule MS, Bharatia PR, Pradhan AM, Tawade YV. Cutaneous malakoplakia: Interesting case report and review of literature. *Indian J Dermatol Venereol Leprol*. 2017;83:584-6.[PMID: 28749381].
10. Shawaf AZ, Boushi LA, Douri TH. Perianal cutaneous malakoplakia in an immunocompetent patient. *Dermatol Online J*. 2010; 16:10. [PMID: 20137752].
11. Mehregan DR, Mehregan AH, Mehregan DA. Cutaneous malakoplakia: a report of two cases with the use of anti-BCG for the detection for micro-organisms. *J Am Acad Dermatol*. 2000;43:351-4. [PMID: 10901721].
12. Stanton MJ, Maxted W. Malacoplakia: a study of the literature and current concepts of pathogenesis, diagnosis and treatment. *J Urol*. 1981;125:139-46. [PMID: 7009885].
13. Debie B, Cosyns JP, Feyaerts A, et al. Malacoplakia in children. *Prog Urol*. 200515:511-3.[PMID: 16097160].
14. Lowitt MH, Kariniemi AL, Niemi KM, Kao GF. Cutaneous malacoplakia: a report of two cases and review of the literature. *J Am Acad Dermatol*. 1996;34:325–32.[PMID: 8655720].
15. Gidwani AL, Gidwani SA, Khan A, Carson JG. Concurrent Malakoplakia of Cervical Lymph Nodes and Prostatic Adenocarcinoma with Bony Metastasis: Case Report. *Ghana Med J*. 2006;40:151–153.[PMID: 17496990].
16. Chaudhry AP, Satchidanand SK, Anthoner R, Baumler RA, Gaeta JF. An unusual case of supraclavicular and colonic malakoplakia—a light and ultrastructural study. *J Pathol*. 1980;131:193–208. [PMID: 6253612].
17. Diapera MJ1, Lozon CL, Thompson LD. Malacoplakia of the tongue: a case report and clinicopathologic review of 6 cases. *Am J Otolaryngol*. 2009;30:101-5.[PMID: 19239951].
18. Davis D, Bigler L, Shimazu C, Omura E. Cutaneous malakoplakia. *J Cutan Pathol*. 1997;24:93.
19. Gliddon T, Proudmore K. Cutaneous Malakoplakia. *N Engl J Med*. 2019;380:580. [PMID: 30726684].
20. Sormes M, Siemann-Harms U, Brandner JM, Moll I. Cutaneous malakoplakia. *J Dtsch Dermatol Ges*. 2011;9:914-5. [PMID: 21899721].
21. Michaelis L, Gutmann C. Ueber Einschlüsse in Blasentumoren. *Ztschr Klin Med*. 1902;47:208–15.
22. Srivastava R, Aggarwal S, Arora VK. Cutaneous malakoplakia: Diagnosed cytologically. *Indian J Pathol Microbiol*. 2012;55:257-8. [PMID: 22771661].
23. Sarkell B, Dannenberg M, Blaylock WK, Patterson JW. Cutaneous malakoplakia. *J Am Acad Dermatol*. 1994;30:834–6.[PMID: 7513327].
24. Christensen M, Knuhtsen S, Knudsen E. Colonic malacoplakia treated with sulfamethizole and trimethoprim. *Ugeskr Laeger*. 2011;173:509-10.[PMID: 21320418].
25. Van der Voort HJ, Ten Velden JA, Wassenaar RP, Silberbusch J. Malacoplakia. Two case reports and a comparison of treatment modalities based on a literature review. *Arch Intern Med*. 1996;156:577–83.[PMID: 8604965].
26. Fudaba H, Ooba H, Abe T, et al. An adult case of cerebral malakoplakia successfully cured by treatment with antibiotics, bethanechol and ascorbic acid. *J Neurol Sci*. 2014;342:192-6.[PMID: 24863007].
27. Graves AL, Texler M, Manning L, Kulkarni H. Successful treatment of renal allograft and bladder malakoplakia with minimization of immunosuppression and prolonged antibiotic therapy. *Nephrology (Carlton)*. 2014;19:18-21.[PMID: 24460630].
28. Flann S, Norton J, Pembroke AC. Cutaneous malakoplakia in an abdominal skin fold. *J Am Acad Dermatol*. 2010;62:896-7. [PMID: 20398824].