



## A minimum three-year clinical and radiological follow up of the utilisation of a Cementless Multihole Mega cups in conversion hip arthroplasty – a prospective analysis

Mohamed NABIL, Ahmed MATTHANA, Mohamed A. IMAM

*From Orthopaedic Department, Suez Canal University Hospitals, Ismailia, Egypt*

The introduction of multihole mega cup has proposed innovative answers in the management of acetabular impediments that ensued from the use of bipolar hemiarthroplasty. This study bestows a prospective analysis of the outcome of conversion surgery from bipolar hemiarthroplasty to total hip replacement in patients with acetabular complications.

Forty-two patients, 22 men and 20 women, with a mean age of 59 years (range 46-69 years) who experienced complex acetabular deficiencies following bipolar hemiarthroplasty, were converted to total hip replacement between January 2008 and June 2010. Pain was the main complaint in all cases. It was primarily confined to the groin region. Limping due to shortening of the affected limb was the second main complaint (30 cases). All cases had erosion of the acetabulum with varying degrees of protrusion. Cementless multihole cups with augmentation by autogenous bone graft from the iliac crest and large metal heads' sizes were used for conversion in all cases.

After a minimum follow-up of 36 months, Harris hip scores (HHS) improved from a mean of  $36.8 \pm 6.8$  (range 21-59) preoperatively to a mean of  $85.9 \pm 5.6$  (range 71 to 94) postoperatively. Thirty six (85.7%) patients experienced no groin pain postoperatively while six patients (14.3%) described limited improvement. Postoperative complications included ; dislocation in two cases which were reduced and did not result in a poor outcome later on. No patients were lost to follow-up.

**Conclusion :** Short-term results at minimum three years follow-up of multihole mega cup were encouraging regarding high capability of acetabular

reconstruction with less morbidity of recipient site. Significant pain and functional improvement were noticeable, however further longer term studies are consequently recommended.

**Keywords :** conversion ; hemiarthroplasty ; total hip replacement ; Multihole mega cup.

### INTRODUCTION

Nowadays, the world has an aging population, causing tremendous pressure on healthcare budgets. Fractures of the neck of femur are increasingly common because of the increased level of activities carried out by the aging population. Consequently, Hip fractures related surgery is a common orthopaedic practice and is set to increase in the near future. In such a milieu, there is a global urge to recognize

- Mohamed Nabil, MD.
- Ahmed Matthana, MD.
- Mohamed A. Imam, MD.

*Orthopaedic Department, Suez Canal University Hospitals, Ismailia, Egypt.*

Correspondence : Mohamed A. Imam, Orthopedic department, faculty of medicine, Suez Canal University, Circular road, Ismailia, Egypt. E-mail : [Mohamed.imam@aol.com](mailto:Mohamed.imam@aol.com)

© 2015, Acta Orthopædica Belgica.

the patients for whom surgical intervention, for managing fractures of the neck of the femur, will provide most gain.

The ideal prosthesis for management of fractures of the neck of femur is controversial and its selection is multifactorial. Bipolar hemiarthroplasty (HA) is a frequently used option in management of those patients. The purported advantages of bipolar HA are dependent on the dual articulation concept. These include lower acetabular erosion, decreased morbidity and mortality rates, easy conversion to Total Hip Replacement (THR), and rapid restoration of pre-operative functional status are all claimed (2,3,15). Yet, recent studies have shown equal outcomes in regard to erosion and dislocation rates when compared to unipolar HA (23,27). The poor reported outcomes were mainly linked to acetabular cartilage loss, hip pain and acetabular protrusion. These may be attributed to failure of bearing surfaces leading to conversion of the bipolar mechanism into a monopolar one (5). Therefore, THRs has been vindicated, as a primary surgical preference, for active elderly patients sustaining femoral neck fractures (27,31).

Painful acetabular obliteration with protrusion, implant failure, peri-prosthetic fractures, femoral component loosening, dislocation, and sepsis are the common indications of HA conversion to THR. However, conversion of HA to THR was reported to be associated with higher complication rates and loosening (4,5,11,13,29).

We aim to report the minimum Three-year clinical and radiographic follow up of the multi-hole mega cup used in conversion of bipolar HA to THR.

## SUBJECTS AND METHODS

Between January 2008 and June 2010, fifty-one hips (51 patients) had a bipolar HA converted to a THR in our institution at three to eight years post implantation. Only forty two hips in 42 patients (Twenty-two males and twenty women) fulfilled our selection criteria of ; acetabular complications of bipolar HA, patients having Paprosky type 1, 2A and 2B acetabular defects (22) (Table I), stable well fixed femoral component, with no absolute medical contraindications to surgery, able and willing to provide informed consent and warranted compliance with radiographic and clinical follow-up post-

Table I. — Distribution of patients according to Paproski classification of acetabular defects

Acetabular defect	Number	Percentage
Paprosky type 1	18	42.9%
Paprosky type 2A	15	35.7%
Paprosky type 2B	9	21.4%

surgery. Patients with neuromuscular compromise in the symptomatic extremity, dementia or have history of substance misuse were excluded. Moreover, patients with thigh pain and radiological signs of stem loosening were excluded.

The mean age of our cohort of patients was 59 years (range 46-69 years). Preoperative assessment was elaborated according to a standardized local regimen of investigations in our institution. Full history was recorded including the main complaint, onset and duration of symptoms, and aggravating and relieving factors. All patients had groin pain as the main complaint ; with thirty patients (71.4%) had limping as a result of shortening of affected limb. All patients were invited to complete a Harris Hip score (HHS) prior to surgery and at yearly intervals, by either postal review or in our follow-up clinics. Clinical and radiological review was undertaken in our dedicated arthroplasty clinics. In addition we have recorded the incidence of complications such as post-operative dislocation, wound infection, and heterotopic ossification. The bearing surfaces used in all cases were Metal on high cross-linked polyethylene liner in cementless dual coated multihole mega cup.

The study was carried out in Suez Canal University Hospitals. A 36-month post-operative follow-up period for each patient was initially envisaged. The study received approval by the Research Ethics Board at our institution.

## Operative technique

All procedures were carried out under combined spinal and epidural anesthesia. Through a direct lateral approach (42 hips-100%) to the hip in lateral decubitus position, using previous surgical skin incision, if possible. A standard operative technique was used in all cases. That involved, initially dislocating the bipolar prosthesis followed by removal of the head of prosthesis. The acetabular floor condition was subsequently evaluated, for assessing the magnitude of protrusion and bony defects. Successively, the acetabulum is reamed and a trial of the cup is applied (measuring 2 mm larger size the last



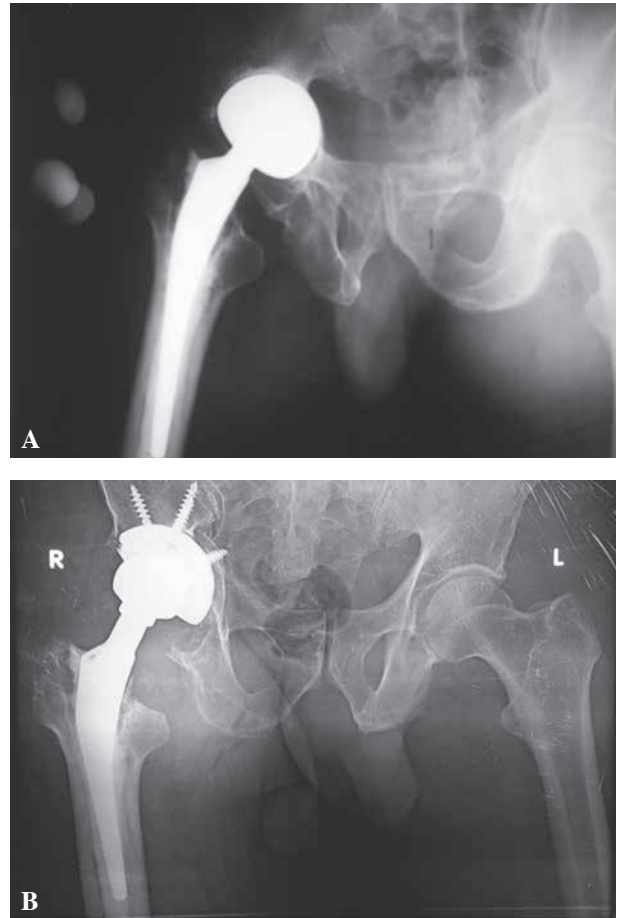
**Fig. 1.** — Gription Multihole Mega Cup

reamer used). Augmentation of the acetabular bony defects was achieved using cancellous autogenous iliac bone graft. Mincing of the graft was accomplished by reverse reaming, trailed by introduction of the Multi-hole mega Gription (Fig. 1) porous coated cups (Depuy J&J, USA) in the best position ; maintaining the inclination and anteversion angles.

Securing the cup into position with 2-4 screws was done in all cases (Fig. 2). Perioperative intravenous antibiotic treatment was routinely administered, and prophylaxis against venous thromboembolism using low molecular heparin applied for all patients. We started physiotherapy including passive range of motion and assisted active exercises as early as the patient is comfortable. The same protocol was followed in all cases, with some individual modifications.

#### *Radiographic evaluation*

Two independent experienced observers reviewed post-operative antero-posterior radiographs of the pelvis and lateral radiographs of the hip. Only patients with at least two post-operative x-rays, one of them is, at least, three years post surgery, were included. X-rays were available for all patients. The postoperative radiographs were evaluated immediately after surgery, 12, 24 and 36 months postoperatively. The parameters recorded were cup inclination angle and incorporation of cup into



**Fig. 2.** — 61 years old patient, A. seven years post surgery ; B. Bipolar HA converted to THR on the right side.

the acetabulum. Incidence of heterotopic ossification at any point during follow-up was recorded and classified as described by Brooker's classification (6). Radiological evaluation of the graft incorporation was determined as matched radio-density of both the graft and the recipient bone together with the presence of evidence of continuity of trabecular bone pattern throughout this site according to the method described by Slooff *et al* (30). Two independent observers evaluated the radiographs for signs of incorporation with no interobserver variability was recorded for the measurement parameters used to assess the incorporation of the graft.

#### *Postoperative follow-up*

The patients had regular follow-up visits for clinical and radiographic evaluations as needed in the first six months, and then at one, two and three years time points,

post surgery. Harris Hip Score (HHS) was recorded at 36 months postoperatively. Our selected group of patients was type 1, 2A and 2B defects, as per Paprosky classification of acetabular defects (22). All patients were admitted to the hospital preoperatively for clinical assessment and laboratory investigations. Written consents were taken for all patients confirming about the operation and data publishing. None of our patients were lost to follow-up.

### Statistical Methods

The analysis examined the HHS over the course of follow up. Not all follow-ups were performed at exact yearly intervals. Summaries of the baseline HHS and at each follow-up year were made. Survival analysis was performed using Graph Pad Prism statistical software version 5.0 for Windows (Graph Pad Software Inc., San Diego, California). The survival rate was calculated using Kaplan-Meier survival curves with 95% confidence intervals (CI). P values less than 0.05 was considered statistically significant.

## RESULTS

The indication for surgery was groin pain in all patients (100%) and accompanied by limping due to shortening of the limb in 30 patients (71.5%). A preoperative diagnosis of acetabular erosion and protrusio was made in 42 patients (100%). Mean preoperative HHS was  $36.8 \pm 6.8$  (range 21-59). A mean shortening of  $2.5 \pm 0.7$  cm (range 1-4 cm) was recorded preoperatively. Acetabular deficiency was seen in all hips (Table I), and was managed with autograft taken from ipsilateral iliac crest and minced in the acetabulum with reverse acetabular reamer. The cup sizes used ranged from 52-66 with a mean of  $59.7 \pm 3.1$  and a median of 60.

### Early postoperative complications (Table II)

Superficial infection occurred in six hips (14.2%) and all cases responded to local wound care and specific antibiotics given according to culture and sensitivity tests. None of those 6 hips required second surgery. Dislocation occurred in two hips on the second and third postoperative day, respectively, which was reduced by closed reduction under

Table II. — Postoperative complications

Type of complication	Number	Percentage
Superficial wound infection	6	14.3%
Dislocation	2	4.8%
Heterotopic calcification	6	14.3%

anesthesia. The affected hip was guarded with an abduction brace for three months and there was no recurrence thereafter. No death was encountered in our study group that could be directly attributed to the surgery or its complications.

### Clinical follow-up

Clinical and functional results in the group improved significantly at minimum three years follow-up. The mean Harris hip scores improved from  $36.8 \pm 6.8$  (range 21-59) preoperatively to  $85.9 \pm 5.6$  (range 71 to 94) at 36 months postoperatively, with a mean difference of  $49.1 \pm 9.0$  (p-value < 0.001). Thirty-six patients (85.7%) showed no hip pain at the end of the study and only six patients (14.3%) reported only partial improvement. Postoperative residual limb length discrepancy ranged from 0-1 cm, with a mean of  $0.32 \pm 0.41$  with a mean difference of  $2.1 \pm 0.5$ , which was highly significant (p-value < 0.0001). The mean acetabular cup inclination angle was  $45.7 \pm 2.6$  degrees (range 42-52 degrees). Incorporation of autograft was noticed in all patients at the end of three years (Fig. 1). Only six patients (14.3%) showed radiological evidence of heterotopic ossification of the studied group, two only (4.7%) had grade 2 or more heterotopic ossification. None of the hips in our cohort were revised at minimum three years (Range 3-6).

## DISCUSSION

We report very good results of the 42 bipolar HA converted to THR. Our study showed excellent (100%) survivorship at a minimum 3 years follow-up. One limitation of the current study is the fact that we have not studied joint range of movement or investigated whether there is any difference in this metric when converted hips are compared with primary THRs. Another limitation is the relatively

short follow-up period, however, we are planning to conduct a long term follow-up study aiming at clinical and radiological follow up for this cohort of patients.

Bipolar HA of the hip is a frequently performed procedure for the management of displaced intra-articular fractures of the neck of the femur in the elderly (9,24). Nonetheless, problems of groin pain and limping after mutable periods of having bipolar HA, chiefly because of acetabular erosions and protrusion, dictating conversion to THR with acetabular reconstruction.

Acetabular defects are a challenge during THR conversion surgery, essentially because the bone stock has to be reconstructed and a load-stable fixation of the cup is a requisite. Various surgical procedures have been described (10,28). This implies that acetabular defects may frequently not be reconstructed using standard techniques. The preferred surgical technique depends, mainly, on the individual proficiency of the surgeon. Some authors recommend a defect-oriented stage-suitable reconstruction of the acetabular defects (19).

There are some advantages of the technique used in this cohort of patients. The cup used is manufactured of titanium with a gradient porosity so as to maintain mechanical integrity under increased forces and loads. Multihole mega cup augments yields to an effective mechanical loading environment for bone ingrowth reconstruction, enabling better cell adhesion and proliferation. This design allows the surgeon to apply screws in the intact areas of good bone stock whatever the morphology of defects that was present (17).

The use of large cups for acetabular revision has various advantages. Those include preparing the acetabulum by reaming to a large hemisphere, a method that is technically straightforward. Moreover, most bone deficiencies are filled by the socket itself, thereby obviating the need for extensive bone-grafting. Also in large cups, there is bigger contact area between the implant and the host bone with the centre of hip rotation is translated to a more lateral and inferior position, allowing restoration of hip biomechanics closer to normal. Acetabular reconstruction in conversion THR can be achieved with dual-coated (porous and hydroxyapatite) multi-hole mega

cups. This dual coating promotes osteointegration and osteoconductive properties. Also, the large cup permits complete coverage of the acetabular socket and the use of large head, which favors reducing the risk of dislocation. These metals have characteristics resembling those of cancellous bone, with increased surface friction characteristics and relatively low moduli of elasticity, thus potentially providing a surface that will result in a long-lasting bond and substantial levels of bone ingrowth (16, 18). The purported advantage of the three-dimensional fixation is maximizing the initial stability, subsequently leading to long-term biologic fixation (18).

However, Tantalum coated cups and augments were not an available option in our institute due to financial issues. Consequently, our concern was directed toward solving this substantial acetabular problem with an available, more biologic, and economic option. To the best of our knowledge, review of literature revealed shortage of the available data concerned with the assessment of the results of combination of autograft with this type of cementless cups. As a result of that, the application of this combined technique was sufficiently attractive to investigate about especially in this selected age group of patient with pore bone stock quality and concomitant osteoporosis.

We have included in our study patients with Paprosky type 1, 2A and 2B acetabular defects for conversion to THR with the use of dual-coated multi-hole mega cups in the acetabulum after filling the defects with autogenous iliac bone graft.

In the literature, dislocation is a significant problem with a dislocation rate of 12% seen with the use of mega cups (32). A dislocation rate of 20% was reported in one series when only the acetabular component was revised (17). The high dislocation rate in isolated acetabular revisions is multifactorial, and may be influenced by the exposure and soft tissue laxity, component alignment, restoration of offset, liner type (neutral versus lipped) and head diameter. It remains to be seen whether the use of large diameter heads in conversion surgery will reduce the rate of this complication (12).

In our study, the dislocation rate was 4.76% (two out of 42 cases) and this can be explained by the use

of large heads (36, 40 mm), which offer more stability, and by the appropriate inclination angle of the cup. Autogenous bone graft, although, providing optimal osteoconductive and osteogenic properties (7), its use for large defects is limited due to its availability. Furthermore, the harvesting of autogenous bone graft is accompanied by a relatively high rate of complications including hematoma, iatrogenic nerve lesions and infections (26).

In our study, the use of autogenous bone graft from the iliac crest was quite sufficient and suitable as the study included only patients having Paprosky type 1, 2A and 2B acetabular defects. We had superficial infection rate of 14.28% (6 out of 42 cases), which responded well to frequent dressing and proper antibiotic therapy.

The shortening of lower limb in our study group changed from  $2.5 \pm 0.7$  to  $0.32 \pm 0.41$  postoperatively ( $p < 0.0001$ ). This could be attributed to the usage of larger head sizes with variable neck length and bone graft to fill the acetabular defects together with the use of mega cup to restore the normal hip center. All these factors contributed to the significant restoration of limb length equality to nearly normal. These results are comparable to those reported by others (1,14,25).

In our study, the HHS showed a highly significant improvement at two years in 42 THRs converted from Bipolar HA. These results were like the reported results of similar studies (8,22,23). We can conclude that short-term results of multihole mega cup were encouraging regarding high capability of acetabular reconstruction with less morbidity of recipient site. Significant pain and functional improvement were noticeable, however further longer term studies are therefore recommended.

#### Acknowledgments

We would like to thank Ahmed Maaty for running statistical analysis for this study. No benefits in any form have been received or will be received from a commercial party related directly or indirectly to the subject of this article.

## REFERENCES

1. Anthony BM, Andrew JG, Philip JO, Anthony CR, Todd DS, Martin HS. A review of symptomatic leg length inequality following total hip arthroplasty. *Hip Int* 2013 ; 23 : 6-14.
2. Bhandari M, Devereaux PJ, Swiontkowski MF *et al.* Internal fixation compared with arthroplasty for displaced fractures of the femoral neck. A meta-analysis. *J Bone Joint Surg Am* 2003 ; 85 : 1673-81.
3. Bhandari M, Devereaux PJ, Tornetta P *et al.* Operative management of displaced femoral neck fractures in elderly patients. An international survey. *J Bone Joint Surg Am* 2005 ; 87 : 2122-30.
4. Bilgen O, Karaeminogullari O, Kulecioglu A. Results of conversion total hip prosthesis performed following painful hemiarthroplasty. *J Int Med Res* 2000 ; 28 : 307-12.
5. Blomfeldt R, Tornkvist H, Eriksson K, Soderqvist A, Ponzer S, Tidermark J. A randomized controlled trial comparing bipolar hemiarthroplasty with total hip replacement for displaced intracapsular fractures of the femoral neck in elderly patients. *J Bone Joint Surg Br* 2007 ; 89 : 160-5.
6. Brooker AF, Bowerman JW, Robinson RA, Riley LH Jr. Ectopic ossification following total hip replacement : Incidence and a method of classification. *J Bone Joint Surg Am* 1973 ; 55 : 1629-32.
7. Cypher TJ, Grossman JP. Biological principles of bone graft healing. *J Foot Ankle Surg* 1996 ; 35 : 413-7.
8. Dearborn JT, Harris WH. Acetabular revision arthroplasty using the so-called jumbo cementless components : an average 7-year follow-up study. *J Arthroplasty* 2000 ; 15 : 8-15.
9. Dorr LD, Glousman R, Hoy AL, Vanis R, Chandler R. Treatment of femoral neck fractures with total hip replacement versus cemented and noncemented hemiarthroplasty. *J Arthroplasty* 1986 ; 1 : 21-8.
10. Eggl S, Muller C, Ganz R. Revision surgery in pelvic discontinuity : an analysis of seven patients. *Clin Orthop Relat Res* 2002 ; 398 : 136-45.
11. Elke R, Wagner A, Berli B, Morscher E. [Acetabulum revision. Classifications and treatment possibilities]. [Article in German]. *Orthopade* 2001 ; 30 : 266-72.
12. Fernandez-Fairen M, Murcia A, Blanco A, Merono A, Murcia JA, Ballester J. Revision of failed total hip arthroplasty acetabular cups to porous tantalum components : a 5-year follow-up study. *J Arthroplasty* 2010 ; 25 : 865-72.
13. Hammad A, Abdel-Aal A. Conversion total hip arthroplasty : Functional outcome in Egyptian population. *Acta Orthop Belg* 2006 ; 72 : 549-54.
14. Hofmann AA, Bolognesi M, Lahav A, Kurtin S. Minimizing leg-length inequality in total hip arthroplasty : use of preoperative templating and an intraoperative x-ray. *Am J Orthop (Belle Mead N J)* 2008 ; 37 : 18-23.
15. Hopley C, Stengel D, Ekkernkamp A, Wich M. Primary total hip arthroplasty versus hemiarthroplasty for displaced intracapsular hip fractures in older patients : systematic review. *BMJ* 2010 ; 340 : c2332.
16. Jasty M, Bragdon C, Burke D, O'Connor D, Lowenstein J, Harris WH. In vivo skeletal responses to porous-surfaced implants subjected to small induced

- motions. *J Bone Joint Surg Am* 1997 ; 79 : 707-14.
17. **Jones CP, Lachiewicz PF.** Factors influencing the longer term survival of uncemented acetabular components used in total hip revisions. *J Bone Joint Surg Am* 2004 ; 86 : 342-7.
  18. **Karageorgiou V, Kaplan D.** Porosity of 3D biomaterial scaffolds and osteogenesis. *Biomaterials* 2005 Sep ; 26 : 5474-91.
  19. **Kruger T, Reichel H, Grubitzsch U, Hein W.** [Etiology of early loosening after aseptic cup replacement using allogenic bone blocks and cement-free press-fit cups]. *Z Orthop Ihre Grenzgeb* [Article in German]. 2000 ; 138 : 209-14.
  20. **Niedhart C, Pingsmann A, Jurgens C, Marr A, Blatt R, Niethard FU.** [Complications after harvesting of autologous bone from the ventral and dorsal iliac crest – a prospective, controlled study]. [Article in German]. *Z Orthop Ihre Grenzgeb* 2003 ; 141 : 81-6.
  21. **Ong BC, Maurer SG, Aharonoff GB, Zuckerman JD, Koval KJ.** Unipolar versus bipolar hemiarthroplasty : functional outcome after femoral neck fracture at a minimum of thirty-six months of follow-up. *J Orthop Trauma* 2002 ; 16 : 317-22.
  22. **Paprosky WG, Perona PG, Lawrence JM.** Acetabular defect classification and surgical reconstruction in revision arthroplasty. A 6-year follow-up evaluation. *J Arthroplasty* 1994 ; 9 : 33-44.
  23. **Patel JV, Masonis JL, Bourne RB, Rorabeck CH.** The fate of cementless jumbo cups in revision hip arthroplasty. *J Arthroplasty* 2003 ; 18 : 129-33.
  24. **Pellegrini VD Jr, Heiges BA, Bixler B, Lehman EB, Davis CM 3rd.** Minimum ten-year results of primary bipolar hip arthroplasty for degenerative arthritis of the hip. *J Bone Joint Surg Am* 2006 ; 88 : 1817-25.
  25. **Plaass C, Clauss M, Ochsner AE, Ilchmann T.** Influence of leg length discrepancy on clinical results after total hip arthroplasty-a prospective clinical trial. *Hip Int* 2011 ; 21 : 441-9.
  26. **Raia FJ, Chapman CB, Herrera MF, Schweppe MW, Michelsen CB, Rosenwasser MP.** Unipolar or bipolar hemiarthroplasty for femoral neck fractures in the elderly ? *Clin Orthop Relat Res* 2003 ; 414 : 259-65.
  27. **Rogmark C, Johnell O.** Primary arthroplasty is better than internal fixation of displaced femoral neck fractures : a meta-analysis of 14 randomized studies with 2289 patients. *Acta Orthop* 2006 ; 77 : 359-67.
  28. **Sharkey PF, Rao R, Hozack WJ, Rothman RH, Carey C.** Conversion of hemiarthroplasty to total hip arthroplasty : Can groin pain be eliminated ? *J Arthroplasty* 1998 ; 13 : 627-30.
  29. **Sierra RJ, Cabanela ME.** Conversion of failed hip hemiarthroplasties after femoral neck fractures. *Clin Orthop Relat Res* 2002 ; 399 : 129-39.
  30. **Slooff TJ, Buma P, Schreurs BW, Schimmel JW, Huiskes R, Gardeniers J.** Acetabular and femoral reconstruction with impacted graft and cement. *Clin Orthop Relat Res* 1996 ; 324 : 108-15.
  31. **Squires B, Bannister G.** Displaced intracapsular neck of femur fracture in mobile independent patients : Total hip replacement or hemiarthroplasty. *Injury* 1999 ; 30 : 345-8.
  32. **Whaley AL, Berry DJ, Harmsen WS.** Extra-large uncemented hemispherical acetabular components for revision total hip arthroplasty. *J Bone Joint Surg Am* 2001 ; 83 : 1352-7.