



EUROPEAN COLORECTAL CONGRESS

# Spotlight on the colon

1 – 5 December 2019, St.Gallen, Switzerland

Spotlight on the colon

Inflammatory bowel diseases (IBD)

Robotics in colorectal surgery

New technologies

Lars Pählman lecture

EAES Presidential lecture

Masterclass in colorectal surgery

Information & Registration

[www.colorectalsurgery.eu](http://www.colorectalsurgery.eu)

The publication of this advertisement does not constitute endorsement by the society, publisher, or Editors, and is unrelated to the content that follows



MR MOHAMED ALY (Orcid ID : 0000-0001-6305-2789)  
MR ADAM STEARNS (Orcid ID : 0000-0003-4327-7360)

Article type : Systematic Review

# Does intra-operative flexible endoscopy reduce anastomotic complications following left-sided colonic resections?

A systematic review and meta-analysis

Mohamed Aly MBBCh MRCS<sup>1,3</sup>, James W O'Brien MBBS MRCS<sup>1,3</sup>, Florence Clark MBBS<sup>1,3</sup>, Sandeep Kapur FRCSI<sup>1,2,3</sup>, Adam T Stearns DPhil FRCS<sup>1,2,3</sup>, Irshad Shaikh MD FRCS<sup>1,2,3</sup>

[1] Department of Colorectal Surgery, Norfolk & Norwich University Hospitals NHS Foundation Trust, Colney Lane, Norwich. NR4 7UY.

[2] Norwich Medical School, University of East Anglia, Norwich, Norfolk.

[3] Norwich Surgical Training and Research Academy, Level 3 Centre, Norfolk & Norwich University Hospital, Colney Lane, Norwich. NR4 7UY

Corresponding author  
Mohamed Aly  
m.aly@nhs.net

## Abstract

### Introduction

Post-operative anastomotic leakage (AL) or bleeding (AB) significantly impacts on patient outcome following colorectal resection. To minimise such complications, surgeons can utilise different techniques perioperatively to assess anastomotic integrity. We aim to assess published anastomotic complication rates following left-sided colonic resection, comparing use of intra-operative flexible endoscopy against conventional tests used to assess anastomotic integrity.

This article has been accepted for publication and undergone full peer review but has not been through the copyediting, typesetting, pagination and proofreading process, which may lead to differences between this version and the Version of Record. Please cite this article as doi: 10.1111/codi.14740

This article is protected by copyright. All rights reserved.

## Methods

PubMed/MEDLINE and EMBASE online databases were searched for non-randomised and randomised case-control studies that investigated post-operative AL and/or AB rates in left-sided colonic resections, comparing intra-operative flexible endoscopy against conventional tests. Data from eligible studies were pooled, and a meta-analysis using Review Manager 5.3 software was performed to assess for difference in AL and AB rates.

## Results

Data from six studies were analysed to assess the impact of flexible endoscopy on post-operative AL and AB rates (1084 and 751 patients respectively). Use of flexible endoscopy was associated with reduced post-operative AL and AB rates, from 6.9% to 3.5% and 5.8% to 2.4% respectively. OR favoured intra-operative flexible endoscopy; 0.37 (95% CI 0.21-0.68,  $p=0.001$ ) for AL and 0.35 (95% CI: 0.15-0.82,  $p=0.02$ ) for AB.

## Conclusion

This meta-analysis showed that the use of intra-operative flexible endoscopy is associated with a reduced rate of post-operative anastomotic leakage and bleeding, compared to conventional anastomotic testing methods.

### **What does this paper add to the literature?**

Most colorectal surgeons will perform some form of assessment of anastomotic integrity, although the evidence for this is lacking. Intraoperative flexible endoscopy has potential advantages with direct visualisation of the anastomosis, but requires

additional equipment and expertise. This meta-analysis shows that intra-operative endoscopy is associated with reduced anastomotic leak and bleeding rates in comparison with conventional anastomotic testing methods.

## **Introduction**

Post-operative anastomotic complications, particularly anastomotic leakage or bleeding, severely impact upon patient outcome following colorectal resection(1).

Anastomotic leakage is the most serious complication and increases morbidity and mortality, length of stay, re-admission rates and treatment costs(2, 3). Anastomotic leakage may reduce disease-free survival following colorectal cancer resections, (4-6). The reported incidence of anastomotic leakage is from 1% to 30%(7), and is affected by multiple risk factors(8). Anastomotic bleeding has been reported to occur in 6% of patients following left-sided colonic resections. Though patients can be managed conservatively, some will require re-intervention with endoscopy, interventional radiology or surgery with significantly increased morbidity and mortality(9, 10).

Multiple factors affect anastomotic integrity and can be broadly classified into patient or technical factors. Patient factors include body habitus, low serum albumin, smoking, diabetes mellitus, pre-operative leucocytosis, high American Society of Anaesthesiologists (ASA) grade, tumour location, intra-abdominal sepsis, post-operative blood transfusion and emergency presentation. Technical factors include tension along the anastomosis, impaired anastomotic blood supply, twisting or kinking of the bowel or poor mucosal apposition(11, 12). Great care is taken to mitigate these factors where possible, in order to avert anastomotic leakage following left-sided colonic or rectal resections(13).

Surgeons demonstrate poor intra-operative subjective assessment of anastomotic integrity(14), so on table “anastomotic leak tests” are frequently utilised(7). Intra-operative assessment of anastomotic integrity has been shown to confer a benefit in reducing post-operative anastomotic complications(15). Air insufflation tests (or modifications using dye) are the most commonly used method of assessing anastomotic structural integrity(16-19). As circular staplers are now often used to perform bowel anastomosis, inspecting the circular tissue remnants or “doughnuts” for completeness can indicate appropriate tissue apposition and predict anastomotic integrity(20). Such conventional anastomotic tests are simple, safe, and when anastomotic leak is detected, action can be taken to reduce patient morbidity and mortality, for example through formation of a proximal loop ileostomy(21, 22).

Previous studies have compared conventional testing of the anastomosis against control groups undergoing no testing at all, and shown no discernible difference in post-operative AL rate. Furthermore, patients without an overt AL during intra-operative conventional testing are still at risk of developing AL in the post-operative period (23, 24).

Numerous studies report the successful reduction of anastomotic complication rates following use of intra-operative flexible endoscopy (FE) for anastomotic assessment. Reported leak rates were 0.9-2.1% after routine use(25-28). Flexible endoscopy offers a more comprehensive platform for anastomotic assessment through air insufflation and anastomotic inspection for mucosal malalignment(29, 30). This technique can also include assessment and treatment of anastomotic bleeding, which conventional techniques cannot detect. The use of intra-operative FE in anastomotic assessment was reported three decades ago(31), and requires



additional cost (equipment and maintenance), expertise (endoscopists and theatre staff) and time(32). The resource-intensive nature of FE might be justifiable, if it improves patient outcome more than the considerably cheaper conventional methods.

By performing a systematic review and meta-analysis, we compare intra-operative flexible endoscopy against conventional anastomotic testing and the subsequent post-operative anastomotic complication rate, for patients undergoing left-sided colonic resection.

## **Methods**

### Search strategy

PubMed/MEDLINE and EMBASE online databases were searched for all relevant publications on the 8<sup>th</sup> May 2018 and repeated on the 8<sup>th</sup> August 2018 using combinations of the following Medical Search Headings (MeSH) and their subheadings:

1. PubMed/Medline: “endoscopy” OR “gastrointestinal” AND “anastomosis” OR “surgical”.
2. EMBASE: (“sigmoidoscopy” OR “rectoscopy” OR “colonoscopy”) AND “anastomosis”

EMBASE free text search using (“intraoperative” OR “intra-operative”) AND (“sigmoidoscopy” OR “colonoscopy”) AND (“anastomosis” OR “anastomotic”) was also performed. Search results were catalogued and deduplicated in Mendeley Desktop 1.19.1 citation management software, into which all other relevant studies were added.

### Inclusion criteria

Relevant non-randomised and randomised case-control studies that investigated post-operative anastomotic leakage and/or anastomotic bleeding rates in left-sided colonic resections, comparing intra-operative flexible endoscopy and conventional anastomotic tests were included. References from those studies were examined and any relevant articles included.

### Exclusion criteria

Conference abstracts, uncontrolled case series, letters, invited comments and case reports were excluded. Furthermore, case-control studies were excluded when leak testing in the endoscopy cohort was performed with rigid sigmoidoscopy, as this methodology lacks consistent visual inspection of the anastomotic line. Inclusion would not be appropriate, as studies used in this meta-analysis undertook mucosal inspection with the flexible sigmoidoscope or colonoscope in addition to an air leak test. Furthermore, flexible endoscopy is more sensitive than rigid endoscopy in spotting abnormalities(33). Case-control studies with unclear control selection criteria were also excluded.

### Study selection

Three reviewers (MA, JO, FC) independently performed the searches, screening the titles and abstracts for relevance. Differences were discussed between two authors (MA, JO) and senior authors (ATS, IS). Full text articles were retrieved and included if exclusion and inclusion criteria were met.

## Definitions

Flexible endoscopy was defined as intraoperative, white light, fiberoptic sigmoidoscopy or colonoscopy used primarily to assess anastomotic integrity using direct mucosal inspection and air insufflation. Anastomotic leakage was defined as a defect of the intestinal wall at the anastomotic site (including suture and staple lines of neorectal reservoirs) leading to a communication between the intra- and extraluminal compartments, as defined by the International Study Group of Rectal Cancer Surgery(34). Anastomotic bleeding was defined as any significant identifiable rectal bleeding that occurs within 24 hours of resection, regardless of treatment. Conventional anastomotic tests are non-endoscopic, mechanical patency tests such as an air leak test, dye test, or inspection of circular stapler tissue remnants (“doughnuts”), as listed by Nachiappan et al.(15) (Table 1).

## Primary outcomes

The primary outcome measure was post-operative anastomotic leakage and bleeding rate following left-sided colonic resection.

## Quality assessment

Included studies were quality assessed by two authors (MA, JO) using the Critical Appraisal Skills Programme (2018) Case Control Study Checklist (CASP).

## Statistical analysis

A meta-analysis was performed using Review Manager (RevMan) software [Computer program], version 5.3, Copenhagen: the Nordic Cochrane Centre, the Cochrane Collaboration, 2014.  $I^2$  was calculated to assess study heterogeneity(35).



Funnel plots were used to assess publication bias. Data were pooled to calculate odds ratio (OR) and confidence intervals (CI) for the post-operative incidence of anastomotic leakage or bleeding, with or without intra-operative flexible endoscopy.

## Results

The search strategy identified 4690 titles. After examining 83 full-texts, six studies were included in the meta-analysis as per the PRISMA diagram (Figure 1)(36). The included studies were published between 1987 and 2013. All six studies were retrospective case-control studies or retrospective analysis of prospectively collected data, and no randomised trials were identified(30, 31, 37-40). Five studies reported post-operative AL (1084 patients)(30, 31, 37-39), and three studies reported anastomotic bleeding (751 patients)(30, 38, 40).

### Use of intra-operative flexible endoscopy and post-operative anastomotic leak rate

Five non-randomised case control studies reported AL rates in a total of 1084 patients after open or laparoscopic left-sided colonic resections with primary stapled anastomosis, with or without flexible endoscopy (table 1). In the flexible endoscopy cohort, 25/464 (2.3%) patients had positive intra-operative leak tests and required additional sutures (n=14), covering stoma (n=12) or the anastomosis refashioned (n=1). None of these patients developed post-operative AL. 439/464 patients (94.6%) in the flexible endoscopy cohort had negative intra-operative leak tests.

From this group, 16 patients (3.6%) developed post-operative AL. In the control cohort, using conventional anastomotic tests, only two studies reported two patients to have a positive leak test, 2/468 patients (Figure 2). The overall AL rate in the flexible endoscopy cohort was 3.5% (16/464) compared to 6.9% (43/620) in the

control cohort using conventional tests. After pooling patient data, calculated odds ratio (OR) for anastomotic leakage was 0.37 (95% CI 0.21-0.68,  $p=0.001$ ), suggesting flexible endoscopy has a protective role against post-operative AL.  $I^2$  was reported as 0% (Figure 3).

#### Use of intra-operative flexible endoscopy and post-operative anastomotic bleeding rate

Three studies reported AB rates in a total of 751 patients. 19/292 (6.5%) demonstrated active bleeding from the staple line during intra-operative endoscopy and were treated with clipping ( $n=15$ ) or cautery ( $n=3$ ). From this group, three patients developed post-operative AB. Overall the post-operative AB rate in the flexible endoscopy cohort was 2.4% (7/292), compared to 5.8% (26/449) in the control cohort. Pooled OR was 0.35 (95% CI: 0.15-0.82,  $p=0.02$ ), suggesting flexible endoscopy has a protective role against post-operative AB.  $I^2$  was reported as 0% (Figure 4).

#### CASP quality assessment

The included studies were assessed for quality using the CASP checklist for case-control studies (Table 1). All studies focused on the impact of flexible endoscopy on reducing post-operative complications, except Sakanoue et al.(31) , which was an earlier publication demonstrating the use of intra-operative colonoscopy. Lieto et al.(38) and Shamiyeh et al.(30) introduced intra-operative FE on a routine basis which raises concerns for selection bias when comparing the reported leak rate to other studies. None of the control groups were randomised, and only Sakanoue et

al.(31) and Yang et al.(39) performed a matched comparison with reported comparable criteria. Yang et al.(39) performed a defunctioning ileostomy for almost 25% of the intra-operative FE group, and reported a significantly lower AL rate. The small cohort sizes in all included studies meant few of the authors could perform robust statistical analysis and hindered application of the results of each study to the wider patient population. Funnel plots were created to assess bias between the included studies (Figure 5).

## **Discussion**

Anastomotic complications can result in mortality, severe morbidity, affect long term quality of life and can hamper the patient-doctor relationship(41). Large cohort studies suggest intra-operative assessment of anastomotic integrity is important.

Allaix et al.(42) report a large retrospective study of prospectively collected data for 777 patients who underwent left-sided colonic and colorectal resections. Patients were classified depending on whether a conventional intra-operative air leak test was performed. Air leak tests were performed routinely by two authors or selectively by the other two authors if there was intra-operative concern for AL. Both patient groups had comparable complication rates, but there was a shorter length of stay for the air leak test cohort. Allaix et al.(42) demonstrated that intra-operative testing allowed surgeons to adequately address AL. Their multivariate analysis showed the intra-operative air-leak test was an independent factor to reduce clinically-relevant AL.

This large case-control study emphasised the importance of intra-operative testing of anastomotic integrity.

Six studies were identified for this meta-analysis: Sakanoue et al.(31) compared post-operative AL rates following intra-operative FE or conventional air leak test in open low anterior resections for rectal carcinoma with a matched, untested cohort. In the FE group, 2/35 (5.7%) patients demonstrated intra-operative AL and required reinforcement of the anastomosis with sutures and the creation of a defunctioning proximal stoma. No patients developed post-operative AL in the FE cohort, while 4/35 (11.4%) patients developed post-operative AL in the control cohort.

Lieto et al.(38) compared anastomotic complication rates following routine intra-operative FE against inspection of circular stapler tissue remnants (doughnut check) in open total gastrectomy and left colorectal resection. In the FE cohort 8/56 (14.2%) demonstrated intra-operative AL, and the anastomosis was oversewn, while 2/56 (3.6%) demonstrated AB, which was managed with compression or additional sutures. Post-operative AL rates were 2/56 (3.6%) and 7/68 (10.3%) in the FE and control cohort, respectively. No post-operative AB was reported in the FE cohort, compared to 2/68 (2.9%) in the control cohort.

Shamiyeh et al.(30) reported anastomotic complication rates following routine FE or conventional testing methods, during laparoscopic left-sided colonic resections. In the FE group, intra-operative AL was detected in 2/85 (2.4%) and the anastomoses were oversewn or revised, while 5/85 (5.9%) developed intra-operative AB which was managed with endoscopic clips. Post-operative AL occurred in 1/85 (1.2%), while 2/85 (2.4%) developed post-operative AB, despite normal intra-operative FE. In the control group, 4/253 (1.6%) and 11/253 (4.3%) developed post-operative AL and AB, respectively.

Lanthaler et al.(37) report post-operative AL rates following laparoscopically-assisted left sided colonic resections, with selective intra-operative colonoscopy or routine air insufflation. In the FE group, AL was detected in 5/73 (6.8%) and the leak was oversewn in all cases. 6/73 (8.2%) developed post-operative AL, including one anastomosis previously detected and repaired intra-operatively after endoscopic testing. In the control group 2/49 (4.1%) developed post-operative AL.

Yang et al.(39) compared AL rates following low anterior resection with intra-operative FE or air insufflation. In the FE cohort, 10/215 (4.7%) patients demonstrated intra-operative AL and underwent defunctioning ileostomy. None of the 10 patients had post-operative AL. In the matched control cohort, air insufflation was positive in 2/215 (0.9%) patients. Both patients were also managed with a defunctioning ileostomy. Post-operative AL rates were 9/215 (4.2%) and 25/215 (11.6%) in the FE and control cohorts, respectively. It should be noted that 50 (23.3%) patients in the FE cohort and 35 (16.3%) in the control cohort received prophylactic defunctioning ileostomy due to presence of risk factors for AL (identified by the authors as low-level anastomosis, history of pelvic radiotherapy, android pelvis, diabetes mellitus and cardiovascular disease). Patients in both cohorts were matched according to age, sex, ASA score, tumour location, pre-operative chemoradiation and operative technique.

Ma et al. compared AB rate following laparoscopic anterior resection, with or without FE. In the FE group 12/128 (9.4%) patients demonstrated intra-operative AB and were treated immediately with endoscopic haemostasis. Post-operatively, 5/128 (3.9%) and 13/151 (8.6%) developed AB in the FE group and control group,

respectively. Tumour location <7cm from the anal verge and the use of FE were independent factors towards the development of post-operative AB(40).

Numerous reviews have compared the various techniques available to assess anastomotic patency, perfusion and allow endoluminal assessment(7, 15, 43).

Anecdotally, the colorectal literature appears to suggest endoscopic assessment is more common in the United States, but the conventional method of assessing a newly created anastomosis, usually insufflation of air via rigid sigmoidoscopy, is still the preferred approach in Europe. We performed this meta-analysis to compare flexible endoscopic mucosal inspection with air insufflation against basic conventional methods of assessing anastomotic integrity. Our analysis suggests flexible endoscopic assessment is associated with reduced anastomotic complication rates for leakage and bleeding, compared to conventional methods alone.

There are multiple limitations to this analysis. Overall, the quality of the included studies was limited by the largely retrospective design. The studies included span over 20 years of practice and demonstrate heterogeneity in patient populations (benign and malignant resections, and varied operative techniques (open or minimally invasive). In most studies, endoscopy was deployed selectively to assess tumour location and resection level, then later to inspect the anastomotic mucosa.

The use of covering ileostomy was sometimes irrelevant to the result of the endoscopic assessment. Most patients included in the meta-analysis were unmatched and it was difficult to ascertain the difference between cases and controls.



Anastomotic complications are well recognised but still relatively uncommon, thus case-control analysis is a valid method to assess the utility of flexible endoscopy in reducing post-operative complications. Identifying and recruiting cases on hospital databases by the intra-operative use of flexible endoscopy is acceptable. However, considering the biases mentioned above, interpreting the results of this meta-analysis requires caution. Table 3 contains studies identified during the literature review. These studies were included in previous systematic reviews but were excluded from this meta-analysis as they did not meet the inclusion criteria.

The results of this analysis suggest that the use of FE for anastomotic assessment should be harnessed as part of continued efforts to reduce AL and AB rates following colorectal resection. Sujatha-Bhaskar et al.(29) went further in suggesting an endoscopic grading system of the colonic mucosa (1-3) following stapled colorectal anastomosis. Grade 3 anastomoses (showing >30% ischaemia of the mucosa or ischaemia/ congestion involving both sides of the staple line) were immediately refashioned to Grade 1 (normal mucosa), and patient outcomes were compared between Grade 1 and Grade 2 (<30% ischaemia of the mucosa). Patients with Grade 2 anastomoses developed AL at a significantly higher rate compared to Grade 1 (40% and 9%, respectively). Although the study was underpowered, it does suggest a role for flexible endoscopy in the presence of consistent use and skill development and suggests clear methodology for interpretation and actioning the FE findings. Singh et al.(44) measured colonic serosal and mucosal oxygen perfusion concentrations at different stations during colorectal resection. Mucosal oxygen perfusion significantly decreased after ligation of the inferior mesenteric artery, however the serosa displayed minimal changes. The ability to detect inadequate

mucosal alignment or oxygenation in the presence of normal serosa might explain why intra-operative FE is associated with reduced AL rates over conventional methods. Using narrow-band imaging, FE can detect vascular patterns in the bowel wall surrounding freshly-created colonic anastomoses(45). Intra-operative endoscopic assessment can include measurement of tissue perfusion and oxygenation(15). Intra-operative tissue perfusion can be assessed with near infra-red imaging and the intra-vascular fluorescent dye indocyanine green (ICG)(46). If perfusion is deemed inadequate, the surgeon might elect to resect further bowel to a more satisfactory anastomotic location(47, 48). However, this technology requires dedicated instruments and training with a significant cost implication and none of the studies included in this analysis described these techniques, which are still not widely available to most institutions in the UK.

In conclusion, this meta-analysis has shown that intra-operative flexible endoscopy, when used to assess a left sided anastomosis, is associated with a reduced post-operative anastomotic leak and bleeding rate, when compared to conventional assessment methods. In order to overcome the heterogenous, low quality data in this area, further studies should be larger and include matched operative and patient characteristics. However, we propose that the results of this analysis suggest that surgeons should consider adopting intra-operative assessment of left sided anastomoses with flexible endoscopy into routine practice, as part of the ongoing surgical commitment to reducing post-operative anastomotic leakage and bleeding.

Figure 1: PRISMA diagram for systematic review of intraoperative flexible endoscopy in left-sided colonic resections

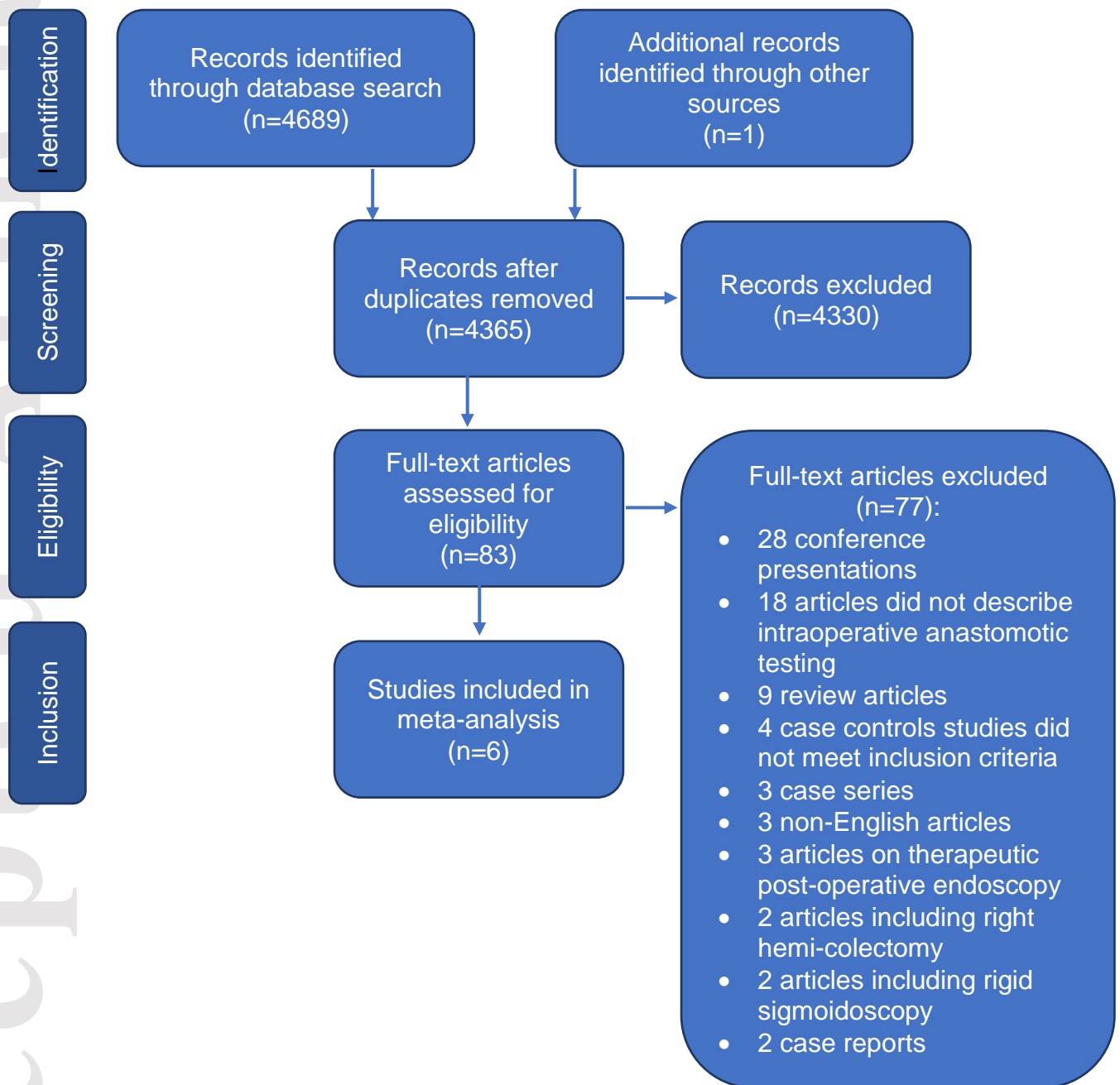
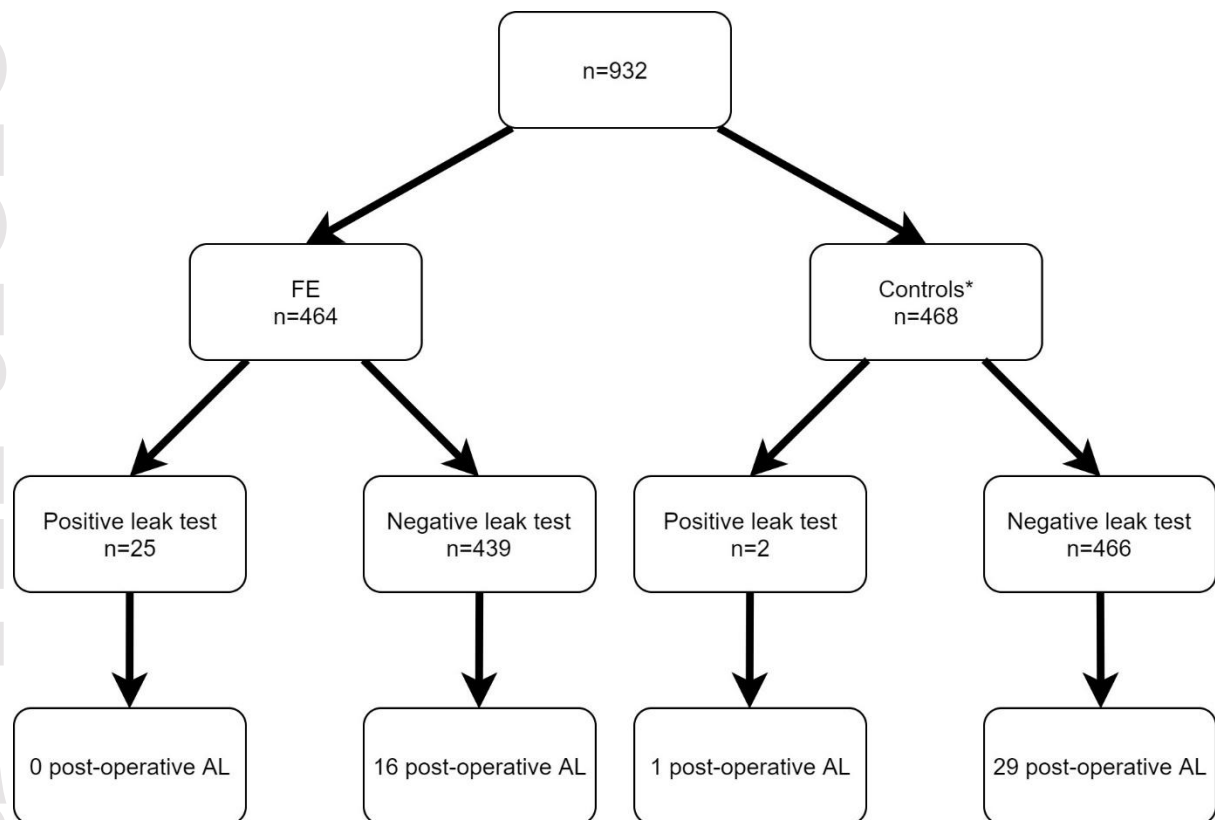


Figure 2: Flow chart of post-operative anastomotic leak rates following the use of flexible endoscopy



\*In comparison with control patients in whom anastomotic testing was performed non-endoscopically (Shamiyeh, Yang)

Figure 3: Effect of flexible endoscopy on post-operative anastomotic leak rates

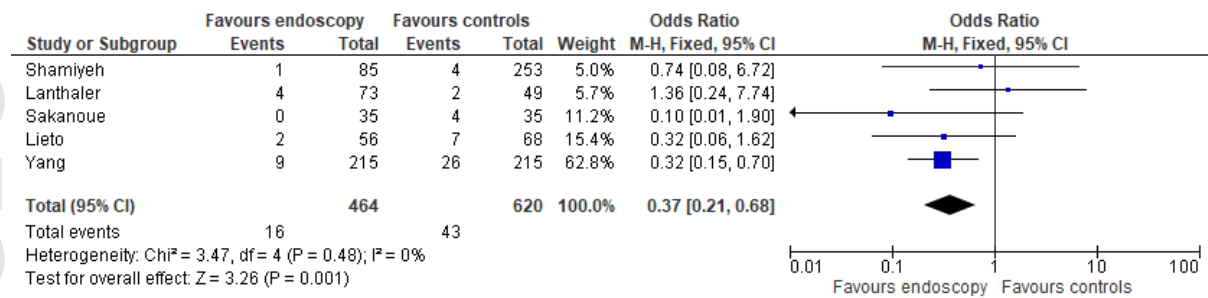


Figure 4: Effect of flexible endoscopy on post-operative anastomotic bleeding rates

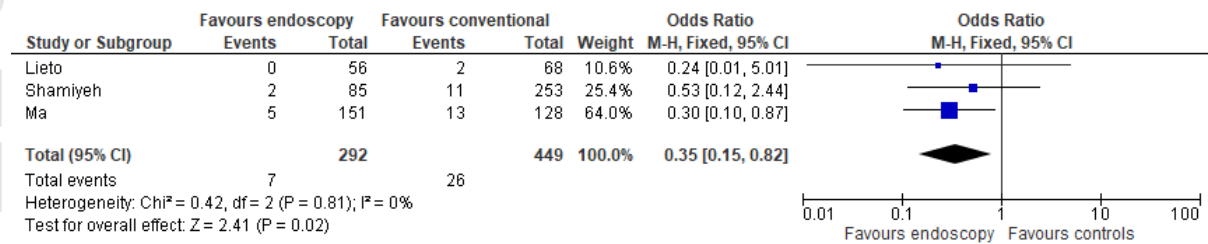


Figure 5: Funnel plot of comparison: Effect of flexible endoscopy on post-operative anastomotic leak rates

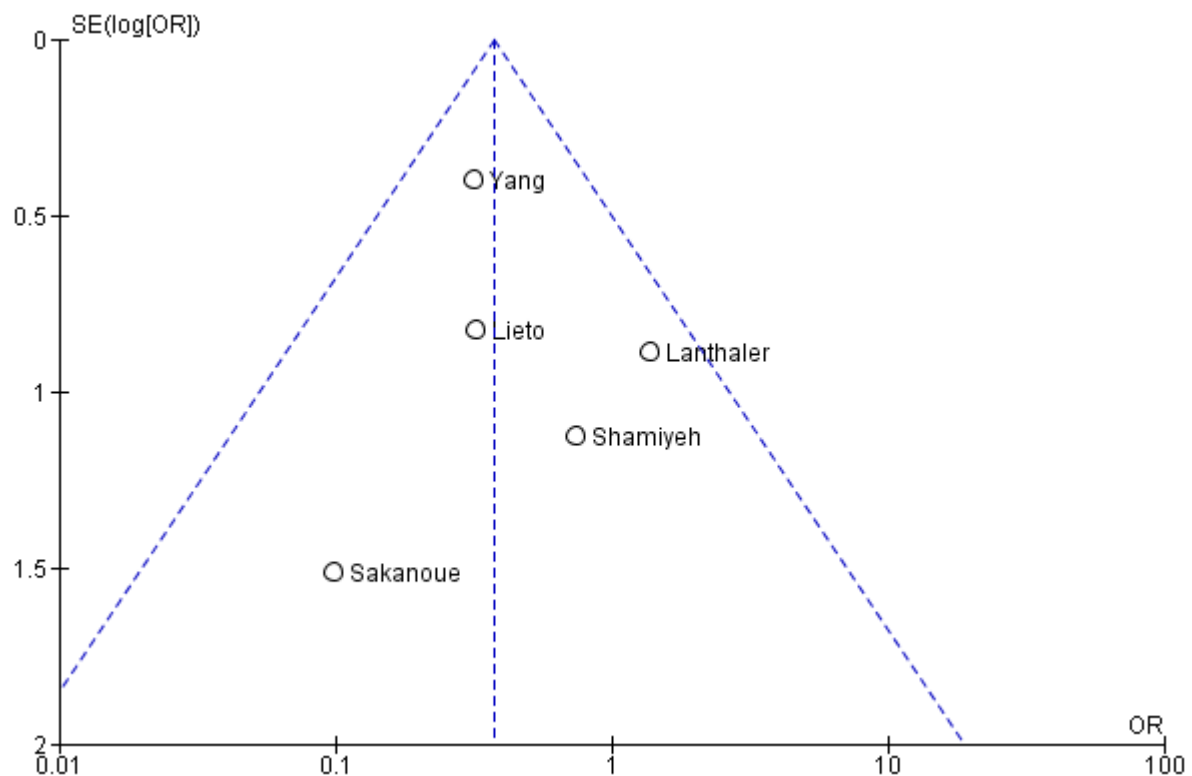


Table 1.: Case-control studies describing the effect of flexible endoscopy on post-operative anastomotic leakage

Study	Study period	Intra-operative endoscopy	Data collection	Case (n)	Case Anastomotic Testing	Control (n)	Control Anastomotic Testing	Control characteristics	Approach	Resection
Sakanoue 1993	1987-1991	Selective	Retrospective	35	FE	35	Untested	Historical, matched	Open	LAR
Lieto 2011	2001-2009	Routine	Prospective	56	FE	68	DC	Historical, unmatched	Open	LC
Lanthaler 2012	2001-2006	Selective	Retrospective	73	FE	49	AI	Temporal, unmatched	Laparoscopic	LC/S/AR
Shamiyeh 2012	1999-2010	Routine	Prospective	85	FE & DC	263	AI, DC & DT	Temporal, unmatched	Laparoscopic	LC
Yang 2017	2009-2013	Selective	Retrospective	215	FE	215	AI	Temporal, matched	Open/ Laparoscopic/Robotic	AR

FE: flexible endoscopy, AI: air insufflation, AR: anterior resection, DC: doughnut check, DT: dye test, LAR: low anterior resection, LC: left colectomy, S: sigmoidectomy



Table 2.: Case-control studies describing the use of flexible endoscopy on post-operative anastomotic bleeding

Study	Study period	Intra-operative endoscopy	Data collection	Case (n)	Control (n)	Control characteristics	Approach	Resection
Ma 2014	2006-2011	Selective	Retrospective	151	128	Temporal, unmatched	Laparoscopic	AR
Lieto 2011	2001-2009	Routine	Prospective	56	68	Historical, unmatched	Open	LC
Shamiyeh 2012	1999-2010	Routine	Prospective	85	263	Temporal, unmatched	Laparoscopic	LC

AI: air insufflation, AR: anterior resection, DC: doughnut check, DT: dye test, LAR: low anterior resection, LC: left colectomy, S: sigmoidectomy

Table 3.: Excluded case-control studies

Study	Methodology	Reason for exclusion
Zmora 2002	Case-control study, two groups of patients underwent flexible endoscopy in open or laparoscopic colorectal resections	No non-endoscopic controls
Schmidt 2003	Cohort study including low colonic tumour resections; flexible endoscopy introduced mid-study period and comparison was made with historical controls	Unable to confirm whether flexible endoscopy was used
Li 2009	Two groups of patients underwent ileorectal or colorectal stapled anastomoses, where flexible endoscopy was used selectively or routinely	No non-endoscopic controls
Gorgun 2013	Case-control study; two groups underwent flexible endoscopy or conventional anastomotic leak testing with historical controls	Mixed operations, including right-sided, subtotal and total resections

## References

1. Davis B, Rivadeneira DE. Complications of colorectal anastomoses: leaks, strictures, and bleeding. *Surg Clin North Am.* 2013;93(1):61-87.
2. Falconi M, Pederzoli P. The relevance of gastrointestinal fistulae in clinical practice: a review. *Gut.* 2001;49 Suppl 4:iv2-10.
3. Hammond J, Lim S, Wan Y, Gao X, Patkar A. The Burden of Gastrointestinal Anastomotic Leaks: an Evaluation of Clinical and Economic Outcomes. *Journal of Gastrointestinal Surgery.* 2014;18(6):1176-85.
4. Kim IY, Kim BR, Kim YW. The impact of anastomotic leakage on oncologic outcomes and the receipt and timing of adjuvant chemotherapy after colorectal cancer surgery. *International journal of surgery (London, England).* 2015;22:3-9.
5. Jung SH, Yu CS, Choi PW, Kim DD, Park IJ, Kim HC, et al. Risk factors and oncologic impact of anastomotic leakage after rectal cancer surgery. *Dis Colon Rectum.* 2008;51(6):902-8.
6. McArdle CS, McMillan DC, Hole DJ. Impact of anastomotic leakage on long-term survival of patients undergoing curative resection for colorectal cancer. *Br J Surg.* 2005;92(9):1150-4.
7. Hirst NA, Tiernan JP, Millner PA, Jayne DG. Systematic review of methods to predict and detect anastomotic leakage in colorectal surgery. *Colorectal disease : the official journal of the Association of Coloproctology of Great Britain and Ireland.* 2014;16(2):95-109.
8. Kingham TP, Pachter HL. Colonic anastomotic leak: risk factors, diagnosis, and treatment. *J Am Coll Surg.* 2009;208(2):269-78.

9. Besson R, Christidis C, Denet C, Bruyns L, Levard H, Gayet B, et al. Management of postoperative bleeding after laparoscopic left colectomy. *International journal of colorectal disease*. 2016;31(8):1431-6.
10. Fernandez de Sevilla Gomez E, Vallribera Valls F, Espin Basany E, Valverde Lahuerta S, Perez Lafuente M, Segarra Medrano A, et al. Postoperative small bowel and colonic anastomotic bleeding. Therapeutic management and complications. *Cir Esp*. 2014;92(7):463-7.
11. Parthasarathy M, Greensmith M, Bowers D, Groot-Wassink T. Risk factors for anastomotic leakage after colorectal resection: a retrospective analysis of 17 518 patients. *Colorectal disease : the official journal of the Association of Coloproctology of Great Britain and Ireland*. 2017;19(3):288-98.
12. Alves YP, Danielle; Trancar, Arnaud. Factors Associated with Clinically Significant Anastomotic Leakage after Large Bowel Resection: Multivariate Analysis of 707 Patients. *World Journal of Surgery*. 2002;26(4):499-502.
13. Veyrie N, Ata T, Muscari F, Couchard AC, Msika S, Hay JM, et al. Anastomotic leakage after elective right versus left colectomy for cancer: prevalence and independent risk factors. *J Am Coll Surg*. 2007;205(6):785-93.
14. Karliczek A, Harlaar NJ, Zeebregts CJ, Wiggers T, Baas PC, van Dam GM. Surgeons lack predictive accuracy for anastomotic leakage in gastrointestinal surgery. *International journal of colorectal disease*. 2009;24(5):569-76.
15. Nachiappan S, Askari A, Currie A, Kennedy RH, Faiz O. Intraoperative assessment of colorectal anastomotic integrity: a systematic review. *Surg Endosc*. 2014;28(9):2513-30.

16. Smith S, McGeehin W, Kozol RA, Giles D. The efficacy of intraoperative methylene blue enemas to assess the integrity of a colonic anastomosis. *BMC Surg.* 2007;7:15.
17. Lazorthes F, Chiotassol P. Stapled colorectal anastomoses: peroperative integrity of the anastomosis and risk of postoperative leakage. *International journal of colorectal disease.* 1986;1(2):96-8.
18. Davies AH, Bartolo DC, Richards AE, Johnson CD, McC Mortensen NJ. Intraoperative air testing: an audit on rectal anastomosis. *Annals of the Royal College of Surgeons of England.* 1988;70(6):345-7.
19. Beard JD, Nicholson ML, Sayers RD, Lloyd D, Everson NW. Intraoperative air testing of colorectal anastomoses: a prospective, randomized trial. *Br J Surg.* 1990;77(10):1095-7.
20. Cauchy F, Abdalla S, Penna C, Anglivièl B, Lambert B, Costaglioli B, et al. The small height of an anastomotic colonic doughnut is an independent risk factor of anastomotic leakage following colorectal resection: results of a prospective study on 154 consecutive cases. *International journal of colorectal disease.* 2017;32(5):699-707.
21. Matthiessen P, Hallbook O, Rutegard J, Simert G, Sjodahl R. Defunctioning stoma reduces symptomatic anastomotic leakage after low anterior resection of the rectum for cancer: a randomized multicenter trial. *Ann Surg.* 2007;246(2):207-14.
22. Montedori A, Cirocchi R, Farinella E, Sciannameo F, Abraha I. Covering ileo-colostomy in anterior resection for rectal carcinoma. *Cochrane Database Syst Rev.* 2010(5):Cd006878.
23. Wu Z, van de Haar RC, Sparreboom CL, Boersema GS, Li Z, Ji J, et al. Is the intraoperative air leak test effective in the prevention of colorectal anastomotic

leakage? A systematic review and meta-analysis. International journal of colorectal disease. 2016;31(8):1409-17.

24. Wheeler JM, Gilbert JM. Controlled intraoperative water testing of left-sided colorectal anastomoses: are ileostomies avoidable? Annals of the Royal College of Surgeons of England. 1999;81(2):105-8.

25. Ishihara S, Nagawa H, Watanabe T. Intraoperative colonoscopy for stapled anastomosis in colorectal surgery. Surgery today. 2008;38(11):1063-5.

26. Kamal T, Pai A, Velchuru VR, Zawadzki M, Park JJ, Marecik SJ, et al. Should anastomotic assessment with flexible sigmoidoscopy be routine following laparoscopic restorative left colorectal resection? Colorectal Disease. 2015;17(2):160-4.

27. Sasaki K, Ishihara S, Nozawa H, Kawai K, Hata K, Kiyomatsu T, et al. Successful Management of a Positive Air Leak Test during Laparoscopic Colorectal Surgery. Dig Surg. 2018;35(3):266-70.

28. Li VK, Wexner SD, Pulido N, Wang H, Jin HY, Weiss EG, et al. Use of routine intraoperative endoscopy in elective laparoscopic colorectal surgery: can it further avoid anastomotic failure? Surgical endoscopy. 2009;23(11):2459-65.

29. Sujatha-Bhaskar S, Jafari MD, Hanna M, Koh CY, Inaba CS, Mills SD, et al. An endoscopic mucosal grading system is predictive of leak in stapled rectal anastomoses. Surgical endoscopy. 2018;32(4):1769-75.

30. Shamiyeh A, Szabo K, Ulf Wayand W, Zehetner J. Intraoperative endoscopy for the assessment of circular-stapled anastomosis in laparoscopic colon surgery. Surgical laparoscopy, endoscopy & percutaneous techniques. 2012;22(1):65-7.

31. Sakanoue Y, Nakao K, Shoji Y, Yanagi H, Kusunoki M, Utsunomiya J. Intraoperative colonoscopy. Surgical endoscopy. 1993;7(2):84-7.



32. Arcila E, Shin J. Utility and techniques of intraoperative endoscopy and interventions. *Seminars in Colon and Rectal Surgery*. 2017;28(1):30-3.
33. Rao VS, Ahmad N, Al-Mukhtar A, Stojkovic S, Moore PJ, Ahmad SM. Comparison of rigid vs flexible sigmoidoscopy in detection of significant anorectal lesions. *Colorectal disease : the official journal of the Association of Coloproctology of Great Britain and Ireland*. 2005;7(1):61-4.
34. Rahbari NN, Weitz J, Hohenberger W, Heald RJ, Moran B, Ulrich A, et al. Definition and grading of anastomotic leakage following anterior resection of the rectum: a proposal by the International Study Group of Rectal Cancer. *Surgery*. 2010;147(3):339-51.
35. Higgins JP, Thompson SG, Deeks JJ, Altman DG. Measuring inconsistency in meta-analyses. *BMJ*. 2003;327(7414):557-60.
36. Liberati A, Altman DG, Tetzlaff J, Mulrow C, Gotzsche PC, Ioannidis JP, et al. The PRISMA statement for reporting systematic reviews and meta-analyses of studies that evaluate healthcare interventions: explanation and elaboration. *BMJ*. 2009;339:b2700.
37. Lanthaler M, Biebl M, Mittermair R, Ofner D, Nehoda H. Intraoperative colonoscopy for anastomosis assessment in laparoscopically assisted left-sided colon resection: Is it worthwhile? *Journal of Laparoendoscopic and Advanced Surgical Techniques*. 2008;18(1):27-31.
38. Lieto E, Orditura M, Castellano P, Pinto M, Zamboli A, De Vita F, et al. Endoscopic intraoperative anastomotic testing may avoid early gastrointestinal anastomotic complications. A prospective study. *Journal of gastrointestinal surgery : official journal of the Society for Surgery of the Alimentary Tract*. 2011;15(1):145-52.

39. Yang SY, Han J, Han YD, Cho MS, Hur H, Lee KY, et al. Intraoperative colonoscopy for the assessment and prevention of anastomotic leakage in low anterior resection for rectal cancer. *International journal of colorectal disease*. 2017;32(5):709-14.
40. Ma JJ, Ling TL, Lu AG, Zong YP, Feng B, Liu XY, et al. Endoscopic management for the assessment and treatment of anastomotic bleeding in laparoscopic anterior resection for rectal cancer. *Surgical laparoscopy, endoscopy & percutaneous techniques*. 2014;24(5):465-9.
41. Di Cristofaro L, Ruffolo C, Pinto E, Massa M, Antoniutti M, Cagol M, et al. Complications after surgery for colorectal cancer affect quality of life and surgeon-patient relationship. *Colorectal Disease*. 2014;16(12):O407-O19.
42. Allaix ME, Lena A, Degiuli M, Arezzo A, Passera R, Mistrangelo M, et al. Intraoperative air leak test reduces the rate of postoperative anastomotic leak: analysis of 777 laparoscopic left-sided colon resections. *Surgical endoscopy*. 2018.
43. Wu Z, Lange J, Menon A, Jeekel J. With routine air leak testing of low colorectal anastomosis is routine intra-operative flexible sigmoidoscopy necessary? *Colorectal Disease*. 2015;17(3):265-.
44. Singh DB, Stansby G, Bain I, Harrison DK. Intraoperative measurement of colonic oxygenation during bowel resection. *Adv Exp Med Biol*. 2009;645:261-6.
45. Milsom JW, Pavoor RS, Shukla PJ. Evaluating the vascularity of intestinal anastomoses - Can narrow band imaging play a role? *Medical Hypotheses*. 2011;77(2):290-3.
46. Sherwinter DA. Transanal near-infrared imaging of colorectal anastomotic perfusion. *Surgical laparoscopy, endoscopy & percutaneous techniques*. 2012;22(5):433-6.

47. Jafari MD, Wexner SD, Martz JE, McLemore EC, Margolin DA, Sherwinter DA, et al. Perfusion assessment in laparoscopic left-sided/anterior resection (PILLAR II): a multi-institutional study. *J Am Coll Surg*. 2015;220(1):82-92 e1.
48. Boni L, David G, Dionigi G, Rausei S, Cassinotti E, Fingerhut A. Indocyanine green-enhanced fluorescence to assess bowel perfusion during laparoscopic colorectal resection. *Surgical endoscopy*. 2016;30(7):2736-42.