

Case Report

Azathioprine-induced interstitial nephritis in an anti-neutrophil cytoplasmic antibody (ANCA) myeloperoxidase (MPO) vasculitis patient

Gilberto Pires da Rosa^{1,2}, Sofia Marques³, Fátima Coelho^{1,2}, Edite Pereira^{1,2}, Ester Ferreira^{1,2}, Pedro Rodrigues-Pereira⁴, Carlos Dias^{1,2}, Paulo Bettencourt^{1,2}

Abstract

Azathioprine (AZA) is used in a wide array of autoimmune diseases, still corresponding to the mainstay maintenance therapy in anti-neutrophil cytoplasmic antibody (ANCA)-associated vasculitides. Although generally well-tolerated, several side effects are recognized. We report the case of a 50-year-old Caucasian man with kidney-limited ANCA myeloperoxidase (MPO) vasculitis who presented with general malaise, fever, worsening renal function, and elevated inflammatory markers 2 weeks after the initiation of therapy with oral AZA. Although a disease relapse was suspected, renal biopsy revealed an eosinophilic infiltrate, suggestive of acute interstitial nephritis. After suspension of AZA, a sustained improvement of renal function and normalization of inflammatory markers was observed. A diagnosis of allergic interstitial nephritis secondary to AZA was established, corresponding to the first biopsy-proven case described in an ANCA MPO vasculitis patient. Although rare, renal toxicity of AZA must be present in the clinician's mind, avoiding the straightforward assumption of disease relapse in the case of worsening renal function.

Keywords: Azathioprine, interstitial nephritis, ANCA, vasculitis

Introduction

Azathioprine (AZA) still corresponds to the mainstay maintenance therapy in anti-neutrophil cytoplasmic antibody (ANCA)-associated vasculitides (1, 2). This drug is mostly well-tolerated, but numerous side effects are recognized. These can be divided in two categories: dose-dependent toxic side effects and rarer dose-independent hypersensitivity reactions (1, 3). The time lag to symptoms in hypersensitivity reactions is wide, ranging from 1 week to 16 months after starting therapy, but occurs more frequently in the first 4 weeks (1, 4). Resolution is swift upon drug cessation, with symptoms waning within a week (4).

Renal impairment with biopsy-proven interstitial nephritis is a rare event that has been reported in patients with vasculitides (2). Prognosis is favorable with drug cessation, and rechallenge should be avoided because of the risk of a severe, even life-threatening, acute response within hours (1, 2).

Case Presentation

A 50-year-old Caucasian man with kidney-limited ANCA MPO vasculitis was admitted to our emergency department due to malaise and fever. The diagnosis of vasculitis had been achieved 6 months earlier in context of rapidly progressive renal failure. Laboratory examination had revealed positivity for ANCA MPO, with renal biopsy displaying crescentic glomerulonephritis. Progressive recovery of renal function was attained under hemodialysis, plasmapheresis, and immunosuppression with methylprednisolone pulses and cyclophosphamide (Endoxan, Baxter Pharmaceuticals, NSW, Australia) administered according to the CYCLOPS protocol. After induction therapy, the patient no longer required renal function replacement therapy, with a serum creatinine value stabilized at 2.54 mg/dL. Five weeks after the last cyclophosphamide pulse (cumulative dose 9 g), maintenance therapy was initiated with oral AZA (Imuran; Aspen Pharma Trading, Dublin, Ireland) 50 mg/day.

Thirteen days later, the patient was admitted to our emergency department complaining of general malaise, fever, diaphoresis, and productive cough with mucous sputum for the last 24 hours.



Cite this article as: da Rosa GP, Marques S, Coelho F, Pereira E, Ferreira E, Rodrigues-Pereira P, et al. Azathioprine-induced interstitial nephritis in an anti-neutrophil cytoplasmic antibody (ANCA) myeloperoxidase (MPO) vasculitis patient. *Eur J Rheumatol* 2018; 5: 135-8.

¹ Department of Internal Medicine, São João Hospital Center, Porto, Portugal

² Autoimmune Diseases Consultation, São João Hospital Center, Porto, Portugal

³ Department of Nephrology, São João Hospital Center, Porto, Portugal

⁴ Department of Pathology, São João Hospital Center, Porto, Portugal

Address for Correspondence:

Gilberto Pires da Rosa, Department of Internal Medicine & Autoimmune Diseases Consultation, São João Hospital Center, Porto, Portugal

E-mail: gilbertopiresrosa@gmail.com

Submitted: 17 April 2017

Accepted: 20 July 2017

Available Online Date: 07.12.2017

©Copyright by 2018 Medical Research and Education Association - Available online at www.eurjrheumatol.org.

Physical examination on admission displayed a patient with good general status, feverish (auricular temperature of 40.4°C), with a blood pressure of 143/95 mmHg, heart frequency of 125 beats per minute, and peripheral oxygen saturation measured by pulse oximetry of 100%.

Laboratory examination revealed normocytic/normochromic anemia (11.4 g/dL), white blood cells count of $9.44 \times 10^9/L$ with predominant neutrophilia (92.2 %) and normal platelet count. Renal function was stable (serum creatinine 2.37 mg/dL, urea 85 mg/dL) but elevated C-reactive protein (CRP)-134.5 mg/L (normal <5 mg/L) was detected. Urine analysis displayed leukocyturia and erythrocyturia. Renal ultrasonography exhibited normally dimensioned kidneys with preserved cortico-parenchymal differentiation and increased echogenicity. Chest computerized tomography scan revealed no evident abnormalities.

Considering the clinical picture of fever in an immunosuppressed patient, and pondering the possibility of a relapse of the vasculitic disease, the patient was hospitalized for further study. Antibiotherapy with piperacillin/tazobactam was instituted. Ambulatory immunosuppressive therapy was maintained.

On admission, a new papular rash located on the dorsum of hands was found (Figure 1). Magnetic resonance imaging of the lumbar spine was performed revealing no signs of spondylodiscitis. The patient maintained fever spikes, with gradual worsening of renal function (to serum creatinine 3.43 mg/dL, urea 71 mg/dL) with sustained CRP elevation and leukocytosis at the fourth day of hospitalization and antibiotic, strengthening the hypothesis of a vasculitic relapse. Pulses of methylprednisolone were instituted (500 mg/day) and a renal biopsy scheduled prior to a new induction cycle of cyclophosphamide, in order to further sustain the relapse hypothesis. A worsening of the dermatologic lesions of hands was also verified, with a purpuric appearance and scattered pustules (Figure 2), and skin biopsy was performed.

After the third methylprednisolone administration, the patient maintained a progressively aggravated renal function (serum creatinine 5.96 mg/dL, urea 175 mg/dL). Renal biopsy was performed, revealing an eosinophilic infiltrate suggestive of acute interstitial nephritis (allergic type), and sequelae of vasculitis, with no signs of acute activity (Figure 3, 4). Despite the absence of peripheral eosinophilia and eosinophiluria, the possibility of allergic interstitial ne-

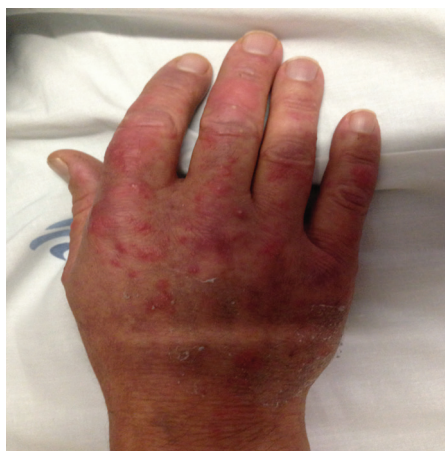

Figure 1. Papular rash located to the dorsum of hands at admission

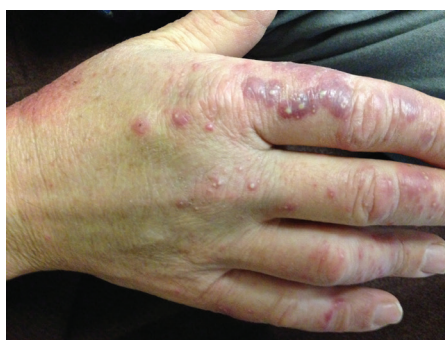

Figure 2. Worsening of the dermatologic lesions, with a purpuric appearance and scattered pustules. Biopsy revealed a neutrophilic dermatitis, with no evidence supporting the diagnosis of vasculitis

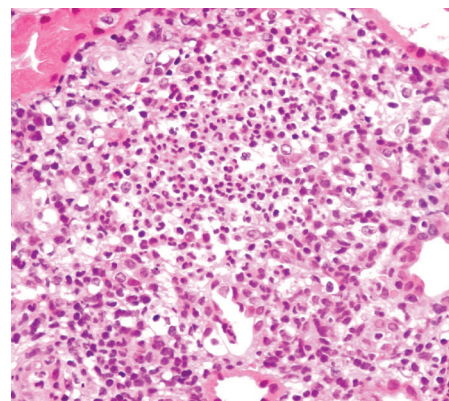


Figure 3. Renal biopsy pathology: marked interstitial inflammation with eosinophil-predominant infiltrate (hematoxylin and eosin 400x)

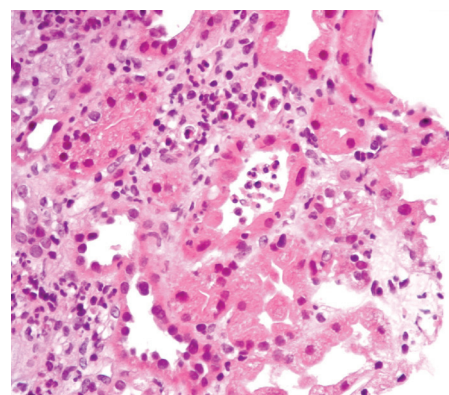


Figure 4. Renal biopsy pathology: tubulitis with intraepithelial neutrophils found in the renal tubules (hematoxylin and eosin 400x)

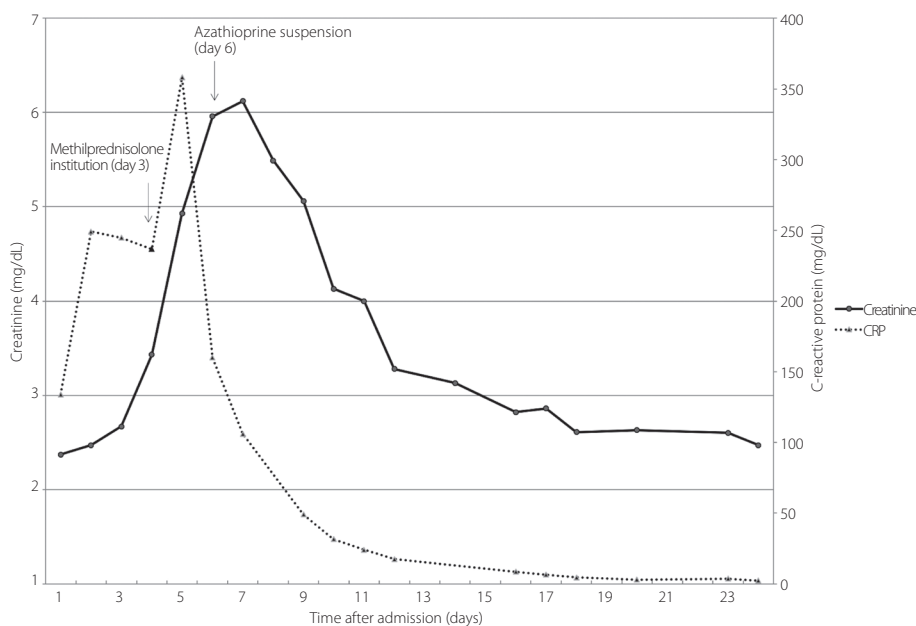


Figure 5. Patient's creatinine and CRP levels, and their evolution during hospitalization. Corticosteroids were introduced on the third day after admission and azathioprine stopped on the sixth day of hospitalization, with a concomitant improvement of renal function.

CRP: C-reactive protein

Factor for converting serum creatinine in mg/dL to mol/L, 88.4

Table 1. Renal causes of eosinophilia**Etiology**

Allergic interstitial nephritis

Renal carcinoma

Transplant rejection

Cholesterol embolic disease

Vasculitis

Renal replacement therapy (peritoneal and hemodialysis)

Chronic kidney disease not on renal replacement therapy

Diffuse proliferative glomerulonephritis

Thrombotic thrombocytopenic purpura

Renovascular disease

Adapted from Diskin et al. (13)

phritis secondary to AZA was considered, leading to discontinuation of both this medication and antibiotic. Corticotherapy was adjusted to oral prednisolone 1 mg/kg/day (70 mg/day). A sustained improvement of renal function was verified with a parallel decrease in inflammatory markers, with stabilized values at discharge (day 18 of hospitalization) at a serum creatinine value of 2.47 mg/dL and CRP of 2.3 mg/L (analytic evolution displayed in Figure 5). A diagnosis of allergic interstitial nephritis secondary to AZA was established.

Additionally, progressive healing of the cutaneous lesions was verified, with no residual scarring, and biopsy revealed a neutrophilic dermatitis, with no evidence supporting the diagnosis of vasculitis. Adding the history of fever, laboratorial abnormalities, and the histologic findings on skin biopsy, a component of the Sweet Syndrome was assumed.

Considering the diagnosis of allergic interstitial nephritis secondary to AZA, maintenance therapy with rituximab (MabThera, Roche Pharmaceuticals, Basel, Switzerland) was instituted according to the MAINRITSAN trial scheme: two administrations (at a fixed 500-mg dose) separated by 2 weeks, and then at months 6, 12, and 18 after the first infusion (5). The patient evolved favorably with stable renal function and clinical status on follow-up.

Discussion

Interstitial nephritis due to AZA sensitivity, though associated with various disorders, has only been confirmed through biopsy in 12 cases: five cases of granulomatosis with polyangiitis (2, 3, 6-8); one of polyarteritis nodosa; two of Henoch-Schönlein purpura; one of Goodpas-

ture syndrome; one of chronic glomerulonephritis; and two transplant recipients (6, 9-11).

In our patient, the diagnosis of hypersensitivity reaction was made more difficult by the similarity of the symptomatology with the presenting signs of the vasculitic disease, mimicking a disease relapse. In this scenario, the biopsy played an essential part directing the diagnosis. The role of repeat biopsy is not formally stipulated for ANCA vasculitides, and a more standardized approach could prove beneficial.

In our case, the renal biopsy displayed an eosinophilic infiltrate suggestive of acute interstitial nephritis, compatible with hypersensitivity reaction to AZA, in which polymorphonuclear infiltrate constitutes the most reported histological feature, but with one case of eosinophil-rich infiltrate being also stated (2). Moreover, the absence of acute signs of disease activity in the biopsy weakened the relapse hypothesis, and the time lag to symptoms after drug initiation and the prompt resolution after cessation reinforced the diagnosis of hypersensitivity reaction to AZA. The absence of eosinophilia and eosinophiluria could be seen as a limitation, but urinary eosinophils are currently considered a test with poor sensitivity and low positive predictive value, with its absence not excluding at all the diagnosis, and eosinophilia is present in only 25%-50% of acute interstitial nephritis cases (12). A list of renal diseases associated with eosinophilia is available in Table 1. A plausible alternate diagnosis considering the biopsy findings could be eosinophilic granulomatosis with polyangiitis (EGPA). Nevertheless, while the prevailing picture in EGPA is ANCA-associated necrotizing crescentic glomerulonephritis, in acute allergic drug-induced interstitial nephritis, the major histologic abnormalities are in the interstitium, which is expanded by a number of inflammatory cells, with the presence of large numbers of eosinophils, as it is seen in this patient.

Sweet Syndrome, also denominated acute neutrophilic dermatosis, has been associated both with autoimmune diseases such as ANCA vasculitides, and drugs, namely AZA (1). In these cases, distinction between a disease and drug-induced Sweet Syndrome might be problematic. The patient fulfilled the diagnostic criteria for Sweet Syndrome, including the two major criteria (abrupt onset of painful erythematous plaques and histopathologic evidence of a dense neutrophilic infiltrate without evidence of leukocytoclastic vasculitis). Additionally, the patient fulfilled the criteria for drug-induced Sweet Syndrome, including the

temporal relationship between drug ingestion and clinical presentation and the temporally related resolution of lesions after drug withdrawal. An alternative diagnosis considering the type of skin lesions that the patient displayed could be neutrophilic urticarial dermatosis. The main factor strengthening the Sweet Syndrome hypothesis was the presence of dermal edema (both clinical and histologically). Additionally, the neutrophilic infiltrate was denser than expected in the case of neutrophilic urticaria. So, considering the presence of a drug-induced Sweet Syndrome component in this patient, the possibility of the kidney biopsy findings corresponding to a renal manifestation of this disease was raised. Nevertheless, literature review revealed no cases of interstitial nephritis as renal manifestation in Sweet Syndrome (being only described mesangiocapillary glomerulonephritis), reinforcing the diagnosis of a hypersensitivity reaction to AZA.

This case report corresponds, according to our literature review, to the first account of a biopsy-proven allergic interstitial nephritis secondary to AZA in an ANCA MPO vasculitis patient, raising awareness to this entity, both for the potentially severe complications and the need for a therapy significantly distinct from disease relapse.

Informed Consent: Written informed consent was obtained from the patient who participated in this study.

Peer-review: Externally peer-reviewed.

Author Contributions: Concept - G.P.R., S.M., F.C., E.F., E.P., P.R.P., P.B., C.D.; Design - G.P.R., S.M.; Supervision - F.C., E.F., E.P., P.B., C.D.; Resources - G.P.R., S.M.; Materials - G.P.R., S.M.; Data Collection and/or Processing - G.P.R., S.M., F.C., P.R.P.; Analysis and/or Interpretation - G.P.R., S.M., P.R.P.; Literature Search - G.P.R., S.M., E.F., E.P., P.B.; Writing Manuscript - G.P.R., S.M., E.F., E.P., P.B., C.D.

Conflict of Interest: The authors have no conflict of interest to declare.

Financial Disclosure: The authors declared that this study has received no financial support.

References

1. Turow A, Yong TY, Fok JS, Li JY. Azathioprine hypersensitivity presenting as cardiogenic shock and Sweet's syndrome in a patient with microscopic polyangiitis. *Internal medicine* 2012; 51: 1889-92. [CrossRef]
2. Reinhold-Keller E, Schmitt WH, Gross WL. Azathioprine toxicity mimicking a relapse of Wegener's granulomatosis. *Rheumatology* 2001; 40: 831-2. [CrossRef]

3. Salama AD, Cook HT, Pusey CD, Pepper RJ. A case of treated ANCA-associated vasculitis with recurrent renal failure. *Clin J Am Soc Nephrol* 2008; 3: 637-45. [\[CrossRef\]](#)
4. Stratton JD, Farrington K. Relapse of vasculitis, sepsis, or azathioprine allergy? *Nephrol Dial Transplant* 1998; 13: 2927-8. [\[CrossRef\]](#)
5. Guillevin L, Pagnoux C, Karras A, Khouatra C, Aumaitre O, Cohen P, et al. Rituximab versus azathioprine for maintenance in ANCA-associated vasculitis. *N Engl J Med* 2014; 371: 1771-80. [\[CrossRef\]](#)
6. Parnham AP, Dittmer I, Mathieson PW, McIver A, Dudley C. Acute allergic reactions associated with azathioprine. *Lancet* 1996; 348: 542-3. [\[CrossRef\]](#)
7. Bir K, Herzenberg AM, Carette S. Azathioprine induced acute interstitial nephritis as the cause of rapidly progressive renal failure in a patient with Wegener's granulomatosis. *J Rheumatol* 2006; 33: 185-7.
8. Ayoub I, Almaani S, Alvarado A, Parikh SV, Rovin BH. Quiz Page February 2016: Acute Kidney Injury in a Patient With Granulomatosis With Polyangiitis Receiving Maintenance Immunosuppressive Therapy. *Am J Kidney Dis* 2016; 67: 20-3. [\[CrossRef\]](#)
9. Shin JI, Lee JS, Jeong HJ. Azathioprine and tubulointerstitial nephritis in HSP. *J Rheumatol* 2006; 33: 2551.
10. Stetter M, Schmidl M, Krapf R. Azathioprine hypersensitivity mimicking Goodpasture's syndrome. *Am J Kidney Dis* 1994; 23: 874-7. [\[CrossRef\]](#)
11. Sloth K, Thomsen AC. Acute renal insufficiency during treatment with azathioprine. *Acta Med Scand* 1971; 189: 145-8. [\[CrossRef\]](#)
12. Praga M, Gonzalez E. Acute interstitial nephritis. *Kidney Int* 2010; 77: 956-61. [\[CrossRef\]](#)
13. Diskin CJ, Stokes TJ, Dansby LM, Radcliff L, Carter TB. The prevalence and meaning of eosinophilia in renal diseases on a nephrology consultation service. *Nephrol Dial Transplant* 2011; 26: 2549-58. [\[CrossRef\]](#)