

# Case Report: Uniportal Video Assisted Thoracoscopic Excision of a Giant Thymic Cyst Mimicking a Pericardial Cyst

Suha Alzafer<sup>1</sup>, Erdal Okur<sup>2</sup>, Semih Halezeroğlu<sup>2</sup>

<sup>1</sup>Acıbadem Üniversitesi Tıp Fakültesi, Göğüs Hastalıkları Anabilim Dalı, İstanbul, Türkiye

<sup>2</sup>Acıbadem Üniversitesi, Göğüs Cerrahisi Anabilim Dalı, İstanbul, Türkiye

## ABSTRACT

Most of the mediastinal cysts are benign but still needs surgical excision for a definitive diagnosis and to prevent compressive symptoms. Radiological examination itself may sometimes have limited diagnostic value. A pericardial cyst is always a benign lesion and does not need an excision unless it reaches to an extreme size while a thymic cyst should be excised when diagnosed since it may rarely show malignant degeneration. Here we present an extreme sized thymic cyst radiologically mimicking a pericardial cyst.

Keywords: thymic cyst, pericardial cyst, mediastinal cysts

## OLGU SUNUMU: PERİKARDAİYAL KİSTİ TAKLİT EDEN DEV BİR TİMİK KİSTİN UNİPORTAL VİDEO YARDIMLI TORAKOSKOPİK EKZİZYONU

### ÖZET

Mediastinal kistler genellikle beningdir. Ancak kesin tanının konulabilmesi ve bası semptomlarını önlemek için cerrahi tedavi gerektirebilirler. Mediastinal kistlerin ayırıcı tanısında bazan radyolojik görüntüleme sınırlı tanısal değere sahip olabilir. Perikardiyal kistler, bening lezyonlardır ve aşırı büyüklüğe ulaşmadıkları sürece cerrahi tedavi gerektirmezler. Timik kistler ise nadiren de olsa malign dejenerasyon gösterebileceklerinden cerrahi olarak çıkarılmalıdırlar. Bu makalede radyolojik olarak perikardiyal kisti taklit eden ve ekstrem boyutlara ulaşmış bir timik kist olgusunu sunduk.

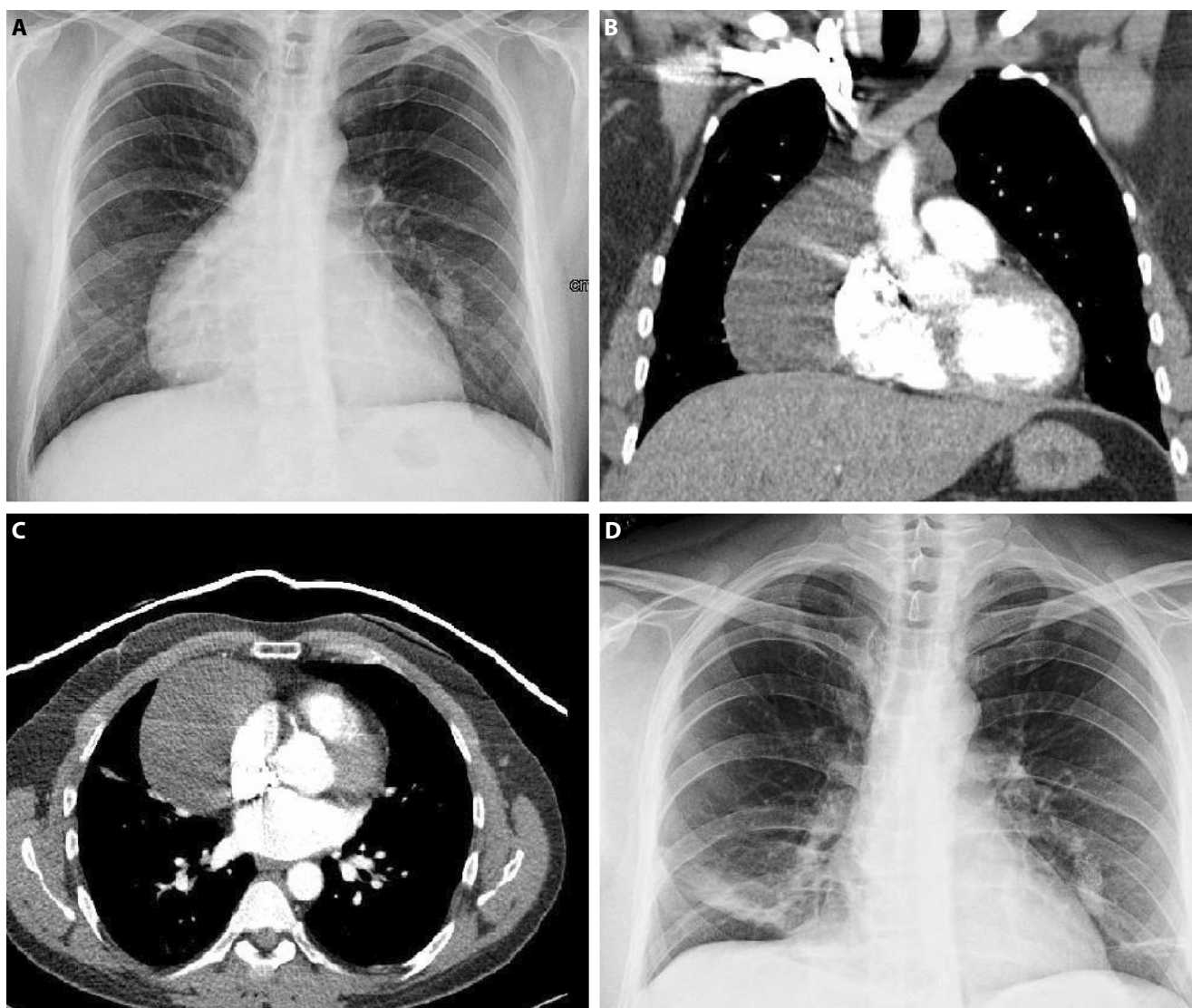
Anahtar sözcükler: timik kist, perikardiyal kist, mediastinal kist

**T**hymic cysts are rare, mostly benign, cervical or mediastinal lesions. They are considered to be sequestered remains of the thymopharyngeal duct structure. They can be located in any position along the normal descent route of the thymus gland, i.e. from the mandible angle, through the lateral neck, up to the sternal notch, with half of them extending in to the anterior mediastinum (1,2,3). The diagnosis is usually made post-operatively, based on histological examination of the excised specimen.

Complete surgical removal remains the treatment of choice (1). We present a case of an extreme-sized thymic cyst mimicking a pericardial cyst or cardiomegaly in the chest x-ray.

## Case report

A 40-year-old gentleman showed a widening of the mediastinum, which was detected in his routine chest X-ray (Figure 1A). He had complained of dyspnea on exertion for a few months. Routine laboratory tests including complete blood count, routine serum biochemistry, urinalysis and an electrocardiography were within normal limits. He was referred to a cardiologist and an echocardiography examination was performed which yielded normal cardiac findings except a cystic lesion was identified adjacent to the pericardium on the right side. A chest computerized tomography showed the cystic lesion measured 10x11 cm on the right and partly anterior to the pericardium (figure 1B and 1C). We had an initial diagnosis of a pericardial cyst, which normally does not need an excision, but since our patient had some extent of dyspnea symptom, we proceeded with an excision.



**Figure 1.** A) Preoperative chest roentgenogram B) Coronal and C) axial section view of chest tomography D) Postoperative chest roentgenogram

We performed a right 2 cm single incision videothoracoscopy, using a 5 mm, 30 degree camera and observed a cystic mass at the anterior mediastinum on the right and slightly anterior to the pericardium. Cyst fluid was aspirated for cytological examination and shrinkage of the cyst eased the dissection and extraction of the cyst from the chest cavity. The cyst wall was released from mediastinal attachments, including the pericardium, with the help of an ultrasonic sealing instrument (Ligasure) and then totally excised. Postoperative period was uneventful and the patient was discharged on postoperative day 2 (Figure 1D). Postoperative pathology yielded a thymic cyst.

## Discussion

Thymic cysts represent rare lesions of the neck or anterior mediastinum. Cervical thymic cysts are less common than

those located in the mediastinum. They are located in the lower third of the neck, typically presenting as a lateral, painless swelling. Most presenting cases are left sided. Approximately 50 % of the cervical thymic cysts extend into the anterior mediastinum (2). Mediastinal thymic cysts are more frequent than cervical (1). They are usually asymptomatic, but can also present with symptoms such as coughing, wheezing, dysphagia, hoarseness and dyspnea, due to compression and displacement of surrounding structures. The sole symptom was dyspnea on moderate exertion with our patient.

A thymic cyst can be easily diagnosed by routine radiographic imaging procedures. These cysts comprise 1 % of all primary mediastinal masses (4, 5). Neck and chest radiography, ultrasonography, CT and especially magnetic

resonance imaging are primarily used during the preoperative evaluation of thymic cysts. Nevertheless, there is no standard imaging examination that can preoperatively eliminate the possibility of malignancy of the lesion. Complete surgical excision of the lesion is recommended for two reasons as soon as they are detected, even in asymptomatic mediastinal thymic cysts. First of all, imaging procedures are almost never able to determine the histologic nature of the lesion. Even though rare, malignant transformation is sometimes found in thymic cysts (6). Histopathology is always necessary for a definitive diagnosis. Secondly, cervical and mediastinal masses tend to become symptomatic sooner and later. Symptoms are due to inflammation, hemorrhage or simply the pressure on the surrounding anatomical structures. Thus, an excision is also very likely to prevent a possible symptom.

Chest X-ray showed a right-sided paracardiac widening of the mediastinum in our case. Echocardiography could only differentiate that the lesion is a paracardiac pathology rather than cardiac enlargement. Our presumptive diagnosis was a pericardial cyst, which is commonly seen on the right paracardiac space. However, we could reach the definitive diagnosis only after a surgical excision and a histological examination. The size and the location of the cyst was extraordinary since generally thymic cysts are only a few centimeters in size and the right paracardiac localization was unusual.

In conclusion, definitive diagnosis of a mediastinal cyst can only be reached by surgical excision. Thymic cysts, which need a surgical excision, can mimick a pericardial cyst that can usually be conservatively followed up.

#### References

1. Amanotidou V, Mavrokosta M, Kourtesis A, Azariadis P, Tsilimigahi A. Cervicomedastinal Tyymic Cyst-Report of a Case. *Thorac Cardiovasc Surg* 2008;56:177-78.
2. Nguyen Q., Tar M., Wells W et al. Cervical thymic cyst: case reports and review of the literature. *Laryngoscope* 1996;106:247-52.
3. Kelley DJ., Gerber ME. Willging JP. Cervicomedastinal thymic cysts. *Int J Pediatr Otorhinolaryngol* 1997;39:139-46.
4. Petropolulos I., Konstantinidis I., Noussious G., Karagiannidis K., Kontzoglou G. Thymic cysts in the differential diagnosis of pediatric cervical masses. *B-ENT* 2006;2:35-37.
5. Stollo DC. Rosado de Christenson ML., Jett JR. Primary mediastinal tumors. Part 1. Tumors of anterior mediastinum. *Chest* 1997;112:511-22.
6. Leong AS, Brown JH. Malignant transformation in a thymic cyst. *Am J Surg Pathol.* 1984; 8: 471-5.