



1992

Regional Accuracy of Temporomandibular Joint Imaging: Comparison of Mr and Ct with Autopsy Specimens

Charles F. Reed
Loyola University Chicago

Follow this and additional works at: https://ecommons.luc.edu/luc_theses



Part of the [Dentistry Commons](#)

Recommended Citation

Reed, Charles F., "Regional Accuracy of Temporomandibular Joint Imaging: Comparison of Mr and Ct with Autopsy Specimens" (1992). *Master's Theses*. 3850.
https://ecommons.luc.edu/luc_theses/3850

This Thesis is brought to you for free and open access by the Theses and Dissertations at Loyola eCommons. It has been accepted for inclusion in Master's Theses by an authorized administrator of Loyola eCommons. For more information, please contact ecommons@luc.edu.



This work is licensed under a [Creative Commons Attribution-Noncommercial-No Derivative Works 3.0 License](#).
Copyright © 1992 Charles F. Reed

REGIONAL ACCURACY OF TEMPOROMANDIBULAR JOINT IMAGING:
COMPARISON OF MR AND CT WITH AUTOPSY SPECIMENS

BY

CHARLES F. REED, D.D.S.

A THESIS SUBMITTED TO THE
FACULTY OF THE GRADUATE SCHOOL
OF LOYOLA UNIVERSITY OF CHICAGO
IN PARTIAL FULFILLMENT OF THE REQUIREMENTS
FOR THE DEGREE OF MASTER OF SCIENCE

JANUARY

1992

Copyright by Charles F. Reed, D.D.S., 1991

All Rights Reserved

TABLE OF CONTENTS

ACKNOWLEDGEMENTS	iv
INTRODUCTION	1
REVIEW OF THE LITERATURE	5
Incidence of Dysfunction	5
Disc Position and Morphologic Changes	6
Imaging Techniques	17
Conventional Films: Transcranial, Tomography	17
Arthrography: Single-Contrast	20
Arthrography: Double-Contrast	33
Computed Tomography	38
Magnetic Resonance	47
Purpose of Study	68
MATERIALS AND METHODS	72
Selection of Specimens	72
MR Technique and Parameters	73
CT Technique and Parameters	75
Anatomical Sectioning	76
Interpretation and Comparison	78
RESULTS	82
Disc Position - General	82
Disc Morphology - General	84
Osseous Anatomy - General	85
Posterior Attachment	87
Disc Position - Specific	89
Disc Morphology - Specific	94
Osseous Anatomy - Specific	98
DISCUSSION	104
CONCLUSIONS	126
APPENDIX	131
REFERENCES	152
VITA	168

ACKNOWLEDGEMENTS

I would like to express my sincerest appreciation to all those who have assisted in making this research possible. A special note of gratitude must be acknowledged to the following people:

To Dr. Lewis Klapper, thesis director and past chairman of the Department of Orthodontics, for his guidance, encouragement, and patience as well as for a superb education in the field of Orthodontics.

To Dr. Raymond Warpeha, chairman of the Department of Plastic Surgery, for his belief in the potential of this study and for his generous financial support.

To Dr. Joseph Gowgiel, chairman of the Department of Anatomy, for his encouragement throughout the course of this investigation.

To Drs. Enrique Palacios, Galdino Valvassori, and Glen Dobben of the Berwyn Magnetic Resonance Center, who so graciously donated the use of their facility for the purposes of this study.

To Mrs. Dorothy Smith and the late Mrs. Susan Regan, who as technicians at the Berwyn Magnetic Resonance Center sacrificed many late evenings and offered invaluable assistance in accomplishing the MR imaging.

To Ms. Nancy Gattuso and the technicians in the Department of Radiology at the Loyola University Medical Center, for their assistance in obtaining the computed tomographic images.

To Mr. Bruce Nowicki of the Medical College of Wisconsin, for his assistance with anatomical sectioning and photography.

To Mrs. Kris Nemelka and Mr. Don Deem for their invaluable assistance in typing and printing this manuscript.

To my wife, Traci, for her sacrifice, encouragement, and love which has given my life meaning and eternal joy.

To my mother and father, for their steadfast love, support, and sacrifices which have blessed my life.

To my Father in heaven, for the gifts of intelligence, opportunity, and insights into those things of eternal importance.

INTRODUCTION

Many of the difficulties that occur in obtaining successful treatment of temporomandibular joint (TMJ) disorders may be due to deficiencies in the original diagnosis. The proper treatment is always predicated upon a proper diagnosis. This is made more complicated due to the complex anatomy and physiology of the TMJ.

Many imaging modalities have been applied to supplement the clinical information in these cases. The most common technique employed is the oblique transcranial radiograph. However, researchers have shown this to be unreliable from a diagnostic point of view.(1-10) Tomography has proved to be more diagnostic for deviations in form, structure, and condylar position within the TMJ.(2,4,7,10,11,12)

With varying degrees of success, these techniques demonstrate osseous anatomy, condylar position, and pathological information within the joint. However, diagnostic information regarding abnormalities of the articular disc, posterior attachment, and soft tissues within the joint are notably absent with conventional radiography, tomography included. These tissues play a highly significant role in the pathophysiology of TMJ disorders.(12-17) Accurate information concerning the position of the articular disc relative to the condyle and glenoid fossa, its morphology and the status of

the attachment tissues must be considered as well as the osseous anatomy in the pretreatment diagnosis.(13,18,19)

Arthrography has been considered the "gold standard" for diagnosing internal derangements of the TMJ over the last ten years.(20-22) By injecting radiopaque dye into the joint compartments, an outline of the disc is obtained which has been shown to have a diagnostic accuracy of between 81% and 97%.(23-27) However, because the technique is technically difficult to perform, iatrogenic complications occur. For example, a false-positive diagnosis of disc perforation has occurred in up to 15% of the cases.(24,28,29) In addition, it is moderately uncomfortable for the patient while the images are sometimes difficult to interpret.(20,30) The patient is exposed to ionizing radiation and since bone detail is not well demonstrated, additional exposure is necessary to supplement the study with plain tomograms.

More recently, imaging techniques have been developed whereby information concerning disc position and osseous abnormalities can be acquired through completely noninvasive means. Computed tomography (CT) offers superior visualization of the osseous elements as well as direct visualization of soft tissue anatomy. Diagnostic accuracy of CT when compared with arthrography and/or surgery has been reported to be 80 to 97%.(31-34) Improved soft tissue resolution is achieved through the direct sagittal approach, however care must be taken with this technique to avoid irradiating the lens of the

eye. Radiation exposure is reduced from that experienced in arthrography, but is still significant.(35) Patient positioning is rather difficult and may limit its application in certain patients.(32)

Magnetic resonance imaging offers an attractive alternative to the above techniques. Greater insight regarding the pathophysiology of the joint can be obtained while eliminating any exposure to ionizing radiation. The technique is completely non-invasive and has been shown to cause no known biological hazards.(36-40) Both hard and soft tissues can be examined in one study limiting the need for plain films including tomograms. Improved diagnostic information is available regarding not only the relative position of joint structures, but also the morphology and histology of the tissues involved.

Preliminary investigations with this technique have concentrated on its clinical application for improved imaging of TMJ disorders.(41-43) In this prospective study of 11 cadavers, we attempted to document the accuracy of MR and direct sagittal CT scans by comparing them with findings from dissections and cryosections of the joints. A surgical evaluation of the morphology and position of the disc as well as the osseous elements of the temporomandibular joint is quite difficult due to the complex anatomy and lateral approach required for surgery. In deference to earlier studies by Helms et al. and Cirbus et al. which compared

results obtained with MRI and surgical findings on patients, a non-biased correlation between MRI, conventional techniques and surgery is not possible among patients.(44,45) This is due to the fact that only certain TMJ disorders are treated surgically and a positive CT or arthrogram is generally obtained prior to a surgical procedure. A study regarding the accuracy of these techniques on clinical patients would disregard the normal situation and any case in which a false-negative diagnosis was made. For these reasons, we have chosen to investigate the diagnostic accuracy of these techniques based on postmortem evaluation.

REVIEW OF THE LITERATURE

Incidence of Dysfunction

Disorders of the temporomandibular joint are quite prevalent in today's society. Epidemiological studies have reported symptoms of general joint dysfunction in 57 to 88% of the population between 15 and 74 years of age.(8,46,47) Significant symptomatology has also been identified in children and adolescents.(48-50) More recent longitudinal studies have clearly demonstrated an increase of symptoms with age.(51-53)

Clinical signs of dysfunction such as clicking have been reported by Nilner and Lassing and Grosfeld and Czarnecka to be present in 13% and 15% of the children between the ages of 6 and 15 respectively.(50,54) In a similar study on adolescents between 15 and 18 years of age, the same authors reported joint noise in 32% of the individuals.(48) Agerberg and Carlsson reviewed 1106 inhabitants from Umea, Sweden between the ages of 15 and 74 and revealed that 39% experienced joint noises.(8) Hansson and Nilner also studied an adult group (20-65 years) of 1069 white-collar workers and tradesmen in Sweden and found crepitation or clicking in 65% of the persons examined.(47)

These epidemiological studies clearly reveal signs of temporomandibular dysfunction in a significant number of young

individuals. The incidence has also been shown to increase appreciably with age to include over one-third of the adult population. The extent of this dysfunction must be recognized and understood in order to apply the appropriate treatment modalities.

Disc Position and Morphologic Changes

The objective clinical finding of clicking within the temporomandibular joints has been investigated by multiple authors who have suggested various theories for its origin. (55-57) Ireland, in 1951, described clicking which occurred just prior to complete closure of the mandible as due to the condyle slipping behind the posterior edge of the disc which then becomes displaced.(58) This is followed during the opening or protrusive phase with another click which occurs at a different point than the closing click. This noise occurs as the condyle slips beneath the posterior band of the disc so that the disc is once again properly interposed between the condyle and the eminence. Farrar coined the phrase, reciprocal clicking, to describe these events.(21)

This view of clicking as associated with anterior displacement of the articular disc has been supported by multiple authors using arthrographic techniques. (20,21,30,59,60) The most convincing studies done on the mechanics of clicking within the joint were reported by Isberg-Holm and Westesson.(61,62) In their research on five

temporomandibular joint autopsy specimens, they utilized arthrography in combination with cineradiography and sound recording to observe the movement of the condyle and disc associated with clicking.(61) They found that the sound occurred, both during protrusion and retrusion, as the condyle slipped under the posterior band of the disc. This movement was associated with a bulge in the condylar path as demonstrated by Farrar and McCarty.(21)

In a similar follow-up study, Isberg-Holm and Westesson used high speed cinematography and sound recording on nine partially dissected autopsy specimens.(62) With this technique using 500 frames per second, the origin of the clicking sound could be identified. The sound was recorded at the instant the condyle contacted the temporal articular surface after passing under the posterior band of the disc. At this point either the disc or posterior attachment tissues were positioned between the two bone surfaces. Four joints studied without the presence of clicking exhibited smooth, synchronized movement between the joint components.

These studies confirm the importance of clicking as a sign of abnormal joint function and morphology. However, clicking is not always caused by anterior disc displacement with reduction and the absence of joint noise does not necessarily indicate a normal joint. A thorough understanding of the pathophysiology of the joint in relation to both the

osseous and soft tissue components is thus a necessity in arriving at an appropriate diagnosis.

Besides anterior disc displacement with reduction, Rohlin, Westesson, and Eriksson have cited a variety of other causes for clicking of the TMJ.(63) These included local thickenings of the articular surface layers, significant macroscopic remodelling and deviation in condylar form.(64-66) Of the five autopsy specimens studied by Isberg-Holm and Westesson for clicking, one displayed a non-reciprocal click which occurred at the same location upon protrusion and retrusion.(61) Upon dissection this was discovered to be due to a bone spicule on the superior surface of the condyle which fit into a depression on the inferior surface of the disc. In this instance, the joint noise was not associated with an anterior displacement of the disc.

Miller et al. reported on a sample of 108 TMJ's examined by arthrotomography with clinically audible clicking.(67) They found that 16 (15%) of these had anteriorly displaced discs without reduction despite the joint noise. In these patients, it was concluded that the clicking was a result of the frictional impact between the degenerated condylar surface and the deformed displaced disc. Due to the essentially normal range of mandibular motion without deviation in these clicking patients, a clinically based diagnosis of disc displacement without reduction would have been virtually impossible. These studies demonstrate that audible clicking

does not necessarily imply displacement or reduction of a disc. Similarly, the absence of joint noise, as is often seen in a "closed-lock" situation, does not necessarily imply a normal joint. Clearly, further diagnostic information must be obtained when a disc displacement or internal derangement is suspected.

In a closed-lock type of internal derangement, the disc is displaced anteriorly and does not reduce to its normal position with opening of the jaw. Limitations on the range of jaw movement are produced, thus the term "closed-lock." The incidence cited for dysfunction of the TMJ based on joint noise would not have included this significant group.

As this disorder progresses, there is compressive thinning of the posterior attachment as the condyle functions on this tissue due to the non-reducing anterior displacement. This often results with eventual perforation. Joint sounds become once again apparent as the articular surfaces undergo further degeneration. Clinically, this is signified by a grating or crepitus sound within the joint on movement. The patient with crepitus typically reports a history of clicking followed by a period of no joint noise and jaw locking, and then the grinding noise begins. The natural process of bone remodelling is replaced with degeneration or arthrosis as the articular surfaces are unable to maintain the equilibrium between form and function due to the increased functional or dysfunctional load.

The progression of this disorder from clicking to degenerative joint disease is not atypical. The severity of the internal derangement is well correlated with the degree and rate of bone loss and the severity of the osseous abnormalities. (31,68,69) Westesson and Rohlin found that discs of even thickness or biconvex configuration in partially or completely anterior position were frequently associated with osteoarthritis, whereas biconcave discs in a superior position were found mostly in joints with normal articular surfaces. (18) Stanson and Baker have shown a 7% incidence of arthritis in patients with disc displacement with reduction, while a 36% incidence is found in patients with disc displacement without reduction (closed-lock). (68,69) As the disease progresses, erosions, cortical flattening, and osteophyte formations occur to the condyle and the articular eminence. (12) In a longitudinal study by Rasmussen of 44 patients with TMJ osteoarthritis, disc perforation was positively correlated to the degree of bone loss of the condyle. (14) Thus internal derangements of the temporomandibular joint appear to be a cause in the development of degenerative arthritis of the joint.

Rohlin, Westesson, and Ericksson studied the relationship between joint sounds and joint morphology using 55 fresh TMJ autopsy specimens. (63) Joint sounds were recorded during manual manipulation to full protrusion and retrusion by recording vibrations in the temporal bone using a vibration

transducer. The joints were classified as being silent, demonstrating clicking, or demonstrating crepitation based on the amplitude of the recorded sounds. The anteroposterior position of the disc and its configuration were then evaluated following sagittal sectioning of the disc while maintaining its posterior attachment to the condyle. The position of the disc was recorded as either superior, partially anterior, or completely anterior while the configuration was classified as biconcave, biplanar, or biconvex. A partial anterior position of the disc was recorded as early as 1918 by Pringle as an anterior position laterally with a superior position medially.(70) The authors also examined the articular surfaces for remodelling or arthrosis and classified perforation of the disc as arthrosis.

Of the fifty-five joints, thirty-two (58%) were silent but demonstrated signs of remodelling of the articular surfaces. Two-thirds of the silent joints had discs in the superior position while one-third (11) had anterior disc displacements. This demonstrates that a silent joint is not necessarily a healthy joint and is in agreement with clinical observations.(21,59,67) Eleven joints (20%) demonstrated clicking with partial displacement in six. The disc configuration was predominantly biplanar or biconvex. The remaining twelve joints (22%) exhibited crepitation. Most of these displayed anterior disc displacements with arthrosis of

the articular surfaces, perforation of the discs, and either a biplanar or biconvex disc configuration.

This study confirms previous findings that reciprocal clicking indicates anterior disc displacement while crepitation usually indicates perforation. (61,62,71,72) Both sounds may be regarded as indicative of abnormal joint morphology. Two silent joints and four joints with clicking also showed arthrosis, indicating that arthrosis may exist without crepitation.

When developing a diagnosis for disorders of the temporomandibular joint, the clinician must consider not only the position of the tissues involved, but also their physical state. An evaluation of the intra-articular morphology of both the osseous and soft tissue components would be valuable for a further understanding of the complex pathophysiology within the joint. Not only the presence, but the degree of deformity within these tissues should be determined. In so doing, we can put together a more complete clinical picture and determine how these changes in form and function may be related.

The relationship between disc position, morphology and joint function was studied by Westesson, Bronstein, and Liedberg. (24) Fifty-eight right TM joints were removed from fresh cadavers and studied by lower compartment arthrography. A transcranial approach was used while opening and closing movements were manually produced and the images recorded on

videotape. The presence of joint noise during movement was registered by palpation and stethoscopic examination. Following arthrography, the specimens were repositioned in what was considered to be the closed-mouth position, frozen, embedded and sagittally sectioned with a band saw. Upon examination, 17 joints displayed a normal biconcave disc in the superior position. Two other joints with discs in the superior position showed morphologic deformities. These discs were reversed in form, being thicker anteriorly than posteriorly. Thirteen joints showed partial anterior disc displacement, or complete anterior disc position in at least two sections with a superior position in the remaining sections. In 31% of these joints the discs were deformed and this occurred consistently in the portion which was anteriorly positioned. Complete anterior disc position was identified in twenty-six joints with deformation of the disc occurring in 77% of these. The most common deformation was an enlargement of the posterior band of the disc (80%). Ten (38%) of the joints with anterior disc position and reduction reduced during opening without clicking. Interestingly, internal derangement might not have been suspected in these joints clinically.(8)

This study showed that partial and complete anterior disc position was associated with disc deformation ($p < 0.001$). Deformation of the disc was also associated with perforation ($p < 0.002$) and with articular surface

irregularities ($p < 0.002$). The authors conclude that disc deformation is preceded by an anterior position in agreement with the results of a previous study by Westesson and Rohlin.(18) Therefore, they recommend early treatment to correct symptomatic internal derangements to decrease the possibility of disc deformation.

In correlating function and morphology the authors revealed that all but one of the anteriorly positioned non-reducing discs were deformed. Deformation was closely associated with disturbed joint function. The evaluation of disc morphology as well as position is therefore essential when planning treatment of internal derangements and in establishing the clinical prognosis. Thus, as is suggested by the authors, undiagnosed disc deformation may be an important explanation of the difficulties encountered in the treatment of internal derangements by splint therapy.

The biological deformation of the disc was defined by Moffett as a passive noncellular alteration in shape or profile caused by compressive loading within the joint.(19) This is in contrast to articular remodelling which is an active cellular adaptation. In their study of the relationship between internal derangements and osteoarthritis in 127 joints, Westesson and Rohlin concluded that "one event in the early development of osteoarthritis might be an altered configuration."(18) They found that deformation of the disc represented a more advanced stage than an altered position

since 50% of the discs in partially or complete anterior position as well as discs of even thickness laterally were associated with osteoarthrosis whereas 90% of the biconvex discs were so associated. Osteoarthrosis was found to be significantly more frequent when the discs were in both an altered position and configuration than in joints with either an altered position or configuration alone. Their results supported the findings of other authors that internal derangements may progress to osteoarthrosis.(13,19,21,59,73) Thus the configuration of the disc as well as its position throughout the joint compartment is a valuable piece of diagnostic information for treatment planning and prognosis.

Along with the increased deformation of the disc seen with internal derangements, histologic evidence of remodelling changes in the posterior attachment can also be found. In a histologic review of serially sectioned whole joints with internal derangements, Scapino found an increased fibrotic character of the anterior region within the posterior attachment. He stated that, "The normal pattern of collagen fibers at the union of the posterior attachment and the posterior band is replaced by a compact mass of fibers which contains fewer or none of the small vessels normally present."(16) This finding was also noted in the work of Steinhardt and Blackwood.(74-76) Blackwood concluded that the fibrosis appeared to be a remodelling due to compressive loading of the posterior attachment.

In an experimental study using Macaca monkeys, Isberg and Isacsson produced a retrusive guidance to the mandible using composite and gold occlusal restorations to study its effect on the TMJ tissues.(77) Their findings, after five weeks of retrusive function, showed that 75% of the experimental animals exhibited marked flattening of the posterior band of the disc in comparison to the anterior band in the same joint and the posterior band of the control animals. The authors noted that, "In the experimental animals the parallel collagenous fibers of the thin part of the disc continued to run parallel throughout the flattened posterior band of the disc in contrast to the controls." The anterior region of the posterior attachment was also composed of a rather dense collagenous tissue. This region of fibrosis may serve as a "pseudo-disc" in response to the compressive loading experienced during function. This histologic change may also be associated with the incompetence of the posterior disc attachment noted as a possible etiologic factor in anterior disc displacements.(78,79)

By examining the temporomandibular joint in more than just one sagittal section a more complete picture and understanding of the pathophysiology can be gained. The presence of a partially anterior disc position, as noted by Pringle in 1918 and more recently by other authors, implies a stretching or tearing of the lateral ligament with rotation of the disc around the medial attachment to the condyle.(13,18,29,70,80)

since the disc is in an anterior position laterally while often maintaining a superior position in the central and medial regions of the joint, an incorrect diagnosis would be made if just one region was examined. The incidence of this type of internal derangement has been reported among random TMJ autopsy specimens to be between 22% and 36%. (18,63,73) Westesson and Rohlin found a partially anterior disc position to be associated with osteoarthrosis as frequently as complete anterior disc position. (18) The lateral third of the joint was the most frequent location for an altered position and/or configuration of the disc. This corresponds well to the increased frequency of osteoarthrosis in this region, in accordance with the findings of Oberg and others. (12,18,66,81)

Imaging Techniques

Conventional Films: Transcranial, Tomography

In order to detect and identify these pathologic changes within the tissues of the temporomandibular joint, various radiographic techniques have been developed. The most common technique employed is the oblique transcranial radiograph. In 1936, Higley first described this technique which images one TMJ on plain film using an x-ray beam originating on the opposite side of the head. (82) Despite being inexpensive and relatively easy to obtain, this technique and its modifications have several disadvantages from a diagnostic point of view. These include an inability to detect soft tissue

changes and disc displacements, exposure to ionizing radiation, unreliable demonstration of condylar position, superimposition of structures over the area of interest, inability to detect abnormalities within the temporal component and a lack of visualization of the medial and superior positions of the condyle.(2,6,7,10,17,83-86) Several investigations have clearly shown that transcranial radiography is unsatisfactory in detecting and evaluating deviations in the position, form, and function of joint components.

Tomography (laminography) was first used by Petrelli and Gurley to image the TMJ in 1939.(87) This technique, which focuses on several selected planes within the joint-like pages within a book, has proven to be more diagnostic in evaluating the osseous elements of the TMJ. The superimposition of adjacent structures as found in plain film radiography is eliminated. This allows for improved spatial resolution and more accurate measurements of joint space. Yale et al. in 1961 reported on the use of "corrected tomograms" to correct for the horizontal angulation of the condyle and acquire a true sagittal image of the joint.(88)

Eckerdal and Lundberg reported the results of a comparative study of 29 autopsy specimens using conventional transcranial radiography, hypocycloidal tomography and cryomicrotome morphologic sectioning.(6,85) They found accordance between conventional images and the other techniques in only 10 out of 28 cases. Transcranial radio-

graphy usually disagreed with regard to the degree of joint displacements. Tomography proved to be more reliable in relation to the type and degree of pathologic change present. The selectivity, or ability to identify even small structural changes with multi-directional tomography was high in the central two-thirds of the joint. The lateral and medial peripheral sections showed blurring with tomography which is in agreement with an earlier work by Eckerdal.(89) The authors concluded that conventional transcranial radiographs reproduce only the lateral pole of the condyle which is not always representative of the joint structure and its spatial relationship, while tomography reproduces the greater part of the joint.

The literature has shown that osteoarthritic bone changes as well as disc displacements and changes in disc configuration, occur most frequently in the lateral and central thirds of the joint.(18,90) Conventional transcranial radiography may be useful in identifying the most lateral of these lesions, however, it is unable to image the superior condylar surface or correct for the condylar long axis which thus limits its general application. Lateral tomography, especially if used with complex motion-hypocycloidal movement, has proven to be the most accurate and most informative technique in identifying lesions of both joint components.(2,10,11,17,86,91) An increase in diagnostic information has resulted from the ability to more accurately measure joint space as well as the opportunity to analyze the

joint in three dimensions through serial sectioning, without the superimposition of adjacent structures.(2,10,12,89) Since tomography is limited by the blurring at the peripheral borders of the joint, the most complete hard tissue evaluation would incorporate both techniques which appear to be supplementary.(2,10,86,91)

Arthrography: Single-Contrast

These previous techniques, however useful, reveal only part of the pathophysiologic state within the temporomandibular joint. Diagnostic information regarding abnormalities of the articular disc, posterior attachment, and soft tissues within the joint are notably absent. As previously stated, these structures play a highly significant role in the pathophysiology of TMJ disorders.

In 1941, Zimmer reported the first clinical use of arthrography for the temporomandibular joint.(92) However, Nørgaard in 1944 developed a standard technique for this difficult procedure and demonstrated its value as a diagnostic tool.(25) Only limited research was done with this technique in the sixties and early seventies due to the technical difficulties and limited clinical application. In the late 1970's, renewed positive interest in accurate information on the disc resulted from some new therapeutic concepts by Farrar and the identification of anterior disc displacements and their association with the "TMJ syndrome" by Wilkes.(22,59,78,93)

During the last ten years, arthrography has been considered the "gold standard" for diagnosing internal derangements of the TMJ. The technique involves the injection of radiopaque dye into the potential joint spaces adjacent to the articular disc. Most commonly, this dye is injected into the inferior joint space using a 23-gauge needle and fluoroscopic guidance to guide correct needle placement. Static transcranial radiographs of the joint are then taken and the position of the disc is inferred by the location and shape of the injected dye. Video-tape recording of joint function is often possible with the use of fluoroscopy as discussed by Farrar, Bell and Walters.(21,94) This technique provides excellent insight into the functional relationships of the disc-condylar complex. Many variations of this standard technique have been reported (Farrar 1972; Farrar and McCarty 1979; Wilkes 1978; Katzberg et al. 1979, 1980; Westesson et al. 1980).(21,22,59,60,78,95,96)

In Nørgaard's original monograph on arthrography in 1947, he evaluated the technique based on his results of 113 arthrograms with surgical correlations in 25 patients.(25) He concluded that arthrography is a valuable diagnostic tool for the TMJ. Later authors who simulated Norgaard's technique (Campbell 1965; Agerberg and Lundberg 1971; Toller 1974), found it to be of great diagnostic or research value but technically too difficult for routine use.(26,97,98) The practical use of single-contrast arthrography was greatly improved following the development of an image intensifier

and a new understanding of the position of the articular disc as it relates to the pathophysiology of the joint.(59,78)

In 1978, Wilkes published two articles on arthrography with associated tomography of the joint, to identify the anatomical and radiographic evidence associated with the clinical diagnosis of TMJ pain-dysfunction-syndrome.(59,78) His technique and observations made the use of arthrography much more reliable and practical. Based on the examination and treatment of 400 cases, he described the position of the articular disc as it related to changes in contour of the radiopaque joint spaces during movement. His technique required the cannulation of both the superior and inferior joint spaces simultaneously under fluoroscopic control using a 2-gauge venocatheter. Static tomographic images of each joint were then taken at four stages in the opening cycle. A tomographic technique was necessary for quality diagnostic films due to the injection of dye into both compartments. The superior joint space overlaps and would obscure detail in the inferior space if conventional transcranial imaging were attempted. He found that the adjustment of fluid volumes during the procedure and avoiding extravasation of contrast material were critical factors in obtaining optimum image quality.

Farrar and Murphy each used a technique in which the dye is injected into the lower compartment followed by fluoroscopic evaluation and transcranial imaging.(21,99)

In a classic study, Farrar, drawing upon the earlier works by Wilkes, correlated the normal and abnormal relationship of the articular disc to the mandibular condyle, with the images produced by inferior joint space arthrography. (21,59,78) He also related the characteristics of the condylar paths during translation to the presence or absence of internal derangements. He concluded that the correlation between arthrography and measurements of condylar paths showed that reciprocal clicking and locking (limitation) are frequently caused by internal derangements of the TMJ, characterized by anterior displacement of the disc associated with posterior displacement of the condyle.

Murphy stated that he preferred arthrography of the inferior joint space because a single injection is less uncomfortable than two, the greatest amount of diagnostic information is obtained by studying the relationship of the condyle to the inferior surface of the articular disc, and because contrast material in the superior joint space overlaps and obscures the inferior space. A one-compartment injection of contrast material also helps to identify perforation of the disc or posterior attachment tissues.

Rasmussen also used a one-compartment technique by injecting contrast medium into the superior joint space. (100) Despite the ability to indirectly identify the position of the disc, its shape or configuration cannot be disclosed by arthrography with injection of contrast into only one compartment. The delineation of disc configuration is essential

for complete diagnosis and prognostication, but would require contrast in both the upper and lower joint compartments.

The use of tomography with arthrography was first used in a few cadaver examinations by Nørgaard in his original work. In 1965, Campbell and Frenkel, in separate studies, reevaluated the use of arthrotomography and introduced it for clinical examination. (98,101) Frenkel also reported on the difficulties with interpretation of arthrograms taken with oblique transcranial radiography. The superior joint space overlaps the inferior space in both a medial and lateral direction. Thus, in order to avoid the superimposition of joint structures into a single plane, a tomographic technique is used to focus on details within one plane while blurring the adjacent planes. It is also possible to study different sections within the joint rather than just the lateral pole as is seen with the transcranial approach. This is important due to the variability in shape and position of the disc within different regions of the joint, as reported earlier.

Katzberg, Dolwick, Helms, et al. reported on the use of arthrotomography together with a single, inferior joint space injection technique. (22) In a related article, Dolwick et al. reported on the use of this arthrotomographic procedure in 35 joints of patients experiencing chronic pain and dysfunction. (30) Based on evidence that derangement of the soft tissue structures of the joint may be an important factor in causing TMJ dysfunction, Dolwick used this technique to demonstrate its

applicability in differentiating organic joint disease from functional disorders. Five arthrotomograms were normal as exhibited by a contiguous relationship between the radiopaque inferior joint space and the surface of the condyle in the closed-mouth position. As the condyle translates anteriorly with an opening movement, the dye fills the joint space posteriorly in a normal fashion. Thirty arthrograms were evaluated to be abnormal revealing a prevalence of internal derangements and soft tissue organic disease in these chronic dysfunction patients. The most common abnormality observed was anterior disc displacement without reduction. This occurred in 11 joints with an additional three showing anterior dislocation together with perforation. Ten other arthrotomograms exhibited "anterior subluxation," or anterior disc displacement followed by reduction on opening. Other radiographic findings included perforation, tenting, adhesions, and signs of degenerative changes. It was the opinion of the authors that arthrography which incorporated fluoroscopy for guidance and tomography to eliminate the super-imposition of structures, has "minimized" the technical difficulties, moderate discomfort, and interpretive difficulties present with the use of transcranial arthrography.

In a similar article by Katzberg et al., 104 arthrotomographic examinations were done on chronic dysfunction patients who were unresponsive to conservative methods of therapy. (60) The authors presented detailed clinical and arthrotomographic evidence of disc dysfunction in 89 patients with surgical

confirmation in 40 joints. Of the 91 joints with reported diagnoses, 26 had no abnormality detected. Twenty-three joints had arthrotomographic features consistent with a diagnosis of anterior disc displacement with reduction, while thirty-one joints showed displacement with non-reduction of the disc. Perforations were identified in eleven cases. However, two of these were surgically proven to be iatrogenically-caused false-positive examples due to improper needle placement. The site of perforation was most frequently within the posterior attachment, while one occurred in the central band of the disc.

Transcranial arthrography and upper joint space arthrotomography were evaluated as alternatives to lower joint space arthrotomography but were found to be inconsistent and often non-diagnostic. Katzberg also experimented with the use of anteroposterior arthrotomograms in the closed-mouth position to evaluate the mediolateral location of the displaced disc. His study showed that in cases of disc displacement without reduction, the disc was most often positioned anterocentrally or anterolaterally. Prior to the time of this publication, radiographic evaluation of the osseous joint emphasized transcranial or tomographic images. The common absence of radiographic abnormalities was accepted as objective criteria for a functional etiology of TMJ disorders.(102,103) The findings of Katzberg et al. suggest a renewed emphasis on the role of the articular disc in function and dysfunction, and a new

awareness of the organic etiology of TMJ disorders due to the increased diagnostic capabilities with arthrography.

While single contrast arthrography has significantly improved our understanding of the pathophysiology of organic joint disorders, several frequent complications and disadvantages must be noted with the technique. Since it is an invasive procedure, the technique is quite difficult requiring significant operator experience and expertise. When dye is injected into the potential joint spaces, moderate to severe pain is often associated with overdistention of the joint compartments. (99,104) If contrast material extravasates extracapsularly into the surrounding soft tissue, pain is immediate and sometimes severe. A sodium free contrast agent is less painful for the patient if extravasation should occur. One must also recognize that the anatomy visualized with arthrography is altered from the true tissue relationships due to the fluid injected which lubricates the joint and distends the joint compartments while displacing various soft-tissue components. It is not uncommon for patients to experience a resolution of an early click together with an apparently normal arthrogram following the initial injection of contrast agent.

Since single-contrast arthrography does not produce a direct image of the disc, its position is inferred by the flow of contrast medium during movement and the length of the anterior recess of the lower compartment. (105) A recent study of healthy subjects demonstrated substantial variation in the length and

shape of the anterior recess and indicated that assessment of disc position based solely on the length of the anterior recess entailed a risk of a false-positive finding in up to one-third of the examined cases.(106)

Arthrography is also complicated by chronic degenerative changes which restrict the joint space. Katzberg et al. reported an inability to successfully opacify the inferior joint space in five patients.(22) Following a surgical evaluation, one patient was proven to have had fibrous obliteration of the inferior joint space from prior mandibular fracture and hemarthrosis. Lynch and Chase also reported difficulty with opacification due to a reduction in the size of the joint space with capsular thickening and with severe osseous spurs or osteoarthritis.(104) This is especially common in post-surgical arthrograms if menisectomies have been performed.

Since arthrography is an invasive procedure, the needle placement itself is often associated with complications. Most techniques recommend advancing the needle until contact is made against the posterior-superior margin of the condyle. This is often painful despite anesthesia. The needle is then slid posteriorly off the condyle as the patient opens the mouth widely. This can be associated with excoriation or eburnation of the condylar articular surface.(107) This damage is difficult to identify and document without a surgical examination or histologic evaluation.

Improper needle placement is also frequently associated with a false-positive diagnosis of perforation.(104) Farrar and McCarty reported on perforations in the posterior ligament in seven out of forty-four arthrograms performed.(59) They commented that, "The probability of perforation being an artifact cannot be completely discounted, because it is necessary to pass the cannula through the superior joint space in order to place it into the inferior joint space." Katzberg et al. diagnosed a perforation in eleven patients by arthrotomography within their study.(22) Two of these were surgically proven false-positive examples of perforation due to inadequate care in needle positioning and manipulation. The true number of false-positive diagnoses of perforation is difficult to determine without a prospective study since surgery is not performed on all patients with a positive diagnosis and because it is difficult to examine the joint completely even with a surgical approach. Delfino and Eppley did a prospective study of 287 patients who were to undergo TMJ surgery for disc dysfunction, using tomography and inferior space arthrography with fluoroscopy.(28) They reported a false-positive diagnosis of perforation in 16/110 or 15% of the cases!

Finally, another disadvantage which is inherent with the technique is the radiation dosage. This can be quite high, particularly to the lens of the eye and thyroid gland, depending on the amount of fluoroscopy used and whether tomograms are obtained.(31,35)

Attempts have been made to correlate arthrographic and surgical findings to determine the accuracy of this technique. Reports in the literature have estimated the accuracy to be between 81% and 97%. (26,27) Bronstein et al. reported on their experience with 81 arthrotomograms in 59 patients who were unresponsive to conventional therapy for their TMJ disorders. (27) A surgical correction was then performed on thirty-four of these symptomatic joints. Their findings at surgery confirmed the arthrographic diagnosis of anterior disc displacement in all but one case. This resulted in a diagnostic accuracy of 97%. However, in this study those symptomatic cases which had an arthrographic diagnosis of normal or of an early disc displacement with reduction did not receive surgical treatment. This results in a bias toward more advanced pathology.

It is obviously difficult to conduct a systematic correlation between arthrography and morphology in live patients because only selected types of pathology are treated surgically. (24) Also, a positive arthrogram is usually a prerequisite for a surgical procedure. Therefore, the identification of a false-negative arthrographic diagnosis is unlikely. Similarly, the correlation in cases with less severe pathology is limited. During a surgical procedure of the temporomandibular joint, there is limited access to the joint in all its dimensions. Visibility is often restricted which thus limits the evaluation of disc position and configuration in all but the most lateral regions.

Westesson et al. recognized these difficulties and decided to use autopsy specimens to study the diagnostic accuracy of transcranial arthrography in comparison with cryosections of the joint.(24) Fifty-eight right temporomandibular joints from human cadavers were studied using fluoroscopy and inferior joint space arthrography with a transcranial projection. Opening and closing movements were manually produced and recorded on videotape. After closing the condyle into the closed-mouth position, the specimens were frozen and cryosectioned for correlation. The cryosections were studied in each of five medial to lateral locations, while the arthrograms were evaluated using both the transcranial and fluoroscopic radiographs. Since these latter techniques concentrate on the lateral regions of the joint, one might expect less diagnostic information to be available with these radiographs in comparison with the cryosections. The arthrographic diagnosis was confirmed in 47 out of 58 joints for both disc position and perforation. The position was misinterpreted in nine joints and perforation was misinterpreted in two others. Four joints were misdiagnosed on the arthrogram as being normal when in fact, three had partial anterior disc displacements. More importantly, five joints were misdiagnosed as having an anterior disc displacement, while the cryomicrotome sections showed a superior disc position with lateral or medial deformation. Most frequently this involved a thicker anterior band of the disc (reversed configuration). This is highly significant

since a positive arthrographic diagnosis in a patient with chronic TMJ dysfunction may warrant a surgical procedure. Two other joints with diagnosed perforations could not be confirmed with sectioning. This results in an 81% accuracy with regard to position and perforation of the disc and an 84% accuracy with regard to the position alone.

The arthrographic technique using fluoroscopy and transcranial projection is one of the most widely used procedures since it is relatively easy to perform clinically. However, this well-designed study points out several significant limitations. Besides the disadvantages with arthrography that have been previously discussed, this technique is unable to differentiate the lateral part of the joint from the medial due to the projected overlap of structures. The use of tomography instead of transcranial radiography would improve this differentiation by allowing an evaluation of the joint in multiple planes. This would also help to identify the partial disc displacement where the disc is rotated around its medial attachment to the condyle. This relationship is seen most frequently in patients with an anterior disc displacement with reduction.(24) These techniques which utilize a one-compartment injection of contrast agent are also unable to determine the morphology of the disc. This information regarding the configuration of the disc in the medial, central and lateral portions of the joint, are essential for a complete

understanding of the stage of derangement, determination of appropriate treatment and prognosis for the patient's response.

Arthrography: Double-Contrast

In an effort to gain more complete diagnostic information regarding the soft tissues of the joint, a technique for double-contrast examination of the temporomandibular joint was described by Arnaudow et al. in 1968 and Arnaudow and Pflaum in 1974.(108,109) Westesson et al. modified the technique following experimentation on autopsy specimens and reported their findings in 1980.(96)

The technique involves the injection of approximately 0.3-0.6ml of water-soluble non-ionic iodine contrast medium into the lower joint space by a cannula under fluoroscopic guidance. Opening and closing movements are then recorded on videotape. Following this lower joint space, single contrast examination, the contrast medium is then aspirated and a cannula is placed in the superior joint space and about 0.3ml of contrast is injected. After this dye is distributed with condylar movement, about 0.5-1.0ml of air is injected into both joint compartments and arthrotomograms are taken. The cannulas are left in place to allow the air to move freely in and out of the syringes during condylar movement and to allow for proper adjustment of fluid and air volumes during the radiographic procedures.

After applying the technique to autopsy specimens, Westesson then examined 105 patients with suspected internal derangements.(110) Difficulty was reported in cannulating the joints in 16 cases. In nine cases only the lower compartment was cannulated and in two cases only the upper compartment was possible. In five other cases, neither compartment could be cannulated on the first attempt. The most distinct arthrograms were taken immediately after the contrast material was injected since a gradual diffusion of the media occurred with time. The disc configuration was obscured at maximum intercuspation due to the narrowness of the joint in this position. This was corrected by taking tomograms at a slightly opened-mouth position.

Twenty-seven examinations revealed a normal superior position and biconcave configuration. Forty-one joints were diagnosed as having a partial anterior disc displacement with the disc forward laterally while the position medially remained normal. Twelve others showed complete anterior displacement with reduction. An interesting finding in Westesson's clinical material was the presence of two patients with anterior disc displacements with reduction, where the condyle displaced anteriorly to the anterior band of the disc and caused a folding of the disc and locked open position. Bronstein et al. reported on a similar case using single-contrast arthrography.(27)

Forty-eight examinations revealed anterior disc displacements without reduction. Eleven of these cases had

associated perforations which were diagnosed during the fluoroscopic portion of the exam. The double-contrast technique also revealed the configuration of the articular disc at different depths within the joint.

It is the opinion of the author that this technique is most diagnostic in the central two-thirds of the joint due to the limitations imposed upon it by the tomographic technique. Tomography was shown by Eckerdal to be limited in its reproduction of the lateral and medial parts of the joint.(2) Since a diagnosis of anterior disc displacement with reduction is frequently associated with an oblique disc position, evaluation of the lateral region of the joint is essential. Westesson has recommended the combination of transcranial arthrography and double-contrast arthrotomography in order to more completely examine the tissues of the joint and to avoid the false-negative findings which can occur with either technique alone.

Westesson and Bronstein studied both the lower space, single-contrast technique and the double-contrast technique in comparison to cryosections of 58 fresh temporomandibular joints.(105) As both techniques examine the joint from a different perspective, the cryosectional findings were used as the morphologic standard. The position of the disc was correctly identified in 84% of the joints using the single-contrast technique and in 91% of the cases using double-contrast arthrography. The presence of a perforation was correctly identified in 97% of the joints with single-contrast arthrography

and in 93% of the joints with the double-contrast technique. The authors found no statistically significant difference between these techniques with respect to these findings. Had the authors used the two techniques in combination with each other, there would have been a significant reduction in the number of false-negative and false-positive diagnoses for a much higher accuracy.

The authors conclude that video tape recording of lower space, single-contrast arthrography was superior in demonstrating joint dynamics and is the optimal imaging modality for patients with functional disturbances i.e. clicking and intermittent locking. Dual space, double-contrast arthrotomography was superior in depicting the soft-tissue anatomic features of the joint. This technique was easier to interpret and would reveal information about the configuration of the disc, the location and extension of perforations and the status of soft tissues in the different mediolateral regions of the joint. Double-contrast arthrotomography is the preferred technique when information about morphologic alterations is more important than that regarding joint dynamics. An example of this would be in the planning of surgical treatment. The drawbacks of the double-contrast technique are the higher radiation exposure, the greater technical difficulty, and the increased time required for the examination.

The diagnostic accuracy of double-contrast arthrotomography was also studied independently by Westesson and Rohlin and compared to autopsy specimens.(23) Sixty-one fresh temporo-

mandibular joints were acquired. The arthrotomographic procedure was unsuccessful in 13 cases due to insufficient amounts of contrast material, capsular leakage of injected air, unsuccessful injection into the upper joint compartment, and extensive extravasation of contrast material. These joints were eliminated from the study but may reflect a bias toward cases which were less technically difficult and showed less joint space constriction due to adhesions, etc. This limited the study to 48 specimens. Following arthrotomography, thirty-six joints were studied by gross dissection while the remaining twelve were studied following cryosectioning.

The arthrotomographic diagnosis was confirmed in 41 out of 48 joints for an accuracy of 85%. The configuration of the disc was misinterpreted in three joints, the position in three joints, and both the configuration and position in one joint. Two of these errors were due to incorrect observations and resulted in false-positive findings. The other five were due to limitations in the tomographic reproduction and led to false-negative reports. Supplemental transcranial arthrography is recommended to improve visualization of the lateral region. The authors also noted a difficulty in determining the disc position radiographically in cases with a biplanar or flattened disc. The posterior band of the disc is not easily detected in these situations with an arthrographic technique since it relies on an outline of the tissue rather than a direct image of the disc.

single-contrast arthrography and double-contrast arthrotomography are thus seen to be complementary with a different diagnostic emphasis for each technique. In studies which are well correlated with the morphologic anatomy, single-contrast, lower space arthrography has been shown to have an accuracy between 81 and 84% while double-contrast techniques have a reported accuracy of 85 to 91%. There are advantages and disadvantages relative to each procedure individually, while both techniques have complications associated with their invasiveness and radiation exposure.

Computed Tomography

Due to the inherent technical difficulties with arthrography, the frequently associated pain and most importantly the invasiveness of the procedure, consideration has been given to other radiographic techniques to evaluate these joint tissues. In the early 1970's, Haunsfield introduced "computerized transverse axial scanning (tomography)." This system has the capability to differentiate subtle tissue densities. Because of this, non-osseous structures of the TMJ can be seen radiographically without the need for dye injection.

The technique involves the use of ionizing radiation in a circular fashion around a subject.(111) The photons of radiation, after passing through the patient, are collected by detectors and their intensities are measured. The computer then calculates a density for each point on a circular image

and then assigns a relative shade of gray to each. This information is then displayed as a series of tomographic slices 1.5mm thick. Initially the data was gathered in only the axial plane and thus was termed computerized axial tomography (CAT). Structures which are best visualized along a different axis, such as the temporomandibular joint, require computer reconstruction of the data on a different plane. Direct sagittal scanning eliminated the need for computer reformatting and thus produced greater resolution. Routine radiography produces superb spatial resolution but poor contrast resolution. Since CT produces a tomographic slice through the specimen, there are no overlying tissues to obscure bony detail. Computerized tomography maintains good spatial resolution for the identification of bone tissue, while excellent contrast resolution allows for soft tissue differentiation. The technique also permits simultaneous acquisition of both soft tissue and bone images from one radiographic exposure through computer manipulation.

The application of computed tomography to the TMJ was introduced by Saurez et al. in 1980.(112) Several other authors reported preliminary results as the technique developed and was modified.(62,113-115) Two techniques have been described for imaging the temporomandibular joint. Helms, Thompson and others use a technique where multiple images taken in an axial plane are reconstructed by the computer in the sagittal plane.(31,33,113) Manzione and others have described a technique

where direct sagittal images of the joint are obtained.
(32,34,35,115)

Helms et al. reported on the use of computed tomography in 200 patients suspected of having internal derangements. (113) seventy-five cases were later correlated with arthrographic or surgical findings. Helms' technique emphasized a single series with the mouth partially opened to 18-20mm. This was done to accentuate the tissue directly anterior to the condyle for better identification. A typical scan of 15-20 sections required approximately fifteen minutes. At least six sagittal reconstructions at different positions were then computer generated. The authors state that in the majority of the cases, the disc could not be identified on the reconstructions without the use of the "blink mode" (GE trade-mark). This technique allows the operator to highlight tissue within a particular density range. Since the articular disc is only minimally increased in density over the surrounding tissues (i.e. lateral pterygoid muscle and tendon), it is difficult to see without the blink mode. Disc displacements, when identified, were graded based on the amount of soft tissue density appearing anterior to the condyle. The authors suggest caution when using the blink mode as too high a setting could artificially make a displaced disc appear normal.

Arthrographic confirmation was obtained in eighteen patients. Using arthrography as the standard, seventeen cases were in agreement while one case produced a false-negative CT

finding. This case was later re-evaluated using the CT data and found to be definitely abnormal. The use of too-high a blink mode setting had masked the presence of a disc displacement. The accuracy of CT in relation to the arthrographic findings was 94%. Fifty-seven patients had subsequent TMJ surgery and confirmation of the CT diagnosis was made in 56 cases for an accuracy of 98%. One case displayed false-positive evidence of an anterior disc displacement which appeared normal during the surgical procedure. The authors concluded that CT is noninvasive, nonpainful, highly accurate, and requires a radiation dose which is less than that needed with arthrotomography.(117,118) However, they advised that a diagnosis of a "mild" displaced disc should be viewed with caution and close clinical correlation should be sought. Despite the high recorded accuracy of this technique, it is also important to point out that nearly all (88%) of the cases with surgical correlation had anterior disc displacements in the moderate to severe category. This biased the interpretation of their results toward cases with more significant pathology. The determination of an anterior disc displacement is made by a rough evaluation of the amount of tissue with an increased density, anterior to the condyle. Little definition is available about either the posterior edge of the disc or its configuration.

Thompson et al. employed several computer software modifications to study high-resolution computed tomography in 43 patients.(33) Fifteen cases were also correlated with

arthrotomographic or surgical findings. In this small series, the CT diagnosis was confirmed by arthrotomography in thirteen cases. Two cases presented false-positive findings of displacement while the arthrotomograms revealed a normal joint anatomy. In this study, the CT accuracy for viewing a dislocated articular disc was approximately 80%. The authors felt that the density of the discs varied considerably so that they were not seen in some patients with dislocation. Similar results were reported by the same authors in a different study which compared computed tomography and double joint space arthrotomography in 18 joints. The CT results were confirmed in 16 cases with two false-positive reports of displacement for an accuracy of 80%. (119)

Some researchers have preferred a direct sagittal scan which provides improved spatial resolution over the reconstructed images since the scan is done directly in the plane of interest. (32,35) The images of the disc generated using sagittal reconstruction methods are computer generated estimates of the size, shape, and location of the true disc and are thus somewhat artifactual. (120) The reconstructed sagittal images are degraded by any slight motion of the patient or condyle, have poorer spatial resolution, show limited bone detail, and require longer examination and computer time according to Hoffman et al. (120)

Manziona et al. emphasized the use of direct sagittal CT imaging which requires special care in proper head positioning. (32) Their study involved a prospective comparison

of direct sagittal CT and arthrotomography in 51 joints. A correlation of CT scans with anatomical sectioning was also studied in four cadaver joints. The four cadaver joints all had a normal disc position which confirmed the CT findings. A low-density area comprised of fat-containing connective tissue was identified in both the anatomic sections and in several CT images. The authors designated this tissue as the "lateral pterygoid fat pad" and identified it as existing between the superior and inferior bellies of the lateral pterygoid muscle. The position of this tissue serves as the anatomical basis for detection of internal disc derangements on a sagittal CT scan, since it is usually seen just anterior to the disc.

Arthrotomography of the inferior joint space was assumed to represent the true status of the disc and was used to correlate with the direct sagittal images in 51 joints. Five joints (10%) were classified as indeterminate using CT since the disc could not be adequately identified. Arthrotomography revealed all five to be false-negatives, with three joints having an anterior disc displacement with reduction and two showing displacement without reduction. Surprisingly, the authors eliminated these cases from the results used to determine accuracy!

Of the remaining 46 joints, 10 were determined by CT to have a normal disc position. Arthrography confirmed this position in 9 joints. The other case was shown to have an anterior disc displacement and thus a false-negative diagnosis with CT. In 13 cases, CT demonstrated anterior disc displacement

with reduction which was confirmed by arthrography in 12. The remaining case showed a false-negative CT result with no disc reduction on opening. Twenty-three cases were determined by CT to have anterior disc displacements without reduction. These were confirmed by arthrography in all but one case which showed reduction with opening and a false-positive CT finding. The study also showed that direct sagittal CT was very accurate for demonstrating bony anatomy and degenerative joint disease.

Manziona et al. determined the overall accuracy of CT in determining disc position as compared to arthrotomography to be 94% (43/46). If we were to include in this the five cases which were eliminated because they had indeterminate CT images, the accuracy would be 84% (43/51). This is similar to the accuracy reported by Thompson et al.(33) The authors point out, however, that in two cases in which CT identified a different type of internal derangement, "it did correctly indicate that the meniscus was abnormal." Also, in the third case which was reported as normal with CT, it is possible that the disc was in a reduced position at that time prior to the arthrogram. The CT acquisitions took 10-15 minutes, or one-third the time needed for arthrotomography. Bone and soft tissue information were gathered simultaneously and noninvasively, eliminating the need for plain tomography.

Manco et al. also performed a prospective study of 454 patients thought to have internal derangements using direct sagittal computed tomography.(34) Seventy-one of the 905 joints

studied were subsequently examined using inferior space arthrotomography and/or surgery. The CT technique described by Manzione et al.(32) was used with the addition of the "blink mode" technique described by Helms et al.(31)

Emphasis was placed on the position of the "lateral pterygoid fat pad" for determining the disc position. Scans were taken in both the open and closed mouth positions. The presence of internal derangements were also correlated with evidence of degenerative joint disease using the CT bone algorithm.

As has been reported, osteoarthritis is often associated with internal disc derangements. Manco et al. found that the overall incidence of degenerative joint disease in joints with internal derangements was 19.1%. This compares well to a study by Katzberg et al. which found an incidence of 22%.(121) The ability of direct sagittal CT to evaluate osseous structures as well as to identify the position of the disc, is an important advantage of this technique according to the authors.

The accuracy and sensitivity of the direct sagittal CT technique in their series correlates well with the findings of Manzione et al.(32) Manco et al. reported five false-negative and four false-positive CT results as compared with the arthrotomographic and surgical findings. This resulted in an accuracy of 87%. The authors noted that anterior disc displacements that do not have a high density and do not distort the lateral pterygoid fat pad are difficult to

differentiate from surrounding muscle tissue and will produce a false-negative result.

Direct sagittal CT scanning offers several advantages over CT with sagittal reconstructions. Greater spatial resolution and improved osseous detail are found with direct sagittal CT in return for a more difficult patient positioning technique and greater risk of radiation exposure to the lens of the eye. Both techniques have a primary advantage over arthrography by being noninvasive. Osseous and soft-tissue structures can be simultaneously evaluated in less time, while the radiation dose is lower than that required by either arthrography or arthrotomography.

Despite the many advantages with computed tomography, the technique still produces only limited soft tissue resolution. Disc position is often determined by the surrounding tissue since the whole disc cannot be identified. The location of the posterior band of the disc, which is most useful in determining the position of the disc relative to the condyle and fossa, is not visible. The important diagnostic information regarding the configuration of the disc is also limited at best. Computed tomography is also unable to identify perforations or provide a "real-time" evaluation of disc dynamics like arthrography can. But above all else, the major advantage of CT over arthrography for soft tissue identification is patient acceptance.

Magnetic Resonance

Despite the significant role that radiographic techniques such as transcranial films, tomography, arthrography, and computed tomography have had in developing current concepts of the pathophysiology and normal states of the TMJ, all of these modalities suffer limitations due to the required use of ionizing radiation. Magnetic resonance imaging (MRI) represents a radical departure from conventional radiography. A radiographic image is produced as a potentially harmful x-ray beam passes through tissue and is attenuated according to the density of the tissue. With MR, the signal originates within the body in response to a very strong magnetic field (40,000 times that of the earth) which is created to excite the protons of hydrogen atoms within a tissue. A brief description of the physics of magnetic resonance may provide some insight into the interpretation of the images.

The principles of nuclear magnetic resonance were first described by two researchers working independently, Bloch and Purcell.(122,123) Their results were published almost simultaneously in 1946 and jointly earned them the Nobel Prize for Physics in 1952. These principles have been used in NMR spectroscopy in the field of analytic chemistry for some time. In 1973, Lauterbur demonstrated the first practical two-dimensional image by applying a field gradient along an object in a number of different directions.(123) These multiple one-

dimensional images were then combined by a computer to give a two-dimensional projection.

In clinical MRI studies, the nucleus (proton) of the ^1H atom is most frequently used since Hydrogen is the most abundant element in all living systems, primarily in the forms of water and fat. It also has the largest magnetic moment which provides excellent NMR characteristics by producing a much stronger signal. The next most favorable nucleus to the proton is phosphorus-31 (^{31}P), which offers insight into basic metabolic processes. Each hydrogen proton within tissue has a magnetic moment due to its spin. These magnetic moments are randomly aligned until they are placed within an external magnetic field, such as a MR scanner. The magnetic poles of the hydrogen protons then line up parallel to the external field. If at this time, a radio frequency pulse is applied using a transmitter coil, the protons will absorb energy and begin to resonate or "precess" around their axis. When the radio frequency pulse is no longer applied, the protons release their built-up energy and return to their alignment in the static magnetic field. This "relaxation" energy signal is emitted in the form of a second radio frequency wave which can be detected by a surface receiver coil. These signals are processed by a computer which generates an image based on the spatial differences of the signals. The density of resonating ^1H proton nuclei in a tissue will influence the contrast between tissues. The relaxation processes of the nuclei are characterized by time constants T_1 and T_2 . These

parameters are distinct and characteristic to a particular tissue. T_1 is the relaxation time constant expressing the effect of the environment on the ^1H nucleus with regard to the transfer of energy. T_2 is the relaxation time constant expressing the effects of nuclei upon each other in relation to the exchange of energy. The contributions of each of these parameters to the appearance of the MR images can be altered by varying the radio frequency pulses, thereby allowing for greater differentiation of tissue types.

Since magnetic resonance incorporates extraordinarily high magnetic fields with a radio frequency (RF) field, some questions have arisen regarding possible adverse effects on normal biologic processes. Several in vivo studies have been performed at various magnetic and RF field strengths to evaluate this effect. Wolff et al. examined human lymphocytes and Chinese hamster ovary (CHO) cells for cytogenetic damage manifested as either chromosome aberrations or sister chromatid exchanges (SCEs). (38) This constituted an extremely sensitive test for genetic or cellular damage. They used a magnetic field strength of 2.35 Tesla and a 100-MHz radio frequency emission as limits well beyond that currently used in a clinical setting. After twelve and one-half hours, no increase in either chromosome aberrations or SCEs, were noted in human lymphocytes or exponentially growing CHO cells following MR exposure. These findings confirmed similar studies performed at lower magnetic

field and radio frequency strengths as well as a microbial assay performed on bacterial strains.(36,37,124)

Geard et al. compared the effect of magnetic resonance and ionizing radiation on mouse cells using even longer exposure times (17 hours) and higher field strengths (2.7 Tesla).(40) He concluded that unlike ionizing radiation, magnetic resonance did not result in either oncogenic or cytogenetic damage under the limits of this study.

The potential effects of magnetic resonance on mammalian ocular tissues was examined by Sacks et al.(39) The eye was chosen due to its well-documented history as a sensitive indicator of ionizing radiation effects. They exposed rats to a magnetic field of 2.7 Tesla and radio frequency pulses of 29mHz at 800ms intervals for six hours. Autoradiograms and cytopathologic analysis over a two-year follow-up period demonstrated that there were no discernable effects on the rat eye.

These prior studies confirm that magnetic resonance has not been shown to have any deleterious effect on biologic tissues under the parameters studied. There are however, several clinical considerations which should be considered. The British National Radiological Protection Board reviewed the effects of human exposure to magnetic fields and electromagnetic radiation and concluded that the more important potential hazards were those which might be caused by excessive tissue heating by radio frequency electromagnetic radiation and by tissue excitation by induced currents from changing magnetic fields. They found

no substantial evidence to support any probability of induced electrical potentials or currents disturbing cardiac or central nervous system function.

The chief clinical concern appears to be related to the effect of a strong magnetic field on ferromagnetic materials such as cardiac pacemakers or metallic implants.(125) The magnetic field may alter pacing modes within the pacemaker or induce arrhythmias produced by conduction within the pacemaker leads. There is also some concern as to the potential for chest soft-tissue trauma due to movement of implanted pacemakers.(126) Patients with ferromagnetic implants and vascular clips are also contra-indicated for MR scanning due to the potential for movement, hemorrhage, tissue damage, or radio frequency heating of such implants. To avoid this, nonmagnetic materials - such as stainless steel alloys with a high nickel content - have been suggested for implants. Special shielding procedures are also implemented to limit access of patients to MRI scanning areas until an appropriate patient assessment and history can be taken.

The first reported application of MRI to the temporomandibular joint was by Helms et al. in 1984.(44) This preliminary report had limited image quality and low resolution due to the use of thick sections and the lack of an image intensifying surface coil. Several publications the following year showed a development of the technique with the application of surface coil technology. A small diameter (6.5cm) surface

coil is placed in close proximity to the structure being studied, to act as a receiver for the radio frequency signal given off during relaxation. This improves the signal-to-noise ratio, resulting in improved spatial and contrast resolution and thus an image with superior detail.(43) Roberts et al. and Katzberg et al. each demonstrated improved resolution with the use of surface coils in limited studies.(41,42) Katzberg et al. felt that even at this early developmental stage, none of the other radiographic modalities could provide the same exquisite detail of the disc and bilaminar zone tissues as was visible with MR imaging.

In the same year, a more extensive study was reported by Harms et al. on 115 TM joints with surgical confirmation in 15 patients.(43) Their technique used a five inch diameter surface coil with a static magnetic field of 0.6 Tesla and an image slice thickness of 0.5cm. Both T_1 and T_2 images were obtained. A T_1 weighted image produces a brighter delineation of joint anatomy due to the high signal from fat and bone marrow. T_2 weighted images are useful for demonstrating fluid or inflammatory changes in the joint. The MR diagnosis was confirmed in all 15 patients for whom there was surgical correlation. Complications were noted in seven examinations where patient motion severely degraded image quality and in three patients who became claustrophobic. The authors found MR to be a superb diagnostic modality for internal derangements since the disc and its attachments were well demonstrated. Besides the improved

soft-tissue resolution, thin section MR imaging produces a high spatial resolution similar to that of CT. Osseous detail and abnormalities were well visualized during the same image acquisition. Harms et al. concluded that MR could eliminate the need for arthrography, tomography, and CT in assessing internal derangements of the TMJ.

This study was expanded the following year to include 454 joints with surgical correlation in 85 patients.(127) Fibrous adhesions were identified by MR in 13 images. Disc morphology and position, as determined by MR, together with the presence of adhesions were confirmed in all 85 joints.

Direct sagittal, coronal, axial, and oblique imaging planes are all easily obtainable with magnetic resonance. Several authors have emphasized the use of a true sagittal plane for the TMJ by correcting for the horizontal angulation of the condyle.(128-130) This can be accomplished by using either a submental vertex radiograph or an axial MR image to calculate the condylar angulation. This information can then be transferred to a cephalostat as described by Laurell et al. for the proper head position.(129) The use of a cephalostat may also reduce the artifacts caused by patient motion and allow for sequential scanning with superimposable reproducibility.

In an early article by Schellhas, Wilkes, et al., magnetic resonance imaging was performed on 105 patients with particular attention given to proper condylar positioning using prior submental vertex projections.(128) The authors found MRI to

be the technique of choice for the examination of patients with suspected disc displacement and limitation of mandibular motion. They also felt that precise medial versus lateral positioning of the disc could be determined from the sagittal views, and were the first to suggest coronal MR imaging for defining disc position. Due to the superior contrast resolution, degenerative alterations in the pterygoid muscles as well as in the anterior discal attachments could be identified using MR. Since the cortical bone of the articular surfaces of the condyle, glenoid fossa, and eminence provide little signal, they contrast well with the high signal intensity of adjacent fat within the marrow of the condyle and temporal bone. The authors found, however, the imaging of bone detail with MR to be less precise than with standard tomography or CT and suggested that screening tomograms would be valuable in most cases.

As magnetic resonance imaging has become increasingly available and has undergone continuous technical improvements, its applicability to TMJ diagnosis has grown considerably. Reported advantages of this technique have included a lack of ionizing radiation, a non-invasive and non-painful procedure, similar spatial resolution to tomographic techniques with superior contrast resolution, and excellent soft-tissue visualization. This technique offers direct visualization of the position of the articular disc together with information about the morphology and histology of the tissues. The ability to image both hard and soft tissues in one study provides excellent differentiation

of tissue types. The main disadvantages with this technique are its cost, difficulty in identifying perforations, and absence of true dynamic images of joint motion.

In an effort to reduce the cost of this modality in comparison with arthrography or computed tomography, Helms has suggested a protocol which reduces the number of images obtained, and thereby cuts the imaging time and related fee in half.(131) This protocol involves a multi-echo technique acquired bilaterally with the jaw partially open. If a disc displacement is suspected, the patient is asked to open their mouth to the point just before the clicking occurs. The more common open and closed MR series are replaced with a single series in an intermediate stage of opening. This protocol effectively reduces the cost of the study, but it also compromises the quality of the diagnostic information produced to an extent that may be unacceptable. This single series would not allow evaluation of the condyle and disc relationship when the jaw was in a centric occlusion or centric relation position. It may also misrepresent dysfunctional situations where the point of reduction of the displaced disc is either clinically indeterminate, or not associated with the presence of joint noise.

In order to determine the accuracy of magnetic resonance imaging, authors have compared it with arthrography which has been considered to be the "gold standard," despite its 81 to 84% accuracy in controlled studies.

In 1986, Katzberg and Burgener reported the results of a comparative study between MR, CT, and arthrography.(132) They evaluated 79 patients (132 joints) with abnormalities of the TMJs, with magnetic resonance. These results were compared with CT in 16 joints and arthrography in 39 joints. The authors concluded that the accuracy of MR was equal to that of arthrography and superior to CT. They found MR particularly suitable for post-surgical follow-up examinations when invasive arthrography would be difficult or contraindicated. It is uncertain why the authors ran comparative studies in less than one half (55 joints) of the total sample.

Cirbus et al. evaluated the diagnostic accuracy of magnetic resonance in nine patients (16 joints) who were unresponsive to nonsurgical therapy.(45) They compared their surgical findings with the results of their clinical and radiographic examinations using transcranial radiography, arthrography, arthrotomography, and magnetic resonance imaging. Their evaluation incorporated an assessment of the disc-condyle relationship and the anatomy of individual joint structures. They concluded that MRI was correct in the diagnosis of disc position in 14 of 16 joints (87%). Technical difficulties prevented open mouth images in one patient (2 joints). Arthrotomography was correct in 11 of the 14 joints (78%). Two joints were excluded due to iodine allergy which permitted only MRI studies. In two joints, the contrast media could not be adequately injected while in a third joint, a false-negative report conflicted with the surgical

finding of an acute closed lock. Magnetic resonance also identified loose articular bodies in the superior joint space (1 joint) and inflammatory changes in three joints which were not identifiable by arthrotomography.

Transcranial projections and tomography proved useful in the diagnosis of degenerative joint disease, but were limited to osseous examination only. Fluoroscopy was found to be very accurate for determining the condyle-disc relationship throughout mandibular movement and was most beneficial for studying joint dynamics. The authors concluded that MRI offered the best soft-tissue examination and "far outweighed" the arthrographic images which give only outlines that are subject to the inaccuracies of technique and invasive contrast penetration. They commented that MRI produced no fluid distortion of the disc as with arthrography and that most of the patients in the study favored MRI because it was painless and radiation free. The major clinical drawback of MRI according to the authors was its inability to diagnose perforations. They point out, however, that the invasiveness of the arthrographic technique can iatrogenically create perforations and that some question exists as to the necessity of imaging perforations once the decision for surgery has already been made.

Magnetic resonance has provided a means to examine the temporomandibular joints of asymptomatic patients with a non-invasive modality. Kircos et al. used this to identify an anterior disc position in 32% of asymptomatic joints!(130)

However, most studies comparing imaging techniques will use arthrography as their standard. In most of these comparative studies involving arthrography, the sample is biased in the direction of more advanced pathology since it is difficult to justify exposure of asymptomatic patients to an invasive procedure. Mild displacements diagnosed by arthrography may go unconfirmed since a surgical procedure for correlation would be unwarranted. Kaplan et al. published an MR study of 28 normal temporomandibular joints as determined by prior inferior joint space arthrography.(106) This study followed a previously published article which evaluated a variation in the configuration of the superior aspect of the anterior recess in asymptomatic normal TMJs with inferior joint space arthrography.(133) The authors felt that MR allowed for direct visualization of the disc and surrounding tissues rather than indirect evidence of disc position and configuration as with arthrography. All 28 joints were diagnosed as normal by both techniques. The variation in the shape of the anterior recess as seen by arthrography correlated with the shape of the anterior band of the disc. When this normal disc had a thicker configuration, a concave anterior recess was seen with arthrography which the authors felt could be mistakenly interpreted to be a mild pathologically displaced disc. They concluded that the anatomic configuration of the disc, rather than its position or orientation, determined the arthrographic appearance of the

anterior recess, and cautioned arthrographers to avoid misinterpretation.

Laurel et al. correlated magnetic resonance images with laminographic, autopsy, and histologic findings in a limited study involving two cadaver joints.(134) Corrected laminographs were taken of each joint at 5mm intervals following submental vertex radiographs. Contiguous 3mm slices were taken along the same plane using a MR multi-echo pulse sequence. Anatomical sectioning was then performed using a band saw yielding 3mm frozen sections. Histologic sections were acquired from these frozen anatomical specimens for microscopic analysis. The authors concluded that magnetic resonance could readily demonstrate all of the abnormalities identified with the other techniques, including anterior disc displacement with atypical fibrous arrangement, exophytic condylar bone growth, abnormally dense fascia, and condylar position. Laminographs correctly identified the condylar position but failed to depict any other abnormalities. One joint was difficult to evaluate since it was perfused prior to imaging and sectioning. Magnetic resonance also confirmed the histologic assessment of loss of cellularity and fibrotic reorganization within the posterior attachment. This appears to be indicative of a pseudo disc formation following chronic anterior disc displacement. This study confirmed the effectiveness of MRI for depicting TMJ morphology as confirmed by direct visualization.

A second study to compare MRI with the apparent "gold standard," arthrotomography, was performed by Donlon and Moon.(135) Twenty-four temporomandibular joints were studied in symptomatic patients using tomography and MRI. Seventeen of these joints were also evaluated using arthrotomography. surgery was performed on thirteen joints. The three imaging techniques were compared for diagnosis of disc displacement, degenerative joint disease, and perforations. These patients were among the first ones to undergo MR examination of the TMJ at their facility which utilizes a rather small magnetic field strength scanner (Siemens 0.5 Tesla).

Five joints were diagnosed as normal with all techniques. Of the nineteen joints with evidence of disc displacement, seventeen had arthrotomograms, which confirmed the disc position in fifteen joints. One study was suboptimal and one could not be completed due to adhesions in the lower joint space. Magnetic resonance confirmed the disc displacements in 15 of 19 joints. However, three joints had very early clicks where the authors admit that patient positioning with the mouth open may have allowed reduction of the displacements. In one MR study, the disc was not visualized but a decreased range of condylar translation was noted.

Arthrotomography identified four perforations which MRI was unable to confirm. Surgery confirmed the presence of all perforations as well as an additional one which was not identified with arthrotomography. Degenerative joint disease was identified

by tomography in three cases while MRI revealed degenerative conditions in five joints which were confirmed by the surgical findings.

The authors concluded that MRI was the study of choice for evaluation of TMJ disc pathosis. They found MRI to be equal to arthrotomography in identifying disc displacements and superior for imaging disc morphology. Unlike a previous study by Schellhas, Wilkes, et al., Donlon and Moon found MRI to be more sensitive in diagnosing DJD than conventional tomography.(128) Arthrotomography had its chief advantage in disclosing perforations.

Schellhas, Wilkes, et al. reported the results of their experience with two imaging modalities to compare the reliability and accuracy of two-compartment arthrography with MR, and to define the respective roles of these procedures in TMJ diagnosis.(136) Surgical correlations were available for 218 of the 743 arthrographic procedures and 170 of the 1052 MR studies. In the arthrographic series, all but two arthrograms were diagnostic and disc position was confirmed in all of the 218 operated joints. Perforation was surgically confirmed in 85 joints, while two unexpected perforations were also identified. Two false-positive arthrographic perforations occurred due to technique error.

The MR images were acquired using a 1.5 tesla superconducting magnet with external rotation of the surface coil to correct for the horizontal angulation of the condyle. The

last 700 joints were also studied using a GRASS (gradient-recalled acquisition in the steady state) axial localizing sequence. This sequence was developed and first reported by Burnett, Davis, and Read.(137) It displays a dynamic or motion study of mandibular condylar movement by sequentially imaging the joint using static, lower resolution "fast-scans" at various stages of mandibular opening. These images are then linked together in a "movie-mode" to simulate movement as with a motion picture. This technique overcomes a reported disadvantage with MR, of not being able to examine the joint function dynamically.

The authors reported difficulty with patient compliance using the MR technique initially. Thirty of over 630 examinations could not be completed due to claustrophobia. This difficulty is now usually overcome with a mild sedative. At least 38 joint studies were reported to be inconclusive due to patient motion, interference from dental braces, or unusual joint anatomy. Patient motion can now be limited due to shorter scanning times and the use of patient head holders. Any interference from metal restorations or appliances is diminished by the use of nonferromagnetic materials and careful patient positioning and orientation before scanning. Disc displacement was confirmed in all 142 joints in which surgery was performed. An additional 28 joints had post-surgical MR scans prior to a second surgery for removal of implants or repair of previously failed arthroplasties. Magnetic resonance has been shown to be sensitive

and very specific in the evaluation of fracture within disc prostheses.(138) Preoperatively diagnosed perforation using MR was confirmed in 64 joints. However, perforation was also identified in 20 joints in which the diagnosis had not been established presurgically. Pathologic joint effusion, diagnosed by MR, was confirmed in all 8 joints for which surgical correlation was available.

The authors concluded that MR is the imaging procedure of choice over arthrography in most circumstances. While arthrography was superior in detecting capsular adhesions and the presence of perforations, magnetic resonance imaging was superior in studying, joint implants and associated complications, joint effusions, medial and lateral disc displacements, and avascular necrosis within the condylar head. Avascular (aseptic) necrosis and osteochondritis dissecans are relatively common and generally unrecognized disorders associated with joint and facial pain and an unstable malocclusion.(139) MR also proved to be the only technique for evaluation of soft-tissue lesions, i.e. muscle atrophy, tendonitis, myxomatous degeneration of the disc, and injuries such as contusions and hematomas.(136,140) Masticatory muscle contraction can also be measured and evaluated using the dynamic GRASS technique.

Just as with arthrography, it is difficult to conduct a systematic correlation between MRI and morphology in live patients due to the limitations that a surgical approach incorporates. These difficulties were reviewed earlier in

relation to arthrographic confirmation. Studies which use arthrography as the standard are also limited since this technique is not 100% accurate itself. Thus, a systematic comparison between MR imaging findings and joint conditions has not been achieved. Westesson, Katzberg, et al. therefore studied sagittal and coronal MR images of fresh autopsy specimens and compared these with corresponding sagittal cryosections of the same joints. (141) Fifteen left TMJs were removed and frozen in the closed-jaw position and embedded in methylnmethacrylate while orientated according to the condylar long axis. A plastic indicator grid was attached to each specimen to confirm the correspondence between the MR images and the cryosections. Each specimen was thawed prior to MR imaging, then refrozen and sectioned using a precision band saw. The resulting images and corresponding sections were evaluated for disc position, configuration, and bony abnormalities.

Magnetic resonance correctly delineated the position of the disc in 11 (73%) joints and incorrectly delineated it in four (27%) joints. The configuration of the disc was correctly determined in nine (60%) joints, incorrectly in five (33%) joints, and not visible in 1 (7%). Medial or lateral displacements of the disc were present in all joints in which disc position was incorrectly determined. An incorrect analysis of disc position was also seen with double contrast and single contrast arthrography when mediolateral displacements occurred. (23,24) Inaccuracies in determining disc configuration were also

associated with the lateral portion of the joint. It is difficult with MR imaging to differentiate between joint capsule and disc tissue in the lateral and anterior regions. MR proved to be 60% accurate in diagnosing osseous anatomy by correctly identifying 9 out of 15 joints. This is comparable to the 64% accuracy reported by Rohlin et al. in their study of osseous changes in the TMJ using hypocycloidal tomography.(126)

The authors conclude that MR imaging is an acceptable alternative to arthrography, especially when information about morphology is more important than evaluating joint function. However, the authors believe that arthrography with video tape recording of joint function is more informative in the clicking patient than MR. With the addition of coronal MR imaging, the tendency for misdiagnosis due to medial and lateral disc displacements could be minimized. The accuracy of MR imaging in a clinical situation could be further increased with the addition of either an open-mouth series or use of the dynamic GRASS technique.

Katzberg, Westesson, et al. further examined the accuracy of coronal and sagittal magnetic resonance imaging in identifying rotational and mediolateral sideways disc displacements.(142) Coronal and sagittal MR images were obtained of 18 fresh TMJ autopsy specimens and compared with corresponding coronal cryosections. An anatomical correlation was not available for the sagittal MR images since the specimens were all sectioned coronally. Clinical MR imaging in 37 patients (61 joints) was

also performed to determine the prevalence of these displacements in patients as well as cadavers. The authors also assessed the diagnostic accuracy, sensitivity, and specificity of coronal MR imaging versus cryosectional anatomy, and the diagnostic capabilities of MR for evaluating osseous abnormalities in the coronal plane. The authors followed a similar experimental protocol as in their prior study.(141)

Magnetic resonance in the coronal plane correctly identified the mediolateral position of the disc in 15 of 18 joints (83%). There were two false-positive findings for disc displacement due to an alteration in the signal intensity along the medial aspect of the joint. One false-negative diagnosis occurred due to poor tissue contrast between a lateral disc displacement and the lateral margin of the condyle. A significant medial or lateral shift of the disc was identified in a total of 8 out of 18 (44%) specimens. Osseous abnormalities were correctly identified by MR in 17 out of the 18 (94%) specimens. Imaging in the coronal plane proved more accurate in the assessment of bone changes than those in the sagittal plane. Clinical MR imaging showed medial disc displacements in 23% of the joints (14 of 61) with a lateral displacement in 3% of the joints (2 of 61).

Their findings indicate that medial sideways and rotational anteromedial disc displacements are more common than those with a lateral component. An attempt by the authors to demonstrate sideways displacements using an anterior arthrographic projection

in 75 patients was unsuccessful. Coronal MR imaging, in combination with sagittal scanning, provides a more thorough assessment of osseous and soft tissue relationships within the TMJ. It is also the technique of choice for identifying rotational or sideways disc displacements.

Both CT and MR have been advocated as noninvasive modalities for the imaging of temporomandibular joint disorders. Westesson, Katzberg, et al. made a systematic comparison of these techniques using 15 fresh autopsy TMJs and compared their diagnostic findings with corresponding cryosections.(143) The CT evaluation was performed with frozen specimens, while the MR images were done when the tissue was thawed. The authors admit that frozen tissue might have behaved somewhat differently with CT than the thawed tissue, but can site no evidence to support this affect.

The CT diagnosis of disc position was correct in 10 of 15 (67%) joints while MR correctly depicted the position in 11 of 15 joints for an accuracy of 73%. Based on their diagnostic findings with MR, it is obvious that this study used the same specimen sample as was reported on in their work comparing MR imaging with cryosectional anatomy.(141) In side-by-side comparisons of the CT and MR images, MR depicted the soft tissue anatomy with greater detail than did CT. Magnetic resonance imaging was also capable of depicting the border between the disc and its anterior and posterior attachments. This posterior determination is important in accurately evaluating the position of the disc. MR also clearly showed the morphology of the disc

in both an anterior and superior position, whereas CT showed this configuration only when the disc was positioned anteriorly. False-positive CT diagnosis of anterior disc position resulted from increased attenuation of the tissues beneath the articular eminence. This may be associated with an increased density within the tendinous attachment of the lateral pterygoid muscle. One false-negative diagnosis occurred with CT in the lateral region. This specimen was correctly identified with MR. This type of displacement, however, has led to diagnostic errors with arthrography and MR as well. (23,24,141) As was reported earlier, incorrect MR diagnoses resulted from a difficulty in differentiating between joint capsule and disc in the lateral and anterior regions of the joint. CT proved to be more accurate in the diagnosis of osseous abnormalities (87%) than was MR (60%), however, this difference was not statistically significant.

The authors concluded by summarizing the advantages and disadvantages of each technique with an emphasis on MR for soft tissue morphology and CT for bone depiction. However, it is their opinion that arthrography with videotape dynamic imaging is still the best imaging method for evaluating patients with functional disturbances.

Purpose of Study

Both computed tomography and magnetic resonance imaging have been shown to be valid as non-invasive modalities for imaging of disc displacements. Arthrographic and surgical

comparisons have traditionally been used with these techniques to determine their diagnostic applicability. (43,106,135,136,140) since both arthrography and surgery are invasive procedures, it is difficult to conduct a systematic correlation because generally only selected types of pathology are exposed to these procedures. (24) Therefore, the correlation in cases with less severe pathology is limited. There are reservations in using arthrography as the comparative standard since its accuracy is less than 100%. (23,24,105) In addition, surgical procedures of the temporomandibular joint offer limited access and restrict the evaluation of disc position and configuration in all but the most lateral regions.

The diagnostic accuracy of these techniques has therefore been shown by only a relatively few sagittal autopsy comparisons. (141-144) Two of these articles involved the same specimen sample in determining the accuracy of sagittal MR imaging. (141,143) One study examined the accuracy of a combination of coronal and sagittal MR imaging, while two separate studies looked at a correlation between CT and autopsy specimens. (142,144) No statistically significant differences were seen between CT and MR procedures in detecting bony abnormalities or disc position. (143) However, MR appeared to be superior in depicting soft-tissue changes while CT was superior in identifying osseous abnormalities. Of the nine incorrect diagnoses with these techniques, five occurred due to difficulties in differentiating tissue in the lateral and medial regions

of the joint. The remaining four diagnoses were false-positive findings of disc displacement due to the inability of CT to differentiate soft-tissue.

The position of the disc was determined by MR with an accuracy of between 73% and 83%.(141,142) The increased accuracy in the second study appeared to be due to the use of coronal MR sections to assist in identifying the mediolateral position of the disc. Neither of these comparative studies evaluated the diagnostic accuracy of the techniques in the medial, central, and lateral regions separately. The diagnosis was based on the entire joint specimen rather than evaluating the technique's capability to correctly demonstrate pathology regionally.

The incorrect diagnoses reported in the previous studies were due to an inability to differentiate the disc from the medial and lateral joint capsule with MR, and from an increase in the attenuation of tissues beneath the bony tubercle in the medial and central regions of the joint with CT. Difficulties in detecting pathology in the medial and lateral regions of the joint have also accounted for incorrect diagnoses in comparative studies with arthrography.(18,24) As each region within the joint presents individual challenges to correctly identifying pathology with both MR and CT imaging, I would like to determine the accuracy of each technique within these three separate regions.

In doing so, I will also compare my results with the only previous study correlating sagittal MR and postmortem morphology. (141,143) This study by Westesson et al. also reports the diagnostic accuracy of direct sagittal CT imaging as it compares with MR in detecting abnormalities in the soft and hard tissues of the TMJ.

MATERIALS AND METHODS

Selection of Specimens

Twenty-two TMJ specimens from eleven fresh cadavers without infectious diseases were acquired. No other attempts were made to be selective. There were nine females and two males with a mean age of 74 years (range: 51-93). The distribution of the material with respect to their age and sex is presented in Table 1.

Table 1: Age and Sex Distribution of Sample

	<u>Specimen Number*</u>										
	1	2	3	4	5	6	7	8	9	10	11
Female		(69)	(91)	(67)	(73)	(71)	(51)	(86)		(88)	(93)
Male	(71)								(58)		
	Total										
Female	9										
Male	2										

*Age in parentheses

Mean age: Male 64 years. Female 77 years. Total 74 years.

Information about possible TMJ symptoms prior to death was unavailable. The number of teeth and presence of dentures was noted. The cadaver heads were removed and the temporomandibular joints left intact until after the MR and CT imaging were performed, in order to correspond with clinical imaging techniques. No attempt was made to mobilize the mandible or

reposition it into maximum intercuspation. Thus, a partial open-mouthed position was usually obtained. This was also intended to correspond to the imaging protocol designed by Helms et al. in their CT and initial MRI studies to accentuate the potential disc displacement. (31,44)

After MR imaging of the fresh specimens, the material was frozen, thawed for CT imaging, then kept frozen until sectioning. Following MR and CT imaging, but prior to anatomical correlation, two specimens were inadvertently destroyed (specimen numbers 4, 5) which limited the total sample size to eighteen joints with a mean age of 75 years. The imaging results of these specimens will be reported but will not be included in the correlations.

MR Technique and Parameters

The fresh cadaver specimens were first imaged using a 1.5 Tesla Signa General Electric magnetic resonance (MR) system* at the Berwyn Magnetic Resonance Center in Berwyn, Illinois. The fresh specimens were placed in the MR in a position corresponding to a supine patient position orientated with the head rotated laterally approximately twenty degrees toward the side being examined. This was intended to correct for the average horizontal angulation of the condylar long axis and thereby obtain an approximately true sagittal image of the temporomandibular joint, as opposed to the entire head. (138,145-147)

* (General Electric, Milwaukee, Wisconsin)

After the specimen was positioned in a lucite head holder for support, a 6.5 cm diameter surface receiver coil was placed over the TMJ on the side being imaged. This coil improves the signal to noise (S/N) ratio of the image to allow for high resolution and thin sections by gathering the same amount of signal data from a smaller region.

Sagittal localizing scans were obtained first using a partial saturation technique to establish the image locations relative to the TMJ anatomy. A variety of pulse sequences were used to arrive at the parameters of an echo delay time (TE) of 20 msec and a pulse repetition time (TR) of 600 msec. An acquisition matrix of 256 x 128 was used along with a display matrix of 512 x 512 and a 16cm field of view. Either a 3mm or 5mm slice thickness was used with an interslice spacing of 50%. This resulted in an acquisition or scan time of 1 minute and 25 seconds.

After determining the optimum image planes, a longer scan was obtained for greater resolution and detail. Again, a variety of pulse sequences were used to determine the optimal parameters for TMJ imaging. The most frequent parameters used involved a partial saturation pulse sequence with two excitations, a TE of 20 msec, a TR of 1000 msec and a spatial resolution of .31mm x .31mm. This is a result of a small 8cm field of view with a 256 x 256 acquisition matrix and 512 x 512 display matrix. In order to image all the tissue without skipping over information between slices, 3mm contiguous or consecutive images

were acquired resulting in 6-7 sections per joint. The resulting scanning time for these high resolution images was 17 minutes and 10 seconds per joint. The specimens were then frozen prior to CT imaging.

CT Technique and Parameters

Following MR imaging, direct sagittal CT scans were obtained on the intact cadaver heads. In order to acquire approximately true sagittal images of the temporomandibular joint without the use of computer reformatting and the resultant loss in resolution, the head was aligned parallel to the scanning plane in a supine position and rotated 20° toward the side being imaged.(145,148) This resulted in views with a similar orientation to those acquired with MRI. This correction for the horizontal condylar angulation would be contraindicated clinically with direct sagittal CT imaging, due to the increased radiation exposure to the lens of the eye.

Both bone and soft tissue algorithms were used with a GE 9800 CT/T scanner* at Loyola University Medical Center in Maywood, Illinois. A coronal scout image facilitated cursor placement and image positions relative to the TMJ anatomy. Each temporomandibular joint was studied separately using contiguous 1.5mm thick scans from the medial to the lateral regions of the condyle. Eighteen to twenty sections were obtained in approximately five to six minutes. Other radio-

*(General Electric, Milwaukee, Wisconsin)

graphic parameters used included: 170mAs, 140kV, 512 x 512 matrix, 3 seconds and a 12.8cm field of view. The estimated radiation dose per section is 1.5 rads for single sections and 1.8 rads for multiple sections. For soft-tissue, a window of 200-350 and level of 40 were used. Bone detail was viewed at a window of 3000 and a level of 760. Each section was photographed using both bone and soft tissue settings with selective use of the soft tissue blink mode to accentuate the image density of the disc. Through computer manipulation of the data, soft tissue and bone images can be obtained in a clinical setting from one exposure without additional exposure time to the patient.

Anatomical Sectioning

After imaging, the specimens were frozen and transported to the Medical College of Wisconsin in Milwaukee, Wisconsin for anatomical sectioning. Eighteen TMJ specimens were removed en bloc from the frozen cadavers. The block was taken from the middle cranial area and measured approximately 10cm x 8cm x 6cm. The frozen blocks were placed in a rectangular support in a position corresponding to a supine patient position with a 20° rotation toward the lateral aspect of the joint. Aqueous carboxymethylcellulose was added as an embedding material and the containers were returned to the freezer. The base of the CMC block was perpendicular to the imaging planes.

Ten joints were sectioned using a heavy duty sledge cryomicrotome (LKB 2250; Gaithersburg, Md) while the remaining eight joints were sectioned using a conventional bandsaw with a fine-toothed metal cutting blade.(160) The band saw produced seven to eight 2.5mm thick sections through the specimens in the same sagittal planes as the MR images. The blocks were kept frozen after each saw cut with carbon dioxide ice. Cryosectioning was performed for a more detailed anatomical display and correlation. It provides very thin polished sections which correspond well to the thin images acquired with CT. A predetermined number of 5 to 50um sections were automatically trimmed off the specimen. The cutting thickness was adjusted according to the hardness of the material, thinner sections being chosen for hard bone and thicker ones for soft-tissues.(149) At 1mm intervals, the specimen surface was gently wiped with a warm cloth soaked in ethylene glycol to remove any ice crystals on the cutting surface and bring out the bright natural colors.

The freshly cut surfaces of the band-saw and cryomicrotome sections were photographed at a 1:1 and 1:2 scale using Kodachrome 25 ASA film and a 35mm SLT camera (Olympus OM2N). A ruler was placed on the surface to aid in measurements on the resulting slides. The camera was equipped with a macro lens (Olympus Zuiko 80mm macro with telescopic auto tube) and two electronic flash units (Olympus T32 flash using cross-polarization filters). The flash attachments were aimed at

the specimen from opposite directions and at an angle of 45° to prevent reflections.

Interpretation and Comparison

Following sectioning of the cadaver material, the MR and CT images were evaluated without knowledge of the cryosectional results. Using the criteria described below, a detailed analysis was recorded from which more general categories were used for comparative purposes. The joints were evaluated in lateral, central, and medial regions for osseous and soft tissue anatomy. Figure 1 illustrates the form used to record the findings.

The soft tissue anatomy was evaluated with regard to the disc position in a sagittal plane relative to the condyle, and recorded according to previously described criteria. (13,23,24) General categories included: 1) superior position - the posterior band of the disc was between the fossa and the superior surface of the condyle; 2) completely anterior position - the posterior band of the disc was anterior to the most superior point of the condyle; 3) posterior - the posterior band of the disc is posterior to the most superior point of the condyle; and 4) partially anterior position - the posterior band of the disc was in a superior position in one region and in an anterior position in another region of the joint. As in the study by Westesson, Bronstein, and Liedberg, partial anterior position implied that at least two of the six sagittal sections demonstrated anterior disc position and the remaining sections

showed a superior position. (13) These changes were graded on a scale of 1 to 3 (1 = mild; 2 = moderate, 3 = severe) as to the degree of displacement or deformation.

The morphology of the disc in a sagittal plane was also recorded as in prior studies. (13,23,24) The configuration was classified as either biconcave or deformed. A deformed disc could be either: 1) biplanar - even thickness; 2) reversed - thicker anteriorly than posteriorly; 3) thickened posterior band - resulting in a convex inferior surface; or 4) biconvex - thickest centrally. Calcifications within the disc were noted when identified. Deformations of the disc were recorded relative to the region of the joint in which they occurred. For overall categorization, however, deformation of the disc within any region resulted in a classification of deformed disc for that joint. The posterior attachment was also evaluated to identify the presence of perforations and/or fibrotic changes.

The MR and CT images were evaluated for osseous abnormalities which included flattening, cortical thinning, erosion, sclerosis, osteophytosis and cystic degeneration of the condyle and bony tubercle. Again, the degree of abnormality was recorded on a scale of 1 to 3.

The MR and CT findings were then correlated with observations from the cryosections in a blinded fashion. The cryosectional findings were used as the morphologic standard. From these comparisons, the diagnostic accuracy of each technique (MR and CT), as well as the sensitivity, specific-

ity, and positive and negative predictive values were calculated in the lateral, central and medial regions of the joint. The diagnostic accuracy was calculated as a percentage of joints with the correct diagnosis (true-positive and true-negative diagnoses) out of all the joints. The sensitivity was calculated as the proportion of existing changes detected; the specificity as the proportion of normal cases identified; the positive predictive value as the proportion of positive diagnoses that were correct; and the negative predictive value as the proportion of negative diagnoses that were correct. After all of the analyses were completed, the MR and CT images were then compared with the cryosections in an attempt to explain any disparities.

Figure 1.
REVIEW OF THE TEMPOROMANDIBULAR JOINT

DATE:

C. F. Reed

CASE NO:

METHOD:

SIDE:

OSSEOUS ANATOMY:

- | | |
|----------------------|-----------------------|
| a) WNL | g) Osteophytosis |
| b) Remodelling | h) Cytic degeneration |
| c) Flattening | i) Osteoarthrosis |
| d) Cortical thinning | j) Steep eminence |
| e) Erosion | k) Other |
| f) Sclerosis | |

L

C

M

CONDYLE: _____

TUBERCLE: _____

SOFT TISSUE ANATOMY:

DISC POSITION (L,C,M)

Relative to Condyle -

- | | |
|-----------------------------|--------------------------|
| ___ Superior | ___ Anteromedial displ. |
| ___ Partial anterior displ. | ___ Anterolateral displ. |
| ___ Anterior displ. | ___ Degree of displ. |
| ___ Posterior displ. | ___ (1,2,3) |
| | ___ N/A |

DISC MORPHOLOGY (L,C,M)

___ Biconcave

DEFORMED:

- | | |
|------------------------------|-------------------|
| ___ Biplanar | ___ Biconvex |
| ___ Reversed | ___ Calcification |
| ___ Thickened posterior band | ___ Other |
| ___ Folded | ___ N/A |

POSTERIOR ATTACHMENT (L,C,M)

- | | |
|------------------------------|-----------------|
| ___ WNL | ___ Perforation |
| ___ Anterior fibrosis | ___ Other |
| ___ Generalized fibrosis | ___ N/A |
| ___ Superior Lam. Identified | |
| ___ Inferior Lam. Identified | |

COMMENTS:

RESULTS

Disk Position - General

When the specimens were evaluated in an overall fashion, summarizing the information from each of the three regions (lateral, central, and medial) into one diagnosis, the MR diagnosis of disc position was correct in 16 of 18 joints, while the CT diagnosis of disc position was correct in 9 joints for an accuracy of 89% and 50% respectively (Table 2).

Table 2: Diagnostic Accuracy of MR and CT for Disc Position (n = 18)

<u>Method</u>	<u>DIAGNOSIS</u>				<u>Accuracy (%)</u> *
	True	False	True	False	
	<u>Neg.</u>	<u>Neg.</u>	<u>Pos.</u>	<u>Pos.</u>	
MR	8	1	8	1	89
CT	4	2	5	7	50

* Number of correct analyses divided by all analyses.

In comparison of the images obtained from the two techniques, MR was seen to more clearly depict the soft-tissue anatomy of the joint than did CT. The anterior, and more importantly, posterior borders of the disc were more consistently identified with MR and were seldom visualized with CT (Fig. 2). Because of this, seven false-positive CT diagnoses of anterior disc position were made based on the increased density of tissue anterior to the condyle and inferior to the bony

tubercle (Figs. 2 and 3). The posterior border of the disc was not visualized to allow a proper determination of disc position. An unusual finding of posterior disc position was correctly identified by MR in three specimens, but incorrectly assessed using CT (Fig. 4). This was due to the inability of CT to identify the posterior border of the disc and the increased attenuation of tissue in the small joint space superior and posterior to the condyle. In two of these specimens a false-positive diagnosis of a disc in an anterior position was made by CT. Review of the cryosectional and MR anatomy showed this to be due to a markedly fibrotic change in the capsular and anterior attachment tissue which CT incorrectly identified as disc tissue.

The outline of the disc was visible with CT only when the disc was anteriorly positioned, whereas MR clearly identified the disc outline in both the anterior and superior positions. This greatly aided in the reliability of the MR diagnosis. Since the disc image was seldom visible with CT when it was superiorly positioned, a diagnosis of superior position was inferred if there was no increased attenuation of tissue anterior to the condyle (Fig. 4). This resulted in one of the two false-negative CT diagnoses of disc position.

There was one false-positive and one false-negative diagnosis of anterior disc position with MR. The false-positive diagnosis occurred in the lateral region of one specimen where the lateral discal ligament and joint capsule merged with the

anterior band of the disc without a significant tissue signal gradient (Fig. 5). Since both tissues have a decreased signal intensity, the combination of tissues was incorrectly interpreted to be an anteriorly positioned disc. A false-negative MR and CT diagnosis of disc position was made in one specimen when the disc was identified to be in a superior position, while the corresponding cryosection revealed an anterior disc position (Fig. 6). Upon further review of the corresponding sections, it was determined that a change in condylar position had occurred between the CT imaging, refreezing and cryosectioning of the specimen which led to an altered disc position.

Disk Morphology - General

When the disc morphology was evaluated in an overall fashion, MR correctly depicted the disc configuration in fifteen joints, while CT was correct in eleven joints. This resulted in an accuracy of 83% for MR and 61% for CT. The number of correct and false diagnoses of disc morphology are presented in Table 3.

Table 3: Diagnostic Accuracy of MR and CT for Disc Morphology
(n = 18)

<u>Method</u>	<u>DIAGNOSIS</u>				<u>Accuracy (%)</u> *
	<u>True Neg.</u>	<u>False Neg.</u>	<u>True Pos.</u>	<u>False Pos.</u>	
MR	3	1	12	2	83
CT	2	4	9	3	61

* Number of correct analyses divided by all analyses.

As was previously stated, MR showed the configuration of the disc in both a superior and anterior position, while CT was best able to identify the outline in an anterior position, but was inconsistent in all positions. The CT image of the disc was so indistinct in two joints that it was not possible to determine the shape of the disc. A disc in superior position with CT was generally assumed to be biconcave due to the difficulty in differentiating its configuration using a soft-tissue algorithm. Some benefit could be gained upon close observation using the CT bone algorithm since the bony outline was very distinct and not blurred into the joint space as with soft tissue CT imaging.

Both false-positive diagnoses with MR occurred in the lateral region when a biconcave disc was incorrectly identified as being deformed and biplanar (Fig. 3a). The false-negative MR diagnosis occurred in the central region when a thickened posterior band was described as normal with MR. Of the seven incorrect CT diagnoses of disc morphology, four occurred in specimens where the disc position was also incorrectly determined.

Osseous Anatomy - General

The osseous anatomy of the condyle and tubercle was also compared throughout all regions. The results of an overall diagnosis for each technique is recorded in Tables 4 and 5.

Table 4: Diagnostic Accuracy of MR and CT for Osseous Anatomy of the Condyle (n = 18)

<u>Method</u>	<u>DIAGNOSIS</u>				<u>Accuracy (%)</u> *
	<u>True Neg.</u>	<u>False Neg.</u>	<u>True Pos.</u>	<u>False Pos.</u>	
MR	2	0	16	0	100
CT	2	0	16	0	100

* Number of correct analyses divided by all analyses.

Table 5: Diagnostic Accuracy of MR and CT for Osseous Anatomy of the Tubercle (n = 18)

<u>Method</u>	<u>DIAGNOSIS</u>				<u>Accuracy (%)</u> *
	<u>True Neg.</u>	<u>False Neg.</u>	<u>True Pos.</u>	<u>False Pos.</u>	
MR	1	3	14	0	83
CT	0	2	15	1	83

* Number of correct analyses divided by all analyses.

The accuracy of both MR and CT techniques was similar for bone in the condyle (100%) and tubercle (83%) despite our expectation that CT would be more reliable. Side-by-side comparison of the MR and CT images clearly showed, however, that CT depicted the osseous anatomy in both regions with greater clarity and detail. Both techniques had three incorrect diagnoses in describing the osseous anatomy of the eminence. There were three false negative diagnoses with MR due to the less distinct bony outline and low signal intensity of the region (Fig. 2). Diagnosis with CT resulted in one false-positive

and two false-negative recordings due to subtle differences in identification of bony changes such as flattening of the eminence (Fig. 4a).

posterior Attachment

The posterior attachment tissues were also evaluated. However, computed tomography was unable to identify any tissues or the presence of perforations due to the small regions being observed in close proximity to two dense bony structures. The soft-tissue algorithm tended to blur the bony margins and obscure any tissue adjacent to them. MR correctly assessed the posterior attachment in 15 out of 18 joints (83%). Perforations were suspected by MR in four joints, and were confirmed by cryosectional analysis in each case (Figs 7, 8, and 9). Criteria that were often present when a perforation was suspected with MR include: significant disc displacement, degenerative changes in the condyle and eminence such as osteophytosis, erosions, or sclerosis, and an increased signal intensity in the posterior attachment which was sometimes associated with an observable break in the low-signal intensity elastic tissue of the superior lamina. Despite our reported success in correctly suspecting a perforation, it should be noted that MR did not identify the perforation in the posterior attachment in itself, but only suspected it due to the chronic and degenerative changes in the joint tissues. These perforations may have been easier to suspect in this sample due to the high mean age (75 years) and increased probability of chronic degenerative changes

resulting in larger perforations. Fibrosis in the posterior attachment was a relatively common finding being observed by MR correctly in five joints and incorrectly identified in two joints (false-positive). One false-negative observation for fibrosis was also made by MR.

The overall sensitivity, specificity, and positive and negative predictive values for MR and CT diagnoses of the joint, regarding changes in bone, disc position and morphology are presented in Table 6.

Table 6: Sensitivity, Specificity, and Positive and Negative Predictive Values of MR and CT in the Diagnosis of Disc Position, Morphology, and Changes of the Bone in the Condyle and Tubercle (n = 18)

Method	Diagnosis	Sensi- tivity ¹	Speci- ficity ²	Positive Predictive Value ³	Negative Predictive Value ⁴
MR	Disc Position	0.89	0.89	0.89	0.89
CT	Disc Position	0.71	0.36	0.42	0.67
MR	Disc Morphology	0.92	0.60	0.86	0.75
CT	Disc Morphology	0.69	0.40	0.75	0.33
MR	Condylar Change	1.00	1.00	1.00	1.00
CT	Condylar Change	1.00	1.00	1.00	1.00
MR	Tubercle Change	0.82	1.00	1.00	0.25
CT	Tubercle Change	0.88	0.00	0.94	0.00

¹ Proportion of existing changes detected

² Proportion of normal cases identified

³ Proportion of positive diagnoses that are correct

⁴ Proportion of negative diagnoses that are correct

Disc Position - Specific

When the specimens were evaluated specifically within each region (lateral, central and medial), the lateral region was found to be the most difficult to correctly assess with both MR and CT imaging. In the lateral region, MR images correctly depicted the disc position in 16 out of 18 joints for an accuracy of 89%. In this same region, CT images depicted the disc position correctly in 8 joints for an accuracy of 44%. The number of correct and false diagnoses of disc position in all three regions are presented in Table 7.

Table 7: Diagnostic Accuracy of MR and CT for Disc Position Within Each Region (n = 18)

Method	<u>DIAGNOSIS</u>					<u>Accuracy (%)</u>
	<u>True</u>	<u>False</u>	<u>True</u>	<u>False</u>		
	<u>Neg.</u>	<u>Neg.</u>	<u>Pos.</u>	<u>Pos.</u>		
L/C/M	L/C/M	L/C/M	L/C/M	L/ C /M		
MR	8/11/12	1/0/0	8/7/6	1/0/0	89/100/100	
CT	5/ 6/ 9	4/2/4	3/3/2	6/7/3	44/ 50/ 61	

Throughout all the regions of the joints, two incorrect diagnoses of disc position were made with MR. Both of these occurred in the lateral region. As was previously reviewed, the false-negative MR diagnosis together with a false-negative CT diagnosis was made in one specimen where an altered condylar

position occurred following CT imaging and prior to cryosectioning (Fig. 6). The disc position was recorded by MR and CT to be in a superior position, while the cryosection revealed it to be anteriorly positioned relative to the displaced condyle. The false-positive MR diagnosis resulted from difficulty in differentiating the lateral discal ligament and joint capsule from the anterior band of the disc in one specimen (Fig. 5).

The CT results in the lateral region produced four false-negative and six false-positive diagnoses. One false-negative diagnosis was due to the altered condylar position previously reported (Fig. 6). In three other joints, the disc was incorrectly assumed to be in the superior position because it could not be identified with CT. In one of these cases the disc was deformed and diminished in size but in an anterior position (Fig. 7a). The other two joints had posteriorly positioned discs which were undetected with CT (Fig. 4a). Four of the six false-positive CT diagnoses incorrectly interpreted the disc to be anteriorly positioned due to the inability of CT to identify the posterior margin of the disc (Figs. 2a and 3a). In two other specimens, the increased attenuation of tissue anterior to the condyle was falsely attributed to an anteriorly positioned disc. Following evaluation of the corresponding anatomical sections, one specimen was seen to have a posteriorly positioned disc with anterior pseudo-disc formation while the second had a medioanterior disc displacement with calcification which was not present in the lateral region (Fig. 8a). In both

cases, the increased attenuation of the region appeared to be due to markedly fibrotic changes in the capsular and anterior attachment tissues.

In the central and medial regions, MR correctly identified the disc position in all cases. CT correctly determined the disc position in nine joints in the central region and eleven joints in the medial region (Table 7). The reasons for the misdiagnoses were the same as previously discussed. The inability to identify the posterior band of the disc with CT resulted in five false-positives in the central region and two in the medial region (Figs. 2b and 3b,c). The increased attenuation of tissue anterior to the condyle due to fibrotic changes accounted for two false-positive CT diagnoses in the central region and one in the medial. The inability to identify the disc position with the assumption that it was superiorly positioned resulted in one false-negative diagnosis in the central and three in the medial regions (Figs. 4b,c and 9c). A false-negative diagnosis also occurred in both the central and medial regions in one specimen due to a small radiopacity anterior to the condyle, which appeared inadequate to be described as an anteriorly positioned disc.

Following a thorough review of the sagittal anatomical sections, the position of the disc could be determined in each of the anteroposterior and mediolateral dimensions. A superior disc position without any medial or lateral component was noted

in five out of the 18 (28%) joints. The results of this analysis are summarized in Table 8.

Table 8: Position of the Disc Relative to the Condyle
(n = 18).

	Super.	Anter.	Supero- Medial	Partial Antero- Medial	Antero- Medial	Partial Pos- terior	Pos- terior
# of Joints	5	0	4	2	4	1	2
Per- centage	28	0	22	11	22	6	11

The most frequent finding among these cadaver specimens was a medial component to the disc displacement. Eleven joints displayed some medial movement of the disc (61%). In four of the 18 (22%) specimens, an anterior displacement was accompanied by a medial rotation of the disc. Surprisingly, no joints displayed purely an anterior disc position or a lateral component to their displacement. Sideways displacements in a purely medial direction without an anterior component were noted in 4 out of the 18 (22%) joint specimens. Partial anteromedial disc displacements were observed in two specimens (11%). This rotational type of displacement occurs when the disc is positioned anterior to the condyle in the lateral region of the joint, while superiorly positioned in either the central or medial regions (Fig. 6).

Sagittal MR imaging revealed the medial component of disc displacement in six out of the eleven joints in which it was identified (54%) (Fig. 10). The correct diagnosis of anteroposterior disc position was made with MR in ten out of the eleven specimens in which a medial component of displacement was noted in the cryosectional material. This includes five cases where MR was unable to identify the medial disc position. Sagittal MR correctly identified this medial position in 3 of the 4 joints with an anteromedial displacement (75%), 2 of the 4 joints with a purely medial displacement (50%), and one joint in which the disc was located posteriorly and medially (100%). On the other hand, CT correctly diagnosed the anteroposterior disc position in only 4 out of 11 joints where a medial component of displacement was present.

A very unusual disc position was observed in three specimens (17%). The left and right joints of one cadaver both displayed a posterior disc displacement. One of these joints also presented a medial component to the displacement (Fig. 4). A partial posterior disc displacement was also noted in a second cadaver. In this case, the finding was unilateral. The posterior disc position was noted in the lateral and central regions while the medial region displayed a superior position of the disc. Significant posterior condylar remodelling was generally associated with this type of displacement. In each case, MR correctly diagnosed the disc position in all regions while CT was unable to identify the

disc. Increased fibrosis of the anterior attachment tissues was noted in two of these specimens which formed a type of pseudo-disc in the region of suspected joint loading.

Disc Morphology - Specific

The lateral region of the joint also proved to be the most difficult in which to diagnose the configuration of the disc with either MR or CT. In the lateral region, MR images correctly depicted the disc morphology in 14 out of 18 joints for an accuracy of 78%. In this same region, CT correctly depicted the disc morphology in 10 joints for an accuracy of 56%. The number of correct and false diagnoses of disc configuration in all three regions are presented in Table 9.

Table 9: Diagnostic Accuracy of MR and CT for Disc Morphology Within Each Region (n = 18)

Method	<u>DIAGNOSIS</u>					<u>Accuracy (%)</u>
	<u>True</u>	<u>False</u>	<u>True</u>	<u>False</u>		
	<u>Neg.</u>	<u>Neg.</u>	<u>Pos.</u>	<u>Pos.</u>		
L/C/M	L/C/M	L/C/M	L/C/M	L/ C /M		
MR	4/10/12	1/1/0	10/7/6	3/0/0	78/94/100	
CT	4/ 6/ 8	4/2/2	6/6/4	4/4/4	56/67/ 67	

One false-negative and three false-positive diagnoses of disc morphology were made with MR in the lateral region. The false-negative diagnosis occurred in a joint where MR

incorrectly identified a thin disc in superior position with biconcave form, while the cryosectional anatomy showed it to be biplanar. MR was also unable to differentiate between the posterior band of the disc and the thickened, fibrotic posterior attachment in one specimen with a slight posterior disc position. Two other false-positive diagnoses of disc morphology occurred due to a tangential imaging plane which occurs in the lateral region and complicates the identification of disc position and morphology (Fig. 3a).

CT evaluation resulted in four false-negative and four false-positive diagnoses of disc configuration in the lateral region. Two false-negative diagnoses resulted from an inability to identify any disc tissue, while two others occurred because only a portion of the anterior band of the disc could be seen (Figs. 3a, 4a and 7a). Three false-positive findings of disc morphology were associated with the increased attenuation and incorrect identification of an anterior disc position in the lateral and anterior regions of the joint (Fig. 8a). In one joint, the false-positive diagnosis occurred because the posterior band of the disc could not be identified. Of the eight false-diagnoses of disc morphology using CT, five occurred in joints where the disc position was also incorrectly determined.

In the central and medial regions, MR correctly identified the disc configuration in 17 and 18 joints respectively, for accuracies of 94 and 100%. A false-negative assessment of disc morphology was made in the central region as MR

was unable to identify a thickened posterior band of the disc in one joint.

CT correctly identified the disc configuration in 12 joints in both the central and medial regions for an accuracy of 67% in both areas. Two false-negative and four false-positive assessments were made in both regions. Three of the four false-negative assessments by CT in these regions were made due to an inability to identify any disc tissue (Figs. 4b,c and 9c). The remaining false-negative finding occurred in the central region due to an inability to identify the posterior band of the disc. The four false-positive findings in the central region were associated with the increased attenuation and incorrect identification of an anterior disc position, as was one false-positive assessment in the medial region (Figs. 2b and 3b,c). The inability to identify the posterior band resulted in the remaining three false-positive diagnoses in the medial region. Of the six false diagnoses for disc configuration in the central region, all occurred in joints where the disc position was also incorrectly identified by CT. In the medial region, four joints were misdiagnosed for both disc position and disc morphology.

MR was unable to assess calcification in the disc. CT identified calcifications in three specimens due to the increased attenuation of this tissue. These findings were confirmed in the corresponding cryosections in two joints (Figs. 8b,c). In the third specimen, the small area of calcifica-

tion could not be seen in the anatomical section (Fig. 9b).

An area of calcification was also seen in the medial cryosection of one joint which was not confirmed by CT (Fig. 7c).

A correlation of the disc configuration seen and the disc position identified is reported in Table 10.

Table 10: Correlation of Disc Position and Disc Configuration Identified From Anatomical Sectioning (n = 18)*

Disc Configuration	DISC POSITION					Total
	Super. Super.	Supero-Medial	Partial Antero-Medial	Antero-Medial	Partial Pos-terior	
Bi-concave	3(17)	1(6)	1(6)	1(6)	1(6)	7(39)
Biconcave Lat. 1/3 of even thick- ness	2(11)	2(11)				4(22)
Even thickness			1(6)			2(11) 3(17)
Biconvex				3(17)		3(17)
Different config. in diff. thirds		1(6)				1(6)
Total	5(28)	4(22)	2(11)	4(22)	1(6)	2(11)

*Percentages are recorded in parentheses adjacent to the number of specimens #(%).

Osseous Anatomy - Specific

The osseous anatomy was also evaluated specifically within the lateral, central and medial regions. The number of correct and false diagnoses for the condyle and tubercle in all three regions are presented in Tables 11 and 12.

Table 11: Diagnostic Accuracy of MR and CT for Osseous Anatomy of the Condyle Within Each Region (n = 18)

Method	<u>DIAGNOSIS</u>				<u>Accuracy (%)</u>
	<u>True Neg.</u>	<u>False Neg.</u>	<u>True Pos.</u>	<u>False Pos.</u>	
	L/C/M	L/C/M	L / C/M	L/C/M	
MR	3/2/4	2/0/2	12/16/11	1/0/1	83/100/83
CT	2/2/4	2/0/1	12/16/12	2/0/1	78/100/89

Table 12: Diagnostic Accuracy of MR and CT for Osseous Anatomy of the Tubercle Within Each Region (n = 18)

Method	<u>DIAGNOSIS</u>				<u>Accuracy (%)</u>
	<u>True Neg.</u>	<u>False Neg.</u>	<u>True Pos.</u>	<u>False Pos.</u>	
	L/C/M	L/C/M	L / C/M	L/C/M	
MR	3/3/7	4/1/3	10/14/6	1/0/2	72/94/72
CT	3/2/6	2/2/0	12/13/9	1/1/3	83/83/83

In the lateral region, MR analysis of the condylar anatomy was correct in fifteen joints (83%) while CT correctly

diagnosed osseous changes in fourteen joints (78%). Two false-negative assessments were made with MR when mild remodelling changes were not identified (Fig. 2a). A false-positive report of lateral condylar flattening by MR could not be confirmed following analysis of the cryosection (Fig. 4a). CT analysis resulted in two false-negative and two false-positive diagnoses. Despite the similar accuracies between the two techniques, side-by-side comparisons of MR and CT images clearly showed that CT depicted osseous anatomy with greater clarity and detail. Both false-negative assessments with CT occurred as mild cortical flattening was not depicted in the CT images. This may be due in part to the tangential sectioning which occurs laterally together with the superimposition of 1.5mm of tissue into a single plane with CT imaging. The two false-positive diagnoses of condylar anatomy in the lateral region occurred in joints where the central region had significant osseous changes. Similar changes were falsely reported in the most medial sections of the lateral region, which led to an incorrect CT diagnosis of this region (Figs. 3a,b and 4a,b).

Both techniques showed excellent accuracy for diagnosing osseous changes of the condyle in the central region (100%). Analyses in the medial region resulted in two false-negative and one false-positive diagnosis with MR for an accuracy of 83%. CT correctly determined the osseous anatomy in 16 out of 18 joints (89%) and had one false-negative and one false-positive assessment. The false-negative assessments by MR both

occurred when MR analysis could not identify mild condylar flattening in the medial region which was identified in cryosectional and CT analysis. A report of condylar remodelling by both MR and CT could not be confirmed with the sectional anatomy, resulting in a false-positive diagnosis for both techniques (Fig. 3c). CT also had one false-negative diagnosis where remodelling changes were not assessed.

Both techniques produced lower accuracies in identifying osseous changes in the tubercle than in the condyle. In the lateral region, MR reported four false-negative and one false-positive diagnosis for an accuracy of 72% (13/10). CT correctly diagnosed the bony anatomy in 15 out of 18 joints for an accuracy of 83%. Two false-negative and one false-positive diagnosis were made with CT. Errors with both MR and CT diagnosis of the tubercle tended to occur in the direction of under-diagnosis, with a greater number of false-negative findings being reported. The increased contour of the lateral region of the tubercle and the superimposition of signal due to the relative thickness of the image slice with MR (3mm) and CT (1.5mm), in comparison to the anatomical slice which lacks thickness, resulted in a decreased identification of osseous changes.

The central region again proved to be more accurate with both techniques. One false-negative diagnosis was made with MR for an accuracy of 94% (Fig. 2b). CT reported two-negative and one false-positive finding for an accuracy of 83%.

The medial region was correctly diagnosed by MR in 13 out of 18 joints for an accuracy of 72%. Three false-negative and two false-positive assessments were made. The CT diagnosis of osseous changes in the medial region was correct in 15 out of 18 joints for an accuracy of 83%. All incorrect diagnoses with CT were due to false-positive findings of mild remodelling changes such as sclerosis, which were not confirmed with the anatomical sections. Similarly, the misdiagnoses with MR were due to mild remodelling changes which were either incorrectly identified or missed with MR assessment (Fig. 3c).

The frequency and distribution of remodelling and osteoarthritic changes in the osseous anatomy of the condyle and tubercle is recorded in Table 13.

Table 13: Frequency and Distribution of Remodelling and Osteoarthritic Changes in the Condyle and Tubercle (n = 18)*

	<u>Lateral</u>	<u>Central</u>	<u>Medial</u>
	<u>N/ R/O</u>	<u>N/ R/O</u>	<u>N/R/O</u>
Condyle	4/ 8/6	2/ 8/8	5/8/5
Eminence	4/10/4	3/11/4	9/6/3

* N/R/O = Normal/Remodelling/Osteoarthrosis

In Tables 14 and 15, the sensitivity, specificity, and positive and negative predictive values for MR and CT diagnoses are recorded respective to the lateral, central, and medial regions of the joint.

Table 14: Sensitivity, Specificity of MR and CT in the Diagnosis of Disc Position, Morphology, and Osseous Changes of the Condyle and Tubercle Within Each Region (n = 18)

Method	Diagnosis	Sensitivity ¹			Specificity ²		
		L	C	M	L	C	M
MR	Disc Position	0.89	1.00	1.00	0.89	1.00	1.00
CT	Disc Position	0.43	0.60	0.33	0.45	0.46	0.75
MR	Disc Morphology	0.91	0.88	1.00	0.57	1.00	1.00
CT	Disc Morphology	0.60	0.75	0.67	0.50	0.60	0.67
MR	Condylar Change	0.86	1.00	0.85	0.75	1.00	0.86
CT	Condylar Change	0.86	1.00	0.92	0.50	1.00	0.80
MR	Tubercle Change	0.71	0.93	0.67	0.75	1.00	0.78
CT	Tubercle Change	0.86	0.87	1.00	0.75	0.67	0.67

¹ Proportion of existing changes detected

² Proportion of normal cases identified

Table 15: Positive and Negative Predictive Values of MR and CT in the Diagnosis of Disc Position, Morphology, and Osseous Changes of the Condyle and Tubercle Within Each Region
(n = 18)

<u>Method</u>	<u>Diagnosis</u>	<u>Positive Predictive Value³</u>	<u>Negative Predictive Value⁴</u>
		L / C / M	L / C / M
MR	Disc Position	0.89/1.00/1.00	0.89/1.00/1.00
CT	Disc Position	0.33/0.30/0.40	0.56/0.75/0.69
MR	Disc Morphology	0.77/1.00/1.00	0.80/0.91/1.00
CT	Disc Morphology	0.60/0.60/0.50	0.50/0.75/0.80
MR	Condylar Change	0.92/1.00/0.92	0.60/1.00/0.67
CT	Condylar Change	0.86/1.00/0.92	0.50/1.00/0.80
MR	Tubercle Change	0.91/1.00/0.75	0.43/0.75/0.70
CT	Tubercle Change	0.92/0.93/0.75	0.60/0.50/1.00

³ Proportion of positive diagnoses that are correct

⁴ Proportion of negative diagnoses that are correct

DISCUSSION

The focus of this study was to identify the accuracy and effectiveness of MR and CT imaging in depicting soft-tissue and osseous anatomy of the temporomandibular joint. A significant amount of variance was seen between the overall accuracies of each technique and the individual accuracies reported for the lateral, central and medial regions of the joint. The greatest inconsistency in diagnostic findings occurred in the most lateral and medial regions of the joint. MR and CT imaging proved to be most reliable in the central two-thirds of the joint. This is similar to the conclusions drawn by other authors studying double-contrast arthrography and tomography.(2,110)

The diagnostic accuracy of MR in assessing the position of the disc was 89%. Similar autopsy studies by Westesson et al. reported accuracies of 84% for lower-space, single-contrast arthrography, and 85% and 91% for dual-space, double-contrast arthrography.(23,24,105) Previous MR studies with anatomic correlation by Westesson et al. revealed an accuracy of 73% in assessing the disc position.(143) Katzberg et al. included coronal MR imaging to achieve an accuracy of 83%.(142) The disc position was correctly assessed with CT in 50% of the cases, compared with 67% reported by Westesson et al.(143) Previously reported, high accuracies for CT imaging of disc position (81%, 87%), appear to be associated with the use of arthrographic

and surgical findings for correlation of CT results.(32-34) These techniques would limit the recognition of false negative diagnoses due to their invasiveness and the limitations that this places on patient selection.

CT evaluation of disc position resulted in a high frequency of false-positive diagnoses and a low positive predictive value in all regions examined. A greater number of false-positive findings occurred in the central and lateral regions. This differs from a previous study which reported the greatest number occurring in the medial region.(143) These false-positive reports with CT were due to an inability to identify the posterior border of the disc to make a proper determination of disc position. In the central and medial regions of the joint, the increased attenuation of the soft tissues anterior to the condyle and inferior to the bony tubercle resulted in several false reports. The tissue which is anterior to the condyle in this region is primarily the lateral pterygoid muscle and its tendon. Due to the blurring effect on the dense bone adjacent to the disc with the soft-tissue algorithm, and the small joint space, a disc which was in a superior position was often not visible with CT. Several false-negative diagnoses were made in each region due to the inability to identify the disc together with the assumption that it was in the superior position. Further information on the disc position was often gained by closely evaluating the bone algorithm image. The disc could sometimes

be identified as a lightly radiopaque structure since the blurring effect of the soft-tissue algorithm was removed.

Magnetic resonance consistently identified the disc position in the central and medial regions of the joint. Incorrect diagnoses were made in the lateral region due to a similarity between the signal intensities of disc tissue and the lateral discal ligament and joint capsule. Similar mis-diagnoses occurred in the lateral region in prior MR studies.(141,143) This region was also frequently associated with incorrect analyses in comparative anatomical studies with tomography, single-contrast arthrography and double-contrast arthrography.(2,24,110) Further differentiation of these tissues using adjusted TE and TR values for MR pulse sequences may improve the reliability of diagnosis in this region.

In a previous article comparing MR, CT and cryosectional anatomy of the joint, only limited attention was paid to the mediolateral position of the disc since it was believed that the sagittal projection would not be optimal for such an evaluation.(143) At least one of the specimens in their sample had a partial anterior disc displacement (rotational), in the lateral region. Difficulties in reliably interpreting MR and CT images from the lateral region would lead to an increase in the number of false-negative diagnoses and a decreased accuracy. Single-contrast arthrography was found to be unable to identify this type of displacement due to difficulties in differentiating the lateral part of the joint from the medial

part.(24) Two specimens in the present study had partial anterior disc displacements (rotational). One case was correctly identified by both MR and CT imaging. The other case was incorrectly assessed by both techniques due to a change in condylar position between CT imaging and refreezing of the sample.

Medial or lateral displacements (sideways or rotational) of the disc were seen in all four joints in which sagittal MR incorrectly assessed the disc position in a prior study.(141) Katzberg et al. used coronal MR in conjunction with a sagittal image to identify this type of displacement.(142) In the present study, using only sagittal imaging, a medial component of displacement was seen in eleven joints (61%). In addition to the two joints which displayed a partial anteromedial disc position (11%), four specimens had complete anteromedial rotational displacements (22%), four had superior medial sideways displacements (22%), and one joint showed a posteromedial rotational displacement (6%). A pure anterior displacement of the disc was not identified in any of the joint specimens. A similar finding was seen in the coronal results of the MR study by Westesson et al.(141) Prior studies have also shown an increased diagnostic difficulty with MR when the disc was displaced either medially or laterally.(141,143) In the present study, medial or lateral displacements did not affect the correct assessment of anteroposterior disc position by MR. On the other hand, CT correctly diagnosed the anteroposterior disc position

in only four out of eleven joints where a medial component of displacement was present.

The present findings suggest that a medial component of disc displacement is more common than a lateral component. This is in agreement with previous autopsy findings by several authors.(141,142) In contrast, Khoury and Dolan found that lateral sideways displacements were more common in a study using arthrography in clinical patients.(150)

Sagittal MR imaging revealed the medial component of disc displacement in six out of the eleven joints in which it was identified without the use of coronal imaging (54%). The inability to identify the medial disc position in the remaining five joints may be associated with the degree of displacement present. The cryomicrotome sections were made at 1mm intervals while the MR slices were 3mm thick. Rotational and sideways disc displacements were recognized with sagittal MR when either the condyle or disc was observed unaccompanied by the other. For example, a medial sideways displacement would be diagnosed if the disc were not present laterally when the condyle was seen, and the disc was observed medially after the condyle was no longer visible. It is recognized, however, that sagittal and coronal planes of imaging with MR are complementary and that both would be important for a complete assessment of the temporomandibular joint in the anteroposterior and mediolateral dimensions.

A partial or complete posterior disc position was observed in three specimens. MR identified this position in each case while CT was unable to view the soft tissue in this region. posterior disc displacements are quite uncommon with few reports in the literature. (18,27,136) The low frequency of reported occurrence may also be a result of the difficulty in diagnosing this disorder both clinically and radiographically. Previously, there has not been a technique which could reliably image this region of the joint. With arthrography, a posterior disc position would appear with a reduced size of the anterior recess in the inferior compartment when filled with radiopaque dye. This finding could incorrectly be identified as a normal joint, or one with anterior adhesions in the inferior compartment. A partial posterior disc displacement would not be recognized with any other radiographic technique, with the possible exception of double-contrast arthrography using tomography in the lateral region. However, this technique would also have difficulty identifying the disc when it is biplanar, as is usually the case when it is posteriorly positioned. (24)

In the present study, one specimen had a partial posterior rotational displacement which was most prominent in the lateral region. A second cadaver had bilateral, complete posterior disc displacements. The presence of this condition bilaterally may imply a traumatic origin. A clinical correlation, however, was unavailable for any of the autopsy specimens. In each case where the disc was completely displaced posteriorly, a biplanar

disc configuration was observed. This change in configuration appears to be a result of the change in functional loading pressure placed on the disc in this position.(47,77) The posterior condylar surface also showed significant regressive remodelling adjacent to the disc. Similar changes have been seen as a result of retrusive forces applied to the mandible in infant and adult monkey TMJs.(151,152)

Another interesting finding which was present in two of the three specimens with a posterior disc displacement, was a well-defined, biconcave area of fibrosis anterior to the anterior band of the disc. This tissue had the appearance of a "pseudo-disc" formation. CT imaging interpreted this tissue to be an anterior disc displacement in two of the specimens. MR correctly identified the fibrotic nature of this tissue. This area of fibrosis appears similar to that often seen posterior to the disc, when a portion of the posterior attachment is exposed to compressive loading by an anterior displacement of the disc.(16,74,75) Scapino observed that the normal pattern of collagen fibers present at the union between the posterior band of the disc and the anterior position of the posterior attachment, was replaced by a compact mass of fibers with fewer or no small vessels present.(16) With MR, this can be seen as a region of low-signal intensity.

MR correctly identified the fibrosis, posterior to the articular disc, in five out of the six specimens in which it was observed. Laurel et al. correlated this loss of cellu-

larity and fibrotic reorganization within the posterior attachment, with MR images in a limited histologic study.(134) The ability of MR to recognize this reorganization is significant, as these tissue changes may imply a functional adaptation or healing process which would influence future treatment protocols.

Perforations within the posterior attachment were correctly diagnosed with MR in four joints, but were not identified with CT in any case. It should be pointed out, however, that MR did not identify the perforation in the posterior attachment in itself, but only suspected it due to the chronic and degenerative changes in the joint tissues. Criteria that were often present when a perforation was suspected with MR include: significant disc displacement, degenerative changes in the condyle and eminence such as osteophytosis, erosions, or sclerosis, and an increased signal intensity in the posterior attachment which was sometimes associated with an observable break in the low-signal intensity elastic tissue of the superior lamina. Despite the success in suspecting perforations, these findings support the conclusions of prior studies which questioned the reliability of MR in diagnosing small and large perforations.(135,136,141) Large perforations in chronic conditions, with bony changes and widely separated fragments, may be seen frequently with MR. However, early conditions with small perforations would most consistently be diagnosed using arthrography, despite the risk of iatrogenic perfora-

tions.(24,105,153) Future consideration should be given to the use of other elements, such as ^{31}P and ^{19}F , for possible injection into the joint spaces prior to MR imaging. This would be beneficial in cases where the presence or absence of a perforation or adhesions are important diagnostic findings. Phosphorus-31 (^{31}P) would also offer insight into basic metabolic processes while fluorine-19 (^{19}F) could be used in fluorinated pharmaceuticals similar to what is done with radiopaque dye and fluoroscopy.

The disc morphology was correctly assessed by MR and CT in 83% and 61% of the cases, respectively. Double-contrast arthrotomography has been reported to be 93% accurate in identifying the disc configuration, while a previous correlative study of MR reported an accuracy of 60%.(105,141) The lateral region again proved to be the most difficult in which to diagnose for both techniques. The diagnostic difficulties in this region are partly due to the increased variability of disc position and configuration laterally.(18,90) A greater degree and extent of pathology has also been associated with the lateral region more than any other.(18,23,90,154) The anatomy of the joint structures in this region also pose a complication in the diagnostic reliability. MR errors, and to a lesser extent, CT errors in both soft-tissue and bone diagnosis, were associated with tangential or oblique imaging slices.(141) The lateral and medial regions of the joint are more highly contoured than the central region. An image slice in these

areas would cross at more of an oblique or tangential direction relative to the tissue surface. This affected the perceived thickness of disc tissue and bony anatomy, and decreased the ability to differentiate disc from capsular tissue. For example, an oblique section through the discal ligament or capsule would appear thicker, and may be incorrectly identified as a biplanar disc. Coronal MR imaging in conjunction with sagittal scanning should aid in the differentiation of tissue in these regions. Coronal MR imaging together with sagittal scanning was shown by Katzberg et al. to increase the diagnostic accuracy over sagittal imaging alone.(142)

Another factor which would exaggerate the effect of an oblique imaging plane is the thickness of the image slice. The MR images included a volume of material 3mm thick compared to a 1.5mm thickness of tissue with CT. These images were correlated with anatomical specimens which consisted of sharp surface images, lacking depth. In an anatomically complex region therefore, several surface images might be needed to display all the morphologic details expressed in one MR or CT slice.(149) Thus, an image which overlaid 3mm of tissue into a single plane, together with an oblique slice relative to a highly contoured surface, may result in an incorrect diagnosis.

It is in situations such as this, where the clinical and diagnostic experience of the observer are so important. The MR and CT techniques, like any other, involve a continuous learning curve in developing a reliable diagnostic acumen.

A specific background relative to the clinical conditions and detailed anatomy are fundamental in establishing a diagnostic foundation. These imaging modalities are not as technique sensitive as arthrography or fluoroscopy, however, a correct interpretation is still sensitive to the experience of the diagnostician.

Deviation from a biconcave disc morphology was seen more commonly in the lateral region than any other. In twenty-two percent of the specimens, the lateral third of the disc was biplanar, while the central and medial regions were biconcave. Similar findings were observed by other authors in cadaver studies.(18,23,154) MR correctly identified the biplanar configuration of the disc laterally in all four instances in which it was present. CT, however, was unable to identify this tissue relationship in any specimen due to the difficulty in visualizing the posterior border of the disc. Single-contrast arthrography has been shown to be completely inadequate for identification of the disc configuration, while double-contrast arthrotomography has difficulty recognizing the disc itself when the posterior band is deformed to a biplanar shape.(23,24,1-05)

Moffett has described the change in disc morphology as a deformation which occurs passively in response to physical compression.(19) The form of the disc follows its function. As the peripheral borders undergo functional compression, they deform and lose their self-positioning shape. This allows the

disc to become displaced more easily. The presence of flattening in the lateral region of the disc is thus significant as it predisposes the patient to a partial anterior displacement.(18,24) This type of displacement is not demonstrated with single-contrast arthrography and has a high correlation with osteoarthritis.(18,24,154) In the present study, a tendency is also seen to show that discs with lateral flattening are more frequently associated with a medial disc position, than are those with a biconcave morphology.

A strong relationship was observed between the disc position and its configuration (Table 10). When the disc was positioned in a superior location, deformation was rarely seen. In the two instances where deformation of a superiorly positioned disc was seen, it was limited to early flattening of the disc in the lateral region. Superior and completely anterior disc positions were more frequently associated with a consistent configuration throughout all regions of the joint. Seven joints were diagnosed as having biconcave discs. Only one of these specimens had a completely anterior displacement. Three others had partial displacements of their biconcave discs in various directions. The degree of deformation of the disc appears to be directly related to the degree of displacement. This conclusion, that disc deformation is preceded by disc displacement, was reached also by Westesson et al. in two prior studies.(13,18) Thus, a change in the shape of the disc is a sign of more advanced pathology than a displacement alone.(18)

In 9 out of 18 joints (50%), a different configuration of the disc was seen in different thirds of the joint. This is presumably in response to the variation in loading pressures on the disc in different thirds of the joint.(16) This also emphasizes the need to evaluate the morphology as well as the position of the disc in separate parts of the joint in order to establish a proper treatment plan and prognosis.

While MR consistently revealed the soft-tissue anatomy with greater clarity and detail, side-by-side comparisons of MR and CT images showed CT to be superior in displaying the osseous anatomy. The reported accuracies for both techniques in diagnosing osseous changes in the condyle and tubercle were the same (100% and 83% respectively). This result was unexpected since previous authors have questioned the reliability of MR in identifying bony changes.(128) The general focus had been on the ability of MR to image soft-tissue structures. The accuracies of both techniques are superior to the 64% accuracy reported by Rohlin et al. in their study of osseous changes using hypocycloidal tomography.(126) Donlon and Moon also found MR to be superior to corrected linear tomography in a limited study of condylar changes.(135)

The 100% accuracy of sagittal MR in diagnosing condylar changes and 83% for changes in the articular tubercle is comparable to the 94% reported in a previous study using coronal MR to identify osseous abnormalities in the TMJ complex.(142) This is, however, significantly higher than

the 60% accuracy reported by Westesson et al. using sagittal MR scanning.(141,143) It should be pointed out though, that these previous articles correlating MR images with cryosectional anatomy did not differentiate between changes in the condyle and the bony tubercle. No information was given as to the regions in which the incorrect diagnoses were made. If the present data is reanalyzed to determine the diagnostic accuracy in depicting bone abnormalities in the condyle and bony tubercle together, an accuracy of 83% is reported for both techniques. The use of coronal MR imaging in combination with sagittal scanning would assist in identifying the mediolateral osseous changes in the condyle, and may improve the diagnostic accuracy.(142) However, little benefit would be expected in improving the ability to depict bony changes in the articular eminence. This is due to the difficulty in clearly imaging the posterior slope of the eminence with an anteroposterior projection. Changes in the height of contour in an anteroposterior direction are best observed with a sagittal view.

The reported accuracy of CT in diagnosing bony changes is very similar to that seen in prior CT studies with anatomical correlations.(32,142) As with MR, CT showed greater difficulty in correctly defining the anatomy of the bony tubercle than with the condyle. A greater number of false-negative assessments of the tubercle were made with MR in the lateral and medial regions, than with CT. CT showed a higher sensitivity in detecting existing changes in this region. This is significant

since degenerative changes occur more frequently in the lateral portion of the articular eminence than in the condyle.(73) Both techniques demonstrate a greater probability in detecting a destructive lesion on the condyle than on the tubercle. The real difference in information gained from MR and CT is, in fact, greater than what is revealed by their similar accuracies. The CT images of bony anatomy consistently revealed greater detail than the MR images. Only the existence of pathology was reported rather than the degree of pathological changes. A greater difference in the accuracy of the two techniques would be expected if attention were paid to minor structural changes and the extent of pathology.(85)

Osteoarthrosis was observed in nine out of eighteen joints in this sample with a mean age of 75 years, for a frequency of 50%. Westesson and Rohlin reported an incidence of 39% in a larger study involving 126 joints.(18) In a study of 400 joints from cadavers, with ages of 40 years or older, Blackwood reported an incidence of osteoarthrosis in 40% of the specimens.(155) The results of the present study agree with previous authors who found that osteoarthrosis is associated with an altered disc position, as only one out of nine joints with osteoarthrosis did not have a displaced disc.(18,90)

As with the soft-tissue analyses, the lateral region of the condyle and articular tubercle was the most difficult to correctly diagnose with both techniques. Diagnostic difficulties in this region have also previously been reported with

tomography, arthrography, arthrotomography, CT and MR. (6,23,24,85-89,127,141) Three possible explanations for this difficulty in the present study are: 1) the superimposition of tissue due to image thickness; 2) the effects of a tangential image plane to areas of tissue contour; and 3) the challenges of precisely coordinating the image plane between different techniques. Previously, I reviewed the difficulties of comparing images of different slice thickness and the superimposition of the volume of material into a single plane. MR would superimpose the greatest volume of material due to its 3mm thickness. On the other hand, the cryosectional material is displayed as a surface image, without any depth. Therefore, several surface images might be needed to display all the morphologic details expressed in one MR or CT slice.(149) Eckerdal found similar "false images due to layer summation" in his study of tomography.(2) He reported that false appearances of both sclerosis and rarefaction were seen especially when the tissue contours were irregular in relation to the tomographic plane. Subtle anatomic details which are clearly seen in the cryosection specimen, may be seen less clearly with CT and even less with MR. This is termed a partial volume effect, and is very familiar to both techniques. This effect is seen more frequently when small structures, such as osseous changes or the thin central band of a disc, are imaged with a relatively thick slice. A prior study by Westesson et al. correlated a 3mm MR slice with a relatively thick (5mm) CT slice, which was

spaced every 3mm.(143) For this reason, a MR and CT imaging protocol was chosen which would minimize the slice thickness and maximize the spatial resolution at the expense of scanning time.

A second explanation for potential errors in the lateral region of the joint is the effect of a tangential imaging plane to areas of tissue contour.(141) Again, false interpretations of sclerosis or rarefaction could result from these images. Coronal imaging would supplement the sagittal scanning of this region and improve the diagnostic reliability of detecting osseous changes.(142)

Finally, some misdiagnoses in regional evaluations were due to the challenges of precisely coordinating the image plane between different techniques. Since the images from each technique had a different thickness, the number of slices needed to completely examine a joint varied. Approximately six images were recorded with MR, 12 images with CT, and 18 cryosections were made, per joint. Thus, each region compared 2 MR images with 4 CT images and 6 cryosections. The exact correlation of a particular image plane between the different techniques was therefore, nearly impossible. Other authors have applied indicator grids to the gross specimens to confirm the correspondence between the MR images and cryosections.(141) Some regional misdiagnoses were seen when soft-tissue and osseous changes were identified in the anatomical sections close to a margin between two regions. These changes may also have been attributed

to an adjacent region if the MR and CT images were not sectioned at precisely the same plane. This difficulty, however, would not affect the overall diagnostic accuracy since the changes would still be noted in that specimen.

It is recognized that the age and sex distribution of the sample in this study differs from that commonly seen in a clinical situation. The findings of this study will still be valid if the pathologic changes on which the comparison of techniques is based, are the same in the cadaver material as with clinical patients. (105,156) The comparison of techniques was based on the identification of disc position, configuration, and osseous changes in the condyle and articular tubercle. Since these pathologic changes are the same as those studied in the clinical situation, the accuracies reported in the present study should also apply to the use of MR and CT with clinical patients. (32,119,128,135,136)

As with all autopsy studies, information regarding the patients' TMJ symptoms and clinical histories was not available for correlation with the present findings. The presence of absence of clinical symptoms should not affect the relevance of these results since this study focused on the structural soft-tissue and osseous pathology. Similarly, the prevalence of internal derangements and an altered disc position in the present study was nearly equivalent to clinical and epidemiological studies. Internal derangements were noted in 72% of the present cases which had a mean age of 75 years. Previous

epidemiological studies by Hansson and Oberg of 67 year olds, and by Agerberg and Osterberg of 70 year olds, reported clinical signs of TMJ dysfunction in 73% and 74% of the patients respectively.(157,158) Other clinical studies have reported internal derangements in 75% of the cases studied.(60,79,80)

The experimental conditions in the present study in some ways exceeded that which is generally seen in a clinical situation. This probably resulted in an improved image quality. The risk of patient motion which would degrade the MR or CT images was eliminated. The difficulty with positioning of the head for direct sagittal CT was also reduced as the concern for radiographic exposure to the lens of the eye was removed. In a clinical setting, the head would not be rotated laterally 20° to compensate for the horizontal angulation of the condyle during direct sagittal scanning. The use of longer scanning times was also available to optimize the image quality.

On the other hand, the additional diagnostic data which could be gained from a MR or CT series in the open-mouth position was not available. This series would add valuable information about the possibility for reduction of a disc displacement which has clinical significance.(128,135,140) The open-mouth MR image is also easier to interpret as the posterior attachment tissues becomes engorged with blood. This tissue would then have a higher signal intensity which contrasts well with the low signal of the disc, improving the ability to identify the disc position. The effects of the experimental conditions such as the improvement

in image quality and the lack of an open-mouth image for correlation, should not affect our comparison of the two diagnostic modalities since both techniques were affected similarly.

In the present study, an emphasis was placed on imaging the cadaver specimens with MR as soon as possible after death. The tissues were refrigerated until the scans could be performed since it is recognized that the T_1 value is stable only for approximately 6 hours at room temperature.(159) This decrease in the T_1 value with time appears to be secondary to the evaporation of water from the specimens. After 24 hours, a significant decrease in the measured value of T_1 occurs which may be inhibited by refrigeration. The T_2 value was remarkably stable for at least 48 hours. The probable decrease in the T_1 value of the present sample would result in a more intense MR signal, and thus a brighter image than would be seen with clinical tissues. Thus in a clinical setting, a decreased imaging time and lack of T_1 degradation would result in a slightly darker image than was seen in this study. The effect that this would have on the diagnostic accuracy of structural changes in the joint is questionable and should not significantly influence the results of this study.

The CT evaluation was performed on specimens after thawing in an attempt to avoid the attenuation differences which occur in frozen tissue. Previous authors have shown that frozen specimens have a considerably altered grey-scale with CT and

that different tissues cannot be identified by their attenuation value alone.(149,160,161) The distinction between muscle and fat tissue was reduced in frozen specimens.(161) In the comparison of MR and CT with autopsy specimens by Westesson et al., their CT evaluation was performed on frozen specimens.(12-7) Any effect from the attenuation differences appears to have been minimal since the present study made similar conclusions regarding soft-tissue and osseous anatomy with CT, and both studies attempted to optimize the quality of each individual image despite the recorded attenuation value.

Since the specimens were thawed prior to the CT series, then refrozen before the anatomical sectioning, the potential for movement of the condyle-disc complex between imaging stages exists. This type of error accounts for subtle discrepancies in the condylar position within the study. It also appears to be the cause of a false-negative diagnosis in the lateral region which was seen with both MR and CT. In this case, the condylar position was apparently altered prior to refreezing the specimen after the CT images were completed. The MR and CT images both show a disc in superior position relative to the condyle, while the cryosection clearly shows a displaced disc and condyle relationship. No other misdiagnoses appear to have been the result of a positional change in tissue relationships between diagnostic stages. Another difficulty with the experimental protocol is the general presence of laxity between the joint structures. This could not be avoided in

the present study since no attempt was made to select specimens with a distinct closed-jaw intercuspal relationship. Both of these errors could be avoided in future studies if the joint specimens were first placed in the closed-jaw position, frozen by repeated applications of liquid nitrogen, then placed in acrylic blocks to maintain the positional relationships throughout the study.(141)

CONCLUSIONS

In review of the various diagnostic modalities which are available for a complete evaluation of the TMJ, consideration must be given to the strengths and weaknesses of each technique. Single-contrast arthrography with fluoroscopy was shown to be 84% accurate in depicting the position of the disc while proving most beneficial in assessing functional joint dynamics.(2-4,105) The invasive technique suffers, however, from an inability to provide diagnostic information regarding the osseous anatomy or the configuration of the disc. Since this information is necessary to understand joint function and to appropriately treatment plan, further radiographic procedures are usually required.(13) This technique is also limited in its ability to diagnose a partial anterior disc position since differentiation of the mediolateral regions of the joint is not possible.(24) Double-contrast arthrography with tomography offers further insight into the soft-tissue morphologic relationships within each region of the joint. Disc position has been diagnosed with an accuracy of 85-91%, while the disc morphology was correctly interpreted in 93% of the cases.(23,105)

This technique is also invasive and requires a higher exposure to radiation, as well as a greater degree of technical difficulty. Like single-contrast arthrography, perforations are readily seen with this modality. However, the positive predictive value of both techniques reflect the risk of iatrogenic perfora-

tions.(105) The double-contrast technique has difficulties in assessing the lateral region of the joint due to tomographic limitations, and would also require further radiographic evaluation for osseous anatomy.(23,105)

With direct sagittal CT scanning, a method exists for assessing the bone and soft-tissue structures with a single study in a non-invasive way. CT evaluation of the joint has proven to be more accurate in diagnosing osseous abnormalities than any other technique, including hypocycloidal tomography.(126,143,144) Previously, direct sagittal CT was shown to be 87% accurate in depicting bony changes, while the present study reported an accuracy of 83% for abnormalities of the tubercle and 100% for condylar changes.(143) Regional evaluation of the TMJ complex is possible with this technique despite a lower diagnostic accuracy in the lateral third of the joint. A direct image of the disc is seen with CT. However, the present study revealed a diagnostic accuracy of 50% in identifying the disc position while previous authors found a 67% accuracy.(143) The reduced accuracy is a result of limited soft-tissue resolution and an inability to identify the posterior border of the disc. This technique is also associated with an exposure to ionizing radiation, which with the direct sagittal approach, is in close proximity to the lens of the eye.

The MR technique offers several significant advantages over previous modalities. As with CT, MR is able to assess both bone and soft-tissue structures with a single technique. MR

acquires this information in a single series while CT uses separate images to focus on the attenuation of bone and soft-tissue structures. The ability of MR to study the joint regionally offers greater insight into the pathophysiology of the joint as a three-dimensional complex. The assessment of bony abnormalities with MR proved to be more accurate than tomography and similar to the accuracy obtained with CT. However, the clarity and detail of osseous structures depicted with MR was inferior to that seen with CT. MR is also completely non-invasive and does not require exposure to ionizing radiation. These factors make MR an excellent modality for longitudinal studies of joint pathophysiology. Due to the excellent soft-tissue resolution, a direct image of the entire disc in its anteroposterior and mediolateral dimensions can be obtained. In the present study, MR correctly assessed the disc position with an accuracy of 89%. Previous authors reported a diagnostic accuracy of 73% for sagittal MR and 83% with the addition of coronal MR imaging.(142,143)

Another significant advantage of MR is the ability to identify the configuration of the disc for a complete diagnosis and treatment plan. This configuration was correctly assessed with MR in 83% of the cases, which compared favorably to the 85-93% accuracy reported with double-contrast arthro-tomography.(23,105) Improved tissue characterization and the identification of histologic alterations in the disc and posterior attachment tissues offers further information which is unavailable

with other techniques. The excellent soft-tissue resolution available with MR may also help to clarify the definition of normality, relative to joint morphology and disc position when clinical signs and symptoms of dysfunction are absent.

The limitations of the MR technique have been reported to include an inability to assess functional joint dynamics since static images are recorded.(105,131,143) However, an imaging protocol is now available in which a series of MR images is obtained while the mouth is incrementally opened using a "fast-scan," or GRASS pulse sequence.(137) The images are then replayed in a video movie mode to reproduce the dynamics of joint movement. This cine-MR protocol offers significant potential in overcoming the limitations of MR in assessing functional joint dynamics.

Identification of perforations of the disc and posterior attachment tissues is unreliable with MR. The present study showed that large perforations in chronic conditions with bony changes, may be suspected with this modality. However, arthrography continues to be the technique of choice to accurately depict perforations.(23,105)

In summary, the purpose of this study was to evaluate the accuracy of MR and CT imaging within different regions of the TMJ, and to identify the strengths and limitations of each technique in assessing the bony and soft-tissue anatomy of the joint. As previous authors have found significant variation in disc position, configuration, and osseous abnormalities in separate parts of the joint, it follows that optimal treatment

planning and prognostication will require a three-dimensional understanding of joint pathophysiology. While CT was superior in depicting osseous changes in all regions, an inability to identify the posterior border of the disc and the increased attenuation of tissues anterior to the condyle resulted in limitations in accurately depicting the configuration and position of the disc. MR correctly assessed the bony anatomy of the condyle and articular tubercle in a high percentage of the cases. However, it excelled in the soft-tissue assessment of disc position and morphology. Diagnostic errors occurred due to difficulties in differentiating disc tissue from capsular tissue and due to tangential imaging planes. The use of coronal MR scanning would supplement the sagittal images and decrease these diagnostic errors. Both techniques proved to be most accurate in the central two thirds of the joint, emphasizing the need for caution in diagnosing the most lateral and medial regions. Based on this information, magnetic resonance imaging appears to be the procedure of choice in the diagnosis and assessment of soft-tissue and osseous abnormalities within the temporomandibular joint.

APPENDIX

Table 1: Age and Sex Distribution of Sample

	<u>Specimen Number*</u>										
	1	2	3	4	5	6	7	8	9	10	11
Female		(69)	(91)	(67)	(73)	(71)	(51)	(86)		(88)	(93)
Male	(71)								(58)		
Total											
Female	9										
Male	2										

*Age in parentheses

Mean age: Male 64 years. Female 77 years. Total 74 years.

Table 2: Diagnostic Accuracy of MR and CT for Disc Position
(n = 18)

<u>Method</u>	<u>DIAGNOSIS</u>				<u>Accuracy (%)*</u>
	<u>True Neg.</u>	<u>False Neg.</u>	<u>True Pos.</u>	<u>False Pos.</u>	
MR	8	1	8	1	89
CT	4	2	5	7	50

* Number of correct analyses divided by all analyses.

Table 3: Diagnostic Accuracy of MR and CT for Disc Morphology
(n = 18)

<u>Method</u>	<u>DIAGNOSIS</u>				<u>Accuracy (%)</u> *
	<u>True Neg.</u>	<u>False Neg.</u>	<u>True Pos.</u>	<u>False Pos.</u>	
MR	3	1	12	2	83
CT	2	4	9	3	61

* Number of correct analyses divided by all analyses.

Table 4: Diagnostic Accuracy of MR and CT for Osseous Anatomy
of the Condyle (n = 18)

<u>Method</u>	<u>DIAGNOSIS</u>				<u>Accuracy (%)</u> *
	<u>True Neg.</u>	<u>False Neg.</u>	<u>True Pos.</u>	<u>False Pos.</u>	
MR	2	0	16	0	100
CT	2	0	16	0	100

* Number of correct analyses divided by all analyses.

Table 5: Diagnostic Accuracy of MR and CT for Osseous Anatomy
of the Tubercle (n = 18)

<u>Method</u>	<u>DIAGNOSIS</u>				<u>Accuracy (%)</u> *
	<u>True Neg.</u>	<u>False Neg.</u>	<u>True Pos.</u>	<u>False Pos.</u>	
MR	1	3	14	0	83
CT	0	2	15	1	83

* Number of correct analyses divided by all analyses.

Table 6: Sensitivity, Specificity, and Positive and Negative Predictive Values of MR and CT in the Diagnosis of Disc Position, Morphology, and Changes of the Bone in the Condyle and Tubercle (n = 18)

Method	Diagnosis	Sensi- tivity ¹	Speci- ficity ²	Positive Predictive Value ³	Negative Predictive Value ⁴
MR	Disc Position	0.89	0.89	0.89	0.89
CT	Disc Position	0.71	0.36	0.42	0.67
MR	Disc Morphology	0.92	0.60	0.86	0.75
CT	Disc Morphology	0.69	0.40	0.75	0.33
MR	Condylar Change	1.00	1.00	1.00	1.00
CT	Condylar Change	1.00	1.00	1.00	1.00
MR	Tubercle Change	0.82	1.00	1.00	0.25
CT	Tubercle Change	0.88	0.00	0.94	0.00

¹ Proportion of existing changes detected

² Proportion of normal cases identified

³ Proportion of positive diagnoses that are correct

⁴ Proportion of negative diagnoses that are correct

Table 7: Diagnostic Accuracy of MR and CT for Disc Position Within Each Region (n = 18)

Method	<u>DIAGNOSIS</u>				<u>Accuracy (%)</u> L / C / M
	<u>True</u> <u>Neg.</u>	<u>False</u> <u>Neg.</u>	<u>True</u> <u>Pos.</u>	<u>False</u> <u>Pos.</u>	
	L/C/M	L/C/M	L/C/M	L/C/M	
MR	8/11/12	1/0/0	8/7/6	1/0/0	89/100/100
CT	5/ 6/ 9	4/2/4	3/3/2	6/7/3	44/ 50/ 61

Table 8: Position of the Disc Relative to the Condyle
(n =18).

	Super.	Anter.	Supero- Medial	Partial Antero- Medial	Antero- Medial	Partial Posterior	Pos- terior
# of Joints	5	0	4	2	4	1	2
Per- centage	28	0	22	11	22	6	11

Table 9: Diagnostic Accuracy of MR and CT for Disc Morphology
Within Each Region (n = 18)

Method	<u>DIAGNOSIS</u>				<u>Accuracy (%)</u> L / C/ M
	True <u>Neg.</u>	False <u>Neg.</u>	True <u>Pos.</u>	False <u>Pos.</u>	
	L/C/M	L/C/M	L/C/M	L/C/M	
MR	4/10/12	1/1/0	10/7/6	3/0/0	78/94/100
CT	4/ 6/ 8	4/2/2	6/6/4	4/4/4	56/67/ 67

Table 10: Correlation of Disc Position and Disc Configuration Identified From Anatomical Sectioning (n = 18)*

Disc Configuration	<u>DISC POSITION</u>						Total
	Super. Medial	Superior/ Medial	Partial Antero-Medial	Antero-Medial	Partial Pos-terior	Pos-terior	
Bi-concave	3(17)	1(6)	1(6)	1(6)	1(6)		7(39)
Biconcave Lat. 1/3 of even thickness	2(11)	2(11)					4(22)
Even thickness			1(6)			2(11)	3(17)
Biconvex				3(17)			3(17)
Different config. in diff. thirds		1(6)					1(6)
Total	5(28)	4(22)	2(11)	4(22)	1(6)	2(11)	

*Percentages are recorded in parentheses adjacent to the number of specimens #(%).

Table 11: Diagnostic Accuracy of MR and CT for Osseous Anatomy of the Condyle Within Each Region (n = 18)

Method	<u>DIAGNOSIS</u>					
	True Neg.	False Neg.	True Pos.	False Pos.	<u>Accuracy (%)</u>	
	L/C/M	L/C/M	L/C/M	L/C/M	L	C / M
MR	3/2/4	2/0/2	12/16/11	1/0/1	83/100/83	
CT	2/2/4	2/0/1	12/16/12	2/0/1	78/100/89	

Table 12: Diagnostic Accuracy of MR and CT for Osseous Anatomy of the Tubercle Within Each Region (n = 18)

Method	<u>DIAGNOSIS</u>				<u>Accuracy (%)</u> L / C / M
	<u>True Neg.</u>	<u>False Neg.</u>	<u>True Pos.</u>	<u>False Pos.</u>	
	L/C/M	L/C/M	L /C /M	L/C/M	
MR	3/3/7	4/1/3	10/14/6	1/0/2	72/94/72
CT	3/2/6	2/2/0	12/13/9	1/1/3	83/83/83

Table 13: Frequency and Distribution of Remodelling and Osteoarthritic Changes in the Condyle and Tubercle (n = 18)*

	<u>Lateral</u>	<u>Central</u>	<u>Medial</u>
	<u>N/R/O</u>	<u>N/R/O</u>	<u>N/R/O</u>
Condyle	4/ 8/6	2/ 8/8	5/8/5
Eminence	4/10/4	3/11/4	9/6/3

* N/R/O = Normal/Remodelling/Osteoarthrosis

Table 14: Sensitivity, Specificity of MR and CT in the Diagnosis of Disc Position, Morphology, and Osseous Changes of the Condyle and Tubercle Within Each Region (n = 18)

Method	<u>Diagnosis</u>	<u>Sensitivity¹</u>	<u>Specificity²</u>
		L / C / M	L / C / M
MR	Disc Position	0.89/1.00/1.00	0.89/1.00/1.00
CT	Disc Position	0.43/0.60/0.33	0.45/0.46/0.75
MR	Disc Morphology	0.91/0.88/1.00	0.57/1.00/1.00
CT	Disc Morphology	0.60/0.75/0.67	0.50/0.60/0.67
MR	Condylar Change	0.86/1.00/0.85	0.75/1.00/0.86
CT	Condylar Change	0.86/1.00/0.92	0.50/1.00/0.80
MR	Tubercle Change	0.71/0.93/0.67	0.75/1.00/0.78
CT	Tubercle Change	0.86/0.87/1.00	0.75/0.67/0.67

¹ Proportion of existing changes detected

² Proportion of normal cases identified

Table 15: Positive and Negative Predictive Values of MR and CT in the Diagnosis of Disc Position, Morphology, and Osseous Changes of the Condyle and Tubercle Within Each Region
(n = 18)

<u>Method</u>	<u>Diagnosis</u>	<u>Positive Predictive Value³</u>			<u>Negative Predictive Value⁴</u>		
		L /	C /	M	L /	C /	M
MR	Disc Position	0.89/	1.00/	1.00	0.89/	1.00/	1.00
CT	Disc Position	0.33/	0.30/	0.40	0.56/	0.75/	0.69
MR	Disc Morphology	0.77/	1.00/	1.00	0.80/	0.91/	1.00
CT	Disc Morphology	0.60/	0.60/	0.50	0.50/	0.75/	0.80
MR	Condylar Change	0.92/	1.00/	0.92	0.60/	1.00/	0.67
CT	Condylar Change	0.86/	1.00/	0.92	0.50/	1.00/	0.80
MR	Tubercle Change	0.91/	1.00/	0.75	0.43/	0.75/	0.70
CT	Tubercle Change	0.92/	0.93/	0.75	0.60/	0.50/	1.00

³ Proportion of positive diagnoses that are correct

⁴ Proportion of negative diagnoses that are correct

OSSEOUS ANATOMY

Specimen		Condyle				Eminence			
		L/C/M Overall				L/C/M Overall			
1 Right	MR	R	R	N	(R)	N	N	N	(N)
	CT	R	R	N	(R)	R	N	N	(R)
	(Cryo) Anat	N	R	N	(R)	N	N	N	(N)
<hr/>									
1 Left	MR	R	R	R	(R)	R	R	R	(R)
	CT	R	R	R	(R)	R	R	R	(R)
	(Cryo) Anat	R	R	R	(R)	R	R	N	(R)
<hr/>									
2 Right	MR	R	R	R	(R)	R	R	R	(R)
	CT	R	R	R	(R)	N	R	R	(R)
	(Band) Anat	R	R	R	(R)	N	R	R	(R)
<hr/>									
2 Left	MR	N	R	R	(R)	R	R	R	(R)
	CT	R	R	R	(R)	O	R	R	(O)
	(Band) Anat	R	R	R	(R)	O	R	R	(O)
<hr/>									
3 Right	MR	N	O	R	(O)	R	R	N	(R)
	CT	O	O	R	(O)	R	R	R	(R)
	(Band) Anat	N	O	N	(O)	R	R	R	(R)
<hr/>									
3 Left	MR	O	O	R	(O)	R	O	R	(O)
	CT	O	O	R	(O)	R	R	R	(R)
	(Band) Anat	O	O	R	(R)	R	O	N	(O)
<hr/>									
4 Right	MR	O	O	O	(O)	O	O	R	(O)
	CT	O	O	O	(O)	O	O	R	(O)
	(N.A.) Anat	N.A.				N.A.			
<hr/>									
4 Left	MR	O	O	R	(O)	O	R	N	(O)
	CT	O	O	R	(O)	R	O	R	(O)
	(N.A.) Anat	N.A.				N.A.			

OSSEOUS ANATOMY

Specimen	Condyle				Eminence			
	L/C/M Overall				L/C/M Overall			
5 Right	MR	R	R	O (O)	R	R	R (R)	
	CT	O	O	R (O)	R	O	R (O)	
(N.A.) Anat		N.A.			N.A.			
<hr/>								
5 Left	MR	R	R	R (R)	R	R	R (R)	
	CT	O	R	R (O)	O	R	R (O)	
(N.A.) Anat		N.A.			N.A.			
<hr/>								
6 Right	MR	O	O	O (O)	R	R	N (R)	
	CT	O	O	O (O)	R	R	N (R)	
(Cryo) Anat		O	O	O (O)	R	R	N (R)	
<hr/>								
6 Left	MR	O	O	O (O)	R	R	N (R)	
	CT	O	O	O (O)	R	R	R (R)	
(Cryo) Anat		O	O	O (O)	R	R	R (R)	
<hr/>								
7 Right	MR	R	R	N (R)	N	R	N (R)	
	CT	R	R	N (R)	N	R	R (R)	
(Cryo) Anat		R	R	N (R)	R	R	R (R)	
<hr/>								
7 Left	MR	N	R	N (R)	N	N	N (N)	
	CT	R	R	N (R)	N	R	N (R)	
(Cryo) Anat		R	R	N (R)	N	R	N (R)	
<hr/>								
8 Right	MR	N	N	N (N)	N	R	N (R)	
	CT	N	N	N (N)	N	N	N (N)	
(Band) Anat		N	N	N (N)	N	R	N (R)	
<hr/>								
8 Left	MR	R	N	N (R)	R	N	N (R)	
	CT	N	N	R (R)	R	N	N (R)	
(Cryo) Anat		R	N	R (R)	R	N	N (R)	

OSSEOUS ANATOMY

Specimen		Condyle				Eminence			
		L/C/M Overall				L/C/M Overall			
9 Right	MR	R	R	R	(R)	N	N	N	(N)
	CT	N	R	N	(R)	N	R	N	(R)
	(Band) Anat	R	R	R	(R)	R	N	N	(R)
<hr/>									
9 Left	MR	R	R	N	(R)	R	R	N	(R)
	CT	R	R	R	(R)	R	R	R	(R)
	(Band) Anat	R	R	R	(R)	R	R	N	(R)
<hr/>									
10 Right	MR	O	O	O	(O)	O	O	O	(O)
	CT	O	O	O	(O)	O	O	O	(O)
	(Cryo) Anat	O	O	O	(O)	O	O	O	(O)
<hr/>									
10 Left	MR	N	O	R	(O)	N	R	R	(R)
	CT	N	O	R	(O)	R	R	R	(R)
	(Cryo) Anat	N	O	R	(O)	R	R	R	(R)
<hr/>									
11 Right	MR	O	O	O	(O)	O	O	O	(O)
	CT	O	O	O	(O)	O	O	O	(O)
	(Cryo) Anat	O	O	O	(O)	O	O	O	(O)
<hr/>									
11 Left	MR	O	O	O	(O)	O	O	O	(O)
	CT	O	O	O	(O)	O	O	O	(O)
	(Cryo) Anat	O	O	O	(O)	O	O	O	(O)

SOFT TISSUE

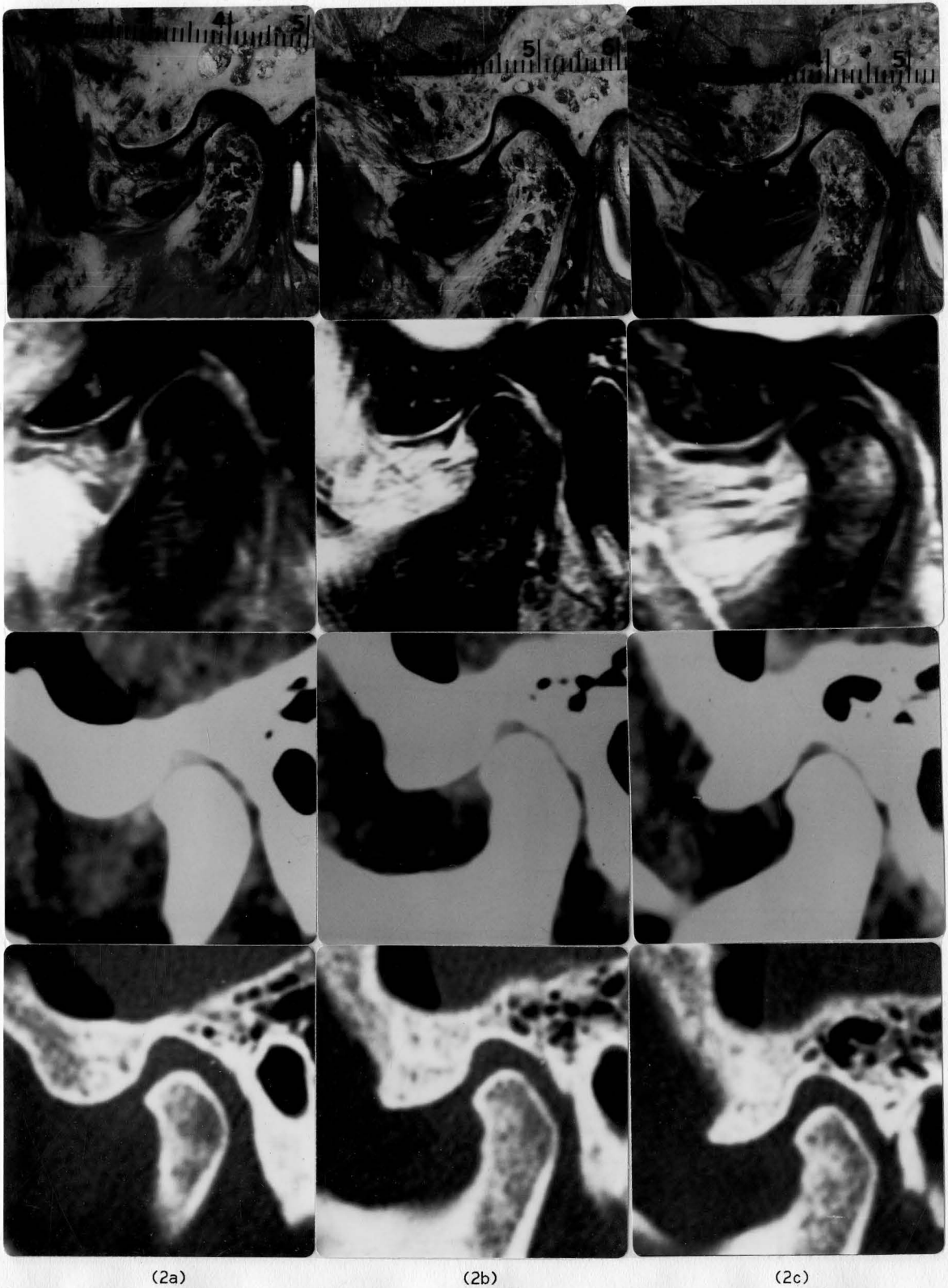
Specimen		Disc Position			Disc Morphology			Posterior Attachment		
		L/C/M	Overall		L/C/M	Overall		L/C/M	Overall	
1 Right	MR	P P P	(P)med	D D D	(D)	F F F	(F)			
	CT	S S S	(S)	- - -	(B)	- - -	(F)			
	(Cryo) Anat	P P P	(P)med	D D D	(D)	N F F	(F)			
1 Left	MR	P P P	(P)	B D D	(D)	F N F	(F)			
	CT	A A S	(A)	D D D	(D)	- - -				
	(Cryo) Anat	P P P	(P)	D D D	(D)	N F F	(F)			
2 Right	MR	P P S	(P)	D D B	(D)	N F F	(F)			
	CT	S A A	(A)	B D D	(B)	- - -				
	(Band) Anat	P P S	(P)	B D B	(D)	N F N	(F)			
2 Left	MR	P P P	(P)	B D D	(D)	F N F	(F)			
	CT	A A S	(A)	D D D	(D)	- - -				
	(Cryo) Anat	P P P	(P)	D D D	(D)	N F F	(F)			
3 Right	MR	S S S	(S)	D B B	(D)	N N N	(N)			
	CT	A A A	(A)	D D D	(D)	- - -				
	(Band) Anat	S S S	(S)med	B B B	(B)	N N N	(N)			
3 Left	MR	A S S	(A)	D B B	(D)	F N N	(F)			
	CT	A S S	(A)	B - -	(B)cal	- - -				
	(Band) Anat	A S S	(A)med	B B B	(B)cal	F N N	(F)			
4 Right	MR	A A A	(A)med	D D D	(D)	N N N	(N)			
	CT	A A A	(A)med	D D D	(D)	- - -				
	(N.A.) Anat	N.A.		N.A.		N.A.				
4 Left	MR	A A A	(A)med	D D D	(D)	N N N	(N)			
	CT	A A S	(A)	D B -	(D)	- - -				
	(N.A.) Anat	N.A.		N.A.		N.A.				

SOFT TISSUE

Specimen		Disc Position			Disc Morphology			Posterior Attachment					
		L/C/M	Overall		L/C/M	Overall		L/C/M	Overall				
5 Right (N.A.)	MR	A	A	A	(A)	-	D	D	(D)	N	N	F	(F)
	CT	S	S	S	(S)	-	-	-		-	-	-	
	Anat	N.A.			N.A.			N.A.					
5 Left (N.A.)	MR	-	S	S	(S)	-	D	D	(D)	N	N	N	(N)
	CT	A	A	A	(A)	-	-	-		-	-	-	
	Anat	N.A.			N.A.			N.A.					
6 Right (Cryo)	MR	S	S	S	(S)med	D	B	B	(D)	F	P	P	(P)
	CT	S	S	S	(S)	B	B	B	(B)	-	-	-	
	Anat	S	S	S	(S)med	D	B	B	(D)	F	F	P	(P)
6 Left (Cryo)	MR	S	S	S	(S)	D	B	B	(D)	N	N	N	(N)
	CT	S	S	S	(S)	B	B	B	(B)	-	-	-	
	Anat	S	S	S	(S)	D	B	B	(D)	N	N	N	(N)
7 Right (Cryo)	MR	S	S	S	(S)med	D	B	B	(D)	N	N	N	(N)
	CT	S	S	S	(S)	D	B	B	(D)	-	-	-	
	Anat	S	S	S	(S)	D	B	B	(D)	N	N	N	(N)
7 Left (Cryo)	MR	S	S	S	(S)	D	B	B	(D)	F	N	N	(F)
	CT	A	A	S	(A)	D	D	B	(D)	-	-	-	
	Anat	S	S	S	(S)	D	B	B	(D)	N	N	N	(N)
8 Right (Band)	MR	A	S	S	(A)	B	B	B	(B)	N	F	F	(F)
	CT	-	S	S	(S)	B	B	B	(B)	-	-	-	
	Anat	S	S	S	(S)	B	B	B	(B)	N	N	N	(N)
8 Left (Cryo)	MR	A	A	A	(A)med	B	B	B	(B)	N	N	N	(N)
	CT	A	S	S	(A)	D	B	B	(D)	-	-	-	
	Anat	A	A	A	(A)med	B	B	B	(B)	N	N	N	(N)

SOFT TISSUE

Specimen		Disc Position		Disc Morphology		Posterior Attachment	
		L/C/M	Overall	L/C/M	Overall	L/C/M	Overall
9 Right (Band)	MR	S S S	(S)	D B B	(D)	N N N	(N)
	CT	A A S	(A)	D D D	(D)	- - -	
	Anat	S S S	(S)med	D B B	(D)	N N N	(N)
9 Left (Band)	MR	S S S	(S)med	B B B	(B)	N N N	(N)
	CT	A A S	(A)	D D D	(D)	- - -	
	Anat	S S S	(S)med	B B B	(B)	N N N	(N)
10 Right (Cryo)	MR	A A A	(A)med	D D D	(D)	P P P	(P)
	CT	A A S	(A)	D D B	(D)cal	- - -	
	Anat	A A A	(A)med	D D D	(D)	P P P	(P)
10 Left (Cryo)	MR	S S S	(S)	D D D	(D)	N F F	(F)
	CT	S S S	(S)	D D D	(D)	- - -	
	Anat	A A S	(A)med	D D D	(D)	N F F	(F)
11 Right (Cryo)	MR	A A A	(A)	D D D	(D)	P P P	(P)
	CT	S A A	(A)	B D D	(D)	- - -	
	Anat	A A A	(A)med	D D D	(D)cal	P P P	(P)
11 Left (Cryo)	MR	- A A	(A)med	- D D	(D)	P P P	(P)
	CT	A A A	(A)	D D D	(D)cal	- - -	
	Anat	- A A	(A)med	- D D	(D)cal	P P P	(P)



(2a) (2b) (2c)

Figure 2. Sagittal correlation of left TMJ of specimen number seven. Lateral (a), central (b), and medial (c) regions display a biconcave disc in a superior position. (Row 1 - anatomical cryosections; Row 2 - MR images; Row 3 - CT soft-tissue images; Row 4 - CT bone images)

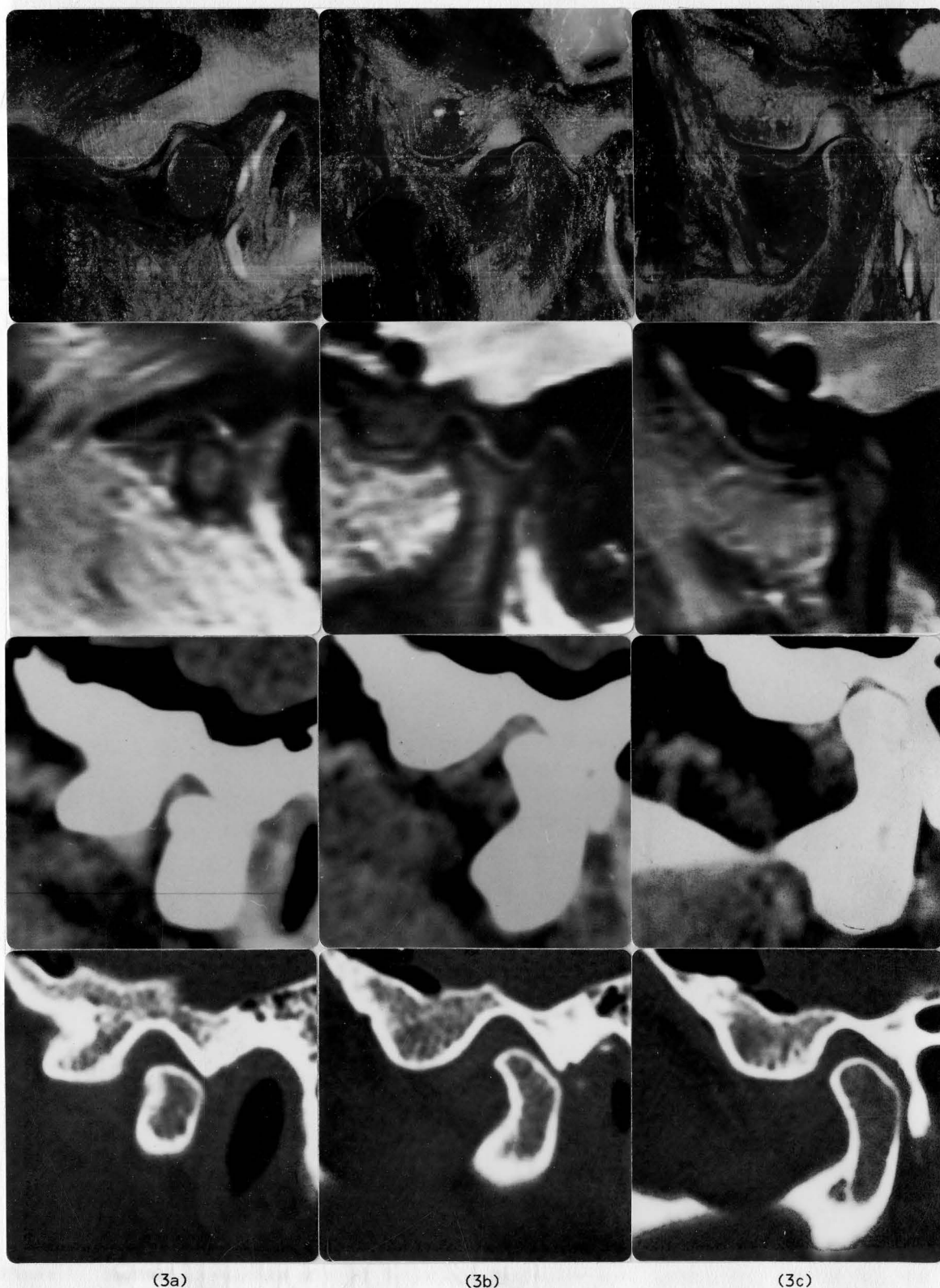


Figure 3. Sagittal correlation of right TMJ of specimen number three. Lateral (a), central (b), and medial (c) regions display a biconcave disc in a superior position. CT soft-tissue images were incorrectly interpreted to have a deformed disc in an anterior position (Row 3).

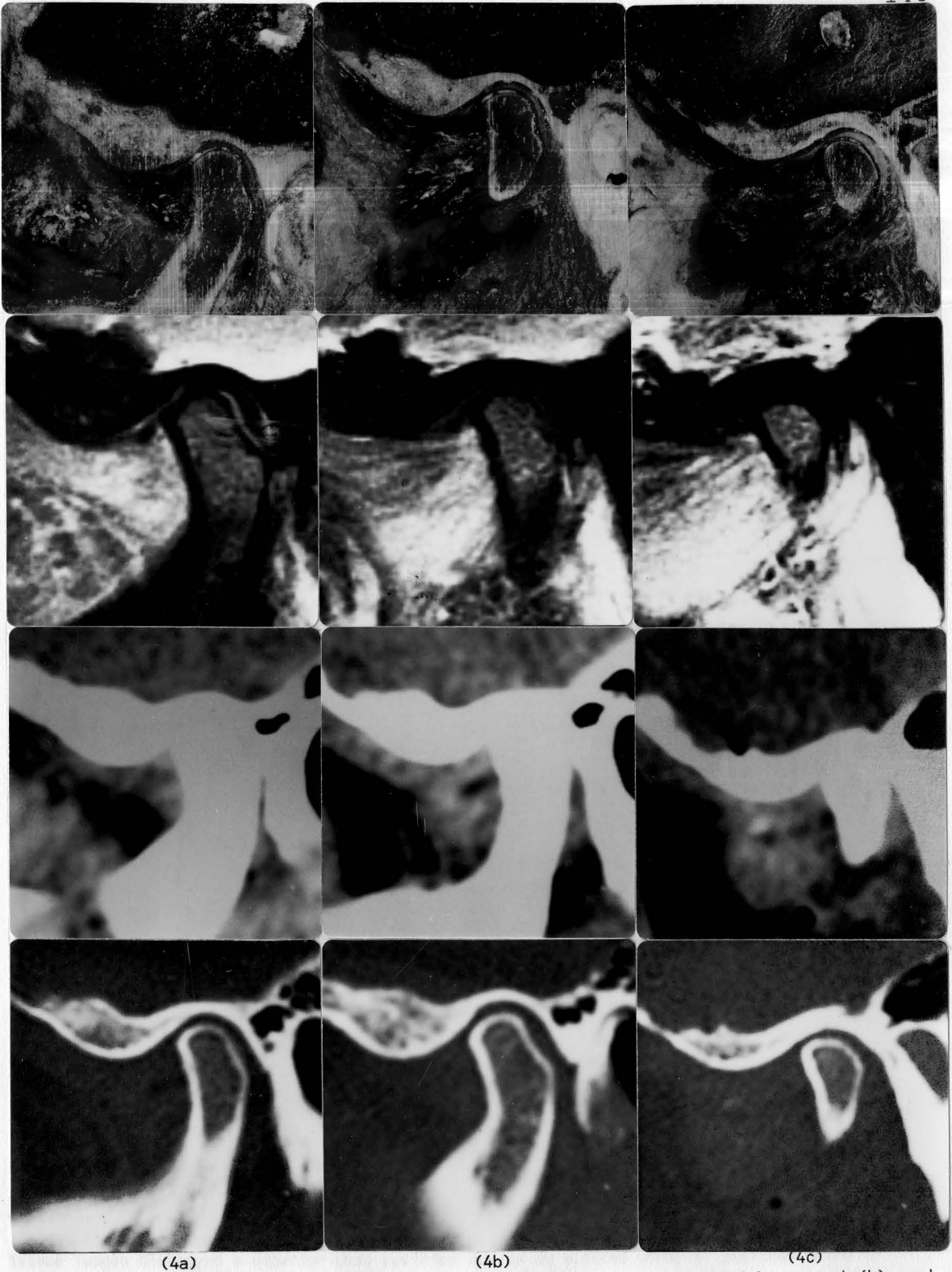


Figure 4. Sagittal correlation of right TMJ of specimen number one. Lateral (a), central (b), and medial (c) regions display a deformed disc in a posterior position, with a pseudo-disc formation in superior position. CT soft-tissue assessment could not ascertain the disc position or configuration, which was therefore assumed to be in a superior position (Row 3).

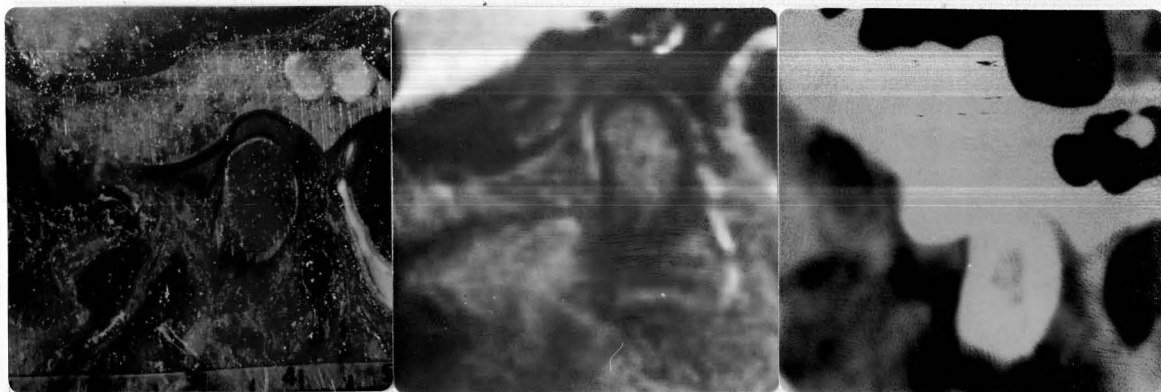

Figure 5. Sagittal correlation of right TMJ of specimen number eight. A biconcave disc with a thinning central band was identified in a superior position in this lateral region. A false-positive assessment of an anterior disc position was made with MR, due to the decreased signal intensity of the joint capsule and disc tissue.

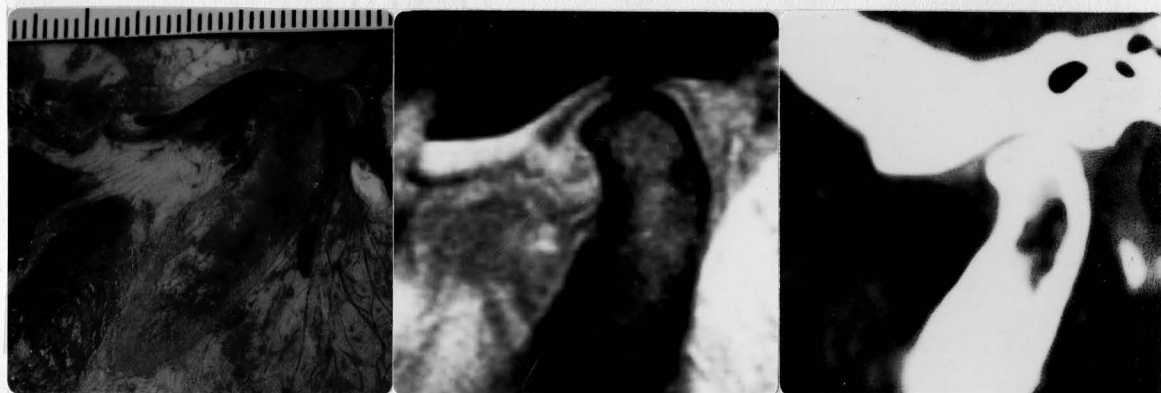

Figure 6. Sagittal correlation of left TMJ of specimen number ten. A deformed disc was identified in the cryosection to be in an anterior position in the lateral region. Both the MR and CT soft-tissue images displayed a superior disc position due to an altered condylar position prior to cryosectional analysis.

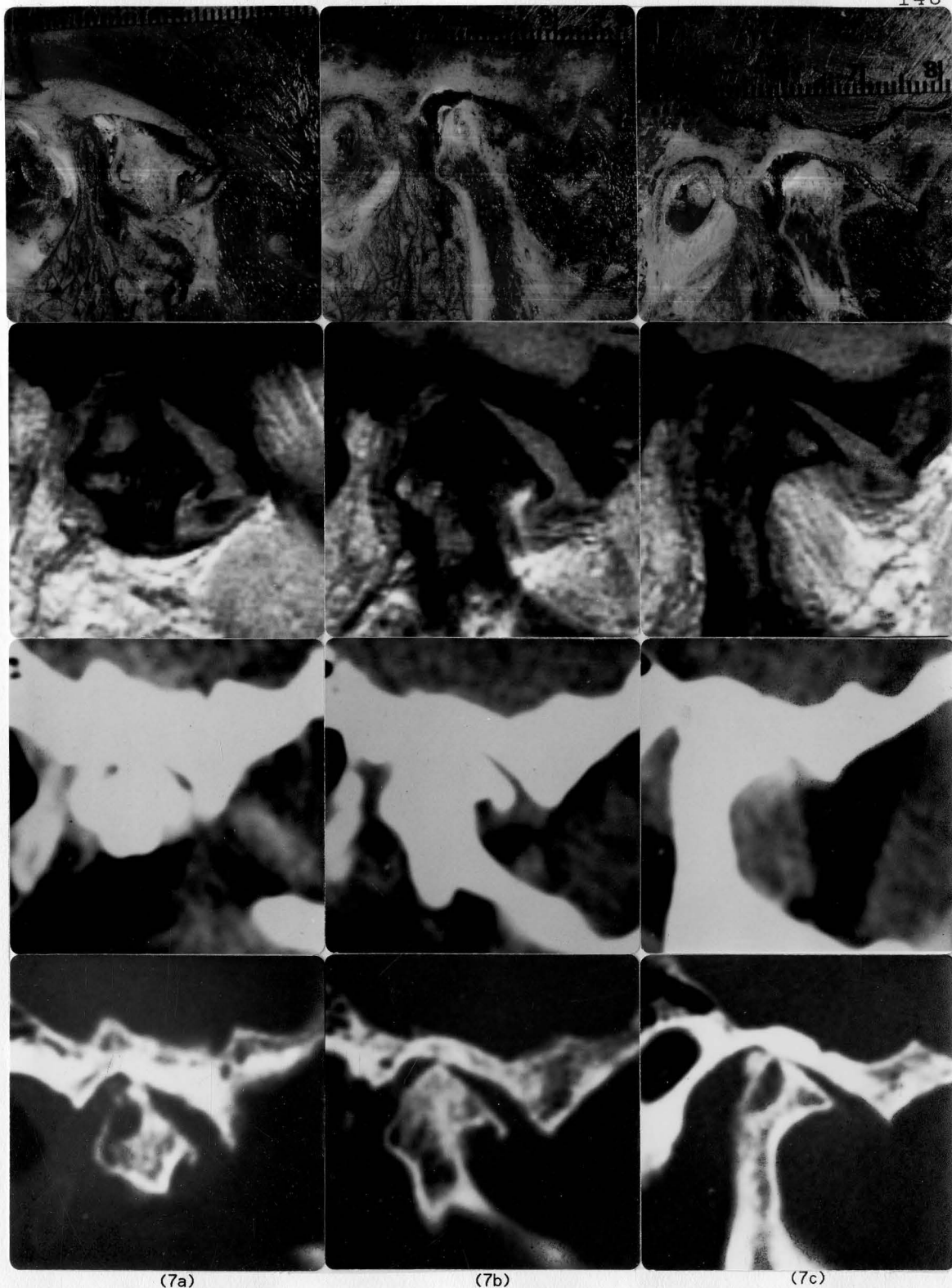
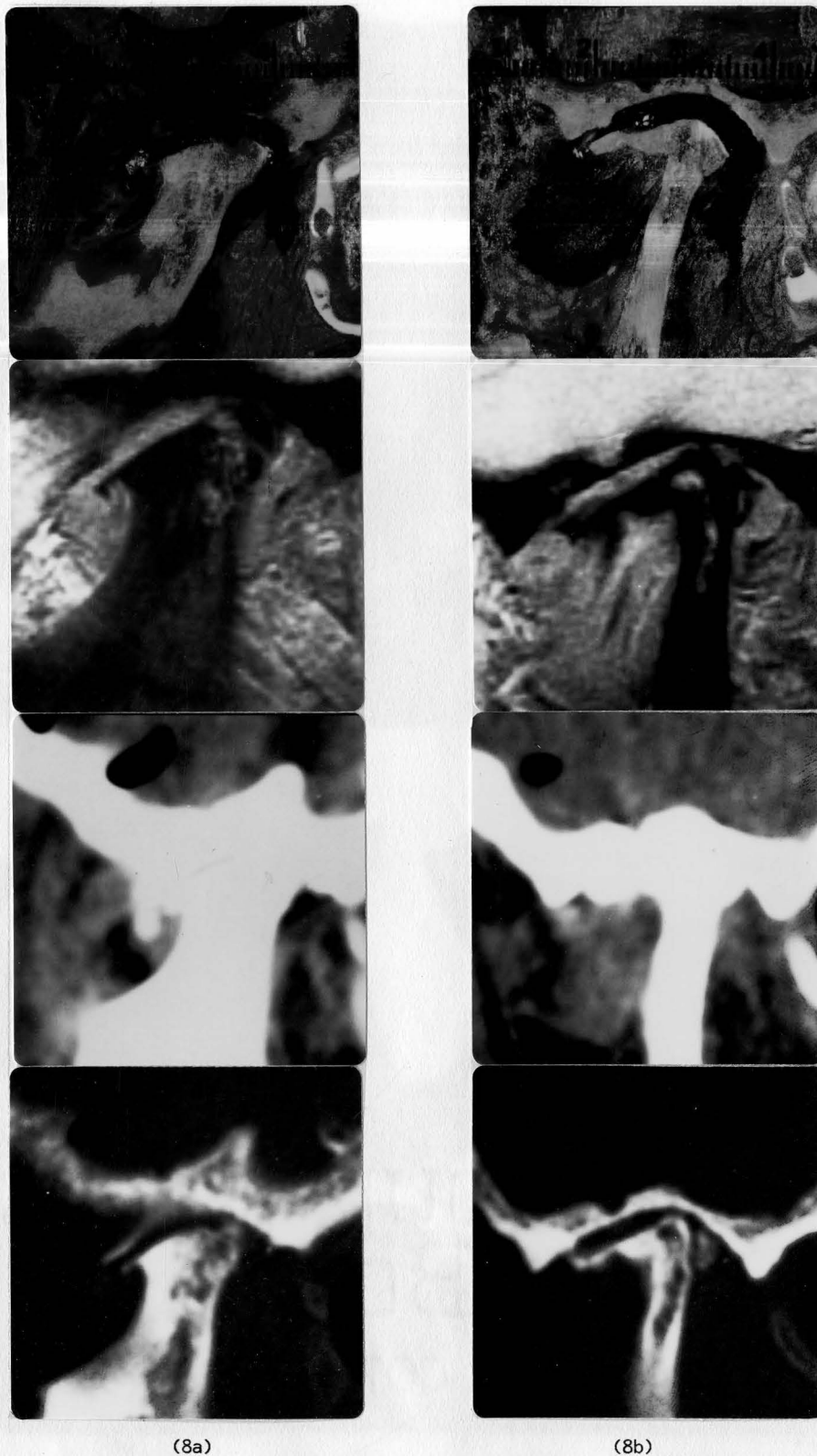


Figure 7. Sagittal correlation of right TMJ of specimen number eleven. Lateral (a), central (b), and medial (c) regions display a deformed disc in an anterior position with a perforation. Severe bony changes with cystic degeneration and osteophyte formation are seen. A false-negative assessment of disc position and configuration was made in the lateral region by CT soft-tissue due to an inability to identify the disc tissue (Row 3).



(8a)

(8b)

Figure 8. Sagittal correlation of left TMJ of specimen number eleven. Lateral (a) and central (b) regions display a deformed disc in an anterior position with a perforation and calcific degeneration. Severe bony changes with erosions and osteophyte formations are seen. Unlike the CT bone and soft-tissue images, MR was unable to clearly identify the calcification.

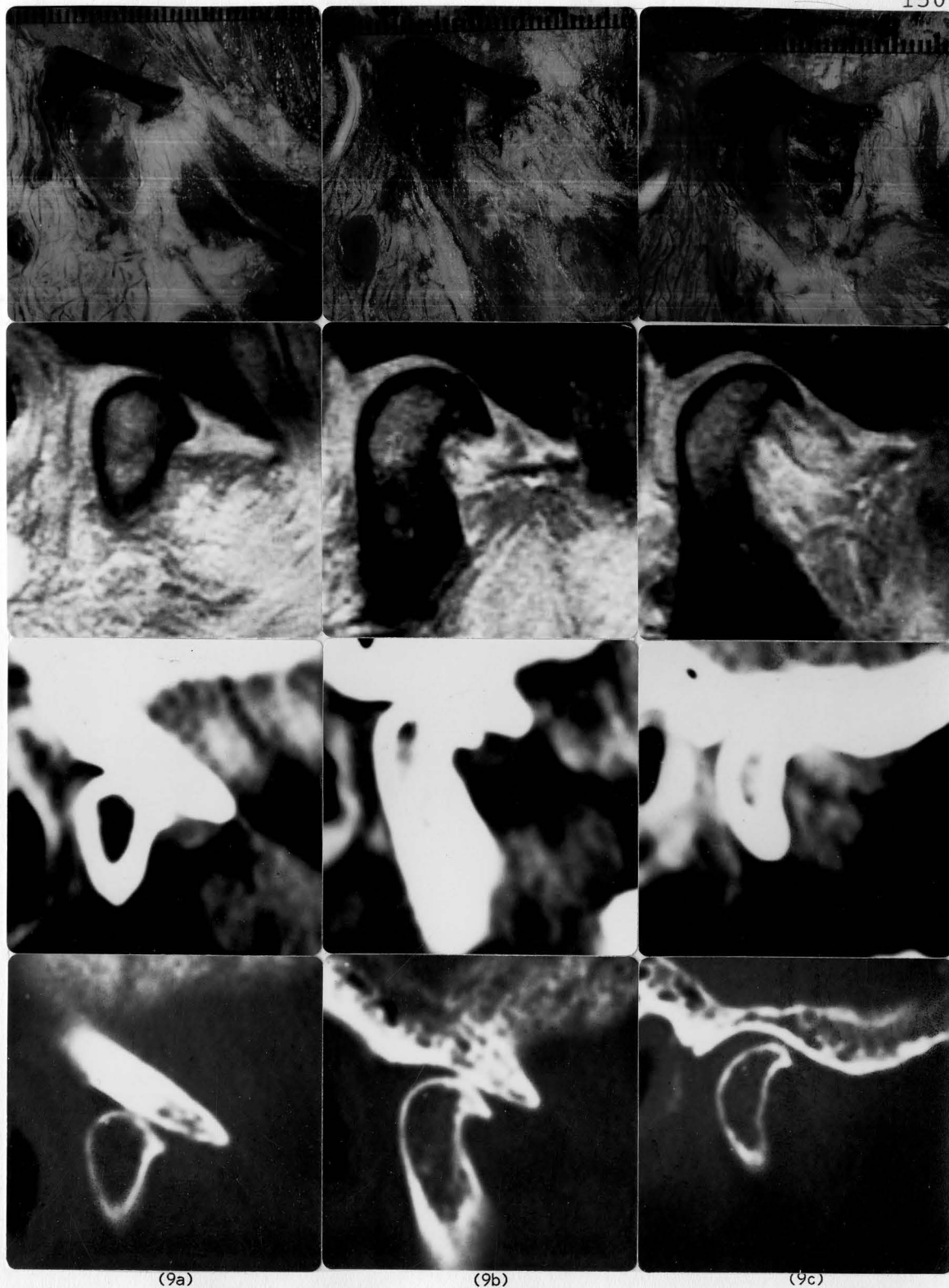


Figure 9. Sagittal correlation of right TMJ of specimen number ten. Lateral (a), central (b), and medial (c) regions display a deformed disc in an anterior position with a perforation. Severe bony changes with osteophyte formation are also seen. A false-negative CT assessment of disc position was made in the medial region (c) when the anterior disc tissue was not clearly identified.

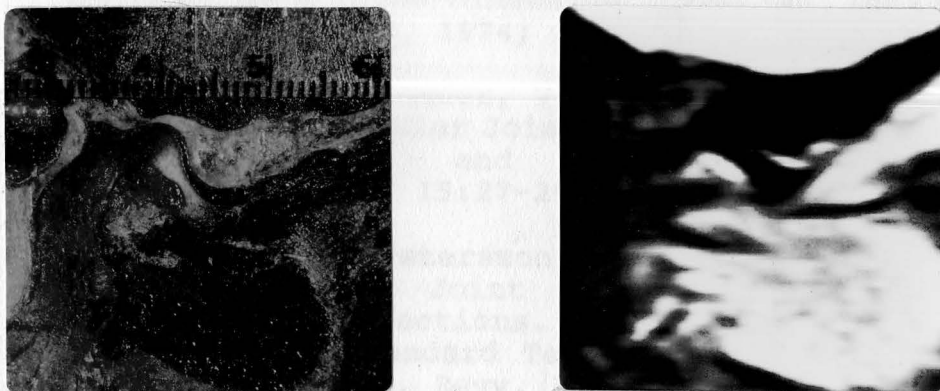


Figure 10. Sagittal correlation of right TMJ of specimen number six. MR and anatomical cryosection of the medial region display a medially displaced biconcave disc, medial to the condylar head. The superior and inferior heads of the lateral pterygoid muscle are also seen.

5. Nale, E. M.: Radiographic Evaluation of the Temporomandibular Joint. *J. Am. Dent. Assoc.* 1961; 62:102-104.
6. Eckert, D. and Sandberg, R.: Temporomandibular Joint Relations as Revealed by Conventional Radiographic Techniques: Comparison With the Radiology and Intraoral Film Methods. *Acta Odontol. Scand.* 1973; 31:111-24.
7. Agrenberg, G. and Dedinsson, G. E.: Functional Disorders of the Masticatory System. Distribution of Symptoms According to Age and Sex as Judged from Investigation by Questionnaire. *Acta Odontol. Scand.* 1972; 30:167.
8. Farber, H. S.: Diagnosis and Treatment of Anterior Displacement of the Articular Disc. *JMI Dent.* 1971; 31:22.
9. Klass, I. E., Kierkegaard, L. and Nilsson, J. G.: Comparison of the Fidelity of Radiographs of the Mandibular Condyle Made by Different Techniques. *J. Prosthet. Dent.* 1974; 24:618.

REFERENCES

1. Ricketts, R. W.: Laminography in the Diagnosis of the Temporomandibular Joint Disorder. *J. Am. Dent. Assoc.* 1953; 46:620-648.
2. Eckerdal, O.: Tomography of the Temporomandibular Joint: Correlation Between Tomographic Image and Histologic Sections in a Three-Dimensional System. *Acta Radiol. [Suppl.] (Stockh)*, 1974; 329:103.
3. Lundberg, M. and Welander, V.: The Articular Cavity in the Temporomandibular Joint. A Comparison Between the Oblique Lateral and the Tomographic Image. *Medicamundi* 1970; 15:27-29.
4. Omnell, K.-A. and Petersson, A.: Radiography of the Temporomandibular Joint Utilizing Oblique Lateral Transcranial Projections. Comparison of Information Obtained with Standard Technique and Individualized Technique. *Odont. Revy.* 1976; 27:77-92.
5. Yale, S. H.: Radiographic Evaluation of the Temporomandibular Joint. *J. Am. Dent. Assoc.* 1969; 79(1):102-107.
6. Eckerdal, O. and Lundberg, M.: Temporomandibular Joint Relations as Revealed by Conventional Radiographic Techniques: A Comparison With the Morphology and Tomographic Images. *Dentomaxillofac. Radiol.* 1979; 8:65-70.
7. Rosenberg, H. M. and Silka, R. E.: TMJ Radiography With Emphasis on Tomography. *Dent. Radiogr. Photogr.* 1982; 55(1):1-24.
8. Agerberg, G. and Carlsson, G. E.: Functional Disorders of the Masticatory System. Distribution of Symptoms According to Age and Sex as Judged From Investigation by Questionnaire. *Acta Odontol. Scand.* Dec. 1972; 30:597.
9. Farrar, W. B.: Diagnosis and Treatment of Anterior Dislocation of the Articular Disc. *NYJ Dent.* 1971; 41:348.
10. Klein, I. E., Blatterfein, L. and Miglino, J. C.: Comparison of the Fidelity of Radiographs of the Mandibular Condyle Made by Different Techniques. *J. Prosthet. Dent.* 1970; 24:419.

11. Petersson, A.: Radiography of the Temporomandibular Joint. A Comparison of Information Obtained From Various Techniques. Thesis. Malmo, Sweden 1976.
12. Bean, L. R., Omnell, K.-A., and Oberg, T.: Comparison Between Radiologic Observations and Macroscopic Tissue Changes in Temporomandibular Joints. *Dentomaxillofac. Radiol.* 1977; 6:90-106.
13. Westesson, P.-L., Bronstein, S. L., and Liedberg, J.: Internal Derangement of the Temporomandibular Joint: Morphologic Description With Correlation to Joint Function. *Oral Surg. Oral Med. Oral Pathol.* 1985; 59:323-331.
14. Rasmussen, O. C.: Disc Perforation During Erosion and Repair in Temporomandibular Joint Osteoarthritis. *J. Dent. Res.* 1984; 63:228.
15. Moffett, B. C., Johnson, L. C., McCabe, I. B., and Askew, H.: Articular Remodelling in the Adult Human Temporomandibular Joint. *Amer. J. Anat.* 1964; 115:119-142.
16. Scapino, R. P.: Histopathology Associated With Malposition of the Human Temporomandibular Joint Disc. *Oral Surg.* 1983; 55(4):382-397.
17. Lindvall, A.-M., Helkimo, E., Hollender, L., and Carlsson, G. E.: Radiographic Examination of the Temporomandibular Joint. A Comparison Between Radiographic Findings and Gross and Microscopic Morphologic Observations. *Dentomaxillofac. Radiol.* 1976; 5:24-32.
18. Westesson, P.-L., and Rohlin, M.: Internal Derangement Related to Osteoarthritis in Temporomandibular Joint Autopsy Specimens. *Oral Surg.* 1984; 57(1):17-22.
19. Moffett, B. C.: Diagnosis of Internal Derangements of the Temporomandibular Joint. Volume I: Double-Contrast Arthrography and Clinical Correlation. Proceedings of a Continuing Dental Education Symposium, University of Washington, Seattle, Washington. Feb. 17, 18, 1984.
20. Balschke, D. D., Solberg, W. K., and Sanders, B.: Arthrography of the Temporomandibular Joint: Review of Current Status. *J. Am Dent. Assoc.* 1980; 100:388-395.

21. Farrar, W. B. and McCarty, W. J., Jr.: Inferior Joint Space Arthrography and Characteristics of Condylar Paths in Internal Derangements of the TMJ. J. Prosthet. Dent. 1979; 41(5):548-555.
22. Katzberg, R. W., Dolwick, M. F., Bales, D. J., and Helms, C. A.: Arthrotomography of the Temporomandibular Joint: New Technique and Preliminary Observations. AJR. 1979; 132:949-955.
23. Westesson, P.-L. and Rohlin, M.: Diagnostic Accuracy of Double-Contrast Arthrotomography of the Temporomandibular Joint: Correlation With Postmortem Morphology. AJNR 1984; 5:463-468.
24. Westesson, P.-L., Bronstein, S. L., and Liedberg, J.: Temporomandibular Joint: Correlation Between Single-Contrast Video-arthrography and Postmortem Morphology. Radiol. 1986; 160:767-771.
25. Norgaard, F.: Temporomandibular Arthrography. Thesis. Copenhagen, Munksgaard, 1947.
26. Agerberg, B. and Lundberg, M.: Changes in the Temporomandibular Joint After Surgical Treatment: A Radiologic Follow-up Study. Oral Surg. 1971; 32:865.
27. Bronstein, S. L., Tomasetti, B. J., and Ryan, D. E.: Internal Derangement of the Temporomandibular Joint: Correlation of Arthrographic With Surgical Findings. J. Oral Surg. 1981; 39(8):572-584.
28. Delfino, J. J. and Eppley, B. L.: Radiographic and Surgical Evaluation of Internal Derangements of the Temporomandibular Joint. J. Oral Maxillofac. Surg. 1986; 44:260-267.
29. Katzberg, R. W., Dolwick, M. F. and Helms, C. A.: Arthrotomography of the Temporomandibular Joint. AJR 1980; 134(5):995-1003.
30. Dolwick, M. F., Katzberg, R. W., Helms, C. A., and Bales, D. J.: Arthrotomographic Evaluation of the Temporomandibular Joint. J. Oral Surg. 1979; 37:793-799.
31. Helms, C. A., Vogler, J. B., Morrish, R. B., Goldman, S. M., Capra, R. E., and Proctor, E.: Temporomandibular Joint internal Derangements: CT Diagnosis. Radiol. 1984; 152(2)459-462.

32. Manzione, J. V., Katzberg, R. W., Brodsky, G. L., Seltzer, S. E., and Mellins, H. Z.: Internal Derangements of the Temporomandibular Joint: Diagnosis by Direct Sagittal Computed Tomography. *Radiol.* 1984; 150(1):111-115.
33. Thompson, J. R., Christiansen, E. L., Hasso, A. N., and Hinshaw, D. B. Jr.: Temporomandibular Joints: High-Resolution Computed Tomographic Evaluation. *Radiol.* 1984; 150:105-110.
34. Manco, L. G., Messing, S. G., Busino, L. J., Fasulo, C. P., and Sordill, W. C.: Internal Derangement of the Temporomandibular Joint Evaluated with Direct Sagittal CT: A Prospective Study. *Radiol.* 1985; 157:407-412.
35. Sartoris, D. J., Neumann, C. H., and Riley, R. W.: The Temporomandibular Joint: True Sagittal Computed Tomography With Meniscus Visualization. *Radiol.* 1984; 150:250-254.
36. Wolff, S., Crooks, L. E., Brown, P., Howard, R., and Painter, R. B.: Tests for DNA and Chromosomal Damage Induced by NMR Imaging. *Radiol.* 1980; 136:707-710.
37. Thomas, A. and Morris, P. G.: The Effects of NMR Exposure on Living Organisms. I. A Microbial Assay. *Br. J. Radiol.* 1981; 54(7):615-621.
38. Wolff, S., James, T. L., Young, G. B., Margulis, A. R., Bodycote, J., and Afzal, V.: Magnetic Resonance Imaging: Absence of In Vitro Cytogenetic Damage. *Radiol.* 1985; 155:163-165.
39. Sacks, E., Worgul, B. V., Merriam, G. R., and Hilal, S.: The Effects of Nuclear Magnetic Resonance Imaging on Ocular Tissues. *Arch. Ophthalmol.* 1986; 104:890-893.
40. Geard, C. R., Osmak, R. S., Hall, E. J., Simon, H., Maudsley, A. A., and Hilal, S. K.: Magnetic Resonance and Ionizing Radiation: A Comparative Evaluation In Vitro of Oncogenic and Genotoxic Potential. *Radiol.* 1984; 152:199-202.
41. Roberts, D., Schenck, J., Joseph, P., Foster, T., Hart, H., Pettigrew, J., Kundel, H., Edelstein, W., and Haber, B.: Temporomandibular Joint: Magnetic Resonance Imaging. *Radiol.* 1985; 155:829-830.

42. Katzberg, R. W., Schenck, J., Roberts, D., Tallents, R. H., Manzione, J. V., Hart, H. R., Foster, T. H., Wayne, W. S., and Bessette, R. W.: Magnetic Resonance Imaging of the Temporomandibular Joint Meniscus. *Oral Surg. Oral Med. Oral Pathol.* 1985; 59:332-335.
43. Harms, S. E., Wilk, R. M., Wolford, L. M., Chiles, D. G., and Milam, S. B.: The Temporomandibular Joint: Magnetic Resonance Imaging Using Surface Coils. *Radiol.* 1985; 157:133-136.
44. Helms, C. A., Richardson, M. L., Moon, K. L., and Ware, W. H.: Nuclear Magnetic Resonance Imaging of the Temporomandibular Joint: Preliminary Observations. *J. Craniomand. Pract.* 1984; 2(3):220-224.
45. Cirbus, M. T., Smilack, M. S., Beltran, J., and Simon D. C.: Magnetic Resonance Imaging in Confirming Internal Derangement of the Temporomandibular Joint. *J. Prosthet. Dent.* 1987; 57(4):488-494.
46. Helkimo, J.: Studies on Function and Dysfunction of the Masticatory System. Age and Sex Distribution of Symptoms of Dysfunction of the Masticatory System in Lapps in the North of Finland. *Acta Odontol. Scand.* 1974; 32:255.
47. Hansson, T. and Nilner, M.: A Study of the Occurrence of Symptoms of Disease of the TMJ, Masticatory Musculature and Related Structures. *J. Oral Rehab.* 1975; 2(4):313-324.
48. Grosfeld, O., Jackowska, M., and Czarnecka, B.: Results of Epidemiological Examinations of the Temporomandibular Joint in Adolescents and Young Adults. *J. Oral Rehab.* 1985; 12:95.
49. Nilner, M.: Epidemiology of Functional Disturbances and Diseases in the Stomatognathic System - A Cross-Sectional Study of 7-18 Year Olds From an Urban District. *Swed. Dent. J. Suppl.* 17, 1983.
50. Nilner, M. and Lassing, S. A.: Prevalence of Functional Disturbances and Diseases of the Stomatognathic System in 7-14 Year Olds. *Swed. Dent. J.* 1981; 5:173.
51. Dibbets, J. M., Van der Weele, L. T., and Uildreks, A. K.: Symptoms of TMJ Dysfunction: Indicators of Growth Patterns? *J. Pedod.* 1985; 9:265.

52. Magnusson, T., Egermark-Eriksson, I. and Carlsson, G. E.: Four Year Longitudinal Study of Mandibular Dysfunction in Children. *Community Dent. Oral Epidemiol.* 1985; 13:117-120.
53. Magnusson, T., Egermark-Eriksson, I., and Carlsson, G. E.: Five Year Longitudinal Study of Signs and Symptoms of Mandibular Dysfunction in Adolescents. *J. Craniomand. Pract.* 1986; 4(4):339-343.
54. Grosfeld, O., and Czarnecka, B.: Musculo-Articular Disorders of the Stomatognathic System in School Children Examined According to Clinical Criteria. *J. Oral Rehab.* 1977; 4:193.
55. Yalelow, I. and Arnold G. S.: Temporomandibular Joint Clicking. *Oral Surg.* 1971; 32:708-715.
56. Carlsson, G. E. and Oberg, T.: Remodelling of the Temporomandibular Joint. In: Zarb, G. A. and Carlsson, G. E. (eds): *Temporomandibular Joint Function and Dysfunction.* Copenhagen, Munksgaard, 1979; p. 159,170.
57. Campbell, J.: The Clicking Jaw. *Curr. Med. Drugs* 1963; 3:20-35.
58. Ireland, V. E.: The Problem of "The Clicking Jaw." *Proc. Roy. Soc. Med.* 1951; 44:363-372.
59. Wilkes, C. H.: Arthrography of the TMJ in Patients With the TMJ Pain-Dysfunction Syndrome. *Minn. Med.* 1978; 61:645-652.
60. Katzberg, R. W., Dolwick, M. F., Helms, C. A., Hopens, T., Bales, D. J., and Coggs, G. C.: Arthrotomography of the Temporomandibular Joint. *AJR* 1980; 134:995-1003.
61. Isberg-Holm, A. M. and Westesson, P.-L.: Movement of Disc and Condyle in Temporomandibular Joints with Clicking. An Arthrographic and Cineradiographic Study on Autopsy Specimens. *Acta Odontol. Scand.* 1982; 40(3):151-164.
62. Isberg-Holm, A. M. and Westesson, P.-L.: Movement of Disc and Condyle in Temporomandibular Joints With and Without Clicking. A High Speed Cinematographic and Dissection Study on Autopsy Specimens. *Acta Odontol. Scand.* 1982; 40(3):165-177.

63. Rohlin, M., Westesson, P.-L. and Eriksson, L.: The Correlation of Temporomandibular Joint Sounds With Joint Morphology in Fifty-Five Autopsy Specimens. *J. Oral Maxillofac. Surg.* 1985; 43:194-200.
64. Nanthaviroj, S., Omnell, K.-A., Randow, K., and Oberg, T.: Clicking and Temporary "Locking" in the Temporomandibular Joint. A Clinical, Radiographic, and Electromyographical Study. *Dentomaxillofac. Radiol.* 1976; 5:33.
65. Carlsson, G. E. and Oberg, T.: Remodelling of the Temporomandibular Joint. In: Zarb, G. A., and Carlsson, G. E. (eds): *Temporomandibular Joint Function and Dysfunction.* Copenhagen, Munksgaard, 1979; p. 170.
66. Hansson, T. and Oberg, T.: Arthrosis and Deviation in Form in the TMJ. A Macroscopic Study on Human Autopsy Material. *Acta Odontol. Scand.* 1977; 35:167.
67. Miller, T. L., Katzberg, R. W., Tallents, R. H., Bessette, R. W., and Hayakawa, K.: Temporomandibular Joint Clicking With Non-reducing Anterior Displacement of the Meniscus. *Radiol.* 1985; 154:121-124.
68. Katzberg, R. W. and Anderson, Q. N.: Tomography. In: Helms, C. A., Katzberg, R. W., and Dolwick, M. F., (eds): *Internal Derangements of the Temporomandibular Joint.* Radiol. Res. and Educ. Found., San Francisco, California. 1983; pp.63-84.
69. Stanson, A. W. and Baker, H. L.: Routine Tomography of the Temporomandibular Joint. *Radiol. Clin. North Am.* 1976; 14:105.
70. Pringle, J. H.: Displacement of the Mandibular Meniscus and its Treatment. *Br. J. Surg.* 1918-1919; 6:385.
71. Toller, P. A.: Temporomandibular Arthropathy. *Proced. of the Royal Soc. of Med.* 1974; 67(2):153-159.
72. Watt, D. M.: Temporomandibular Joint Sounds. *J. Dent.* 1980; 8:119.
73. deBont, L. G., Boering, G., Liem, R. S., Eulderink, F., and Westesson, P.-L.: Osteoarthritis and Internal Derangement of the Temporomandibular Joint: A Light Microscopic Study. *J. Oral Maxillofac. Surg.* 1986; 44:634-643.

74. Steinhardt, G.: Untersuchungen Über die Beanspruchung der Kiefergelenke und Ihre Geweblichen Folgen. Dtsch. Zahnheilkd. 1934; 91:1-78.
75. Steinhardt, G.: Die Anatomisch- Physiologischen Verhältnisse des Zahnlosen Kiefers, Insbesondere der Gelenkle in Ihre Beziehungen Zur Technik der Bissnahme und Kunstlichen Articulation. Dtsch. Zahn-, Mund-, Kieferheilkd. 1936; 3:209-235.
76. Blackwood, H. J.: Adaptive Changes in Mandibular Joints With Function. In: Symposium on Temporomandibular Joint Dysfunction. Dent. Clin. North Am. 1966; p.p.559-566.
77. Isberg, A. M. and Isacsson, G.: Tissue Reactions of the Temporomandibular Joint Following Retrusive Guidance of the Mandible. J. Craniomand. Pract. 1986; 4(2):144-148.
78. Wilkes, C. H.: Structural and Functional Alterations of the Temporomandibular Joint. NW Dent. 1978; 57:287-294.
79. Eriksson, L. and Westesson, P.-L.: Clinical and Radiological Study of Patients With Anterior Disc Displacement of the Temporomandibular Joint. Swed. Dent. J. 1983; 7:55-64.
80. Westesson, P.-L.: Double-Contrast Arthrotomography of the Temporomandibular Joint: Introduction of an Artrographic Technique for Visualization of the Disc and Articular Surfaces. J. Oral Maxillofac. Surg. 1983; 41:163-172.
81. Oberg, T., Carlsson, G. E., and Fajers, C.-M.: The Temporomandibular Joint. A Morphologic Study on Human Autopsy Material. Acta Odontol. Scand. 1971; 29:349.
82. Higley, L. B.: A New Specific Method of Producing Temporomandibular Articulation Radiograms. Int. J. Orthod. Oral Surg. 1936; 22:983-991.
83. Dixon, D. C. and Graham, C. S. et al.: The Validity of Transcranial Radiography in Diagnosing Temporomandibular Joint Anterior Disc Displacement. J. Am. Dent. Assoc. 1984; 108:615-618.
84. Petersson, A.: Radiography of the Temporomandibular Joint. A Comparison of Information Obtained from Different Radiographic Techniques. Thesis. Malmo, Sweden, 1976.

85. Eckerdal, O. and Lundberg, M.: The Structural Situation in the TMJ: A Comparison Between Conventional Oblique Transcranial Radiography, Tomography and Histologic Sections. *Dentomaxillofac. Radiol.* 1979; 8:42-49.
86. Larheim, T. A.: Comparison Between Three Radiographic Techniques for Examination of the TMJ in Juvenile Rheumatoid Arthritis. *Acta Radiol. Diag.* 1981; 22:195-201.
87. Petrelli, A. and Gurley, J. F.: Tomography of the Temporomandibular Joint. *J. Am. Dent. Assoc.* 1939; 26:218-224.
88. Yale, S. H., Rosenberg, H. M., Ceballos, M. Hauptfueher, J. D.: Laminographic Cephalometry in the Analysis of Mandibular Condyle Morphology. *Oral Surg.* 1961; 14:793-805.
89. Eckerdal, O.: Tomography of the Temporomandibular Joint. Correlation Between Tomographic Image and Histologic Sections in a Three-Dimensional System. *Acta Radiol. Suppl.* 329, 1973.
90. Oberg, T., Carlson, G. E., and Fajers, C.-M.: The Temporomandibular Joint: A Morphologic Study on Human Autopsy Material. *Acta Odontol. Scand.* 1971; 29:349-384.
91. Larheim, T. A., Tveito, L., Dole, K., and Ruud, A. F.: Temporomandibular Joint Abnormalities in Rheumatoid Arthritis. Comparison of Different Radiographic Methods. *Acta Radiol. (Diagn.) (Stockh)* 1981; 22(6):703-707.
92. Zimmer, E. A.: Die Rontgenologie des Kieferglenkes. *Schweiz. Monatschr. f Zahnherlk.* 1941; 51:949.
93. Farrar, W. B.: Characteristics of the Condylar Path in Internal Derangements of the TMJ. *J. Prosthet. Dent.* 1978; 39:319-323.
94. Bell, K. A. and Wolters, P. J.: Videofluoroscopy During Arthrography of the Temporomandibular Joint. *Radiol.* 1983; 147:879.
95. Farrar, W. B.: Differentiation of TMJ Dysfunction to Simplify Treatment. *J. Prosthet. Dent.* 1972; 28(6):629-636.

96. Westesson, P.-L., Omnell, K.-A., and Rohlin, M.: Double-Contrast Tomography of the Temporomandibular Joint. A New Technique Based on Autopsy Specimen Examinations. *Acta Radiol. [Diagn.] (Stockh)*, 1980; 21(6):777-784.
97. Toller, P. A.: Opaque Arthrography of the Temporomandibular Joint. *Int. J. Oral Surg.* 1974; 3:17-24.
98. Campbell, W.: Clinical Radiological Investigations of Mandibular Joints. *Br. J. Radiol.*, 1965; 38:401-421.
99. Murphy, W. A.: Arthrography of the Temporomandibular Joint. *Radiol. Clin. North Am.* 1971; 19(2):365-378.
100. Rasmussen, O. C.: Semiopaque Arthrography of the Temporomandibular Joint. *Scand. J. Dent. Res.* 1980; 88:521-534.
101. Frenkel, B.: Untersuchungen mit der Kombination Arthrographie and Tomographie zur Darstellung des Discus Articularis des Menschen. *Dtsch. Zahnärztl. Z.* 1965; 20:1261-1274.
102. Guralnick, W., Kaban, L. B., and Merrill, R. G.: Temporomandibular Joint Afflictions. *N. Engl. J. Med.* 1978; 229:123-129.
103. Lasken, D. M.: Etiology of the Pain Dysfunction Syndrome. *J. Am. Dent. Assoc.* 1969; 79:147-153.
104. Lynch, T. P. and Chase, D. C.: Arthrography in the Evaluation of the Temporomandibular Joint. *Radiol.* 1978; 126:667-672.
105. Westesson, P.-L. and Bronstein, S. L.: Temporomandibular Joint: Comparison of Single and Double-Contrast Arthrography. *Radiol.* 1987; 164:67-70.
106. Kaplan, P. A., Tu, H. K., Williams, S. M., and Lydiatt, D. D.: The Normal Temporomandibular Joint: MR and Arthrographic Correlation. *Radiol.* 1987; 165:177-178.
107. Thompson, J. R.: Letters to the Editor Re: Computed Tomography vs. Arthrography in the Evaluation of the Temporomandibular Joint. *Radiol.* 1984; 152(3):825-826.
108. Arnaudow, M., Haage, H., and Pflaum, I.: Die Doppelkontrast-arthrographie des Kiefergelenkes. *Dtsch. Zahnärztl. Z.* 1968; 23:390-393.

109. Arnaudow, M. and Pflaum, I.: Neue Erkenntnisse in der Beurteilung bei der Kiefergelenktomographie. Dtsch. Zahnarztl. Z. 1974; 29:554-556.
110. Westesson, P.-L.: Double-Contrast Arthrotomography of the Temporomandibular Joint: Introduction of an Arthrographic Technique for Visualization of the Disc and Articular Surfaces. J. Oral Maxillofac. Surg. 1983; 41:163-172.
111. Cohen, H., Ross, S., and Gordon, R.: Computerized Tomography as a Guide in the Diagnosis of Temporomandibular Joint Disease. J. Am. Dent. Assoc. 1985; 110:57-60.
112. Suarez, F. R., Bhussry, B. R., and Neff, P. A., et al.: A Preliminary Study of Computerized Tomographs of the Temporomandibular Joint. J. Craniomand. Prac. 1980; 1(3):217-222.
113. Helms, C. A., Morrish, R. B. Jr., Kircos, L. T., Katzberg, R. W., and Dolwick, M. F. et al.: Computerized Tomography of the Meniscus of the Temporomandibular Joint: Preliminary Observations. Radiol. 1982; 145(3):719-722.
114. Katzberg, R. W., Dolwick, M. F., Keith, D. A., Helms, C. A., and Guralnick, W. C.: New Observations With Routine and CT Assisted Arthrography in Suspected Internal Derangement of the TMJ. Oral Surg. 1981; 51(6):569-574.
115. Manzione, J. V., Seltzer, S. E., Katzberg, R. W., Hammerschlag, S. B., and Chiango, B. F.: Direct Sagittal Computed Tomography of the Temporomandibular Joint. AJR 1983; 140:165-167.
116. Smith, F. W., Hutchison, I. M. S., Mallard, J. R., Johnson, G., Redpath, T. W., Selbie, R. D., Reed, A., and Smith, C. C.: Oesophageal Carcinoma Demonstrated by Whole-Body Nuclear Magnetic Resonance Imaging. Br. Med. J. 1981; 282:510-512.
117. Maue-Dickson, W., Trefler, M., and Dickson, D. R.: Comparison of Dosimetry and Image Quality in Computed and Conventional Tomography. Radiol. 1979; 131:509-514.
118. Trefler, M. and Houghton, V. M.: Patient Dose and Image Quality in Computed Tomography. AJR 1981; 137:25-27.

119. Thompson, J. R., Christiansen, E., Sauser, D., Hasso, A. N., and Hinshaw, D. B. Jr.: Dislocation of the Temporomandibular Joint Meniscus: Contrast Arthrography vs. Computed Tomography. *AJNR* 1984; 5:747-750.
120. Hoffman, D. C., Berliner, L., Manzione, J., Saccaro, R., and McGivern, B. E. Jr.: Use of Direct Sagittal Computed Tomography in Diagnosis and Treatment of Internal Derangement of the Temporomandibular Joint. *J. Am. Dent. Assoc.* 113:407-411.
121. Katzberg, R. W., Keith, D. A., Guralnick, W. C., Manzione, J. V. Jr., and Ten Eick, W. R.: Internal Derangement and Arthritis of the Temporomandibular Joint. *Radiol.* 1983; 146:107-112.
122. Purcell, E. M., Torrey, H. L., and Pound, R. V.: Resonance Absorption by Nuclear Magnetic Moments in a Solid. *Phys. Rev.* 1946; 69:37.
123. Block, F., Hansen, W. W., and Packard, M. E.: Nuclear Induction. *Phys. Rev.* 1946; 69:127.
124. Cooke, P. and Morris, P. G.: The effects of NMR Exposure on Living Organisms. II. A Genetic Study of Human Lymphocytes. *Br. J. Radiol.* 1981; 54(7):622-625.
125. Engler, M. B. and Engler, M. M.: The Hazards of Magnetic Resonance Imaging (Clinical News). *Am. J. Nurs.* June 1986; 650.
126. Pavlicek, W., et al.: The effects of Nuclear Magnetic Resonance on Patients With Cardiac Pacemakers. *Radiol.* 1983; 147(4):194-153.
127. Wilk, R. M., Harms, S. E., and Wolford, L. M.: Magnetic Resonance Imaging of the Temporomandibular Joint Using a Surface Coil. *J. Oral Maxillofac. Surg.* 1986;44:935-943.
128. Schellhas, K. P., Wilkes, C. H., Heithoff, K. B., Omlie, M. R., and Block, J. C.: Temporomandibular Joint: Diagnosis of Internal Derangement Using Magnetic Resonance Imaging. *Minn. Med.* 1986; 69:516-519.
129. Laurell, K. A., Tootle, R., Cunningham, R., Beltran, J., and Simon, D.: Magnetic Resonance Imaging of the Temporomandibular Joint. Part III: Use of a Cephalostat for Clinical Imaging. *J. Prosthet. Dent.* 1987; 58(3):355-359.

130. Kircos, L. T., Ortendahl, D. A., Mark, A. S., and Arakawa, M.: Magnetic Resonance Imaging of the TMJ Disc in Asymptomatic Volunteers. *J. Oral Maxillofac. Surg.* 1987; 45:852-854.
131. Helms, C. A., Gillespy, T., Sims, R. E., and Richardson, M. L.: Magnetic Resonance Imaging of Internal Derangement of the Temporomandibular Joint. *Radiol. Clin. North Am.* 1986; 24(2):189-192.
132. Katzberg, R. W. and Burgener, F. A.: Kernspintomographie des Kiefergelenks. Vergleich mit Computertomographie und Arthrographie. *ROFO* 1986; 145(1):38-43. GER (Eng. Abstr.)
133. Kaplan, P. A., Tu, H. K., Sleder, R. P., Lydiatt, D. D., and Laney, T. J.: Inferior Joint Space Arthrography of Normal Temporomandibular Joints: Reassessment of Diagnostic Criteria. *Radiol.* 1986; 159:585-589.
134. Laurell, K. A., Tootle, R., Cunningham, R., Beltran, J., and Simon, D.: Magnetic Resonance Imaging of the Temporomandibular Joint. Part II: Comparison With Laminographic, Autopsy, and Histologic Findings. *J. Prosthet. Dent.* 1987; 58(2):211-218.
135. Donlon, W. C. and Moon, K. L.: Comparison of Magnetic Resonance Imaging, Arthrotomography and Clinical and Surgical Findings in Temporomandibular Joint Internal Derangements. *Oral Surg. Oral Med. Oral Pathol.* 1987; 64:2-5.
136. Schellhas, K. P., Wilkes, C. H., and Omlie, M. R., et al.: The Diagnosis of Temporomandibular Joint Disease: Two-Compartment Arthrography and MR. *AJNR* 1988; 9:579-588, *AJR* 1988; 151:731-735.
137. Burnett, K. R., Davis, C. L., and Read, J.: Dynamic Display of the Temporomandibular Joint Meniscus by Using "Fast-Scan" MR Imaging. *AJR* 1987; 149:959-962.
138. Dumas, A. L. and Moaddab, M. B. et al.: A Combined Tomographic-Cephalometric Analysis of the TMJ. *J. Craniomand. Pract.* 1983; 1(3):23-26.
139. Schellhas, K. P., Wilkes, C. H., and Fritts, H. M., Omlie, M. R., and Lagrotteria, L. B.: MR of Osteochondritis Dissecans and Avascular Necrosis of the Mandibular Condyle. *AJNR* 1989; 10:3-12.

140. Schellhas, K. P., Wilkes, C. H., Fritts, H. M., Omlie, M. R., Heithoff, K. B., and Jahn, J. A.: Temporomandibular Joint: MR Imaging of Internal Derangement and Postoperative Changes. *AJNR* 1987; 8:1093-1101, *AJR* 1988; 150(2):381-389.
141. Westesson, P.-L., Katzberg, R. W., Tallents, R. H., Sanchez-Woodworth, R. E., Svensson, S. A., and Espeland, M. A.: Temporomandibular Joint: Comparison of MR Images With Cryosectional Anatomy. *Radiol.* 1987; 164:59-64.
142. Katzberg, R. W., Westesson, P.-L., Tallents, R. H., Anderson, R., Kurita, K., Manzione, J. V., and Totterman, S.: Temporomandibular Joint: MR Assessment of Rotational and Sideways Disk Displacements. *Radiol.* 1988; 169:741-748.
143. Westesson, P.-L., Katzberg, R. W., Tallents, R. H., Sanchez-Woodworth, R. E., and Svensson, S. A.: CT and MR of the Temporomandibular Joint: Comparison With Autopsy Specimens. *AJR* 1987; 148:1165-1171.
144. Christiansen, E. L., Thompson, J. R., Hasso, A. N., and Hindshaw, D. B.: Correlative Thin Section Temporomandibular Joint Anatomy and Computed Tomography. *Radiographics* 1986; 6:703-723.
145. Ricketts, R. M.: Variations of the Temporomandibular Joint as Revealed by Cephalometric Laminography. *Am. J. Orthod.* 1950; 36:874-898.
146. Blaschke, D. D. and Blaschke, T. J.: A Method for Quantitatively Determining Temporomandibular Joint Bony Relationships. *J. Dent. Res.* 1981; 60:35-43.
147. Williamson, E. H. and Simmone, M. D.: Mandibular Asymmetry and its Relation to Pain Dysfunction. *Am. J. Orthod.* 1979; 76:612-617.
148. Pullinger, A. and Hollender, L.: Assessment of Mandibular Condyle Position: A Comparison of Transcranial Radiographs and Linear Tomograms. *Oral Surg.* 1985; 60(3):329-334.
149. Rauschnig, W.: Computed Tomography and Cryomicrotomy of Lumbar Spine Specimens - A New Technique for Multiplanar Anatomic Correlation. *Spine* 1983; 8(2):170-178.

150. Khoury, M. B. and Dolan, E.: Sideways Dislocation of the Temporomandibular Joint Meniscus: The Edge Sign. AJNR 1986; 7:869-872.
151. Janzen, E. K. and Bluher, J. A.: The Cephalometric, Anatomic and Histologic Changes in Macaca mulatta After Application of a Continuous-acting Retraction Force on the Mandible. Am. J. Orthod. 1965; 51:823-855.
152. Ramfjord, S. P. and Hiniker, J. J.: Distal Displacement of the Mandible in Adult Rhesus Monkeys. J. Prosthet. Dent. 1966; 16:491-502.
153. Helms, C. A., Katzberg, R. W., Dolwick, M. F., and Bales, F. J.: Arthrotomographic Diagnosis of Meniscus Perforations in the Temporomandibular Joint. Br. J. Radiol. 1980; 53(4):283-285.
154. Hansson, T., Oberg, T., Carlsson, G. E., and Kopp, S.: Thickness of the Soft Tissue Layers and the Articular Disc in the Temporomandibular Joint. Acta Odontol. Scand. 1977; 35:77-83.
155. Blackwood, H. J.: Arthritis of the Mandibular Joint. Brit. Dent. J. 1963; 115:317-326.
156. Gelfand, D. W. and Ott D. J.: Methodologic Considerations in Comparing Imaging Methods. AJR 1985; 144:1117-1121.
157. Hansson, T. and Oberg, T.: En Kliniskt - Bettfysiologisk Undersokning av 67-Aringar I Dalby. Tandlakartidningen Sept. 15, 1971; 63:650.
158. Agerberg, G. and Osterberg, T.: Maximal Mandibular Movements and Symptoms of Mandibular Dysfunction in 70 Year-Old Men and Women. Sven. Tandlak. Tidskr. 1974; 67(5):147-163.
159. Thickman, D. I., Kundel, H. L., and Wolf G.: Nuclear Magnetic Resonance Characteristics of Fresh and Fixed Tissue: The Effect of Elapsed Time. Radiol. 1983; 148:183-185.
160. Rauschnig, W., Bergstrom, K. and Pech, P.: Correlative Craniospinal Anatomy Studies by Computed Tomography and Cryomicrotomy. J. Comput. Assist. Tomogr. 1983; 7:9-13.

161. Hemmingsson, A., Johansson, A. and Rauschnig, W.:
Attenuation in Human Muscle and Fat Tissue in Vivo and
in Vitro. Acta Radiol. [Diagn.] (Stockh), 1982;
23:149-151.

VITA

The Author, Charles Francis Reed, was born October 24, 1957, in Indianapolis, Indiana.

Dr. Reed received his undergraduate education at Loyola University of Chicago from 1975 to 1978, where he majored in Biology. He graduated summa cum laude with a Bachelor of Science degree in January, 1980.

In 1978, Dr. Reed began his dental education at the Loyola University School of Dentistry. He received his Doctor of Dental Surgery degree, magna cum laude, in 1982. Dr. Reed also received Clinical Honors in Orthodontics as well as the American Association of Orthodontists Award the same year.

Dr. Reed pursued his graduate education at the Loyola University School of Dentistry where he received his Certificate of Specialty in Orthodontics in 1984. In 1983, Dr. Reed began his Masters thesis investigating the use of Magnetic Resonance Imaging and Computed Tomography in the imaging of internal derangements of the temporomandibular joint.

Dr. Reed has been in the clinical practice of dentistry and orthodontics for eight years. During this time, he has also served as a TMJ Consultant to the Berwyn Magnetic Resonance Center for two years. In 1987, he received the Joseph E. Johnson Award and First Place Table Clinic Honors

at the American Association of Orthodontists National Meeting. In 1988 he received the Maxima Cum Laude Table Clinics Award from the American Society of Neuroradiology for his work with magnetic resonance imaging of the TMJ. In 1990, Dr. Reed coauthored a book with Drs. Palacios, Valvassori, and Shannon entitled, "Magnetic Resonance Imaging of the Temporomandibular Joint", published by Thieme Medical Publishers, New York, New York.

THESIS APPROVAL SHEET

The thesis submitted by Charles F. Reed, D.D.S. has been read and approved by the following committee:

Lewis Klapper, D.M.D., M.Sc.D., D.Sc., Director
Past Chairman Dept. of Orthodontics
Loyola University School of Dentistry

Raymond Warpeha, D.D.S., M.D., PhD.
Chairman Dept. of Plastic Surgery
Loyola University Medical Center

Joseph Gowgiel, D.D.S., PhD.
Chairman Dept. of Anatomy
Loyola University School of Dentistry

The final copies have been examined by the director of the thesis committee and the signature which appears below verifies the fact that any necessary changes have been incorporated and that the thesis is now given final approval by the committee with reference to content and form.

The thesis is, therefore, accepted in partial fulfillment of the requirements for the degree of Master of Science.

6/22/91
Date


Director's Signature