

8-2018

Trans-lymphatic Contrast-Enhanced Ultrasound in Combination with Blue Dye Injection is Feasible for Detection and Biopsy of Sentinel Lymph Nodes in Breast Cancer

Xiangmei Chen, MD

Jieyu Zhong, MD

Zhengming Hu, MD

Wei Wei, MD

Weihua Yin, MD

See next page for additional authors

Let us know how access to this document benefits you

Follow this and additional works at: <https://jdc.jefferson.edu/radiologyfp> Part of the [Oncology Commons](#), and the [Radiology Commons](#)

Authors

Xiangmei Chen, MD; Jieyu Zhong, MD; Zhengming Hu, MD; Wei Wei, MD; Weihua Yin, MD; Ligang Cui, MD; Ji-Bin Liu, MD; and Desheng Sun, MD

Trans-lymphatic Contrast-Enhanced Ultrasound in Combination with Blue Dye Injection is Feasible for Detection and Biopsy of Sentinel Lymph Nodes in Breast Cancer

Xiangmei Chen, MD^{a,1}, Jieyu Zhong, MD^{a,1}, Zhengming Hu, MD^a, Wei Wei, MD^b, Weihua Yin, MD^c, Ligang Cui, MD^d, Ji-Bin Liu, MD^e, Desheng Sun, MD^{a,*}

^aDepartment of Ultrasonography, Peking University Shenzhen Hospital, Shenzhen, China; ^bDepartment of Breast and Thyroid Surgery, Peking University Shenzhen Hospital, Shenzhen, China; ^cDepartment of Pathology, Peking University Shenzhen Hospital, Shenzhen, China; ^dDepartment of Ultrasonography, Peking University Third Hospital, Beijing, China; ^eDepartment of Radiology, Thomas Jefferson University, Philadelphia, PA, USA.

Received December 15, 2017; revision requested February 15, 2018; revision received February 14; accepted March 4.

¹Xiangmei Chen and Jieyu Zhong contributed equally to this study.

Objective: The best method for sentinel lymph node biopsy (SLNB) in early-staged breast cancer (EBC) remains controversial. This study aimed to evaluate a novel method by combining trans-lymphatic contrast-enhanced ultrasound (TLCEUS) with blue dye injection as a guidance of SLNB.

Methods: TLCEUS was performed in 88 patients with newly diagnosed EBC. Methylene blue dye was percutaneously injected into enhanced sentinel lymph nodes (SLNs) under ultrasound guidance, followed by standard SLNB and axillary lymph node dissection. Enhancement patterns and the arriving time (AT) of contrast agent within SLNs were evaluated. Histopathological examination of dissected nodes was performed to confirm metastasis.

Results: A total of 95 enhanced SLNs were identified and biopsied in 86 of 88 patients with identification rate of 97.7%. The specificity was 75.0%, sensitivity was 83.3%, and false-negative rate was 16.7%. Contrast-enhanced SLNs with type I, type II, and type III patterns had a metastatic positive rate of 11.4% (5/44), 57.1% (12/21) and 80.0% (24/30), respectively. Metastatic positive SLNs showed a mean AT of 61.6 ± 58.7 s while metastatic negative SLNs showed a mean AT of 41.3 ± 19.9 s, which was statistically significantly different.

Conclusion: The TLCEUS/blue dye method can be used as an alternative to the radioisotope/blue dye method for its feasibility and accuracy.

Key words: Axillary lymph node dissection; Contrast-enhanced ultrasound; Early-staged breast cancer; Methylene blue dye; Sentinel lymph node biopsy

Advanced Ultrasound in Diagnosis and Therapy 2018;02:094–100

Breast cancer is one of the most common cancers in Chinese women. Early-staged breast cancer (EBC) is mostly curable by current treatment.

Status of axillary lymph node (ALN) metastasis is a key indicator to accurately define EBC. Axillary lymph node dissection (ALND) was a routine processing

* Corresponding Author: Department of Ultrasonography, Peking University Shenzhen Hospital, 1120 Lianhua Road, Shenzhen, Guangdong, 518036 China.
e-mail: szdssun1@126.com

in surgical treatment for all breast cancer patients until 1990s [1]. However, patients with EBC could not benefit from ALND, but may suffer from various postoperative complications associated with ALND, such as lymphedema and sensory- and motor-dysfunction. To reduce the risk of ALND in EBC patients, sentinel lymph node biopsy (SLNB) was developed since 1990s [2]. As illustrated by Dixon et al. [3], the validity of SLNB was based on two principles: First is the existence of an orderly and predictable pattern of lymphatic drainage to a regional node basin, or the so-called sentinel lymph nodes (SLNs), and second is that the first node act as an effective filter for tumor cells [3]. Previous clinical trials reported that EBC patients with negative SLNB shared similar long-term prognosis with those having negative ALND, while positive SLNB accurately predicted ALN metastasis [4–7]. Therefore, ALND could be avoided in certain EBC patients after negative SLNB although treatment has to be escalated for patients with positive SLNB. Currently, SLNB is considered as the standard of clinical care in EBC patients.

Although SLNB is important in patients with EBC, preoperative detection and selection of SLNs for biopsy remain challenging. According to current guidelines, the recommended “gold-standard” for SLNB is the combined use of a radioisotope and an aniline dye (isosulfan or methylene blue), or the so-called radioisotope/blue dye method [8]. However, these methods have some shortcomings. Firstly, necessary special including radioisotope itself and well-trained staffs are not always available in most hospitals, let alone its inevitable radioactive contamination. Secondly, high false-positive and negative rates of SLNs by mean of conventional blue dye injection may induce unnecessary lymph node dissection [9]. Thirdly, it can only provides rough location of SLNs which require large dissection for biopsy and thus give less help for making operation plan before and during surgery. In addition, it is impossible to use radioisotope/blue dye method to get imaging characteristics of SLNs and nearby structures, which is supposed to be helpful information for diagnosis and treatment strategy. All these disadvantages limit its widely use in clinical practice.

Contrast-enhanced ultrasound (CEUS) technique has been widely accepted as a revolutionary development in the field of ultrasound imaging. Contrast microbubbles, which can easily pass through lymphatic channel, were supposed to be a promising agent for lymphatic imaging [10]. Trans-lymphatic contrast-enhanced ultrasound (TLCEUS) has been reported to be feasible for mapping SLNs in EBC patients [11]. Some preliminary studies had reported promising diagnostic value of trans-lymphatic CEUS (TLCEUS) for evaluating ALN

metastasis of EBC [12–14]. To improve the accuracy of SLNB and identification of SLNs at surgery, we hypothesis that TLCEUS in combination with blue dye injection of enhanced SLNs can serve as a method for SLNB and surgery in EBC patients. The aim of this study was to evaluate the novel method by combining TLCEUS with blue dye injection of enhanced SLNs for guiding SLNB and to identify SLNs at surgery in order to improve the positivity of SLNs detection.

Patients and methods

Patients

This clinical research was approved by the institutional ethics committee of Peking University, Shenzhen Hospital. Between January 2013 and December 2015, 88 female patients with newly diagnosed EBC and undergoing SLNB and surgery were enrolled in this study. The definition of the EBC was defined as breast cancers that has not spread beyond the breast or the ALNs, including ductal carcinoma in situ and stage I, stage IIA, stage IIB, and stage IIIA breast cancers. Patients with inflammatory breast cancer, previous surgery in the ipsilateral breast or axillary, under neoadjuvant chemotherapy, pregnancy or nursing and contraindication to ultrasound contrast agent were excluded. Informed consent was collected from each patient before the procedure. The characteristics of enrolled patients were listed in Table 1.

Instruments and materials

The ultrasound scanner (MyLab 90, ESAOTE, Italy) equipped with high frequency linear array probes (LA5-10) and contrast pulse sequences (MI 0.07) for gray-scale and contrast-enhanced scanning was used in this study. Ultrasound contrast agent SonoVue® (Bracco Imaging, Italy) was used for TLCEUS. Before injection, 59 mg SonoVue powder was suspended by 5 mL normal saline and shaken vigorously for more than 30 s to ensure a homogenous suspension. Methylene blue as a lymph node marker was purchased from Jumpcan Pharmaceutical (Taizhou, Jiangsu, China).

Gray-scale and contrast ultrasound imaging

Before TLCEUS, a conventional gray-scale ultrasound was performed to examine the axillary area for evaluation of regional lymph node in each patient. Any lymph nodes greater than 1 cm or with round-shape and hilum disappeared features was considered as a metastasis node and documented for later analysis. Then 1.5 mL contrast agent suspension was intradermally injected into the peri-areola area at the tumor-located quadrant. Immediately after the injection, contrast imaging mode was used to identify enhanced lymphatic drainage channels, and lead

to detecting the SLNs. The location of the enhanced SLNs was labeled by mark pen on the skin. The size of enhanced SLNs, enhancement patterns, arriving time (AT) which was defined as time between injection of contrast agent and first enhancement of the SLNs were recorded for further analysis.

Table 1 Clinical characteristics of enrolled patients

Clinical characteristics	Data (n = 88)
Menopause status	
Postmenopause	25/88 (28.4%)
Premenopause	63/88 (71.6%)
Age	
Mean	46.0 ± 10.9 years
Median	45 (27–74) years
Tumor orientation	
Upper outer quadrant	32/88 (36.4%)
Upper inner quadrant	20/88 (22.7%)
Lower outer quadrant	17/88 (19.3%)
Lower inner quadrant	16/88 (18.2%)
Central area	3/88 (3.4%)
Maximum SLN diameter	
Mean	21.6 ± 8.5 mm
Median	21.0 (7.0–48.0) mm
Tumor stage	
Tis	50/88 (56.8%)
T1	16/88 (18.2%)
T2	22/88 (25.0%)
HER2 positive	
HER2 positive	15/88 (17.0%)
Triple negative	
Triple negative	14/88 (15.9%)

SLN, sentinel lymph node; HER2, human epidermal growth factor receptor 2.

Blue dye injection to labeled SLNs

After SLNs were identified by TLCEUS, up to 0.5 mL methylene blue dye was subsequently injected into the enhanced SLNs under ultrasound guidance. For abnormal lymph nodes which were considered as SLNs by gray-scale ultrasound imaging, but did not show any enhancement in TLCEUS, methylene blue dye was also injected into these nodes under ultrasound guidance.

TLCEUS enhancement patterns of SLNs

The enhancement patterns of lymph nodes in contrast imaging were classified into three types. Type I: Complete enhancement of the cortex and medulla area of SLNs with smooth border; type II: Annular enhancement mainly at the cortex area with regular/irregular border while less enhancement in the medulla area; type III Partial enhancement of cortex and medulla area with irregular border (Fig. 1A). The contrast-enhanced SLNs were reviewed and categorized into three types of enhancement patterns in blind fashion compared with pathological results.

SLNB and ALND procedure

After ultrasound evaluation of enhanced and suspicious SLNs with blue dye labeling procedure, local anesthesia was given before CEUS and fixed-point dye injection. Right after the injection finished as above, standard SLNB was performed by three well-trained surgeons. The blue dye marked SLNs were completely dissected. After SLNB, a standard ALND was performed to all patients enrolled. Excised lymph nodes were numbered, fixed with 10% formalin, and underwent histology, cytology and immunohistochemistry examination for possible cancer metastasis. The final pathological diagnosis of SLNs' status were compared with enhancement patterns of SLNs. Immunohistochemical parameters (ER, PR, Her2, Ki-67) of each breast tumor were recorded for further analysis.

Statistics

The diagnostic performance of TLCEUS with blue dye injection of SLNs was evaluated by accuracy, specificity, sensitivity, false-negative rate and false-positive rate. Chi-square test or Fisher's exact test was employed for analyzing categorical variables; Student's t-test was used for analyzing continuous variables. SPSS statistical software version 21.0 (SPSS Inc. Chicago, USA) was used in this study. A *p* value less than 0.05 was considered as statistically significant.

Results

SLNs identification by TLCEUS with blue dye marker and gray-scale US

In 86 out of 88 (97.7%) patients, 95 SLNs were identified by TLCEUS. Of the 86 patients, 78 patients had one SLN identified in each patient, 7 patients identified two SLNs, and one patient identified three SLNs. In addition, five patients with nine lymph nodes which were suspected as metastatic SLNs by gray-scale US, but did not enhance by TLCEUS were also included for SLNB and pathology analysis. All of the

88 patients underwent SLNB successfully with removal of 104 lymph nodes. After SLNB, all of the 88 patients underwent ALND successfully too.

The diagnostic value of TLCEUS with blue dye injection method for SLNB

The TLCEUS combined with dye injection for guiding SLNB were successfully performed in all the 95 enhanced SLNs (Fig.1B). Among the 95 biopsied SLNs, 41 SLNs from 39 patients were proved to be positive in metastasis by pathological examination. The metastatic positive rate of TLCEUS/blue dye injection method for SLNB was 43.2% (41/95). After SLNB, ALND was performed to all patients enrolled, and non-SLNs metastasis status of each patient was confirmed. As is shown in Table 2, in the 86 patients with SLNs identified by TLCEUS/blue dye injection method, metastasis was confirmed in 27 patients in both SLNs and non-SLNs; 42 patients were SLNs and non-SLNs double negative. There were five patients whose SLNs were metastasis negative pathologically, but their ALND confirmed "non-SLNs skip metastasis". Therefore, results of these five patients were regarded as false-negative during analysis. Thus, the diagnostic value of TLCEUS with blue dye labeling method was high for SLNs detection and non-SLNs metastasis prediction, with a specificity of 75.0%, a sensitivity of 83.3%, and a false-negative rate of 16.7% (Table 2).

Table 2 Diagnostic value of SLNB guided by TLCEUS/fixed-point dye injection method

Metastasis status	non-SLN+	non-SLN-	Total
SLN+	25 (83.3%)	14 (25.0%)	39 (45.3%)
SLN-	5 (16.7%)	42 (75.0%)	47 (54.7%)
Total	30 (100%)	56 (100%)	86 (100%)

SLNB, sentinel lymph node biopsy; TLCEUS, trans-lymphatic contrast-enhanced ultrasound; SLN, sentinel lymph node.

Enhancement patterns related to metastasis positivity of SLNs

Clinical factors, including age, tumor stage, tumor location, HER2 status, triple negative EBC or not, Ki67 index level had no statistical differences between metastasis positive SLNs and negative SLNs of the patients. However, two imaging parameters (*i.e.*, TLCEUS enhancement patterns and contrast arriving time) did show significant difference between these two groups of patients. First, contrast-enhanced SLNs with type I, type II, and type III patterns had a metastasis positive rate of 11.4% (5/44), 57.1% (12/21) and 80.0%

(24/30), respectively. The difference was significant between type I and type II ($p=0.0002$), but was not significant between type II and type III ($p=0.077$). In the other nine lymph nodes dissected, which were suspected as SLNs by gray-scale ultrasound but were not enhanced by TLCEUS, eight nodes were confirmed as metastasis positive on pathology. The metastatic positive rate was 88.9% (8/9) (Fig. 1C). Second, for the contrast arriving time (AT), metastatic positive SLN group showed a mean AT of 61.6 ± 58.7 s, while metastatic negative SLN group showed a mean AT of 41.3 ± 19.9 s, which was statistically significantly different with a p value of 0.047 (Fig. 1D).

Discussion

Incidence of breast cancer keeps on rising in China. According to the Chinese National Central Cancer Registry, the age-standardized rate (ASR) of breast cancer was as high as 34.3 cases per 100 000 women in urban areas and 17.0 cases per 100 000 women in rural areas in 2014 [15]. In spite of the high morbidity, 5-year overall survival (OS) of breast cancer in China was more than 80% as was reported by CONCORD-2 [16]. The importance of SLNB for staging and treatment of EBC has been recognized in clinical practice. Many methodological studies have been performed trying to find a method with acceptable specificity, sensitivity and false-negative rate to specifically guide preoperative SLNB. For example, PET/CT, SPECT/CT, MRI and traditional gray-scale US have all been attempted. As was reported, the addition of PET/CT, SPECT/CT or MRI to traditional preoperative examination could all contribute to improve diagnostic accuracy to SLNs [17–21]. However, these studies are currently either too preliminary or too expensive to be widely applied in clinical setting. Conventional gray-scale ultrasound is inexpensive and feasible, and thus is a preferred modality in China for preoperative diagnosis and staging of breast cancer patients [22]. However, routine US examination is not sensitive and specific enough for identification of SLNs. A meta-analysis published in 2014 reported that although approximately 50% of patients with axillary involvement could be identified preoperatively by conventional ultrasound, there were still 25% of patients in which an ultrasound-guided biopsy-"proven" negative axilla had a positive SLNB [23]. Although radioisotope/blue dye method is imperfect, it remains the primary recommended method for guiding SLNB. Considering the deficiencies of radioisotope/blue dye method, developing new technique is of great clinical value. In this study, a novel method by TLCEUS guided blue dye injection for SLNB was explored in patients of breast cancer.

Goldberg et al. [24] firstly reported the application of TLCEUS for SLNs detection in 2004. The contrast agent used by TLCEUS has been proved to be a stable

tracer which can be easily taken by, rapidly accumulated in, and of strong lymphatic tropism to the lymphatic drainage pathway. Therefore, it can act as an ideal

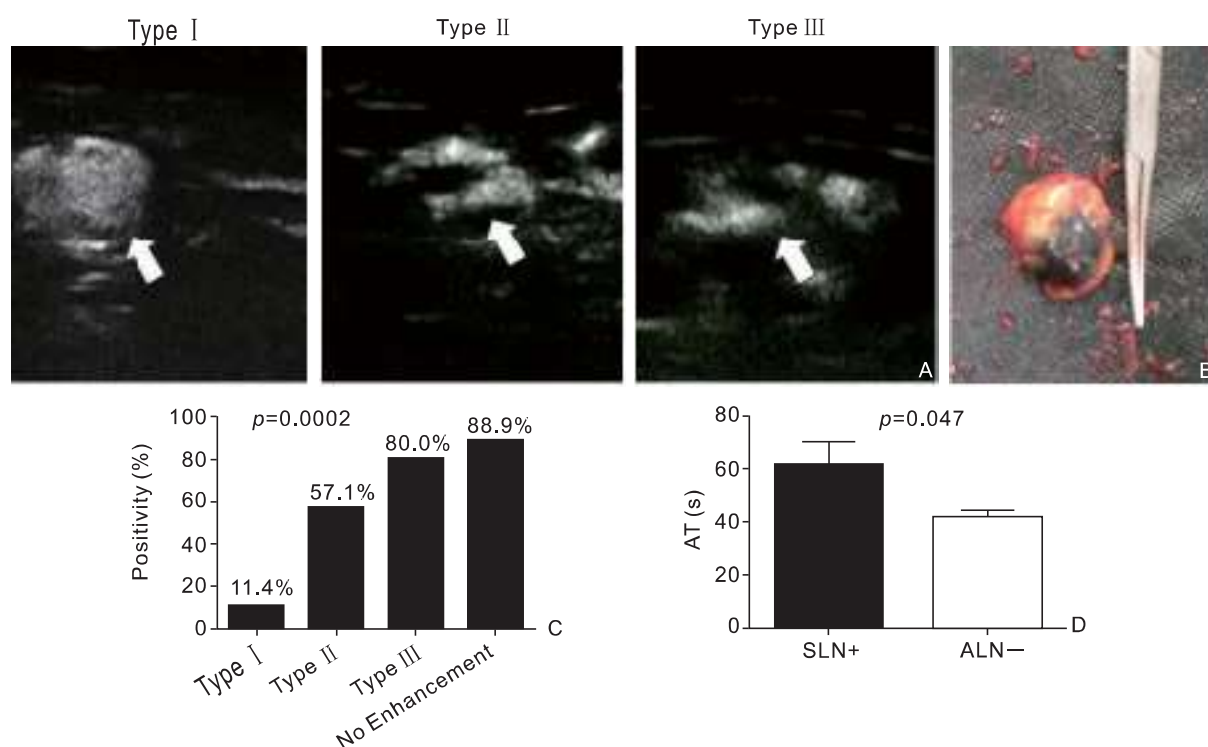


Figure 1 TLCEUS/blue dye injection method is sensitive and specific for SLNB. A) Different contrast pattern of SLNs observed by TLCEUS; B) Sample of dissected SLNs with obvious blue dye; C) Lymph nodes with type II and type III contrast pattern, and lymph nodes without enhancement are more likely to be metastasis positive; D) Positive SLNs showed a longer AT between contrast agent injection and lymph node enhancement than negative SLNs. TLCEUS, trans-lymphatic contrast enhanced ultrasound; SLNs, sentinel lymph node; AT, arriving time. A p value less than 0.05 is considered as statistically significant.

alternative for SLNs detection instead of blue dye alone. Since 2004, many studies have reported the diagnostic value of TLCEUS for SLNs detection and guided-SLNB [11,14,25–27]. According to these studies, the TLCEUS identification rate for SLNs was about 80%, while its sensitivity was relatively as low as 60%–80%. Most importantly, the false negative rate was about 10%–16%. Although TLCEUS is considered as a potential alternative to radioisotope/blue dye method for SLNs detection in patients with breast cancer, the identification rate and sensitivity of TLCEUS alone, as was reported, was relatively low for clinical application [25–27]. The reason for its low identification rate and sensitivity may be that the contrast agent injected during TLCEUS, although traceable under US probe scanning, cannot be traced and detected in the SLNs during biopsy. Thus, the SLNB after TLCEUS is less targeted without any marker. We believe that placing a marker in enhanced SLNs during preoperative TLCEUS is needed for SLNB to improve its identification rate and sensitivity. In consideration that contrast agent is a better tracer

than blue dye, conventional blue dye injection near the primary tumor site for SLN mapping is redundant and unnecessary. In this study, methylene blue dye as surgical marker was injected directly into the enhanced SLNs identified by TLCEUS. Our results showed the identification rate of TLCEUS in detecting SLNs was as high as 97.7% (86/88 patients). Intra lymph nodes dye injection under the guidance of ultrasound can ensure the precision of the dye into targeted SLNs and thus reduce the shortcoming of high false positivity by traditional blue dye mapping method. All enhanced SLNs in our study were well dyed according to naked eye judgment during SLNB and operation and were completely resected. Blue dye showed no influence for the following pathological diagnosis. In this situation, the methylene blue dye does not only act as mapping tracer, but also as labeling marker for biopsy and resection. According to surgery outcomes, TLCEUS combined with blue dye injection method presented a better performance on localizing and labeling SLNs than TLCEUS alone. The sensitivity (83.3%) of this new method was close to

that of radioisotope/blue dye method (90%) as reported, while the false-negative rate (16.7%) was also similar to that of radioisotope/blue dye method (10%-16%) [28,29]. Comparing with current radioisotope/blue dye mapping methods, TLCEUS with blue dye labeling method is a feasible alternative for identification of SLNs and guidance of SLNB.

This study also demonstrated that TLCEUS could have potential value in judging whether metastasis existed inside the SLNs. There are several factors helpful for predicting metastasis status of SLNs. The first is the contrast enhancement pattern. The enhanced SLNs with wheel-like smooth border or with evenly distributed contrast agents inside cortex and medulla are most likely to be non-metastasis normal nodes. The SLNs with irregularly border and only partially enhanced at cortex area are more likely to be the metastasis SLNs. In addition, SLNs suspected by conventional gray-scale ultrasound but showed no enhancement by TLCEUS are the most likely to be metastatic SLNs. The second factor which is helpful for predicting metastasis status is the AT of contrast agent in the SLNs after injection. The result of this study revealed that metastasis positive SLNs showed a much longer AT compared with normal SLNs. Both of these two factors indicate that lymphatic drainage or parenchyma of cortex and medulla is blocked or destructed by cancer infiltration. In metastasis positive SLNs, micrometastasis blocks the lymphatic inside or outside of SLNs, thus resulting in the truncated enhancement or no enhancement sign, and the prolonged AT [30].

Conclusion

Accurate SLNB can provide beneficial information for patients' prognosis and treatment. In this study, we developed a method combining TLCEUS and methylene blue dye injection for detecting SLNs and guiding SLNB. According to our results, this is a reliable method and can be used as a feasible alternative technique to the radioisotope/blue dye in clinical setting. The imaging characteristics, including the enhancement pattern and AT, would possibly further predict metastasis status of SLNs, thus providing additional clinical information for treatment strategy of breast cancer.

Conflicts of Interest

This work was supported by the Basic Research Project of Shenzhen Science and Technology Program (Grant No. 201202008 and 20160428173422809).

References

- [1] Noguchi M, Morioka E, Ohno Y, Noguchi M, Nakano Y, and Kosaka

T. The changing role of axillary lymph node dissection for breast cancer. *Breast Cancer* 2013;20:41–6.

- [2] Fu Y, Chung D, Cao MA, Apple S, Chang H. Is axillary lymph node dissection necessary after sentinel lymph node biopsy in patients with mastectomy and pathological N1 breast cancer? *Ann Surg Oncol* 2014;21: 4109–23.
- [3] Dixon JM. Sentinel Lymph Node Biopsy in Breast Cancer Surgery. *Ann Surg Oncol* 2016;23:3426–8.
- [4] Andersson Y, de Boniface J, Jonsson PE, Ingvar C, Liljegren G, Bergkvist L, et al. Axillary recurrence rate 5 years after negative sentinel node biopsy for breast cancer. *Br J Surg* 2012;99:226–31.
- [5] Kootstra JJ, Hoekstra-Weebers JE, Rietman JS, de Vries J, Baas PC, Geertzen JH, et al. A longitudinal comparison of arm morbidity in stage I-II breast cancer patients treated with sentinel lymph node biopsy, sentinel lymph node biopsy followed by completion lymph node dissection, or axillary lymph node dissection. *Ann Surg Oncol* 2010;17:2384–94.
- [6] Kuehn T, Bauerfeind I, Fehm T, Fleige B, Hausschild M, Helms G, et al. Sentinel-lymph-node biopsy in patients with breast cancer before and after neoadjuvant chemotherapy (SENTINA): a prospective, multicentre cohort study. *Lancet Oncol* 2013;14:609–18.
- [7] Takei H, Kurosumi M, Yoshida T, Ishikawa Y, Hayashi Y, Ninomiya J, et al. Axillary lymph node dissection can be avoided in women with breast cancer with intraoperative, false-negative sentinel lymph node biopsies. *Breast Cancer* 2010;17:9–16.
- [8] Goldhirsch A, Wood WC, Coates AS, Gelber RD, Thurlimann B, Senn HJ. Strategies for subtypes—dealing with the diversity of breast cancer: highlights of the St. Gallen International Expert Consensus on the Primary Therapy of Early Breast Cancer 2011. *Ann Oncol* 2011;22:1736–47.
- [9] Nowikiewicz T, Kurylcio A, Polkowski W, Zegarski W. Imaging methods for the local lymphatic system of the axilla in early breast cancer in patients qualified for sentinel lymph node biopsy. *Prz Menopauzalny* 2016;15:52–5.
- [10] Goldberg BB, Merton DA, Liu JB, Murphy G, Forsberg F. Contrast-enhanced sonographic imaging of lymphatic channels and sentinel lymph nodes. *J Ultrasound Med* 2005;24:953–65.
- [11] Cox K, Sever A, Jones S, Weeks J, Mills P, Devalia H, et al. Validation of a technique using microbubbles and contrast enhanced ultrasound (CEUS) to biopsy sentinel lymph nodes (SLN) in pre-operative breast cancer patients with a normal grey-scale axillary ultrasound. *Eur J Surg Oncol* 2013;39:760–5.
- [12] Cox K, Weeks J, Mills P, Chalmers R, Devalia H, Fish D, et al. Contrast-Enhanced Ultrasound Biopsy of Sentinel Lymph Nodes in Patients with Breast Cancer: Implications for Axillary Metastases and Conservation. *Ann Surg Oncol* 2016;23:58–64.
- [13] Matsuzawa F, Einama T, Abe H, Suzuki T, Hamaguchi J, Kaga T, et al. Accurate diagnosis of axillary lymph node metastasis using contrast-enhanced ultrasonography with Sonazoid. *Mol Clin Oncol* 2015;3:299–302.
- [14] Saracco A, Szabo BK, Tanczos E, Bergh J, and Hatschek T. Contrast-enhanced ultrasound (CEUS) in assessing early response among patients with invasive breast cancer undergoing neoadjuvant chemotherapy. *Acta Radiol* 2017;58:394–402.
- [15] Fan L, Strasser-Weippl K, Li JJ, Louis JS, Finkelstein DM, Yu KD, et al. Breast cancer in China. *Lancet Oncol* 2014;15:e279–89.
- [16] Allemani C, Weir HK, Carreira H, Harewood R, Spika D, Wang XS, et al. Global surveillance of cancer survival 1995–2009: analysis of individual data for 25 676 887 patients from 279 population-based registries in 67 countries (CONCORD-2). *Lancet* 2015;385:977–1010.
- [17] Fujii T, Yajima R, Tatsuki H, Kuwano H. Prediction of Extracapsular

- Invasion at Metastatic Sentinel Nodes and Non-sentinel Lymph Nodal Metastases by FDG-PET in Cases with Breast Cancer. *Anticancer Res* 2016;36:1785–9.
- [18] Arslan G, Altintoprak KM, Yirgin IK, Atasoy MM, Celik L. Diagnostic accuracy of metastatic axillary lymph nodes in breast MRI. *Springerplus* 2016;5:735.
- [19] Pouw JJ, Grootendorst MR, Bezooijen R, Klazen CA, De Bruin WI, Klaase JM, et al. Pre-operative sentinel lymph node localization in breast cancer with superparamagnetic iron oxide MRI: the SentiMAG Multicentre Trial imaging subprotocol. *Br J Radiol* 2015;88:20150634.
- [20] Borrelli P, Donswijk ML, Stokkel MP, Teixeira SC, van Tinteren H, Rutgers EJ, et al. Contribution of SPECT/CT for sentinel node localization in patients with ipsilateral breast cancer relapse. *Eur J Nucl Med Mol Imaging* 2016;44: 630–37.
- [21] Nakano Y, Noguchi M, Yokoi-Noguchi M, Ohno Y, Morioka E, Kosaka T, et al. The roles of (18)F-FDG-PET/CT and US-guided FNAC in assessment of axillary nodal metastases in breast cancer patients. *Breast Cancer* 2017;24:121–7.
- [22] Nieciecki M, Dobruch-Sobczak K, Wareluk P, Guminska A, Bialek E, Cacko M, et al. The role of ultrasound and lymphoscintigraphy in the assessment of axillary lymph nodes in patients with breast cancer. *J Ultrason* 2016;16:5–15.
- [23] Diepstraten SC, Sever AR, Buckens CF, Veldhuis WB, van Dalen T, van den Bosch MA, et al. Value of preoperative ultrasound-guided axillary lymph node biopsy for preventing completion axillary lymph node dissection in breast cancer: a systematic review and meta-analysis. *Ann Surg Oncol* 2014; 21:51–9.
- [24] Goldberg BB, Merton DA, Liu JB, Thakur M, Murphy GF, Needleman L, et al. Sentinel lymph nodes in a swine model with melanoma: contrast-enhanced lymphatic US. *Radiology* 2004;230:727–34.
- [25] Esfehiani MH, Yazdankhah-Kenari A, Omranipour R, Mahmoudzadeh HA, Shahriaran S, Zafarghandi MR, et al. Validation of Contrast Enhanced Ultrasound Technique to Wire Localization of Sentinel Lymph Node in Patients with Early Breast Cancer. *Indian J Surg Oncol* 2015;6:370–3.
- [26] Sever AR, Mills P, Weeks J, Jones SE, Fish D, Jones PA, et al. Preoperative needle biopsy of sentinel lymph nodes using intradermal microbubbles and contrast-enhanced ultrasound in patients with breast cancer. *AJR Am J Roentgenol* 2012;199:465–70.
- [27] Xie F, Zhang D, Cheng L, Yu L, Yang L, Tong F, et al. Intradermal microbubbles and contrast-enhanced ultrasound (CEUS) is a feasible approach for sentinel lymph node identification in early-stage breast cancer. *World J Surg Oncol* 2015;13:319.
- [28] Kim T, Giuliano AE, Lyman GH. Lymphatic mapping and sentinel lymph node biopsy in early-stage breast carcinoma: a metaanalysis. *Cancer* 2006;106:4–16.
- [29] Lyman GH, Temin S, Edge SB, Newman LA, Turner RR, Weaver DL, et al. Sentinel lymph node biopsy for patients with early-stage breast cancer: American Society of Clinical Oncology clinical practice guideline update. *J Clin Oncol* 2014;32:1365–83.
- [30] Han C, Yang L, Zuo W. A mini-review on factors and countermeasures associated with false-negative sentinel lymph node biopsies in breast cancer. *Chin J Cancer Res* 2016;28:370–6.