

Proceedings of the Iowa Academy of Science

Volume 67 | Annual Issue

Article 77

1960

Cottontails With "Horns"

Arnold O. Haugen

Iowa Cooperative Wildlife Research Unit

Let us know how access to this document benefits you

Copyright ©1960 Iowa Academy of Science, Inc.

Follow this and additional works at: <https://scholarworks.uni.edu/pias>

Recommended Citation

Haugen, Arnold O. (1960) "Cottontails With "Horns"," *Proceedings of the Iowa Academy of Science*, 67(1), 610-615.

Available at: <https://scholarworks.uni.edu/pias/vol67/iss1/77>

This Research is brought to you for free and open access by the Iowa Academy of Science at UNI ScholarWorks. It has been accepted for inclusion in Proceedings of the Iowa Academy of Science by an authorized editor of UNI ScholarWorks. For more information, please contact scholarworks@uni.edu.

Cottontails With "Horns"¹

ARNOLD O. HAUGEN²

Abstract. Published information on papillomas, commonly called horns, on cottontails (*Sylvilagus floridanus*) in Iowa dates back to 1907. Specimens of horned rabbits are on record from Woodbury, Pottawattamie, Cherokee, Franklin, and Boone counties. Those from the last two counties were necropsied at Iowa State University in 1958 and 1959-60, respectively. Information from conservation officers and biologists shows sight records for a number of years past for at least 16 additional counties. The malady seems to be limited almost entirely to the western half of the state.

Man is not alone in suffering from tumors. They also occur in domestic animals and birds, and so far as is known, in almost all wild mammals and birds. Two types of external skin tumors have been reported from cottontails (*Sylvilagus floridanus*). One kind, known as a fibroma and found occasionally on cottontails east of the Mississippi River, is a hairless wart-like growth arising from connective tissue.

Forty cottontails with fibromas were found by the author in southwestern Michigan 20 years ago (Figure 1). These hairless, pale-colored and roundish growths occurred most often on the feet but were also found on the nose, eyelids, lips, and ears, usually where the hair was short (Haugen, 1942). In that study, the growths (mistakenly called papillomas at that time) were found only during the fall months and occurred almost exclusively on young-of-the-year. Affected cottontails lost their tumors during winter, as the growths were missing when ear-tagged rabbits were re-trapped the following spring and summer. Evidence of regression and disappearance of fibromas is also available from Maryland (Herman *et al.*, 1956).

The second type of tumorous external growth, known as papillomas or "horns," is common on cottontails from central Iowa west. These growths are horn-like, hard, blackish and rough, and involve only the skin. The earliest records for Iowa were reported to the Iowa Academy of Science by Guthrie (1919) (Table 1). His pub-

¹Journal Paper No. 3716 of the Iowa Agricultural and Home Economics Experiment Station, Ames, Iowa. Project No. 1119. Contribution of the Iowa Cooperative Wildlife Research Unit; Iowa State University of Science and Technology; Iowa State Conservation Commission; Wildlife Management Institute; and U. S. Fish and Wildlife Service, Bureau of Sport Fisheries and Wildlife, cooperating.

²Biologist, Bureau of Sport Fisheries and Wildlife, and Leader, Iowa Cooperative Wildlife Research Unit, Ames, Iowa.

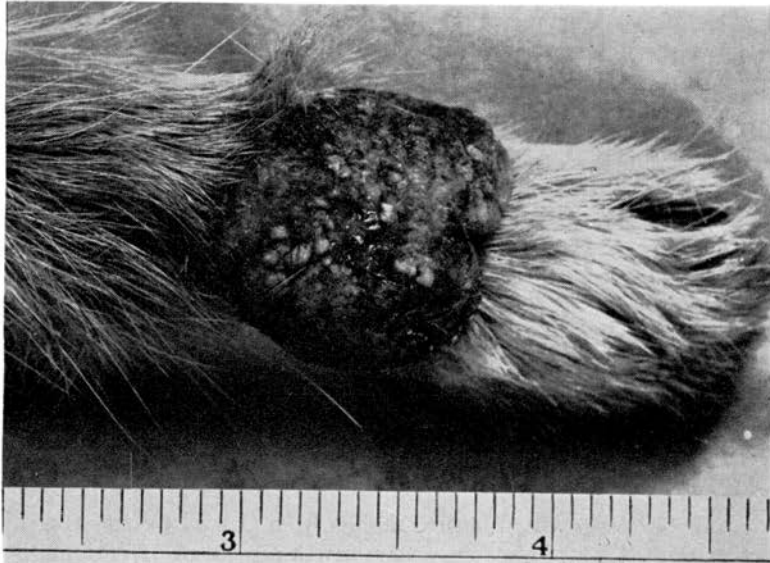


Figure 1. Fibroma on the front foot of a cottontail from Michigan. Photograph by courtesy of Michigan Department of Conservation.

lished photograph indicated the "horns" were papillomas. Histologic examination of a specimen from Woodbury County, Iowa, at that time showed that the growth consisted of a dense mass of cornified epithelium.

Table 1

Occurrence of Warts on Cottontail Rabbits As Reported by Guthrie (1919)

Location	Year	Number specimens	Local occurrence
Pottawattamie County, Iowa	1907	1	First one seen
Woodbury County, Iowa	1918	1	Rare
	1919	1	
Harrison County, Iowa	1918		Common
Black Hawk County, Iowa	1919	1	
S. E. South Dakota	1918-19		About 10% infected
South-Central Minnesota (Faribault County)	1918-19		Few
Nebraska (southern)	1901		80% in some counties

Shope's (1933) original work on papillomas was with warts collected from a cottontail near Cherokee, Iowa, by Clifford Peck of that city. His study resulted in the discovery of a virus as the causative agent and produced data on the histology, etiology, and experimental transmission of the malady. In commenting on the source of the specimens, Shope wrote, "Our attention was recently called to a disease occurring in rabbits in northwestern Iowa. Rabbits shot there . . . have numerous horn-like protuberances on the

skin. . . ." He further commented that 11 of 75 wild cottontails from southern Kansas were affected with the same wart-like disease.

Seton (1929) reported such horns on cottontails from Oklahoma, Nebraska, and Colorado. His published sketches showed the arrangement and size of the growths, which numbered as many as 15 on one specimen. Sizes ranged up to two and one-half inches in length.

Speaker (1959) reported the first time he saw horns on cottontails was in October, 1925, along Indian Creek in Sac County, Iowa. He commented that rabbits were numerous and nearly one-half of those observed had horns, mostly on the head. Some growths were up to two inches in length. In 1938, he found numerous similarly infected individuals in a large population of cottontails in Van Buren County, Iowa.

Smith (1960) reported horned rabbits from Carroll County, Iowa, in the 1958-59 hunting seasons, when five or six out of 35 cottontails bagged were afflicted. Four out of 20 killed in the 1959-60 season were horned, with from one to 35 growths per cottontail. The outbreak seemed to be localized along the railroad tracks east of Carroll.

Records from the Iowa Veterinary Medical Diagnostic Laboratory of Iowa State University show one case of papillomas in 1929, three in 1958 (Franklin County), one in 1959, and one in 1960 (Boone




Figure 2. Papillomas or "horns" on a cottontail from Hampton, Franklin County, Iowa.

County). These records were kindly provided by Dr. Paul C. Bennett of the Diagnostic Laboratory. No cases were observed at the clinic in the intervening years.

Three cottontail specimens acquired from the Loren Stock farm at Hampton, Iowa, were examined by the author and then sent on to the Veterinary Diagnostic Laboratory for necropsy. The horns observed on these specimens were located on the head and varied from barely visible to three inches in length. Numbers were almost impossible to count because the larger growths supported many smaller horns until a total of between two and three dozen separate tips were visible on the specimen most severely infected (Figure 2). Conservation Officer James Gregory, who collected the specimens by shooting (June 3), reported the horned individuals appeared unsteady on their feet and ran with their heads tilted.

The Boone County specimen for 1960 was picked up as a roadkill on April 4 by Conservation Commission Biologist Eldie Mustard. Horns that ranged in size roughly up to an inch in length occurred around the base of the ears. Many small horns hidden in the fur were found along the throat and near the umbilical region; when palpated, they felt like cockleburs. Figure 3 shows the flesh

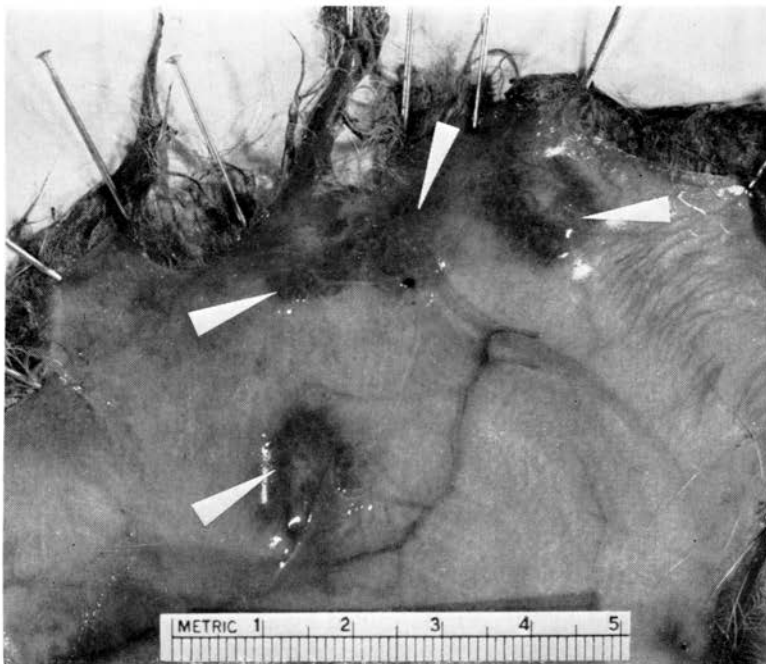

Figure 3. Cottontail papillomas are not visible from the flesh side of the skin, but each site of attachment is indicated by a slightly inflamed area. The inner surface layer of the skin could be moved about without moving the papilloma.

side of the skin at the base of some of the "horns" from this specimen.

Replies to a questionnaire sent to all Iowa conservation officers and a few other selected conservation officials indicate that Iowa cottontails with "horns" are almost entirely limited to the western half of the state (Figure 4). Their replies cover observations over a period of years. Guthrie's (1919) records indicated the presence of "horned" cottontails in Iowa's western border counties, in states farther west, and in south-central Minnesota. At the present time it seems that U. S. Highway 69, which runs north to south through the central part of Iowa, is the eastern boundary for "horned" rabbits. Known exceptions to this rule are the records from Van Buren County in southeast Iowa in 1938, and from Hampton in 1958. Hampton, however, is only 22 miles east of the line.

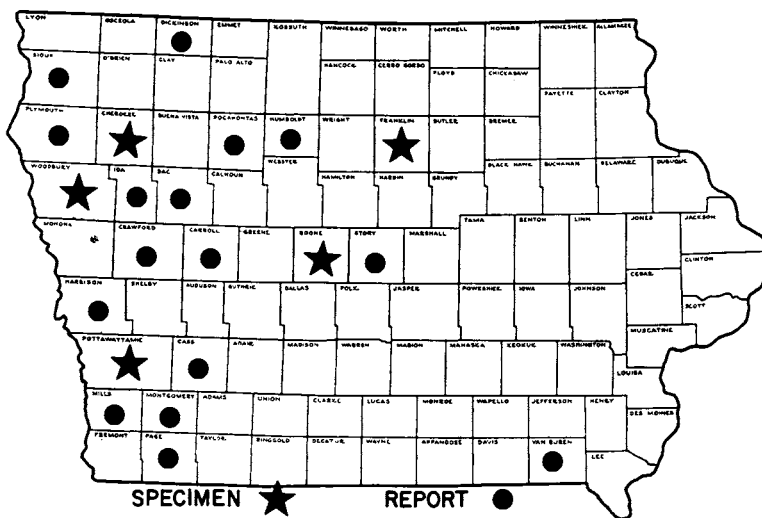


Figure 4. Distribution of known cases of papillomas in cottontails in Iowa in years past.

Both fibromas and papillomas normally are non-malignant in cottontails, but a few cases of malignant cancerous growths associated with horns have been reported from cottontails in Kansas and Oklahoma (Kidd *et al.*, 1940). Tumors on wild rabbits are of considerable interest to cancer specialists because they are examples of growths caused by an infectious agent. Such growths on cottontails have no known relation to cancer in man.

Both types of skin tumors are caused by a virus infection spread by blood-sucking insects. Three species of mosquitos (Kilham *et al.*, 1955) and one species of flea (Kilham *et al.*, 1953) are known vectors for fibromas. Ticks, and very likely mosquitos and biting

flies, spread the virus of papillomas from infected to healthy individuals (Green, 1936). Rabbits that recover from their tumors are regarded as immune to further infection (Shope, 1932). Fibromas may be infective to other rabbits for periods as long as 10 months (Kilham *et al.*, 1955).

Whether or not any significant number of deaths of cottontails results from the tumors is uncertain in the light of present knowledge. However, Green (1936) and Kidd *et al.* (1940) both believe that many of the cottontails die from the affliction. Mortality to the European chamois and ibex from papillomas has been reported by Bouvier *et al.* (1951). It is probable that individual cottontails affected to the extent shown in Figure 2 may fall easy prey to enemies, including foxes, dogs, cats, owls and hawks. The "picking off" of such "horned" rabbits, if and when it occurs, can be regarded as a "sanitary operation," a service by the predators in removing carriers or reservoirs as sources for further spreading of the infection.

It is fortunate for Iowa sportsmen that the occurrence of papillomas is limited, because the unsightly appearance is enough to cause many hunters to discard affected rabbits. The relative rarity of such "horned" growths is indicated by their occasional display as a biological oddity at local taverns. Actually, the "horns" do not spoil the meat for eating (Herman *et al.*, 1956) as they come off with the skin.

Literature Cited

- Bouvier, G., Burgisser, H., and Schweizer, R. 1951. Papillomatose du chamois. Schweiz. Arch. Tierheilk. 93(9):623-627.
- Green, R. G. 1936. Wildlife disease and population cycles research. Trans. N. A. Wildl. Conf. 1:469-471.
- Guthrie, J. E. 1919. Notes on the occurrence of warts on cottontail rabbits. Iowa Acad. Sci. 26:157-161.
- Haugen, A. O. 1942. Life history studies of the cottontail rabbit in southwestern Michigan. The Am. Midl. Nat. 28(1):204-244.
- Herman, C. M., Kilham, Lawrence, and Warbach, Oscar. 1956. Incidence of Shope's rabbit fibroma in cottontails at the Patuxent Research Refuge. J. Wildl. Mgmt. 20(1):85-89.
- Kidd, John G., and Rous, Peyton. 1940. Cancers deriving from the virus papillomas of wild rabbits under natural conditions. J. Exp. Med. 71(4):469-494.
- Kilham, Lawrence and Dalmat, H. T. 1955. Host-virus-mosquito relationship of Shope fibromas in cottontail rabbits. Am. J. Hyg. 61(1):45-54.
- , Herman, C. M., and Fisher, E. R. 1953. Naturally occurring fibromas of gray squirrels related to Shope's rabbit fibroma. Proc. Soc. Exper. Biol. and Medicine 82:298-301.
- Seton, E. T. 1929. Lives of game animals. Doubleday Doran Co., Garden City, N. Y. Vol. 4, Part 2.
- Shope, R. E. 1932. A filterable virus causing a tumor-like condition in rabbits and its relationship to virus myxomatousum. J. Exp. Medicine 56(6):803-822.
- . 1933. Infectious papillomatosis of rabbits with a note on the histopathology by E. Weston Hurst. J. Exp. Med. 58(5):607-624.
- Smith, Thomas S. 1960. Personal letter to author under date of February 9.
- Speaker, E. B. 1959. Personal letter to author under date of November 3.