

# Proceedings of the Iowa Academy of Science

---

Volume 70 | Annual Issue

Article 72

---

1963

## Effect of Irradiation On Nissl Granules In Rat Spinal Cord Neurons - A Pilot Study

S. D. Miroyiannis

*College of Osteopathic Medicine and Surgery*

B. A. Raines

*College of Osteopathic Medicine and Surgery*

V. Jurczenko

*College of Osteopathic Medicine and Surgery*

Copyright © Copyright 1963 by the Iowa Academy of Science, Inc.

Follow this and additional works at: <https://scholarworks.uni.edu/pias>

---

### Recommended Citation

Miroyiannis, S. D.; Raines, B. A.; and Jurczenko, V. (1963) "Effect of Irradiation On Nissl Granules In Rat Spinal Cord Neurons - A Pilot Study," *Proceedings of the Iowa Academy of Science*: Vol. 70: No. 1 , Article 72.

Available at: <https://scholarworks.uni.edu/pias/vol70/iss1/72>

This Research is brought to you for free and open access by UNI ScholarWorks. It has been accepted for inclusion in Proceedings of the Iowa Academy of Science by an authorized editor of UNI ScholarWorks. For more information, please contact [scholarworks@uni.edu](mailto:scholarworks@uni.edu).

unexpectedly high tolerance to hypoxia of our *Terrapene* (12 hours).

#### Literature Cited

1. Carr, Archie. 1952. Handbook of turtles. Comstock Publ. Assoc., Ithaca, N. Y., 542 p.
2. Conant, R. A. 1958. A field guide to reptiles and amphibians. Houghton Mifflin, Boston, 366 p.
3. Dunson, W. A. 1960. Aquatic respiration in *Trionyx spinifera aspera*. *Herpetologica* 16:277-283.
4. Gaumer, Albert E. H. 1952. Comparison of the oxygen dissociation curve of the blood of an aquatic and a terrestrial turtle. *Anat. Rec.* 113:23.
5. Gage, S. H. and S. P. Gage. 1886. Aquatic respiration in soft shelled turtles. *Amer. Nat.* 20:233.
6. McCutcheon, F. H. 1943. The respiratory mechanism of turtles. *Physiol. Zool.* 16:255-269.
7. Musacchia, X. J. 1959. The viability of *Chrysemys picta* submerged at various temperatures. *Physiol. Zool.* 32:47-50.
8. Prosser, C. Ladd. 1950. Comparative animal physiology. W. B. Saunders Co., Philadelphia, 888 p.
9. Root, R. W. 1949. Aquatic respiration in the musk turtle. *Physiol. Zool.* 22:172-178.
10. Shaw, R. J. and F. M. Baldwin. 1935. The mechanics of respiration in turtles. *Copeia* 1:2-15.

## Effect of Irradiation On Nissl Granules In Rat Spinal Cord Neurons—A Pilot Study<sup>1</sup>

S. D. MIROYIANNIS, B. A. RAINES, V. JURCZENKO<sup>2</sup>

*Abstract.* Literature concerning the structure and function of Nissl granules and the effect of irradiation on the central nervous system is reviewed. Four groups of rats were irradiated in the lower thoracic spinal region, using doses of 600 r, 900 r, 1200 r, and 4200 r respectively. Higher doses of the irradiation caused depletion of the Nissl granules and other effects on the nerve cells. Increasing chromatolysis was found with increasing doses of irradiation. These findings warrant further study.

The existence of Nissl granules in nerve cells was first reported in 1894 (1). Since then they have been the subject of much controversy. At first the dispute concerned the very existence of these granules. Authors disagreed on whether Nissl granules were an actual part of the nerve cell cytoplasm (2,3,4) or whether they were just artifacts produced by preparation of the tissue for study (5,6,7,8). However, modern technics of freezing-drying (3), phase contrast (9), and electron microscopy (10,11,12,13) have demonstrated their presence, and the majority of present-

<sup>1</sup> This study was supported by grants from the American Osteopathic Association and the National Institutes of Health.

<sup>2</sup> Department of Anatomy, College of Osteopathic Medicine and Surgery, Des Moines, Iowa.

day cytologists ascribe to the actual existence of Nissl granules as an integral part of the nerve cell (3,4,9,10,11,12,13). Palay and Palade (12) and others (3) have demonstrated by electron microscopy that these cytoplasmic clumps consist of endoplasmic reticulum and are actually tubular structures containing cisternae and vesicles between which are scattered minute granules 10-30 micra in diameter.

Investigation of Nissl granules today centers around determining their chemical composition (3,14,15,16,17,18) and function (16,19,20,21,22,23,24,25,26,27). Deitch and Moses (17) using ultraviolet absorption technics have found that Nissl granules contain ribonucleo-proteins. Other investigations (18) lend support to this finding. Nicholson (19) feels that Nissl granules aid in nerve conduction by the release of iron which acts as a catalytic agent in increasing the metabolic activity of the cell at the passing of an impulse. It is known that during times of stress on the nerve cell the Nissl granules tend to disappear (20). This process is called chromatolysis. Many stressor agents are capable of producing chromatolysis (20,21,24), for example, severing of the axon near the cell body, the administration of certain anesthetics, prolonged activity of the cell, and such diseases as poliomyelitis. It has, therefore, been postulated that these granules are concerned with active protein metabolism (15,22,23,24) and may function as a replenisher for the nerve cell cytoplasm and axoplasm that has been depleted in the metabolism of the nerve cell (16,25,26). This theory, however, is not unanimously accepted (28). It has been shown that these granules are not present around the axon hillock (15), and it is postulated that they disappear from this area rapidly because they are constantly releasing their contents here into the axon (15,27) to replenish the cytoplasm being metabolized during the passage of impulses.

Since irradiation is known to affect the molecular structure of cellular components (29), and especially the larger molecules (30), the ribonucleoprotein present in Nissl granules should also be affected and thereby result in visible chromatolysis. This study was instituted to test this hypothesis.

Many investigations have been carried out on the effects of irradiation on the peripheral nerves and the central nervous system. However, most of this work is concerned with the clinical and not the histological effects of irradiation. Those histological investigations which have been done have produced numerous conflicting results as to what the actual histological picture is following irradiation. Generally, reports on the irradiation of the central nervous system have centered around its effects on the vascular system supplying this area

(30,31,32,33,34,35,36,37,38,39,40,41,42,43,44). Some of the vascular effects which have been noted are vasculitis and other inflammatory changes focal hemorrhages, and obstruction and "ischemic" changes. There is little agreement as to whether irradiation can directly affect nerve cells, some authors (31,36,41, 42,43,44) claiming the changes seen in the nerve cells are totally due to the secondary effects of the vascular changes, while others (35,39,45,46,47) attribute the nerve cell changes to the direct effects of the irradiation. Some of the effects which have been noted on nerve cells proper are degeneration and necrosis of neurons (30,32,36,42,48,49), "irreversible morphological damage" (50), pyknosis (31,32,33,36,43,51), edema (32), and eccentric nuclei (52). Many investigators (39,45,47,50,53) do not even mention the effect that the irradiation had on the Nissl granules. Others show wide variance of opinion. Haymaker et al. (31) and others (38,52) have reported the continued existence of Nissl granules after doses of irradiation as high as 16,000 r. Many others have reported the converse, stating that chromatolysis occurs occasionally (31,43,44,51,54) or frequently (30,32,43,46,49, 52) after the administration of 3,000 to 30,000 r of irradiation. None of these investigators has reported consistent changes occurring in the Nissl granules. No work has been done specifically investigating the effects of irradiation on Nissl granules. This is then the proposed object of the present study.

Previous results on the effects of irradiation have varied with the duration (36,37), rate (36,37), and dosage (32,35,37,42,43,46) of irradiation given. However, the type of irradiation does not seem to appreciably affect the qualitative histological results (37).

Two divergent opinions also exist on whether the nervous system is relatively resistant (32,34,44) or susceptible (45,47,53) to irradiation. Present-day investigators seem to feel that it is more radiosensitive than was previously believed.

#### MATERIALS AND METHODS

Since there is so much disagreement over whether the Nissl granules are influenced by irradiation it was decided to do a pilot study first (the present paper) and, if consistent results were obtained, to run a larger scale investigation later which could be subjected to statistical analysis.

The animals used in this study were albino male rats (no specific strain) weighing 140 to 160 grams. They were divided into five groups of five rats each: Controls, R-1, R-2, R-3, R-4.

The source of the irradiation was a therapy-radiography unit employing a 1.0 mm aluminum filter and having a permanent

output of 30 r per minute at a focal spot to subject distance of 45 cm.

The animals were anesthetized with pentobarbital to make them more manageable during the irradiation procedure.

During the irradiation the x-ray unit was centered over the region of the 12th thoracic vertebra.

R-1 received 600 r in one dose,

R-2 received 900 r in two 450 r doses,

R-3 received 1200 r in two 600 r doses, and

R-4 received irradiation in 600 r doses until there was clinical evidence of toxicity (diarrhea, decreased activity, and coarse, dry hair). The average dose received was seven 600 r doses (4200 r) in three days.

The animals were sacrificed 24 hours following the completion of their irradiation. The entire procedure from sacrifice, to removal of the spinal cord, to fixing of the cord substance took approximately 10 minutes. The spinal chords were excised and the gray matter of the anterior horns near the 12th thoracic vertebral area was removed. Both paraffin-block sectioning and smear technics for preparing the spinal cord material were evaluated (as were various fixing and staining solutions). It was found that the smear technic gave as satisfactory results as the sectioning technic, and so this method was adopted for preparing the slide material for the investigation. The fresh gray matter was carefully smeared on the slide and then fixed in 95% alcohol. The slides were allowed to remain in 95% alcohol over night and then were stained with cresyl violet.

Control animals were subjected to all the above procedures except the actual irradiation.

#### RESULTS AND DISCUSSION

In the control group, the Nissl granules, stained very well and were found to be numerous and evenly distributed throughout the cytoplasm. The nucleus was centrally placed and contained a prominent nucleolus (Figures 1 and 2).

The R-1 group showed little or no change from the controls (Figures 3 and 4).

The R-2 group had inconstant changes; some cells showed a slight decrease in the number of Nissl granules, others appeared normal. The nucleoli seemed to be less prominent (Figures 5 and 6).

The R-3 group began to show moderate chromatolysis, pyknosis, and slight vacuolation of the cytoplasm. The Nissl granule pattern appeared much finer in consistency than in the control

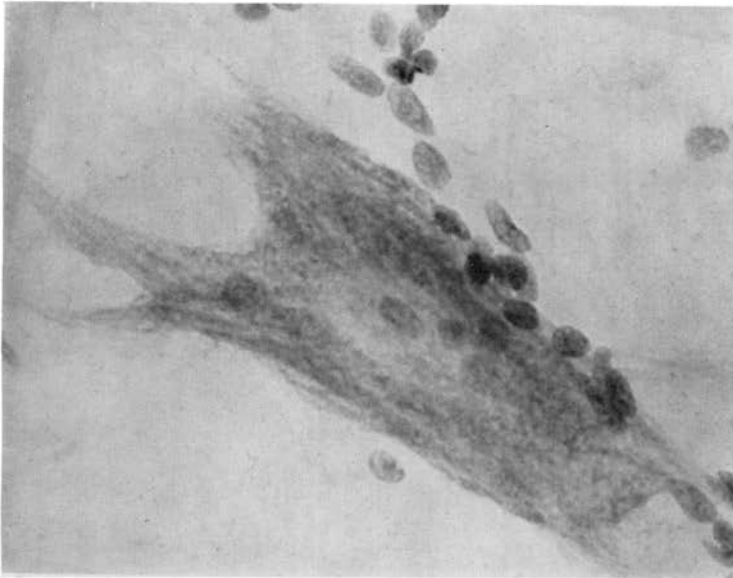


Figure 1. Appearance of the Nissl granules in the control animals.

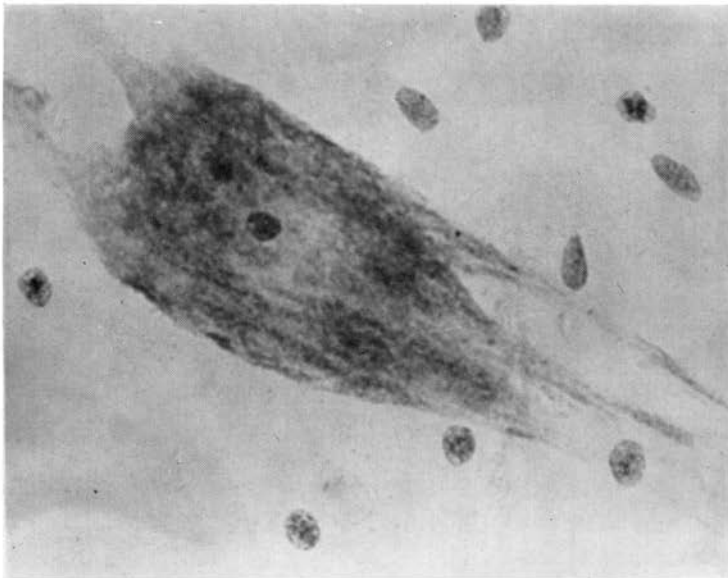


Figure 2. Appearance of the Nissl granules in the control animals.

group. There was an increase in the size of the clear zone around the periphery of the cell (Figures 7 and 8).

The R-4 group showed progression of the changes noted above.

There was extensive chromatolysis, pyknosis, eccentricity of the

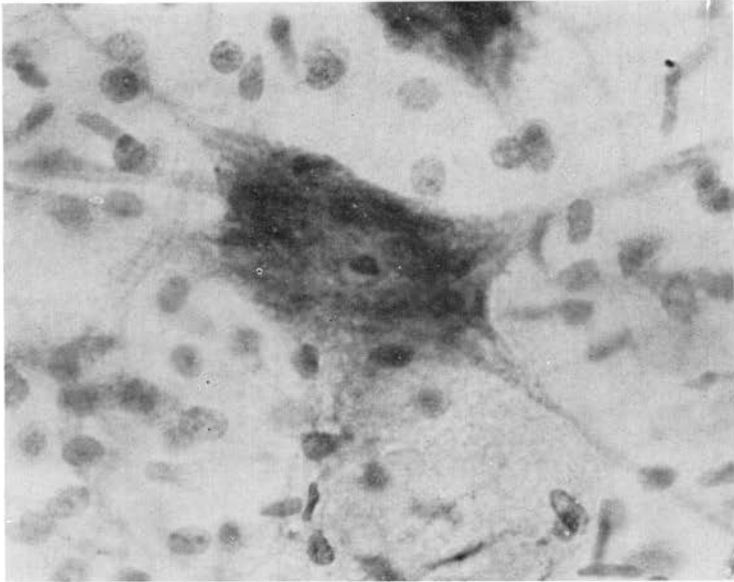


Figure 3. R-1 group cell (600 r).

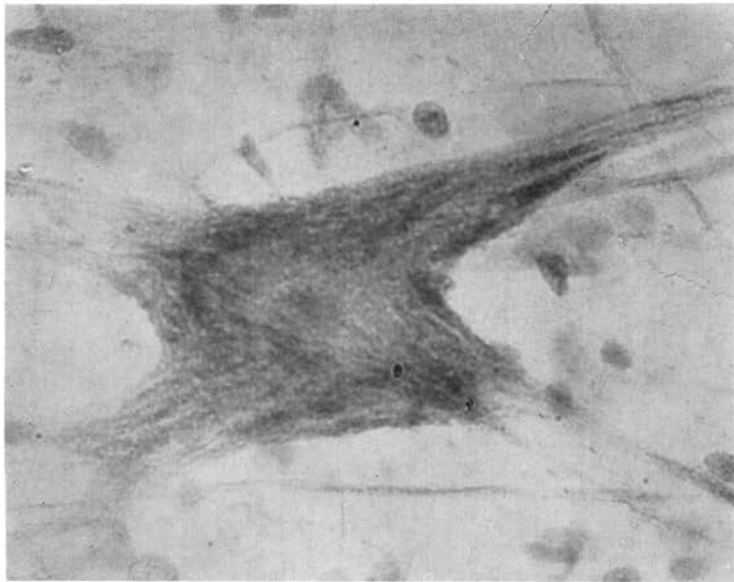


Figure 4. R-1 group cell (600 r).

few remaining nuclei, absence of nucleoli, and extensive marginal vacuolation. Large degenerative areas appeared in the cytoplasm. The Nissl granules were greatly depleted or were very fine when present (Figures 9,10,11, and 12).

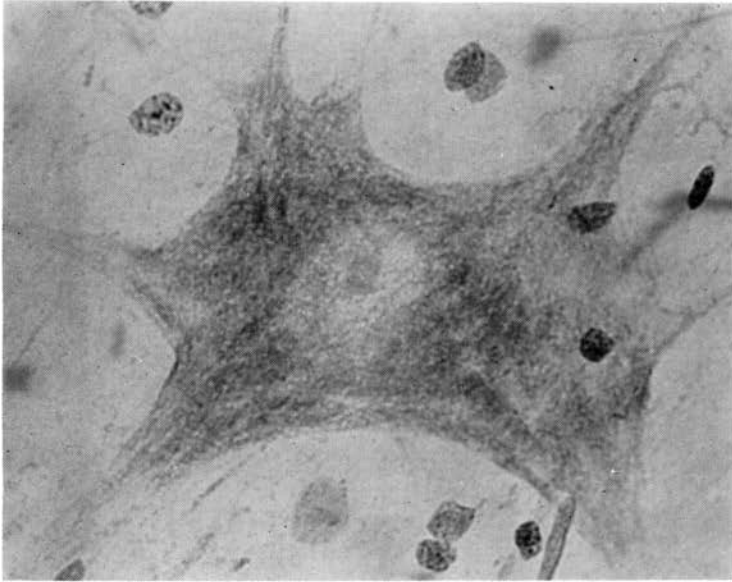


Figure 5. R-2 group cell (900 r).

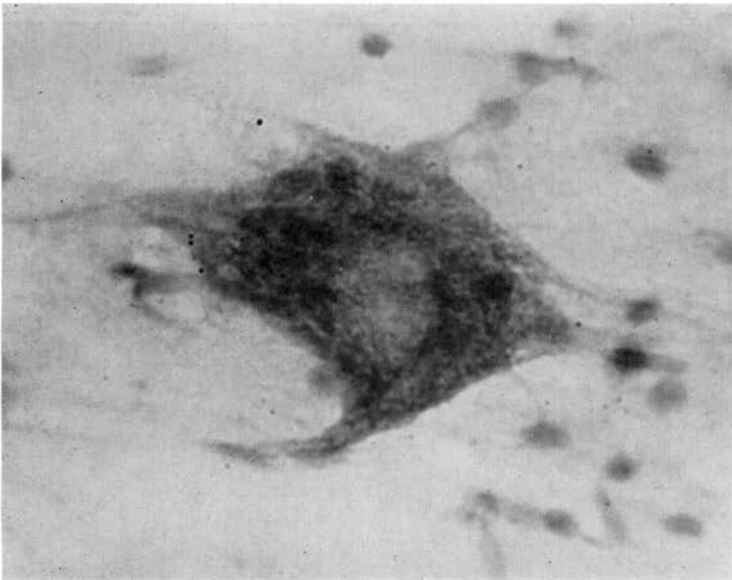


Figure 6. R-2 group cell (900 r).

There was obvious progression in the destruction of the Nissl granules as the dosage of irradiation was increased, and it appeared to be one of the first components of the cell to be affected by the irradiation. The clinical symptoms observed in the ani-



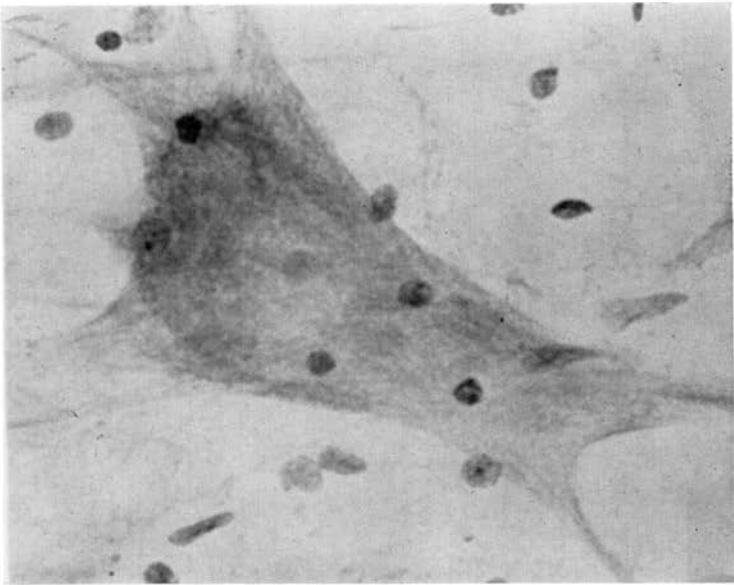


Figure 7. R-3 group cell (1200 r).

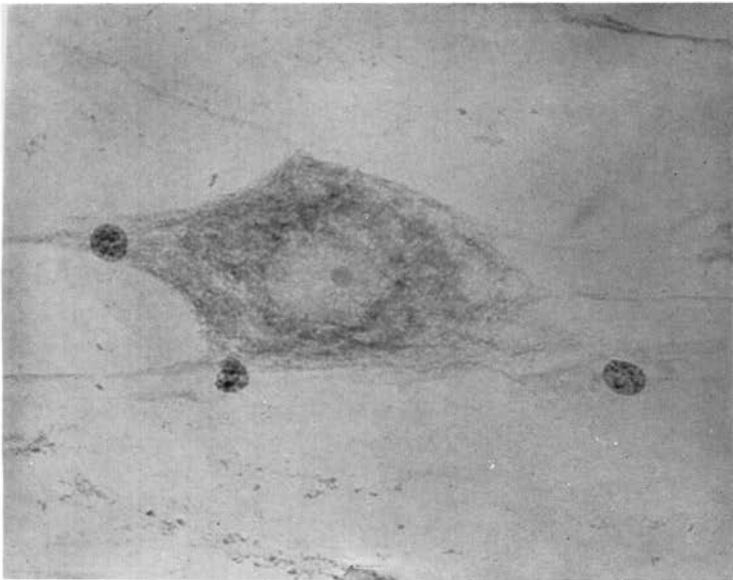


Figure 8. R-3 group cell (1200 r).

imals seemed to parallel the changes in the nerve cells. The animals receiving the higher doses of irradiation became apathetic, somnolent, and even prostrate with the heaviest doses.

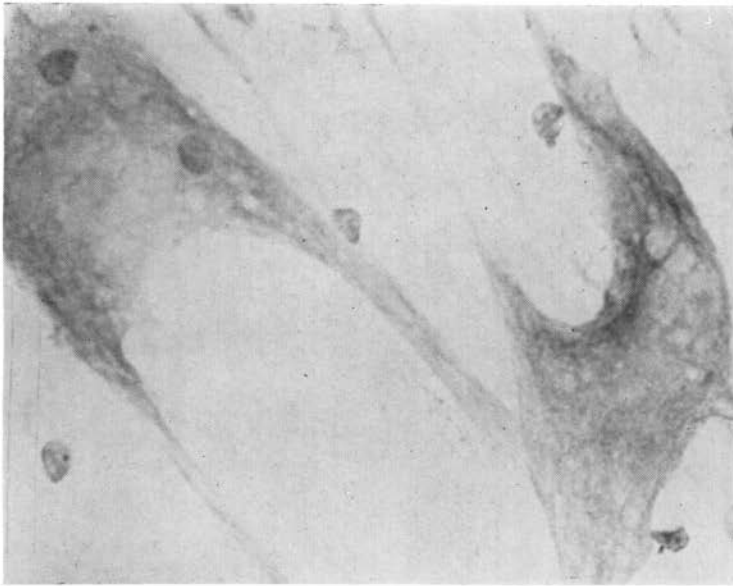


Figure 9. R-4 group cells (4200 r).

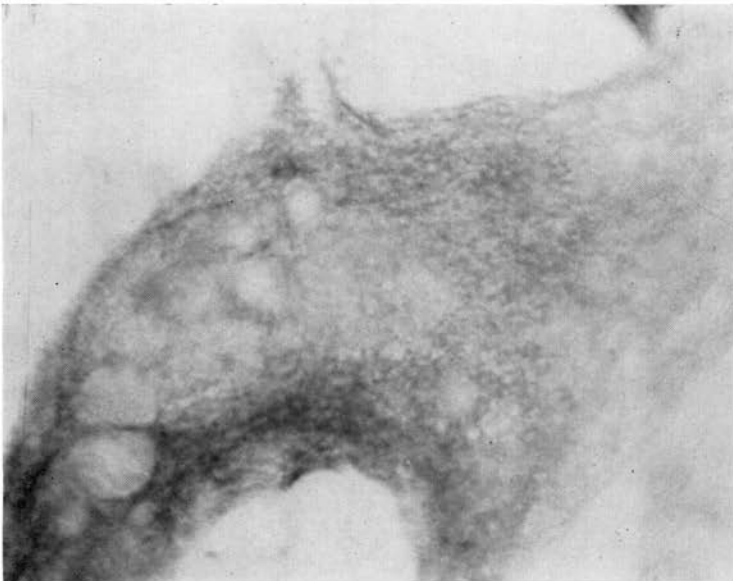


Figure 10. R-4 group cell (4200 r).

#### SUMMARY AND CONCLUSIONS

A pilot study to determine the effects of irradiation on the Nissl granules of the anterior horn cells of the rat spinal cord was performed. One control and four test groups of animals

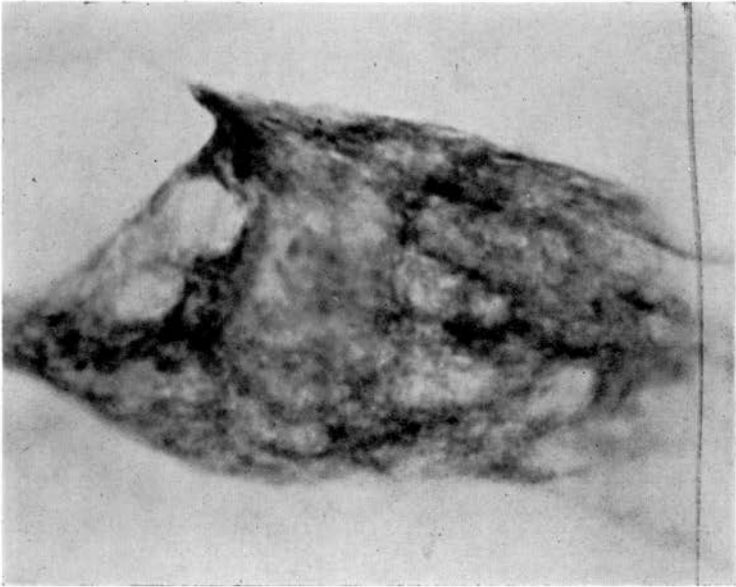


Figure 11. R-4 group cell (4200 r.)

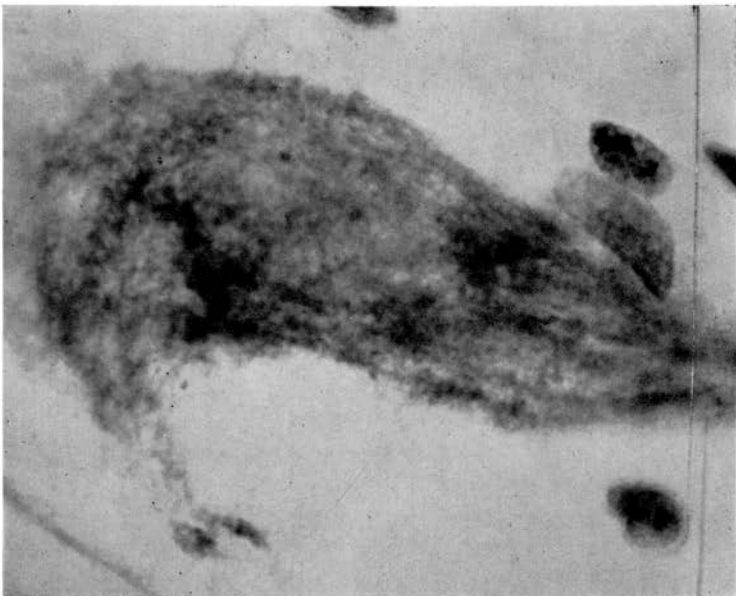

Figure 12. R-4 group cell (4200 r).

were used, the test groups being given 600 r, 900 r, 1200 r, and 4200 r respectively. Histological evaluation of the irradiation effects showed increasing chromatolysis and other changes with increasing doses of irradiation. It may be concluded that in this

pilôt study increasing doses of irradiation appeared to have an increasing effect on the Nissl granules of the anterior horn cells. It is felt that these findings warrant further study of the problem with a greater number of animals in order to make these findings and conclusions statistically valid.

#### Literature Cited

1. Nissl, F. 1894. Ueber die sogenannten Cranula der Nervenzellen. *Neurol. Zentr.* 13:676-685.
2. Mühlmann, M. 1929. Ueber die Natur der Tigroidsubstanz der Nervenzellen. *Z. Zellf. mikr. Anat.* 9:297-317.
3. Bensley, R. R. and Gersh, I. 1933. Studies on cell structure by the freezing-drying method. III. The distribution in cells of the basophil substances in particular the Nissl substance of the nerve cell. *Anat. Rec.* 57:369-385.
4. LaVelle, A. 1956. Nucleolar and Nissl substance development in nerve cells. *J. Comp. Neurol.* 104:175-205.
5. Held, H. 1895. Beiträge zur Structur der Nervenzellen und ihrer Fortsätze. Erste Abhandlung. *Arch. Anat.* p. 396-416.
6. Ibid. 1897. Beiträge zur Structur der Nervenzellen und ihrer Fortsätze. Zweite Abhandlung. *Arch. Anat.* p. 204-294.
7. Hopkins, A. E. 1924. The appearance of Nissl substances in nerve cells following variations in fixation. *Anat. Rec.* 28:157-163.
8. Sheinin, J. J. 1932. On changes in the size, shape, and distribution of the basophil substance in the neurocytosome after fixation in different fluids. *Anat. Rec.* 52:83-93.
9. Deitch, A. D. and Murray, M. R. 1956. The Nissl substance of living and fixed spinal ganglion cells. I. A phase contrast study. *J. Biophys. Biochem. Cytol.* 2:433-444.
10. Beams, H. W. et al. 1952. A correlated study on spinal ganglion cells and associated nerve fibers with the light and electron microscopes. *J. Comp. Neurol.* 96:249-281.
11. Chu, L.-W. 1954. A cytological study of anterior horn cells isolated from human spinal cord. *J. Comp. Neurol.* 100:381-413.
12. Palay, S. L. and Palade, G. E. 1955. The fine structure of neurons. *J. Biophys. Biochem. Cytol.* 1:69-88.
13. Haguenau, F. and Bernhard, W. 1953. Aspect de la substance de Nissl au microscope Electronique. *Exp. Cell Res.* 4:496-498.
14. Caspersson. 1950. Cell growth and cell function W. W. Norton and Co. New York.
15. Gersh, I. and Bodian, D. 1943. Some chemical mechanisms in chromatolysis. *J. Cell Comp. Physiol.* 21:253-279.
16. Bodian, D. 1947. Nucleic acid in nerve-cell regeneration. *Symp. Soc. Exp. Biol.* 1:163-178.
17. Deitch, A. D. and Moses, M. J. 1957. The Nissl substance of living and fixed spinal ganglion cells. II. An ultraviolet absorption study. *J. Biochem. Cytol.* 3:449-556.
18. Herwerden, M. Av. 1913. Über die Nucleasewirkung auf tiersche Zellen. Ein Beitrag zur Chromidien-frage. *Arch. Zellforsch.* 10:431-449.
19. Nicholson, F. M. 1923. The changes in amount and distribution of the iron-containing proteins of nerve cells following injury to their axones. *J. Comp. Neurol.* 36:37-77.
20. Mangione, F. 1954. Modificanzioni strutturali citochimiche nelle cellule motrici spinali di animali affaticati. *Arch. ital. Anat. Embriol.* 58:410-437.
21. Hydén, H. 1950. Spectroscopic studies on nerve cells in development, growth, and function, p. 176-193. In *Genetic neurol*, ed. by Paul Weiss. Univ. Chicago Press, Chicago.
22. ——— 1943. Protein and nucleotide metabolism in the nerve cell under different functional conditions. *Symp. Soc. Exp. Biol.* 1:152-162.
23. LaVelle, A. O. et al. 1954. Acid phosphatase activity as related to nucleic acid sites in the nerve cell. *Anat. Rec.* 119:305-323.

24. Hydén, H. 1943. Protein metabolism in the nerve cell during growth and function. *Acta Physiol. Scand.* 17 (Suppl. 6) :1-136.
25. Bodian, D. and Mellors, R. C. 1945. The regenerative cycle of motoneurons, with specific reference to phosphatase activity. *J. Exp. Med.* 81:469-487.
26. Cavanaugh, M. W. 1951. Quantitative effects of the peripheral innervation area on nerves and spinal ganglion cells. *J. Comp. Neurol.* 94:181-219.
27. Nicholson, F. M. 1924. Morphologic changes in nerve cells following injury to their axons. *Arch. Neurol. Psychiat.* 11:680-697.
28. Claude. 1950. Studies on cell morphology and functions. *Ann. N. Y. Acad. Sci.* 50:854-860.
29. Reynolds, L. 1946. Newer investigations of radiation effects and their clinical applications. *Am. J. Roentgenol.* 55:135-152.
30. Clemente, C. D. and Holst, E. A. 1954. Pathological changes in neurons, neuroglia, and blood brain barrier induced by x-irradiation of heads of monkeys. *Arch. Neurol. Psychiat.* 71:66-68.
31. Haymaker, W. et al. 1958. The effect of Ba-140-La-140 gamma radiation on the central nervous system and pituitary glands of macaque monkeys: a study of 67 brains and spinal cords and 77 pituitary glands. *J. Neuropath.* 17:12-57.
32. Lindenberg, R. 1956. Morphotrophic and morphostatic necrobiosis. Investigations on nerve cells of the brain. *Am. J. Path.* 32:1149-1177.
33. Vogel, F. S. et al. 1958. The induction of acute morphological changes in the central nervous system and pituitary body of macaque monkeys by Co-60 gamma radiation. *J. Neuropath.* 17:138-150.
34. Rudis-Jicinsky, J. 1902. Experimental investigations with roentgen rays upon living tissue. *N. Y. Med. J.* 76:850-853.
35. Ellinger, F. 1942. Direct and or indirect action or roentgen rays on the brain. *Am. J. Roentgenol.* 47:775-776.
36. Hicks, S. P. et al. 1956. Time-intensity factors in radiation response. I. The acute effects of megavolt electrons and high-and low-energy x-rays with special reference to the brain. *Arch. Pathol.* 61:226-238.
37. McLaurin, R. L. 1955. The effects of gamma and roentgen radiation on the intact spinal cord of the monkey. *Am. J. Roentgenol.* 73:827-835.
38. Lyman, R. S. et al. 1933. Effect of roentgen rays on the central nervous system; results of large doses on brains of adult dogs. *Arch. Neurol. Psychiat.* 29:56-87.
39. O'Connell J. E. A. and Brunschwig, A. 1937. Observations on the roentgen treatment of intracranial gliomata. *Brain* 60:230-258.
40. Marburg, O. et al. 1945. Changes after treatment of an unprotected brain with large doses of roentgen radiation. *Am. J. Roentgenol.* 53:171-178.
41. Dugger, G. S. et al. 1954. Necrosis of the brain following roentgen irradiation. *Am. J. Roentgenol.* 72:953-960.
42. Russell, D. S. et al. 1949. Experimental radionecrosis of the brain in rabbits. *J. Neurol. Neurosurg. Psychiat.* 12:187-195.
43. Alpers, B. J. and Pancast, H. K. 1933. The effect of irradiation on normal and neoplastic brain tissue. *Am. J. Cancer* 17:7-24.
44. Bagg, H. J. 1921. The effects of radium emanation on the adult mammalian brain. *Am. J. Roentgenol.* 8:536-547.
45. Arnold, A. et al. 1954. Changes in the central nervous system following irradiation with 23-mev x-rays from the betatron. *Radiol.* 62:37-44.
46. Davidoff, L. M. et al. 1938. The effect of radiation applied directly to the brain and spinal cord. *Radiol.* 31:451-463.
47. Stahl, W. R. 1959. A review of Soviet research on the central nervous system effects of ionizing radiations. *J. Nerv. Ment. Dis.* 129:511-529.
48. Hicks, S. P. and Montgomery, P. O'B. 1952. The effects of acute radiation on the adult mammalian central nervous system. *Proc. Soc. Exper. Biol. and Med.* 80:15-18.
49. Horsley, V. and Finzi, N. S. 1911. The action of filtered radium rays when applied directly to the brain. *Brit. Med. J.* 2:898-900.

50. Rugh, R. 1958. Responses of the developing fetal nervous system to roentgen irradiation. *Radiol.* 71:729-731.
51. Shiraki, H. et al. 1958. Effects of atomic radiation on the brain in man. *J. Neuropath. Exp. Neurol.* 17:79-137.
52. Wachowski, T. J. and Chenault, H. 1945. Degenerative effects of large doses of roentgen rays on the human brain. *Radiol.* 45:227-246.
53. Arnold, M. C. et al. 1961. The effect of radiation on the mammalian nerves. *Radiol.* 77:264-268.
54. Scholz, W. and Hsü, Y. K. 1938. Late damage from roentgen irradiation of the human brain. *Arch. Neurol, Psychiat.* 40:928-936.

## The Effects of 600 Roentgens of X-Irradiation on the Nuclei of Mouse Liver Cells<sup>1</sup>

LAVERNE BOLDHAUPT<sup>2</sup>

*Abstract.* Four methods were employed to detect a change in the parenchymal nuclei of liver cells in 8 week old female A-Jax mice after receiving 600 roentgens of localized X-irradiation. These methods were: (1) determination of the percentage of parenchymal cell volume made up of nuclear material by means of the Chalkley point = ratio method, (2) estimation of the actual nuclear volume by means of camera lucida drawings, (3) estimation of the number of nuclei per cc of tissue, and (4) estimation of the ploidy distribution of the nuclei as inferred from nuclear volumes. Irradiated and non-irradiated mice were sacrificed immediately, in 6 hours, 12 hours, 18 hours, 24 hours, 48 hours, and 72 hours following X-irradiation. No significant difference was noted between the irradiated and between the non-irradiated nuclei from one time of sacrifice to the next. When the data from all times of sacrifice were combined, no significant change attributable to radiation damage was noted in the nuclei.

Early in the history of the application of ionizing radiations to research it was recognized that radiations demonstrated a selective action toward different areas of the body. The liver has been regarded as a tissue highly resistant to the action of roentgen rays. Rhoades (1948) found that with few exceptions the liver was not affected by irradiation. However, Wilson and Stowell (1953) noted that the nuclei of mouse liver parenchymal cells increased in size following irradiation with 12,000 roentgens. It was also noted by Torapova (1957) that the nuclei, observed in mouse liver homogenates, increased in size and decreased in number following X-irradiation.

Generally, actively dividing cells are more radiosensitive than non-dividing cells. Radiation injury can be achieved in cells not actively dividing. Moderate X-irradiation may injure cells through a mechanism other than through aberration in cellular

<sup>1</sup> Part of a thesis submitted in partial fulfillment of the requirements for a Master of Arts degree in the Department of Biology of Drake University, Des Moines, Iowa, 1960.

<sup>2</sup> Department of Biology, Wisconsin State College, LaCrosse, Wisconsin.