

Single-center experience in the management of spontaneous isolated abdominal aortic dissection

Dittmar Böckler¹ · Claudio Bianchini Massoni² · Philipp Geisbüsch¹ · Maani Hakimi¹ · Hendrik von Tengg-Kobligk³ · Alexander Hyhlik-Dürr¹

Abstract

Objective This study aims to report the management of patients with spontaneous isolated dissection of the abdominal aorta (sIAAD).

Methods A cohort of 18 consecutive patients (12 male, mean age 58 years) with sIAAD was treated between 1990 and 2009. Dissection was asymptomatic in ten and symptomatic in eight patients. Retrospective data analysis from patient charts was performed. Follow-up included clinical examination, ultrasound, and/or CT-angiography. Mean follow-up was 54 months (range 1–211).

Results In total, eight out of 18 received invasive treatment. All asymptomatic patients initially underwent conservative treatment and surveillance. Spontaneous false lumen thrombosis occurred in four (40 %), and three patients showed relevant aneurysmatic progression and underwent elective invasive treatment (open $n=2$, endovascular $n=1$), representing a crossover rate of 30 %. Late mortality was 20 % ($n=2$) in this group. In symptomatic patients, five underwent urgent treatment due to persistent abdominal or back pain ($n=4$) or contained rupture ($n=1$); one was treated for claudication. The remaining two patients presented with irreversible spinal cord ischemia and were treated conservatively. Three patients

were treated by open surgery and three by endovascular interventions (two stentgrafts, one Palmaz XXL stent). Early and late morbidity and mortality was 0 % in this group. There were no reinterventions.

Conclusion The majority of patients with sIAAD require invasive treatment, with EVAR being the preferable treatment option today. In asymptomatic IAAD, primary surveillance is justifiable, but close surveillance due to expansion is necessary.

Keywords Aorta · Dissection · Endovascular · Aneurysm · Stentgraft · Surveillance

Aortic dissection commonly affects the ascending and descending aorta and is associated with significant morbidity and mortality [1]. In contrast, spontaneous isolated dissection of the abdominal aorta (sIAAD) is a rare finding with an incidence of 1.1–4 % [2, 3]. It was first described by Shekelton in 1822 [4]. Due to its low incidence, literature findings are limited to case reports and small patient series [5–7]. The natural history of sIAAD is unknown, and treatment strategies remain poorly defined and non-standardized. A meta-analysis, published by Jonker et al. [3], added more information and provided a better understanding of sIAAD. Two single-center series published their mid- and long-term results on endovascular treatment of IAAD to be feasible with no mortality and low rate of reinterventions [8, 9]. Supplementarily, we present our single-center experience of 18 consecutive patients with long-term follow-up results for this rare aortic pathology.

Materials and methods

Patients Records of 18 consecutive patients (12 male, 6 female, median age 63 years, range 26–7) with sIAAD, treated

✉ Dittmar Böckler
dittmar.boeckler@med.uni-heidelberg.de

¹ Department of Vascular and Endovascular Surgery, Ruprecht Karls-University Heidelberg, Im Neuenheimer Feld 110, 69120 Heidelberg, Germany

² Unit of Vascular Surgery, Department of Experimental, Diagnostic and Speciality Medicine, University of Bologna, Policlinico Sant'Orsola-Malpighi, Bologna, Italy

³ Department of Diagnostic, Interventional and Pediatric Radiology University Hospital of Bern, Bern, Switzerland

between January 1990 and May 2009, were reviewed. Data were obtained retrospectively from patient charts. Only patients with spontaneous isolated abdominal aortic dissection, defined as a tear in the aorta creating a false channel, were included in this study. Patients with concomitant thoracic dissection (type B or residual type A) and iatrogenic abdominal dissection such as from previous catheterization were excluded from the study.

Hypertension was the most frequent observed risk factor and noted in 12 patients (66.7 %), followed by hyperlipidemia in seven patients (38.9 %). There was no history of blunt abdominal trauma in the cohort. Two patients had radiotherapy of the prostate in their past medical history. One patient had positive family history for aortic dissection. Postoperatively, two patients showed findings for Takayasu arteritis and Ehlers-Danlos syndrome in the histological findings.

Asymptomatic sIAAD were noted in ten (56 %) (group 1) and symptomatic in eight (44 %) patients (group 2), respectively. In group 2, four symptomatic patients complained of back pain and one of mild to severe claudication. Additionally, one patient had intermittent paraparesis; another patient had paraplegia of the lower extremity due to spinal cord ischemia. No critical visceral or leg malperfusion were detected. Patient presentation and demographics are summarized in Table 1.

Diagnostics Initial imaging studies consisted of computed tomography (CT) scans or magnetic resonance imaging (MRI) scans of the abdomen and thorax. Original films were reviewed when available. Localization and extension of sIAAD and maximum aortic diameter were documented. Non-dissected aorta was defined by the absence of a dissection flap beginning below the celiac trunk or by visualization of a false and true lumen.

Aortic anatomy sIAAD was localized below the renal arteries in 13 patients (72.2 %) and in juxta- or suprarenal position in five patients (27.8 %). The sIAAD extended in six patients (33.3 %) into the iliofemoral axis. Moreover, CT or MRI scan revealed an abdominal aortic aneurysm (AAA) in seven patients (38.9 %), a penetrating aortic ulcer (PAU) in two patients (11.1 %), and an intramural hematoma (IMH) in one patient (5.6 %) (Fig. 1).

Definitions Significant expansion of the aorta was defined as transverse aortic diameter increase >5 mm within 6 months in CT or MRI scan.

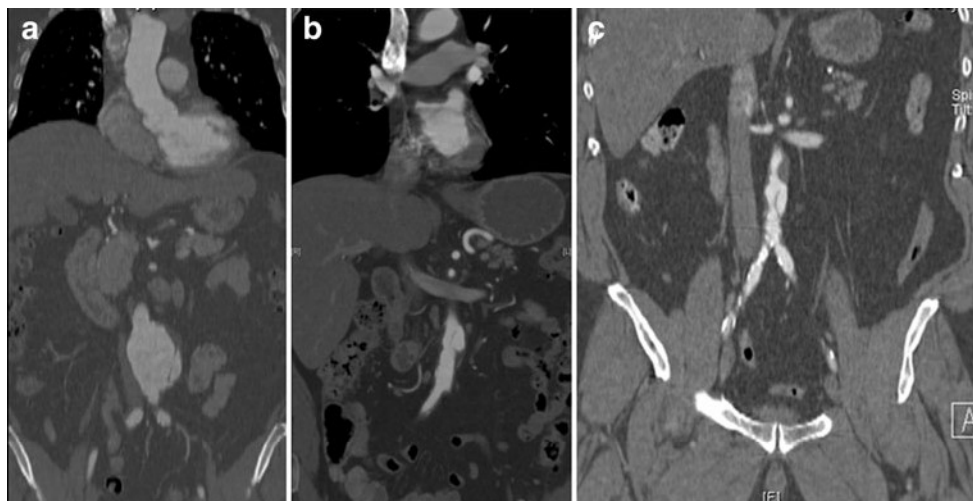
Procedures Conservative treatment including surveillance and best medical treatment (BMT) was offered to asymptomatic patients with a diameter less than 50 mm. Endovascular aortic repair (EVAR) was selected as the treatment of choice

Table 1 Patient demographics with follow-up period and clinical outcome

Pat. No	Year of treatment	Sex/age	Diagnosis	Clinical presentation indication	Treatment	Follow-up (months)	Outcome at latest FU
1	2004	M / 71	IAAD + PAU + RAS	Symptomatic, back pain	EVAR (AUI)	40	Alive
2	2005	M / 67	IAAD + PAU	Symptomatic, claudication	Palmaz XXL Stent	15	Alive
3	2006	M / 76	IAAD	Asymptomatic (no expansion)	conservative	12	Alive
4	2005	M / 58	IAAD + AAA	Asymptomatic (expansion 55 mm)	OR (tube graft)	31	Alive
5	2004	W / 67	IAAD	Asymptomatic, (no expansion)	Conservative	18	Dead
6	1997	M / 54	IAAD + AAA	Asymptomatic (expansion 40 mm)	OR (aorto-biiliacal graft)	94	Alive
7	1999	W / 56	IAAD + AAA	Symptomatic, back pain	OR (aorto-biiliacal graft)	100	Alive
8	1990	M / 26	IA	Symptomatic back pain	OR (tube graft)	211	Alive
9	2002	W / 52	IAAD + inflammatory AAA	Symptomatic, rupture	EVAR (AUI)	67	Alive
10	2003	M / 72	IAAD + IMH	Symptomatic, SCI	Conservative	48	Alive
11	2000	M / 43	IAAD	Asymptomatic (no expansion)	Conservative	94	Alive
12	2000	W / 57	IAAD	Symptomatic, back pain	Conservative	86	Alive
13	2003	W / 63	IAAD + AAA	Asymptomatic (no expansion)	Conservative	3	Dead
14	1999	M / 65	IAAD+AAA	Asymptomatic, expansion 45 mm)	EVAR (AUI)	7	Alive
15	2007	W / 64	IAAD	Symptomatic, SCI, and paraplegia	Conservative	1	Alive
16	1984	M / 38	IAAD + AAA	Asymptomatic (no expansion)	Conservative	156	Alive
17	2004	M / 78	IAAD + AAA	Asymptomatic (no expansion)	Conservative	64	Alive
18	2009	M / 54	IAAD + iliac aneurysm	Asymptomatic (no expansion)	Conservative	2	Alive

IAAD infrarenal abdominal aortic dissection, PAU penetration aortic ulcer, NAST stenosis of A. renalis, IMH intramural hematoma, AUI aortouniliac, EVAR endovascular aortic repair, OR open repair, FU follow-up, AAA abdominal aortic aneurysm, RAS renal artery stenosis, COBP cross-over bypass)

Fig. 1 a–c Imaging shows different pathologies associated with isolated dissection of the abdominal aorta. **a** Computed tomography of an aneurysm of the abdominal aorta (coronary slice). **b** Computed tomography of an intramural hematoma (coronary slice). **c** Computed tomography of a penetrating aortic ulcer (coronary slice, virtual reconstruction)



whenever aortic anatomy and morphology were suitable. Conventional open repair (OR) was performed otherwise (Fig. 2).

Follow-up Patients were followed by routine outpatient clinic visits including an annual physical examination and CT angiogram.

Results

All ten asymptomatic patients underwent primary conservative treatment with BMT and surveillance. Significant aortic expansion was observed in three patients, out of whom all underwent elective invasive treatment (open $n=2$, endovascular $n=1$), representing a crossover rate of 30 %. Each of these patients

showed additional AAA. Four patients (22 %) showed spontaneous healing of the sIAAD with thrombosis of the false lumen. Late mortality was 20 % ($n=2$) in this group. Both patients (11.1 %) died from unknown cause 3 and 18 months after diagnosis of sIAAD, respectively.

In symptomatic patients, five underwent urgent treatment due to persistent abdominal or back pain ($n=4$) or contained rupture ($n=1$); one was treated for claudication. Three patients were treated by open surgery and three by endovascular therapy (Table 1): One more patient received emergency EVAR for contained rupture of the infrarenal aorta using a monoiliac stentgraft device (Talent® Medtronic, Santa Rosa, CA, USA) with a femoro-femoral cross-over bypass graft (10 mm Intergring® prosthesis, WL Gore & Ass., Flagstaff, AZ, USA) (Fig. 3). Two patients were treated with EVAR according to the anatomy and morphology of the aortoiliacal vessels. The

Fig. 2 3-D CT-angiography after endovascular AUI repair and crossover-bypass

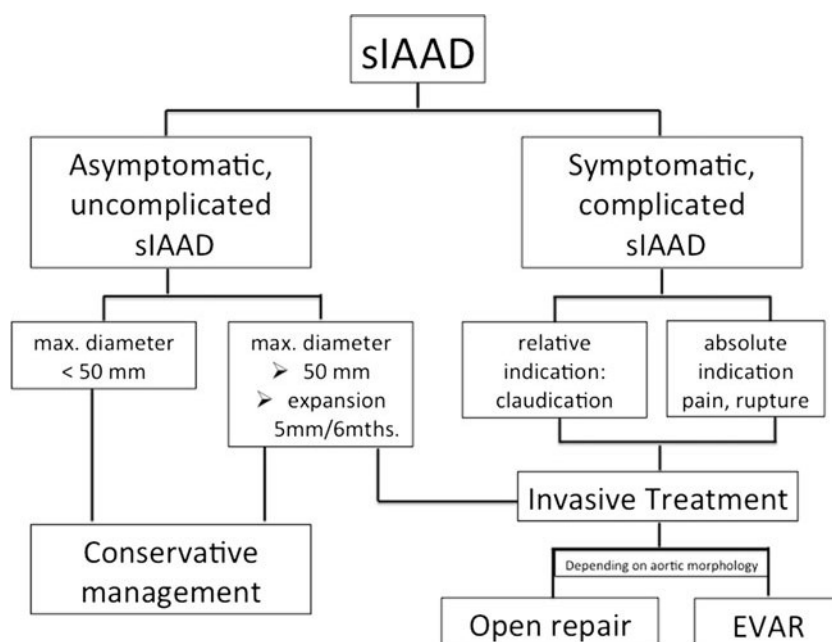

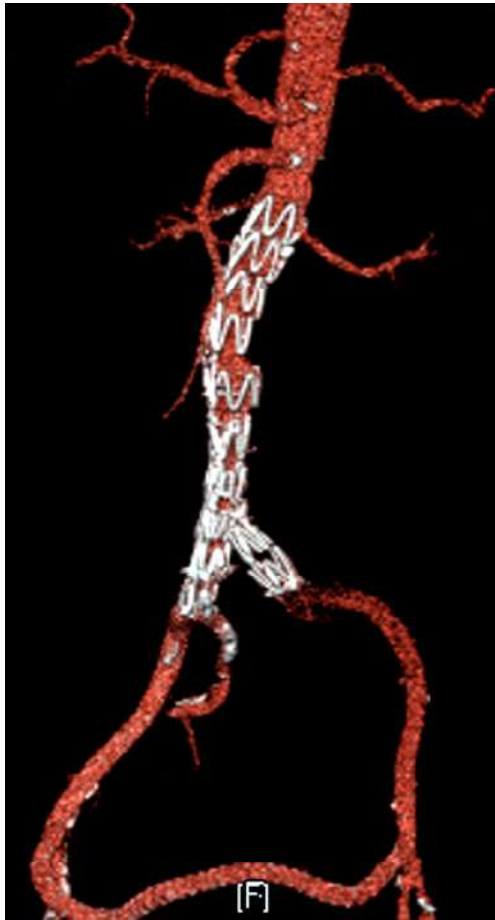


Fig. 3 **a** Computed tomography (virtual reconstruction) of a patient with isolated dissection of the abdominal aorta treated conservatively. **b** Healed spontaneously with best medical treatment

other patient (5.6 %) was treated with a bifurcated stentgraft device (Excluder, WL Gore & Ass., Flagstaff, AZ, USA). Following EVAR, no endoleaks, material failure, or migration of the stentgraft was observed during follow-up. One patient with claudication received a Palmaz stent XXL (14/40 mm, Cordis Corporation, Miami Lakes, FL, USA) in the infrarenal aorta for closure of the proximal entry and aortic remodelling (Fig. 4).

Open surgery was performed in three patients being morphologically unsuitable for endovascular exclusion due to missing landing zones and one endovascular aortic aneurysm repair. Either a tube graft ($n=2$) or aorto-biiliacal bifurcation ($n=1$) with a Dacron prosthesis (Gelsoft® Vascutek, Glasgow, Scotland) insertion was performed via transabdominal approach. All patients recovered uneventfully in their postoperative course. Two patients following open surgical repair had multiple extensive operations and interventions due to the underlying pathology (Takayasu arteritis with aorto-duodenal fistula and Ehlers–Danlos syndrome with thoracic expansion).

The remaining two patients of group 2 presented with irreversible spinal cord ischemia were treated conservatively.

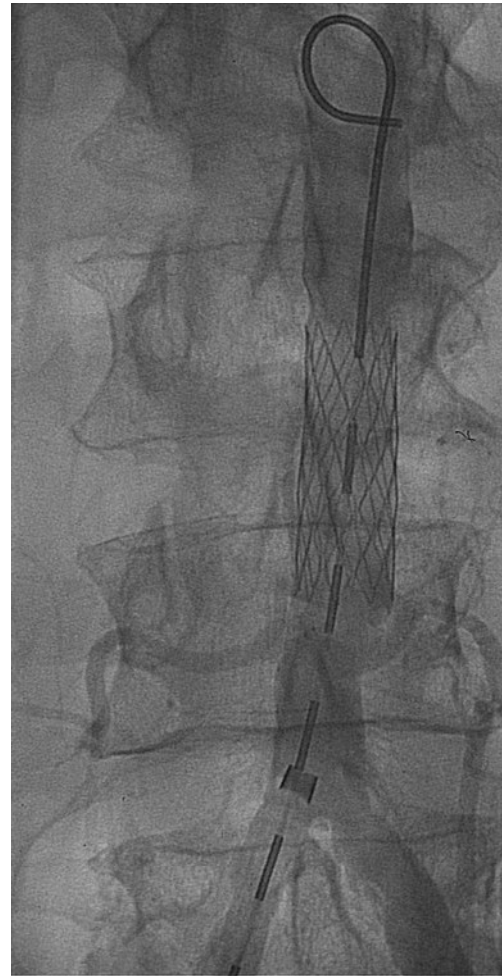

Fig. 4 Multimodal treatment algorithm for the management of the isolated dissection of the abdominal aorta

Early and late morbidity and mortality was 0 % in this group. There were no IAAD-associated reinterventions during follow-up.

Discussion

This consecutive series show sIAAD as a rare pathology that requires close follow-up, best medical treatment if asymptomatic, and early surgery if symptomatic.

Dissection of the aorta commonly originates in the thoracic segment. In contrast, the spontaneous isolated dissection of the abdominal aorta (sIAAD) is a rare finding and is reported to occur in 0.4 to 2 % of all dissections of the aorta [5, 6]. Graham et al. found sIAAD in 70 % spontaneous followed by traumatic and iatrogenic etiology each with 15 %, respectively [10]. The true prevalence of this condition is unknown since almost half of the patients present without any symptoms. sIAAD most frequently diagnosed with CT or MRI is commonly associated with degenerative abdominal aortic

pathology such as aortic aneurysm, PAU, and IMH. Mostly, sIAAD is in the infrarenal aorta located with various affection of the iliac–femoral axis. Management of sIAAD still remains under controversial discussion. An overview of the literature of the last 50 years mainly provides case reports and lacks a treatment algorithm for this unusual vascular disease.

The patient cohort median age at diagnosis of 64 years is similar to that reported in the series of Farber et al. and Graham et al. [7, 10]. The majority of sIAAD was idiopathic. Hypertension was the most frequent vascular risk factor in sIAAD, followed by elevated blood lipids. Remarkably, two patients had a past history of radiation to paraaortic lymph nodes in their past medical history. One patient suffered from Ehlers–Danlos syndrome. Almost half of the patients were asymptomatic at diagnosis, a rate which is greater than seen historically in the literature. A possible explanation might be the increasing availability and more liberal use of CT and MRI scan, which reveal an increasing number of sIAAD. The most frequent symptom was severe, sharp, and knife-like abdominal or back pain [5]. Rarely, it was followed by alarming symptoms such as paraplegia due to spinal cord ischemia. The mechanism for spinal cord ischemia in sIAAD is not yet well understood. Neurological complications such as paraplegia as presenting manifestation of aortic dissection are exceedingly rare and are only published in association with spontaneous thoracic dissection [11]. Traumatic abdominal dissection series also show a high prevalence of spinal cord ischemia, underlining the importance of sIAAD [12, 13]. Paraplegia as a result of sIAAD was only described once [12, 14]. One patient had contained rupture of the infrarenal aorta, resulting in emergency EVAR.

Besides early complications, we found late complications of sIAAD such as expansion of the aorta in up to 30 % of the cases. Remarkably, expansion during follow-up was strongly associated with the presence of an AAA at the time of diagnosis. Therefore, the presence of an AAA seems to be a potential risk factor for progression. The rates of expansion in sIAAD are not well known but seem to be comparable to thoracic aortic dissection [2]. However, sIAAD is a condition that may present differently compared with classic type B aortic dissections. The natural history of sIAAD suggests, at least in this consecutive series, that it causes more often early and late complications (up to 75 %).

The natural history of sIAAD is not well established, and risk factors for prediction of complications are not available yet [15]. Traditionally, asymptomatic dissections are managed with best medical treatment and good management of modifiable risk factors. Open surgical and endovascular repairs were performed in case of complicated sIAAD or chronic expansion. Previously, EVAR has been successfully used in sIAAD. In this series, the use of endovascular techniques in sIAAD has been successful in early- and long-term follow-up, showing no early mortality, 95 % survival rate at 5 years, high aortic remodelling rates, and cumulative free-from-

reintervention rate estimated to be 90.9 % at 58 months [8, 9, 16]. The use of a non-coated stent in the aorta for closure of the entry in acute sIAAD must be critically discussed, even when a good result with complete thrombosis and shrinkage of the false lumen can be obtained. Treatment risk in sIAAD seems to be less than that of descending thoracic aortic dissection [11, 17, 18].

Clear limitations of this study are the retrospective design, the small sample size during and the inclusion of five to six patients in a long study period of 19 years (1990–2009), in which strategies and developments changed and evolved.

Nevertheless, the present series represents one of the larger consecutive single-center series. The following treatment algorithm for the management of sIAAD (Fig. 2) was elaborated out of this experience:

1. Conservative treatment with best medical treatment and regular follow-up in the case of asymptomatic uncomplicated sIAAD according to the frequency in thoracic aortic dissection
2. Endovascular repair in complicated sIAAD (free/contained rupture of the infrarenal aorta, maximum transverse diameter of the abdominal aorta greater > 50 mm, expansion of the diameter more than 5 mm in 6 months, or persistent abdominal/back pain) if the anatomy and the morphology of the underlying pathology enable application
3. Otherwise open surgical repair

Conclusion

The majority of patients with sIAAD require invasive treatment, with EVAR being the preferable treatment option today. In asymptomatic IAAD, primary surveillance is justifiable, but close surveillance due to expansion is necessary. Symptomatic sIAAD needs invasive treatment. This study underlines the importance of managing patients with IAAD in specialized aortic centers offering all treatment modalities. As postulated by others [16, 18], a more aggressive management rather than conservative strategy is recommended.

Conflicts of interest None.

References

1. Meszaros I, Morocz J, Szilavi J et al (2000) Epidemiology and clinicopathology of aortic dissections. *Chest* 117:1271–1278
2. Trimarchi S, Tsai T, Eagle KA et al (2007) Acute abdominal aortic dissection: insight from the International Registry of Acute Aortic Dissection (IRAD). *J Vasc Surg* 46:913–919

3. Jonker FHW, Schlöser FJV, Moll FL, Muhs BE (2009) Dissection of the abdominal aorta. Current evidence and implications for treatment strategies: a review and meta-analysis of 92 patients. *J Endovasc Ther* 16:71–80
4. Shekelton J (1822) Dissections and aneurysm. *Dublin Hosp Rep* 3: 231–240. In Peacock TB. Report on cases of dissecting aneurysm. *Tr Path Soc London* (1863) 14: 87–99
5. Becquemin J-P, Deleuze P, Watelet J, Testard J, Melliere D (1990) Acute and chronic dissections of the abdominal aorta: clinical features and treatment. *J Vasc Surg* 11:397–402
6. Roberts CS, Roberts WC (1991) Aortic dissection with the entrance tear in the abdominal aorta. *Am Heart J* 121:1834–1835
7. Farber A, Wagner WH, Cossman DV, Cohen JL, Walsh DB, Fillinger MF, Cronenwett JL, Lauterbach SR, Levin PM (2002) Isolated dissection of the abdominal aorta: clinical presentation and therapeutic options. *J Vasc Surg* 36:205–210
8. Jawadi N, Bisdas T, Torsello G, Stavroulakis K, Donas KP (2014) Endovascular treatment of isolated abdominal aortic dissections: long-term results. *J Endovasc Ther* 21(2):324–328
9. Kouvelos GN, Vourliotakis G, Arnaoutoglou E, Papa N, Avgos S, Peroulis M, Papadopoulos G, Matsagkas MI (2013) Endovascular treatment for isolated acute abdominal aortic dissection. *J Vasc Surg* 58(6):1505–1511
10. Graham D, Alexander JJ, Franceschi D, Rashad F (1988) The management of localized abdominal aortic dissections. *J Vasc Surg* 8:582–591
11. Nandeesh BN, Mahadevan A, Santosh V, Yasha TC, Shankar SK (2007) Acute aortic dissection presenting as painful paraplegia. *Clin Neurol Neurosurg* 109:531–534
12. Solovei G, Alame A, Bardoux J, Cart P, Vix J, Petit J et al (1994) Paraplegia and dissection of the abdominal aorta after closed trauma. Apropos of a case. Current review of the literature (1982–1993). *J Chir (Paris)* 131:236–244
13. Berthet JP, Marty-Ané CH, Veerapen R, Picard E, Mary H, Alric P (2003) Dissection of the abdominal aorta in blunt trauma: endovascular or conventional surgical management. *J Vasc Surg* 38:997–1003
14. Devesa A, Sáez-Pérez JM, Sánchez-Roy R, Torres-García J, Simó C (1999) Spinal cord ischemia as a consequence of dissection of an abdominal aortic aneurysm. *Rev Neurol* 28:878–880
15. Mózes G, Gloviczki P, Park WM, Schultz HL, Andrews JC (2002) Spontaneous dissection of the infrarenal aorta. *Sem Vasc Surg* 15: 128–136
16. Adam DJ, Roy-Choudhury S, Bradbury AW (2007) Endovascular repair of spontaneous infrarenal aortic dissection presenting as severe lower extremity ischemia. *Eur J Vasc Endovasc Surg* 34:699–701
17. Böckler D, Schumacher H, Ganten M, von Tengg-Kobligk H, Schwarzbach M, Fink C, Kauczor HU, Bardenheuer H, Allenberg JR (2006) Complications after endovascular repair of acute symptomatic and chronic expanding Stanford type B aortic dissections. *J Thorac Cardiovasc Surg* 132:361–368
18. Flores J, Kunihara T, Shiya N, Yoshimoto K, Matsuzaki K, Nakamura M et al (2005) Importance of early repair of isolated abdominal aortic dissecting aneurysm. *Vasa* 34: 118–122