

Prevalence of Femoroacetabular Impingement Features in Japanese Young Adults without Symptoms: Hip Joint Morphology Using Radial Reformation from Computed Tomography

Keizo TANITAME^{1,*}, Hidenori MITANI², Yukiko HONDA², and Kazuo AWAI²

1) Department of Radiology, Chugoku Rosai Hospital, Kure, Japan

2) Diagnostic Radiology, Graduate School and Institute of Biomedical and Health Sciences, Hiroshima University, Hiroshima, Japan

ABSTRACT

Purpose: To determine the prevalence of femoroacetabular impingement (FAI) morphology in asymptomatic Japanese young adults using multi-detector computed tomography (MDCT) scan.

Materials and Methods: A total of 170 subjects (85 men; age, 19–39 years) without hip-related problems were included. Radial slices of 2-mm thickness at 30° intervals were reconstructed perpendicular to the central axis of the femoral head and neck for both hips. Alpha (α) angles, acetabular (AC) depths, and lateral centre-edge (LCE) angles were measured; maximum value of measured α angles was defined as max α angle, and minimum value of measured AC depths was defined as min AC depth. Max α angle > 55° was considered positive for cam-type FAI feature and min AC depth < 0 mm or LCE angle > 40° was considered positive for pincer-type FAI feature. Differences among planes, right-left correlations, and sex differences in FAI abnormalities were assessed.

Results: The α angles at 1- and 2-o'clock positions in men and at 2-o'clock position in women were significantly greater than those at other positions. AC depths at 2-o'clock position were smallest in men and women. Max α angles and min AC depths and LCE angles showed strong right-left correlations. Max α angles and the numbers of hips with cam features were significantly higher in men than in women. The prevalence of pincer features was similar between men and women.

Conclusion: The prevalence of cam type deformity is higher in men. Our results in Japanese populations were similar to those reported previously for Caucasians.

Key words: Femoroacetabular impingement, Alpha angle, Acetabular depth, MDCT

INTRODUCTION

Femoroacetabular impingement (FAI) has recently been recognised as a cause of groin pain in active young adults. Furthermore, this condition has been proposed as the leading cause of labral tears and subsequent development of hip osteoarthritis (OA)^{2,8,28,29}. FAI is classified into three types: an insufficient offset or pistol grip deformities of the femoral head-neck junction is referred to as cam-type, acetabular overcoverage of the femoral head is identified as pincer-type, and hip joint contour with both these characteristics is classified as combined cam- and pincer-type^{2,8,10}.

FAI is a common cause of primary OA of the hip in Caucasians. In contrast, FAI has been considered to be less common in Japanese individuals, because the hip joints of the Japanese are typically smaller than those of Caucasians, and acetabular dysplasia is the main cause of

hip OA in Japanese individuals^{5,11,20}. However, FAI has been recently reported to be occasionally problematic in Japanese young adults. The prevalence of FAI morphological features in Japanese young adults is unknown, because few studies focused on Japanese FAI have been published.

Plain radiography^{1,6,14,18,23,27}, computed tomography (CT)^{4,7,12,16,17}, and magnetic resonance imaging (MRI)^{10,15,21,22,24,25} can be used to confirm the FAI diagnosis. Multi-detector CT (MDCT) produces isotropic high spatial resolution images and can provide arbitrary radial reformation images of the hip joint, allowing a more precise evaluation of FAI morphology compared to plain radiography^{4,7,12,16,17}.

The aim of this study was to evaluate the prevalence of FAI morphology in the hip joints of asymptomatic Japanese young adults by using radial reformation from MDCT volume data and to determine the radial angle most frequently associated with anatomical abnormali-

* Corresponding author: Keizo Tanitame, M.D.

Department of Radiology, Chugoku Rosai Hospital, 1-5-1 Hiro-Tagaya, Kure 737-0193, Japan
Tel: +81-823-72-7171, Fax: +81-823-74-0371, E-mail: tntrad@gmail.com

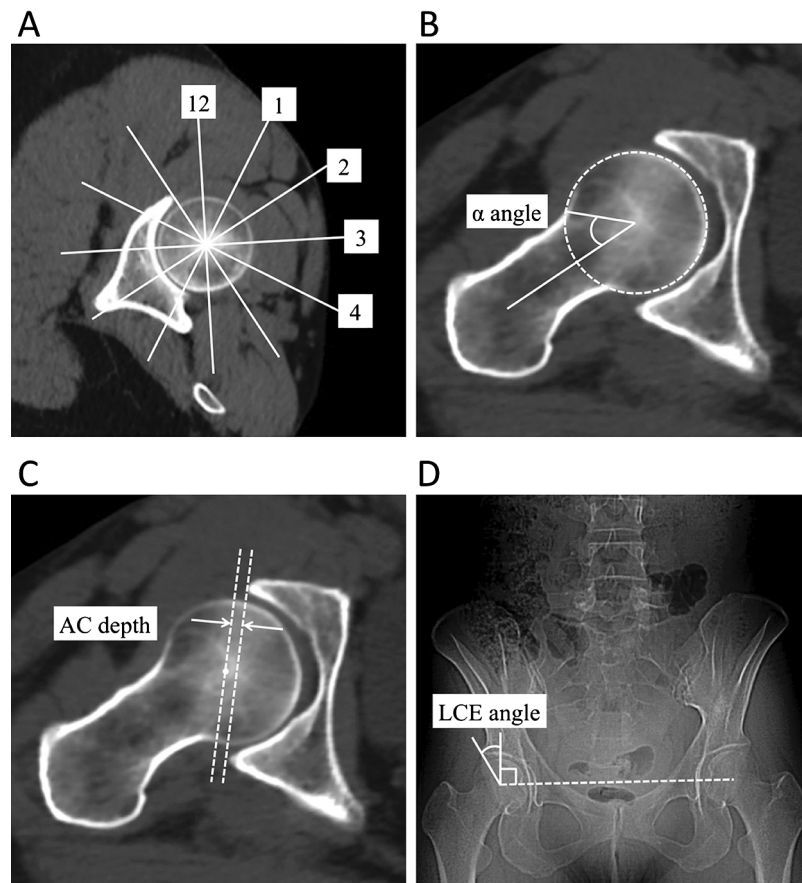


Figure 1 A. Radial reference lines at 30° intervals superimposed on the localizer image, that is through the centre of the femoral head, and orthogonal to the central axis of the femoral neck. A clockface orientation was adopted, and the anterior and superior locations were designated 3-o'clock and 12-o'clock, respectively. B. α angle for evaluating cam-type FAI feature. The α angle is formed by a line drawn from the centre of the femoral head through the central axis of the femoral neck and a line from the centre of the femoral head to the point where the femoral head/neck junction diverges from a best fit circle drawn around the perimeter of the femoral head. The α angle > 55° was defined as cam-type FAI feature. C. AC depth for evaluating pincer-type FAI feature. The AC depth is defined by the distance between the centre of the femoral head and the line through the anterior and posterior acetabular rim. Pincer-type FAI feature was considered positive (AC depth < 0 mm) if the centre of the femoral head was medial to the line. D. LCE angle for evaluating pincer-type FAI feature. The LCE angle is formed by a vertical line through the femoral head centre and a line connecting the femoral head centre with the lateral edge of the acetabulum. The LCE > 40° was also considered as pincer-type FAI feature. Abbreviation: FAI, femoroacetabular impingement; AC, acetabular; LCE, lateral centre-edge

ties, the right-left correlation, and sex difference concerning cam-, pincer-, and combined cam- and pincer-type FAI features.

MATERIALS AND METHODS

Subjects

The study was approved by our institutional review board, and the need for written informed consent was waived. A total of 170 Japanese subjects (85 men, 85 women) with age ranging from 19 to 39 years (age correlation between men and women: $r = 0.976$) who reported no hip-related problems and prior hip surgeries at an oral interview were recruited. Other exclusion criteria were lumbar scoliosis and deformities of pelvic bone on anterior-posterior (AP) scout views of CT scan. Each subject had complained of nonspecific abdominal pain and underwent abdominopelvic CT scan between January 2016 and July 2017.

Imaging technique

A 64-MDCT scanner (Optima CT660 Pro; GE Healthcare, Milwaukee, WI, USA) (scan settings: helical pitch 1.375, table movement 68.75 mm/s, scanning field-of-view 32–40 cm, voltage 120 kV, and smart mA [noise index 11]) was used to obtain 3D volume raw data. Subsequently, 2-mm thickness radial slices were reconstructed at 30° intervals perpendicular to the central axis of the femoral head and neck using a separate workstation (AW server 2.0, GE Healthcare, Milwaukee, USA) (Figure 1A). A clockface nomenclature was adopted for localization, and the anterior and superior locations were designated 3-o'clock and 12-o'clock, respectively.

Image evaluation

A radiologist (K.T) with 23 years of experience in skeletal radiology measured alpha (α) angles (Figure 1B) using a previously published method^{12,21,22} at 12-, 1-, 2-, 3-, and 4-o'clock positions; acetabular (AC) depths (Figure 1C)²² at 2-, 3-, and 4-o'clock positions (AC depth cannot be measured at 12- and 1-o'clock positions due to

acetabular notch); and lateral centre-edge (LCE) angles^{12,28}) on AP scout views of CT scan (Figure 1D) in both hips. The differences of α angle among the five radial planes and of AC depths among the three radial planes were assessed. Furthermore, the maximum value of α angles at 12- to 4-o'clock positions was defined as max α angle, and minimum value of AC depths at 2- to 4-o'clock positions was defined as min AC depth, and right-left correlations and sex differences concerning max α angle, min AC depth, and LCE angle were assessed. Max α angle $> 55^\circ$ was considered positive for cam-type FAI feature^{4,16,17,24}) and min AC depth < 0 mm or LCE angle $> 40^\circ$ was considered positive for pincer-type FAI features^{4,13,16,17}). Then, the numbers of FAI deformities (i.e., max α angle $> 55^\circ$, min AC depth < 0 mm, LCE angle $> 40^\circ$) were compared between men and women.

Statistical methods

Tukey-Kramer post hoc analysis was used to compare α angles and AC depths among previously described

radial angles. Then, right-left correlations in max α angles, min AC depths, and LCE angles were ascertained using the Pearson's correlation coefficient test. Independent sample *t* tests were used to compare the degrees of max α angles, min AC depths, and LCE angles between men and women. A *p* value < 0.01 was considered statistically significant, and correlations were considered strong for $r > 0.70$. Microsoft Excel 2010 (Microsoft Corp., Redmond, WA, USA) with the add-in software Statcel 3 (OMS Ltd., Tokyo, Japan) was used for statistical data analysis.

RESULTS

No significant difference in α angles was found between 1- and 2-o'clock positions in both hips of men; however, the angles in these positions were greater than those at 12-, 3-, and 4-o'clock positions (each $p < 0.01$). On the other hand, α angles at 2-o'clock position were significantly greater than those at any other radial plane

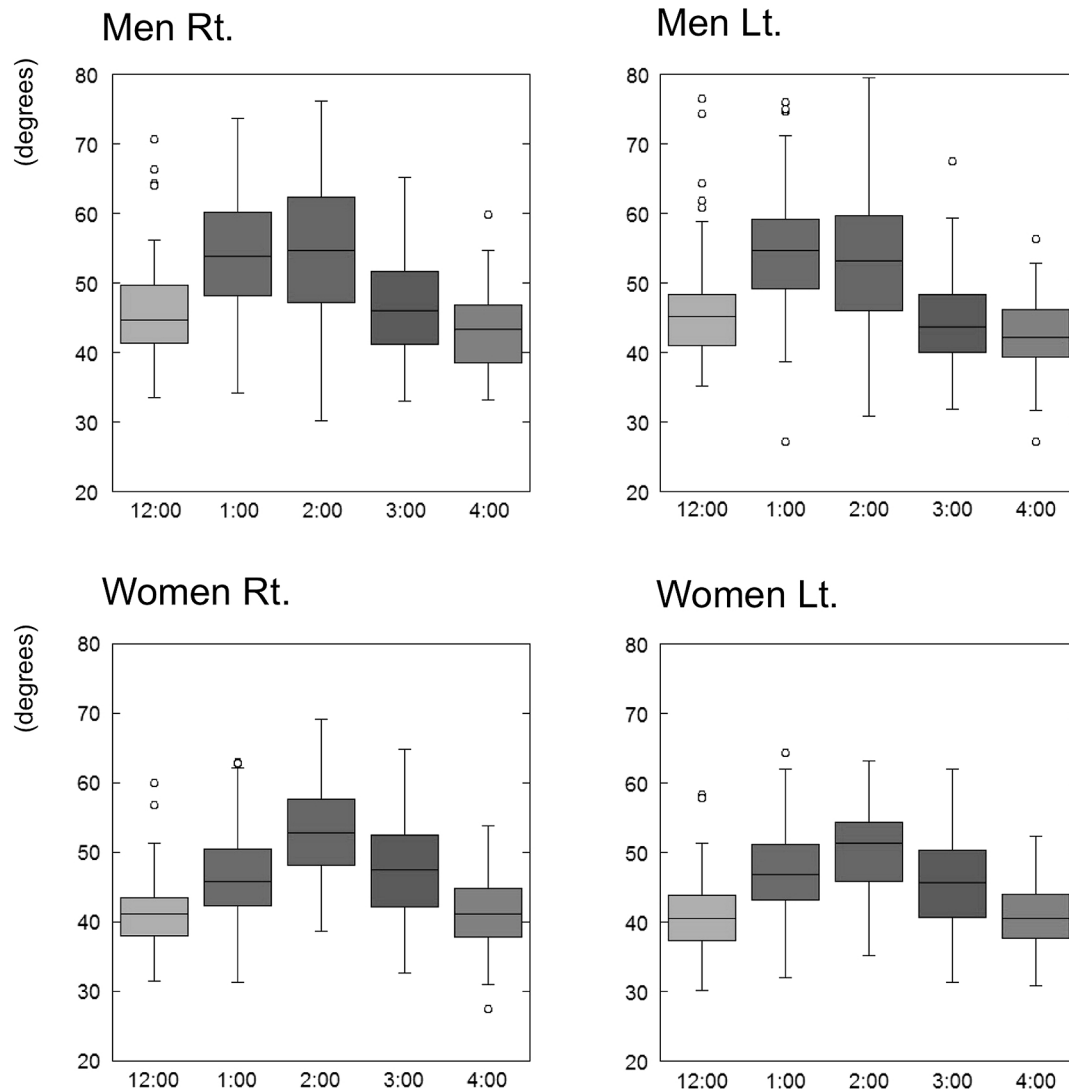


Figure 2 α angles at five positions from anterior to superior in hips of men and women. The boxes and error bars indicate 25–75 percentiles and 95% confidence intervals, respectively. α angles at 1- and 2-o'clock positions were significantly greater than those at any other o'clock positions in men, and those at 2-o'clock position were the greatest among the five positions in women. Abbreviation: Rt., right; Lt., left

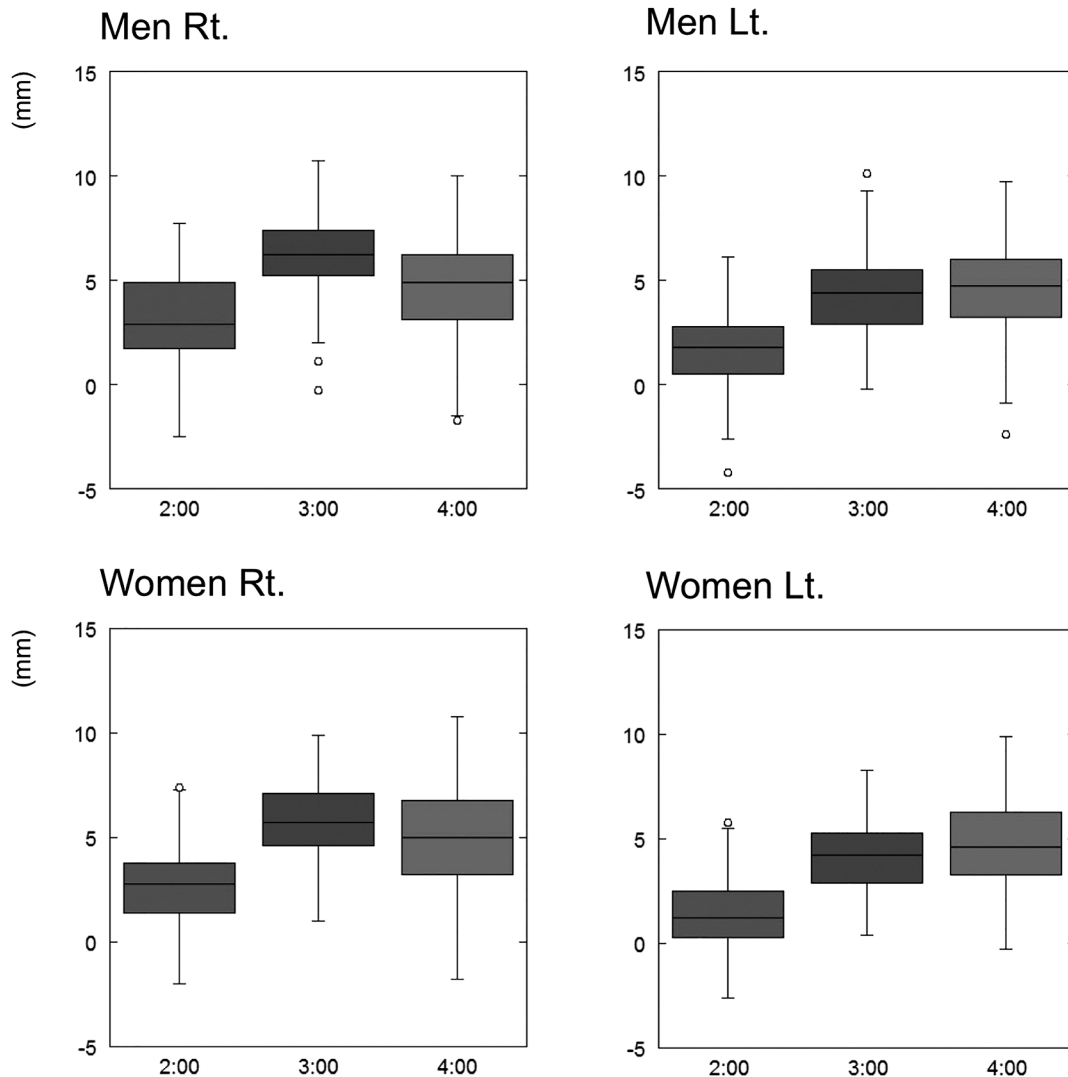


Figure 3 AC depths at three positions (2-, 3-, and 4-o'clock position) in hips of men and women. The boxes and error bars indicate 25–75 percentiles and 95% confidence intervals, respectively. The AC depths at 2-o'clock position were significantly smaller than those at any other o'clock positions in men and women. Abbreviation: Rt., right; Lt., left; AC, acetabular

in both hips of women (each $p < 0.01$) (Figure 2). AC depths at 2-o'clock position were significantly smaller than those in any other plane in both hips of men and women (each $p < 0.01$) (Figure 3).

Strong right-left correlations in max α angles (men: $r = 0.81$; women: $r = 0.77$), min AC depths (men: $r = 0.72$; women: $r = 0.75$), and LCE angles (men: $r = 0.80$; women: $r = 0.81$) were detected.

The mean values of max α angles in the right and left hips of men were 58.8° and 58.2° , respectively, while those of women were 54.2° and 52.3° , respectively. Max α angles of right and left hips in men were significantly greater than those in women (each $p < 0.01$) (Figure 4A). Cam morphology with α angle $> 55^\circ$ was detected in 61% of right hips and in 59% of left hips in men, and in 35% of right hips and in 26% of left hips in women. The numbers of right and left hips with cam-type FAI feature (max α angle $> 55^\circ$) in men were higher than those in women.

The mean values of min AC depths in the right and left hips of men were 2.66 mm and 1.64 mm, respectively, while those of women were 2.42 mm and 1.30 mm,

respectively. No significant sex differences were detected in min AC depths (right; $p = 0.47$, left; $p = 0.27$) (Figure 4B), and the right and left hips with AC depth < 0 mm were detected in 12% and 16% of men, and in 14% and 21% of women, respectively.

The mean values of LCE angles in the right and left hips of men were 32.4° and 34.3° , respectively, while those of women were 31.4° and 33.3° , respectively. No significant sex differences in LCE angles were found (right; $p = 0.35$, left; $p = 0.34$) (Figure 4C). Right and left hips with LCE angle $> 40^\circ$ were detected in 13% and 16% of men, and in 11% and 16% of women, respectively.

The overall prevalence of cam-, pincer-, and combined cam- and pincer-type FAI features in men and women is shown in Table 1. The majority of the FAI features in men and women were bilateral (69–100%). The prevalence of pincer- and combined cam- and pincer-FAI features was similar between men and women.

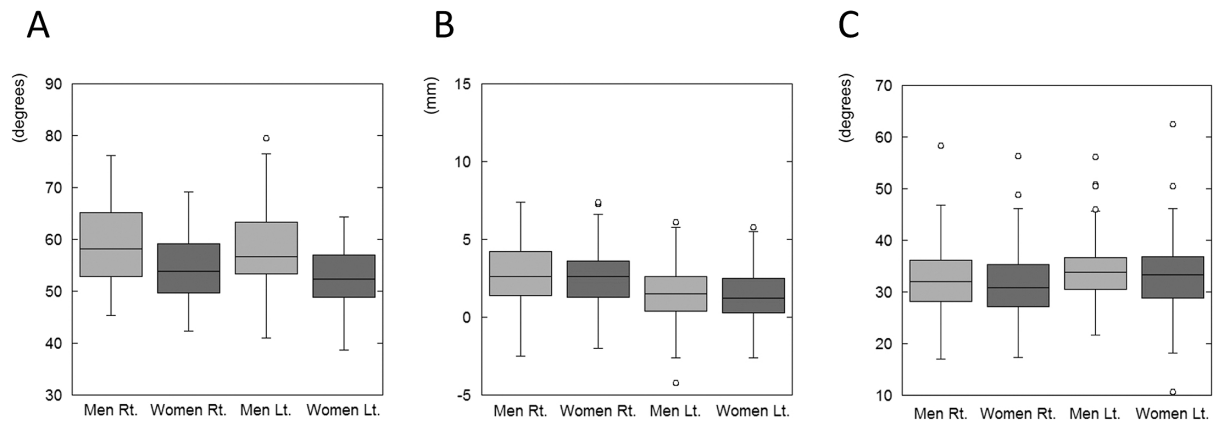


Figure 4 Sex differences in morphological abnormalities associated with FAI. A. Max α angles in men were significantly greater than those in women. B, C. No sex differences were detected in min AC depths (B) and LCE angles (C). Abbreviation: Rt., right; Lt., left; FAI, femoroacetabular impingement; AC, acetabular; LCE, lateral centre-edge

Table 1 Overall prevalence of cam-, pincer-, and combined cam- and pincer-type FAI features in men and women.

		Right-only	Left-only	Bilateral	Total
Men	Cam	3	1	40	44
	Pincer	0	1	8	9
	Combined	0	0	9	9
Women	Cam	2	0	17	19
	Pincer	1	4	11	16
	Combined	2	0	9	11

The majority of the FAI features were bilateral (69–100%). The number of men with cam-type FAI feature is significantly greater than that of women with this deformity. The prevalence of pincer- and combined cam- and pincer-FAI features was similar between men and women. Abbreviation: FAI, femoroacetabular impingement

DISCUSSION

Some studies on CT-based FAI-associated morphology in old Japanese subjects and in Japanese subjects with a wide range of age have been already published^{15–17,19}. However, FAI also affects young patients. To the best of our knowledge, this is the first study focusing on FAI morphology in asymptomatic young Japanese adults. Thus, we think that our results could be compared with those of studies on young Caucasians.

Radiography^{1,6,14,18,23,27}, CT^{4,12,17,19}, and MRI^{10,15,21,22,24,25} are validated modalities for imaging of FAI features of the hips. Primary studies of bony abnormality related to FAI used plan radiography to assess this syndrome. However, these evaluations had poor reproducibility due to the features of this imaging technique, such as positioning of the patient, film-focus distance, and the radiation dosage. Radial scan of the hip joint using MRI has become the most useful diagnostic tool for the pre-operative assessment of the hip, as it can reveal not only bony abnormalities, but also those of soft tissue structures, such as acetabular labrum and cartilage^{9,26}. However, MRI scanning of many healthy young volunteers for assessing the prevalence of FAI morphology is difficult because of the excessive time, cost, and manpower. In contrast, the post-processing technique of CT scan can achieve adequate assessment of the hip joint morphology in healthy young adults, whose abdomen and pelvis were

scanned for symptoms other than those of hip joint pathology.

Although α angles could be measured at 12-, 1-, 2-, 3-, and 4-o'clock positions, AC depths could not be measured at 12- and 1-o'clock positions because the osseous margin of the acetabulum is deficient at the acetabular notch. Thus, we measured LCE angles instead of the AC depth at 12-o'clock position. LCE angles could be measured more easily on AP scout views of the CT scan than on X-ray summation images from 3D volume data of CT scans; therefore, we have chosen the AP scout views for measuring the LCE angles.

We demonstrated that there was no significant difference in α angles at 1- and 2-o'clock positions, that these angles were greater than those at other positions in Japanese young men, and that α angles at 2-o'clock position were greater than those at any other o'clock position in Japanese young women. Our results are consistent with those of other reports on Caucasians^{4,22,24,25} and Japanese subjects¹⁷. Moreover, we demonstrated that AC depth at 2-o'clock position was significantly smaller than those in any other position in men and women. These results show that the contours of the acetabulum and femoral head-neck junction at the antero-superior position must be evaluated first for FAI morphology.

Strong right-left correlations were found in max α angles, min AC depths, and LCE angles. Allen et al.¹¹ demonstrated that most patients with a symptomatic

cam-FAI deformity of at least one hip had bilateral deformities on radiography. It remains to be shown whether those individual differences depend on genetic or environmental factors or not. The correlations of FAI-associated features in family members should be assessed in the future.

We found that max α angles of men were significantly greater than those of women, and that more men than women had cam-type deformity (max α angle $> 55^\circ$). Chakraverty et al.⁴⁾ demonstrated that 60% men and 35% women displayed at least one abnormality associated with cam-type FAI on radial reformation of CT scan, and Mineta et al.¹⁷⁾ showed that 54.4% men and 32.3% women had cam-type deformity in Japanese asymptomatic adults with age ranging from 20 to 89 years. Our results based on multi-sectional radial reformation of CT scan data were consistent with the results of these previous reports. Previous reports using X-ray^{14,23)} or only one oblique axial image of CT scan^{12,15,21)} detected fewer cam-type FAI features; Ergen et al.⁷⁾ showed that α angles obtained from radial reformatted images were higher than those from only an axial oblique image. It should be considered that fewer sectional evaluations could decrease the number of detected cam-type FAI features.

We detected no significant sex differences in pincer-type FAI deformities; however, there was a slight predominance of women in the population with AC depth < 0 mm or LCE angle $> 40^\circ$. Pfirrmann et al.²²⁾ and Tannast et al.²⁸⁾ demonstrated a higher prevalence of established pincer-type FAI among women. Chakraverty et al.⁴⁾ demonstrated that 36.7% of the hip joints of men and 42.5% of those of women had at least one pincer-type characteristic, and the prevalence of pincer-type morphologic features was similar between the sexes, with slight women predominance. On the other hand, Mineta et al.¹⁷⁾ reported that the prevalence of pincer-type FAI was predominant in Japanese men among a wide range of ages. Laborie et al.¹⁴⁾ also demonstrated that pincer-type deformities were more frequently seen in healthy young men compared to women in their large population study using X-ray films. Considering our results and those of these previous reports, sex difference in the prevalence of pincer-type FAI must be small.

Acetabular dysplasia is an anatomical abnormality that induces hip OA; moreover, repeated bony contusion due to reduced range of motion (ROM) induced by FAI is another cause of the OA^{2,8,28,29)}. Although we demonstrated that the prevalence of FAI features in Japanese young adults was similar to that in young Caucasians^{4,25)}, it is unclear what proportion of Japanese people with FAI-like features will have symptomatic FAI in the future. Moreover, although most cases of Japanese hip OA are induced by acetabular dysplasia, we think that some patients with latent hip OA due to FAI are overlooked. A long-term follow-up study of Japanese young subjects with FAI features is important for investigating their natural history.

Our study has some limitations. First, although we confirmed that all subjects had no symptoms and no operation history of their hip joints, femoroacetabular

impingement tests were not performed, which is a weak point of our study. However, Hack et al.¹⁰⁾ demonstrated the lack of association between an elevated α angle and a positive impingement test. Moreover, another study has recently found positive impingement sign to be an indicator of labral abnormality³⁾. Second, we found that the α angles of many healthy subjects were around 55° . Although we used a single cut-off value for cam-type FAI (i.e., 55°) based on previous reports on patients from Western countries, it is unclear whether this cut-off value of α angle is suitable for Japanese subjects who have smaller hip joints. Thus, we believe that a prospective cohort study on young adults with large α angles is warranted to determine the best cut-off value for α angle. Third, we did not measure Caucasian hip joints directly, and the assessment of ethnic differences based on Western reports remains ambiguous. Fourth, we measured LCE angles on AP scout views of the CT scans. As the subjects were scanned on a curved table top of the CT scanner, LCE angles measured in this study might be slightly different from those measured on X-ray images obtained from subjects lying on a flat table.

In conclusion, radial reformation of the hip joint from CT volume data can delineate FAI morphology. The prevalence of cam-type FAI morphology is higher in young Japanese men than in women. The prevalence of FAI morphological features in Japanese young adults is considered similar to that previously reported for Caucasian adults.

(Received May 1, 2018)

(Accepted July 31, 2018)

REFERENCES

1. Allen, D., Beaulé, P.E., Ramadan, O. and Doucette, S. 2009. Prevalence of associated deformities and hip pain in patients with cam-type femoroacetabular impingement. *J. Bone Joint Surg. Br.* 91: 589–594.
2. Beck, M., Kalhor, M., Leunig, M. and Ganz, R. 2005. Hip morphology influences the pattern of damage to the acetabular cartilage: femoroacetabular impingement as a cause of early osteoarthritis of the hip. *J. Bone Joint Surg. Br.* 87: 1012–1018.
3. Burnett, R.S., Della Rocca, G.J., Prather, H., Curry, M., Maloney, W.J. and Clohisy, J.C. 2006. Clinical presentation of patients with tears of the acetabular labrum. *J. Bone Joint Surg. Am.* 88: 1448–1457.
4. Chakraverty, J.K., Sullivan, C., Gan, C., Narayanaswamy, S. and Kamath, S. 2013. Cam and pincer femoroacetabular impingement: CT findings of features resembling femoroacetabular impingement in a young population without symptoms. *AJR Am. J. Roentgenol.* 200: 389–395.
5. Das De, S., Bose, K., Balasubramaniam, P., Goh, J.C. and Teng, B. 1985. Surface morphology of Asian cadaveric hips. *J. Bone Joint Surg. Br.* 67: 225–228.
6. Dudda, M., Kim, Y.J., Zhang, Y., Nevitt, M.C., Xu, L., Niu, J., et al. 2011. Morphologic differences between the hips of Chinese women and white women: could they account for the ethnic difference in the prevalence of hip osteoarthritis? *Arthritis Rheum.* 63: 2992–2999.
7. Ergen, F.B., Vudal, S., Sanverdi, E., Dolgun, A. and

- Aydingöz, Ü. 2014. CT assessment of asymptomatic hip joints for the background of femoroacetabular impingement morphology. *Diagn Interv. Radiol.* 20: 271–276.
8. Ganz, R., Parvizi, J., Beck, M., Leunig, M., Nötzli, H. and Siebenrock, K.A. 2003. Femoroacetabular impingement: a cause for osteoarthritis of the hip. *Clin. Orthop. Relat. Res.* 417: 112–120.
 9. Gold, S.L., Burge, A.J. and Potter, H.G. 2012. MRI of hip cartilage: joint morphology, structure, and composition. *Clin. Orthop. Relat. Res.* 470: 3321–3331.
 10. Hack, K., Di Primio, G., Rakhra, K. and Beaulé, P.E. 2010. Prevalence of cam-type femoroacetabular impingement morphology in asymptomatic volunteers. *J. Bone Joint Surg. Am.* 92: 2436–2444.
 11. Hoaglund, F.T., Shiba, R., Newberg, A.H. and Leung, K.Y. 1985. Diseases of the hip. A comparative study of Asian Oriental and American white patients. *J. Bone Joint Surg. Am.* 67: 1376–1383.
 12. Kang, A.C., Gooding, A.J., Coates, M.H., Goh, T.D., Armour, P. and Rietveld, J. 2010. Computed tomography assessment of hip joints in asymptomatic individuals in relation to femoroacetabular impingement. *Am. J. Sports Med.* 38: 1160–1165.
 13. Kutty, S., Schneider, P., Faris, P., Kiefer, G., Frizzell, B., Park, R., et al. 2012. Reliability and predictability of the centre-edge angle in the assessment of pincer femoroacetabular impingement. *International Orthopaedics* 36: 505–510.
 14. Laborie, L.B., Lehmann, T.G., Engesæter, I.Ø., Eastwood, D.M., Engesæter, L.B. and Rosendahl, K. 2011. Prevalence of radiographic findings thought to be associated with femoroacetabular impingement in a population-based cohort of 2081 healthy young adults. *Radiology* 260: 494–502.
 15. Lee, E. and Choi, J.A. 2015. Associations between Alpha Angle and Herniation Pit on MRI Revisited in 185 Asymptomatic Hip Joints. *Korean J. Radiol.* 16: 1319–1325.
 16. Mimura, T., Mori, K., Itakura, S., Furuya, Y., Kawasaki, T. and Imai, S. 2017. Prevalence of pincer, cam, and combined deformities in Asian hip joints evaluated with the Asian Hip Society diagnostic guideline for femoroacetabular impingement: A CT-based study. *J. Orthop. Sci.* 22: 105–111.
 17. Mineta, K., Goto, T., Wada, K., Tamaki, Y., Hamada, D., Tonogai, I., et al. 2016. CT-based morphological assessment of the hip joint in Asian patients: association with radiographic predictors of femoroacetabular impingement. *Bone Joint J.* 98-B: 1167–1174.
 18. Mori, R., Yasunaga, Y., Yamasaki, T., Nakashiro, J., Fujii, J., Terayama, H., et al. 2014. Are cam and pincer deformities as common as dysplasia in Asian patients with hip pain? *Bone Joint J.* 96-B: 172–176.
 19. Nakahara, I., Takao, M., Sakai, T., Nishii, T., Yoshikawa, H. and Sugano, N. 2011. Gender differences in 3D morphology and bony impingement of human hips. *J. Orthop. Res.* 29: 333–339.
 20. Nakamura, S., Ninomiya, S. and Nakamura, T. 1989. Primary osteoarthritis of the hip joint in Japan. *Clin. Orthop. Relat. Res.* 241: 190–196.
 21. Nötzli, H.P., Wyss, T.F., Stoecklin, C.H., Schmid, M.R., Treiber, K. and Hodler, J. 2002. The contour of the femoral head-neck junction as a predictor for the risk of anterior impingement. *J. Bone Joint Surg. Br.* 84: 556–560.
 22. Pfirrmann, C.W., Mengiardi, B., Dora, C., Kalberer, F., Zanetti, M. and Hodler, J. 2006. Cam and pincer femoroacetabular impingement: characteristic MR arthrographic findings in 50 patients. *Radiology* 240: 778–785.
 23. Pollard, T.C., Villar, R.N., Norton, M.R., Fern, E.D., Williams, M.R., Simpson, D.J., et al. 2010. Femoroacetabular impingement and classification of the cam deformity: the reference interval in normal hips. *Acta Orthop.* 81: 134–141.
 24. Rakhra, K.S., Sheikh, A.M., Allen, D. and Beaulé, P.E. 2009. Comparison of MRI alpha angle measurement planes in femoroacetabular impingement. *Clin. Orthop. Relat. Res.* 467: 660–665.
 25. Reichenbach, S., Jüni, P., Werlen, S., Nüesch, E., Pfirrmann, C.W., Trelle, S., et al. 2010. Prevalence of cam-type deformity on hip magnetic resonance imaging in young males: a cross-sectional study. *Arthritis Care Res.* 62: 1319–1327.
 26. Stelzeneder, D., Mamisch, T.C., Kress, I., Domayer, S.E., Werlen, S., Bixby, S.D., et al. 2012. Patterns of joint damage seen on MRI in early hip osteoarthritis due to structural hip deformities. *Osteoarthritis Cartilage* 20: 661–669.
 27. Takeyama, A., Naito, M., Shiramizu, K. and Kiyama, T. 2009. Prevalence of femoroacetabular impingement in Asian patients with osteoarthritis of the hip. *Int. Orthop.* 33: 1229–1232.
 28. Tannast, M., Siebenrock, K.A. and Anderson, S.E. 2007. Femoroacetabular impingement: radiographic diagnosis—what the radiologist should know. *AJR Am. J. Roentgenol.* 188: 1540–1552.
 29. Tanzer, M. and Noiseux, N. 2004. Osseous abnormalities and early osteoarthritis: the role of hip impingement. *Clin. Orthop. Relat. Res.* 429: 170–177.