

Hiroshima J. Med. Sci.  
Vol. 66, No. 1, 7~10, March, 2017  
HIJM 66-2

## A Case of Holocord Leptomeningeal Dissemination from Cerebellar Hemangioblastoma without von Hippel-Lindau Disease

Hideo OHBA<sup>1)</sup>, Satoshi YAMAGUCHI<sup>1)</sup>, Takuro MAGAKI<sup>2)</sup>, Masaaki TAKEDA<sup>1)</sup>,  
Manish KOLAKSHYAPATI<sup>1)</sup>, Takashi SADATOMO<sup>3)</sup> and Kaoru KURISU<sup>1)</sup>

1) Department of Neurosurgery, Institute of Biomedical and Health Sciences, Hiroshima University, 1-2-3 Kasumi, Minami-ku, Hiroshima 734-8551, Japan

2) Department of Neurosurgery, Hiroshima Prefectural Hospital, Ujinakanda 1-5-54, Minami-ku, Hiroshima 734-0004, Japan

3) Department of Neurosurgery, National Hospital Organization Higashihiroshima Medical Center, 513 Jike, Saijo-cho, Higashihiroshima 739-0041, Japan

### ABSTRACT

Hemangioblastoma disseminated along leptomeninges from the solitary cranial lesion without von Hippel-Lindau (VHL) disease is a quite rare instance with 23 cases reported in 40 years. We add a new case and discuss these rare instances. A 55-year-old female underwent surgery for total removal of cerebellar hemangioblastoma. Twenty months later, magnetic resonance (MR) images of the spinal cord revealed a tumor compressing the thoracic cord at T3-4 level which was removed en bloc by emergent spinal surgery. However, paraplegia and bowel bladder dysfunction recurred 5 months after the spinal surgery. Spine MR images showed diffuse enhancement of subarachnoid space. Exploratory surgery disclosed that the enhanced lesion was disseminated hemangioblastoma. After whole spinal irradiation, she was transferred to a palliative care hospital. Even after complete removal, possibility of leptomeningeal dissemination demands continuous follow-up. The mechanism of seeding of hemangioblastoma remains unclear, but attention must be paid to avoid spreading tumor cells during surgery because all the disseminated cases had precedent cranial surgery.

**Key words:** Hemangioblastoma, Leptomeningeal dissemination, von Hippel-Lindau disease

Hemangioblastomas are vascular-rich neoplasms, which typically arise in the cerebellum and account for 1.5-2.5% of all intracranial tumors<sup>21)</sup>. Approximately one fourth to one third of total hemangioblastomas are associated with von Hippel-Lindau (VHL) disease while the others are sporadic<sup>5,18,21)</sup>. The first-line treatment for solitary hemangioblastomas is total resection as they are generally considered to be curable, non-metastasizing tumors because of their low relapse rate<sup>3,7,11,15,19)</sup>. However, 23 cases of leptomeningeal dissemination of hemangioblastomas from the solitary cranial lesion without VHL disease have been reported since Mohan et al described the first case in 1976<sup>1,4,8,10,12-14,16,17,22,26,27)</sup>. We add a new case of leptomeningeal dissemination of hemangioblastomas without VHL disease and discuss these rare instances.

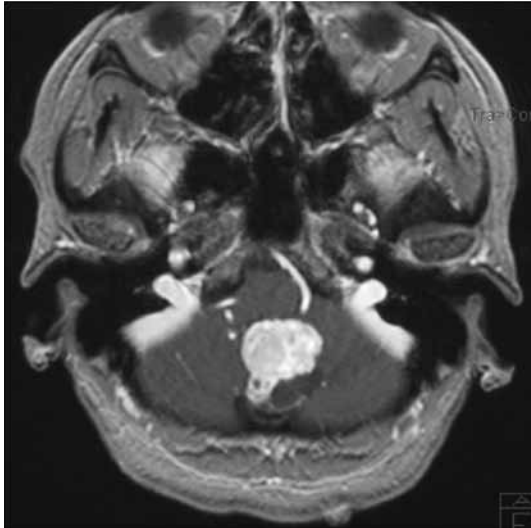### CASE REPORTS

A 55-year-old female presented with cerebellar hemangioblastoma manifested by headache (Fig.


1). She had neither familial history nor clinical symptoms associated with VHL disease. She underwent total removal of the tumor and ventriculoperitoneal shunt for idiopathic hydrocephalus. However, she presented with paraplegia 20 months after the craniotomy.

T1-weighted MR images with gadolinium-diethylenetriaminepentacetate (Gd-DTPA) revealed a strongly enhanced tumor compressing the thoracic cord at T3-4 level (Fig. 2-a). We immediately removed the tumor en bloc. Her symptoms temporarily recovered to be ambulant with the assistive braces. Histopathological diagnosis was typical benign hemangioblastoma except for high Ki-67 labeling index with a value of 30%. However, paraplegia and bowel bladder dysfunction recurred five months after the surgery.

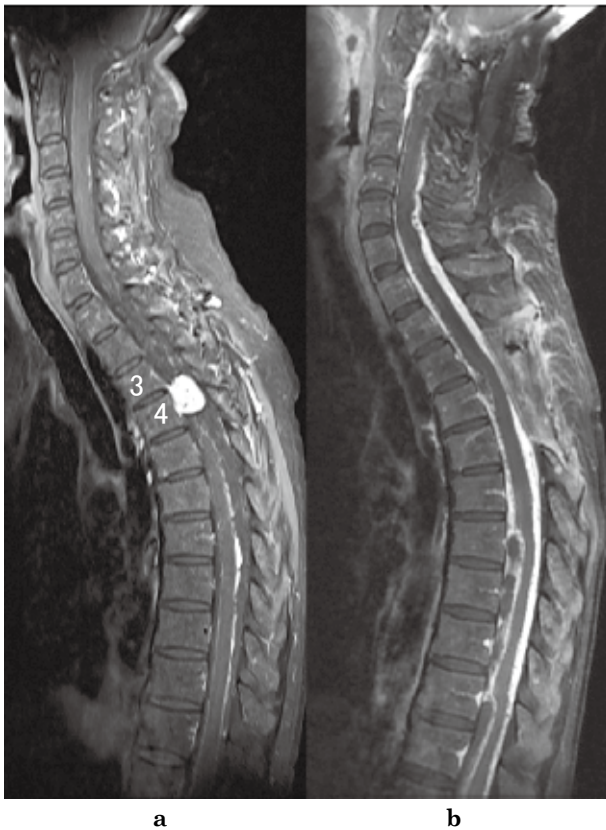
T1-weighted MR images with Gd-DTPA showed that almost the entire subarachnoid space of the spinal cord was strongly enhanced (Fig. 2-b). Exploratory surgery affirmed that the enhanced lesion was leptomeningeal dissemination of the hemangioblastoma (Fig. 3). Whole spinal irradiation at 45 Gy did not



**Fig. 1.** Gadolinium (Gd) -enhanced T1-weighted magnetic resonance (MR) image showing a strongly enhanced mass compressing the inferior vermis and medulla oblongata.



**Fig. 3.** Histological examination of tumor specimen stained with hematoxylin and eosin showing vacuolated stromal cells in rich capillary network. The stromal cells showed marked pleomorphic nuclei with degenerative atypia and hyperchromatic nuclei with scant lipid containing vacuoles. These findings indicate a histological diagnosis of hemangioblastoma.



**Fig. 2**

- a) T1-weighted MR image with Gd-diethylenetriaminepentacetate (Gd-DTPA) demonstrating a highly contrasted tumor compressing the thoracic cord at T3-4 level.  
 b) T1-weighted MR image with Gd-DTPA revealing almost the entire subarachnoid space of the spinal cord is strongly enhanced.

yield significant improvement of her symptoms. She was transferred to a palliative care hospital after the therapies.

## DISCUSSION

Hemangioblastomas are generally considered benign neoplasms and are classified as World Health Organization Grade I. Most of the recurrences after total resection of sporadic hemangioblastoma are usually observed at the primary site<sup>3,7,15,19</sup>. Although VHL disease can present with multifocal lesions, leptomeningeal dissemination of hemangioblastoma from the solitary lesion is an extremely rare occurrence. A review of relevant medical literatures published in the past 40 years including the present case identified 31 cases of leptomeningeal dissemination of hemangioblastoma: 24 associated with sporadic hemangioblastoma<sup>1,4,8,10,12-14,16,17,22,26,27</sup> and 7 with VHL disease<sup>2,6,9,23-25,28</sup>.

The demographic and clinical characteristics of each sporadic case are detailed in Table 1. The age at the primary surgery of hemangioblastoma ranged from 4 to 71 years (mean: 44.9 years old) and included 13 males and 11 females. The primary lesion of all but one case were located in the posterior cranial fossa. The latent period from the onset of primary hemangioblastoma to dissemination ranged from 7 months to 22 years (mean: 85.1 months). This is longer than the prevailing concept. Surgery and/or cerebrospinal fluid cytology confirmed dissemination of hemangioblastoma in all cases. Although most of the cases received secondary palliative surgery and adjuvant therapy, as in our case, none of those therapies were effective. The mean survival after the diagnosis of dissemination in fatal cases ranged from 2 to 79 months (mean: 25.7 months). Even in the survivors, most of the pa-

**Table 1.** Summary of the reported cases of leptomeningeal dissemination of hemangioblastoma without VHL disease

Author	Year	No.	Age	Sex	Primary site	Interval* (months)	Treatment**	Survival*** (months)	Seeding location
Mohan J et al. <sup>17)</sup>	1976	1	28	M	Cerebellum	96	Surgery (B+S), RTx	Dead (24)	Pons, cervical spinal cord
		2	39	M	Cerebellum	168	Surgery (B+S), RTx	Dead (3)	Cervical spinal cord
Tohyama T et al. <sup>26)</sup>	1990	3	51	M	Cerebellum	14	Surgery (B)	Dead (2)	Whole spine
Hande and Nagpal <sup>8)</sup>	1996	4	4	F	Cerebellum	9	Surgery (B), RTx	N/A	Multiple brain, spinal cord
Weil RJ et al. <sup>27)</sup>	2002	5	43	F	Cerebellum	84	Surgery (B+S), IFN-2 $\alpha$	Dead (18)	Suprasellar, pons, cerebellum, spinal cord
		6	47	F	Cerebellum	72	Surgery (B+S), RTx	Dead (48)	Cerebellum, medulla, spinal cord
		7	34	M	Cerebellum	2	Surgery (B+S), RTx	Dead (37)	Posterior fossa, spinal cord, optic chiasm
		8	41	M	Cerebellum	96	Surgery (B+S), RTx, RS	Dead (24)	Pons, medulla, spinalcord
Kato M et al. <sup>12)</sup>	2005	9	29	F	Cerebellum	264	Surgery (B+S), RTx	N/A	Brain stem, cerebellum, spinal cord
Lightfoot NJ et al. <sup>16)</sup>	2007	10	71	F	Foramen magnum	60	Surgery (B+S), RTx	N/A	Brain stem, spinal cord
Kim HR et al. <sup>13)</sup>	2009	11	41	M	Cerebellum	120	Surgery (B+S), RTx, RS	Dead (12)	Suprasella, medulla, spinal cord
Reyes-Botero G et al. <sup>22)</sup>	2012	12	31	M	Cerebellum	60	Surgery (B), Sunitinib	Dead (15)	Cerebellum, brain stem, whole spine
Chung SY et al. <sup>4)</sup>	2014	13	59	M	Cerebellum	60	Surgery (B+S), RS	N/A	Cerebellum, brain stem, multiple spine
Akimoto J et al. <sup>1)</sup>	2014	14	45	F	Cerebellum	91	Surgery (B+S), RTx, RS	Dead (29)	Multiple brain and spine
		15	57	F	Cerebellum	53	Surgery (B), RTx	Alive (90)	Sellar, midbrain pons, spinal cord
Higuchi T et al. <sup>10)</sup>	2015	16	71	F	Cerebellum	84	Surgery (B+S)	N/A	Multiple spine
Koo HW et al. <sup>14)</sup>	2016	17	46	F	Cerebellum	68	Surgery (B+S)	Dead (38)	Multiple spine
		18	36	M	Cerebellum	204	Surgery (B+S)	Alive (26)	Pons, cerebellum, spinal cord
		19	45	M	Cerebellum	39	Surgery (B)	Alive (46)	Medulla, spinal cord
		20	53	M	Cerebellum	136	Surgery (B), RTx	Dead (79)	Interpeduncular, prepontine, CPA, cisterna magna
		21	54	F	Cerebellum	50	Surgery (B), RTx	Alive (22)	Basal cistern, premedullary cistern, tentorium
		22	48	M	Spine	132	Surgery (S)	Alive (67)	CPA, frontal base, middle cranial fossa
Present case	2016	23	51	M	Cerebellum	64	Surgery (S)	Dead (5)	Pons, midbrain, insula, parietal lobe
		24	55	F	Cerebellum	24	Surgery (B+S), RTx	Alive (5)	Whole spine
<b>Mean age at initial surgery (years old, range)</b>						44.9 (4-71)			
<b>Mean time to dissemination (months, range)</b>						85.1 (9-264)			
<b>Mean survival in fatal cases (months, range)</b>						25.7 (2-79)			

Abbreviations: VHL=Von Hippel-Lindau, B=brain, S=spine, RTx=radiotherapy, RS=radiosurgery, CPA=cerebellopontine angle

Interval\*: time to dissemination after the initial surgery, Treatment\*\*: treatment for primary and disseminated lesion

Survival\*\*\*: survival after the diagnosis of dissemination

tients remained bedridden. These facts indicate a dismal prognosis for disseminated hemangioblastoma. The exact mechanism of dissemination after long latency is enigmatic. However, the fact that all disseminated cases had precedent cranial surgery implies the spillage of tumor fragments as a cause of dissemination. The slow-growing nature of this originally benign tumor may be associated with years of latency. The histopathological diagnosis made for each lesion in our case was typical hemangioblastoma without malignancy except for a high Ki-67 index. This high proliferative index value might have affected hasty dissemination. Further accumulation of such cases is necessary to elucidate the relationship between proliferative index and possibility of leptomeningeal dissemination.

## CONCLUSION

We add a new case of leptomeningeal dissemination of hemangioblastoma. The review documented disseminated hemangioblastoma may occur after years of latency and have a dismal prognosis. Continuous follow-up longer than a decade might be necessary. Absence of dissemination in patients without craniotomy implies intraoperative spillage of tumor fragments as the etiology of leptomeningeal

dissemination. Despite the occult mechanism of delayed dissemination, attention must be paid to avoid spreading tumor cells during surgery

(Received November 24, 2016)

(Accepted December 6, 2016)

## REFERENCES

1. Akimoto, J., Fukuhara, H., Suda, T., Nagai, K., Hashimoto, R. and Michihiro, K. 2014. Disseminated cerebellar hemangioblastoma in two patients without von Hippel-Lindau disease. *Surg. Neurol. Int.* **5**: 145.
2. Bakshi, R., Mechtler, L.L., Patel, M.J., Lindsay, B.D., Messinger, S. and Gibbons, K.J. 1997. Spinal leptomeningeal hemangioblastomatosis in von Hippel-Lindau disease: magnetic resonance and pathological findings. *J. Neuroimaging* **7**: 242-244.
3. Bründl, E., Schödel, P., Ullrich, O.W., Brawanski, A. and Schebesch, K.M. 2014. Surgical resection of sporadic and hereditary hemangioblastoma: Our 10-year experience and a literature review. *Surg. Neurol. Int.* **5**: 138.
4. Chung, S.Y., Jeun, S.S. and Park, J.H. 2014. Disseminated Hemangioblastoma of the Central Nervous System without Von Hippel-Lindau Disease. *Brain Tumor Res. Treat.* **2**: 96-101.

5. **Conway, J.E., Chou, D., Clatterbuck, R.E., Brem, H., Long, D.M. and Rigamonti, D.** 2001. Hemangioblastomas of the central nervous system in von Hippel-Lindau syndrome and sporadic disease. *Neurosurgery* **48**: 55-62.
6. **Courcoutsakis, N.A., Prassopoulos, P.K. and Patronas, N.J.** 2009. Aggressive leptomeningeal hemangioblastomatosis of the central nervous system in a patient with von Hippel-Lindau disease. *AJNR Am. J. Neuroradiol.* **30**: 758-760.
7. **Fukuda, M., Takao, T., Hiraishi, T., Yoshimura, J., Yajima, N., Saito, A., et al.** 2014. Clinical factors predicting outcomes after surgical resection for sporadic cerebellar hemangioblastomas. *World Neurosurg.* **82**: 815-821.
8. **Hande, A.M. and Nagpal, R.D.** 1996. Cerebellar haemangioblastoma with extensive dissemination. *Br. J. Neurosurg.* **10**: 507-511.
9. **Hanse, M.C., Vincent, A. and van den Bent, M.J.** 2007. Hemangioblastomatosis in a patient with von Hippel-Lindau disease. *J. Neurooncol.* **82**: 163-164.
10. **Higuchi, T., Maeda, M., Umino, M., Matsubara, T. and Sakuma, H.** 2015. Postoperative disseminated hemangioblastomatosis without von Hippel-Lindau disease. *Jpn. J. Clin. Radiol.* **60**: 681-684.
11. **Jagannathan, J., Lonser, R.R., Smith, R., DeVroom, H.L. and Oldfield, E.H.** 2008. Surgical management of cerebellar hemangioblastomas in patients with von Hippel-Lindau disease. *J. Neurosurg.* **108**: 210-222.
12. **Kato, M., Ohe, N., Okumura, A., Shinoda, J., Nomura, A., Shuin, T., et al.** 2005. Hemangioblastomatosis of the central nervous system without von Hippel-Lindau disease: a case report. *J. Neurooncol.* **72**: 267-270.
13. **Kim, H.R., Suh, Y.L., Kim, J.W. and Lee, J.I.** 2009. Disseminated hemangioblastomatosis of the central nervous system without von Hippel-Lindau disease: a case report. *J. Korean Med. Sci.* **24**: 755-759.
14. **Koo, H.W., Park, J.E., Cha, J., Kim, D.J., Kang, S.G., Lim, S.C. et al.** 2016. Hemangioblastomas with leptomeningeal dissemination: case series and review of the literature. *Acta Neurochir. (Wien)* **158**: 1169-1178.
15. **Liao, C.C. and Huang, Y.H.** 2014. Clinical features and surgical outcomes of sporadic cerebellar hemangioblastomas. *Clin. Neurol. Neurosurg.* **125**: 160-165.
16. **Lightfoot, N.J., Lucas, P.G. and Finnis, N.D.** 2007. Disseminated haemangioblastoma without evidence of the von Hippel-Lindau syndrome or haemangioblastomatosis--A case report and clinico-pathological correlation. *Clin. Neurol. Neurosurg.* **109**: 305-310.
17. **Mohan, J., Brownell, B. and Oppenheimer, D.R.** 1976. Malignant spread of haemangioblastoma: report on two cases. *J. Neurol. Neurosurg. Psychiatry* **39**: 515-525.
18. **Neumann, H.P., Eggert, H.R., Weigel, K., Friedburg, H., Wiestler, O.D. and Schollmeyer, P.** 1989. Hemangioblastomas of the central nervous system. A 10-year study with special reference to von Hippel-Lindau syndrome. *J. Neurosurg.* **70**: 24-30.
19. **Niemelä, M., Lemeta, S., Summanen, P., Böhling, T., Sainio, M., Kere, J., et al.** 1998. Long-term prognosis of haemangioblastoma of the CNS: impact of von Hippel-Lindau disease. *Acta Neurochir. (Wien)* **141**: 1147-1156.
20. **Padhi, S., Sarangi, R., Challa, S., Bussary, P., Panigrahi, M.K. and Purohit, A.K.** 2011. A 10-year retrospective study of hemangioblastomas of the central nervous system with reference to von Hippel-Lindau (VHL) disease. *J. Clin. Neurosci.* **18**: 939-944.
21. **Rachinger, J., Buslei, R., Prell, J. and Strauss, C.** 2009. Solid haemangioblastomas of the CNS: a review of 17 consecutive cases. *Neurosurg. Rev.* **32**: 37-47.
22. **Reyes-Botero, G., Gallego Perez-Larraya, J. and Sanson, M.** 2012. Sporadic CNS hemangioblastomatosis, response to sunitinib and secondary polycythemia. *J. Neurooncol.* **107**: 439-440.
23. **Reyns, N., Assaker, R., Louis, E. and Lejeune, J.P.** 2003. Leptomeningeal hemangioblastomatosis in a case of von Hippel-Lindau disease: case report. *Neurosurgery* **52**: 1212-1215.
24. **Rogers, L.R., LoRusso, P., Nadler, P., Malik, G., Shields, A. and Kaelin, W.** 2011. Erlotinib therapy for central nervous system hemangioblastomatosis associated with von Hippel-Lindau disease: a case report. *J. Neurooncol.* **101**: 307-310.
25. **Rojiani, A.M., Elliott, K. and Dorovini-Zis, K.** 1991. Extensive replacement of spinal cord and brainstem by hemangioblastoma in a case of von Hippel-Lindau disease. *Clin. Neuropathol.* **10**: 297-302.
26. **Tohyama, T., Kubo, O., Kusano, R., Miura, N. and Himuro, H.** 1990. A case of hemangioblastoma with subarachnoid dissemination. *No Shinkei Geka* **18**: 83-88.
27. **Weil, R.J., Vortmeyer, A.O., Zhunag, Z., Pack, S.D., Theodore, N., Erickson, R.K. et al.** 2002. Clinical and molecular analysis of disseminated hemangioblastomatosis of central nervous system in patients without von Hippel-Lindau disease. Report of four cases. *J. Neurosurg.* **96**: 775-787.
28. **Zhang, Q., Ma, L., Li, W.Y., Chen, J., Ju, Y. and Hui, X.H.** 2011. Von Hippel-Lindau disease manifesting disseminated leptomeningeal hemangioblastomatosis: surgery or medication? *Acta Neurochir. (Wien)* **153**: 48-52.