

Hiroshima J. Med. Sci.  
Vol. 66, No. 2, 45~48, August, 2017  
HIJM 66-9

## A Case of Foraminal Disc Herniation Successfully Treated via Paraspinal Transpars Approach

Yuyo MAEDA<sup>1)</sup>, Satoshi YAMAGUCHI<sup>1,\*</sup>, Masaaki TAKEDA<sup>1)</sup>,  
Manish KOLAKSHYAPATI<sup>1)</sup>, Junichi MIZUNO<sup>2)</sup> and Kaoru KURISU<sup>1)</sup>

1) Department of Neurosurgery, Institute of Biomedical and Health Sciences, Hiroshima University, Hiroshima, Japan

2) Department of Spine, Spinal Cord and Peripheral Nerve Surgery, Shin-Yurigaoka General Hospital, Kawasaki, Kanagawa, Japan

### ABSTRACT

A 61-year-old man presented with an excruciating pain in the right lower extremity. The pain was aggravated by a short distance walk and lateral bending to the right. These symptoms implied right L4 radicular pain. Magnetic resonance images revealed foraminal disc herniation at the right L4-5 level. After failure of conservative treatment, the patient underwent surgery via the paraspinal transpars approach. Following exposure of the right lateral edge of the L4 lamina, we partially resected a part of the pars interarticularis in accordance with the preoperative simulation using a 3-dimensional printed bone model. Fragmented discs compressing the dorsal root ganglion of L4 nerve root were totally removed. Postoperative computed tomography showed complete preservation of the facet. The patient showed remarkable relief from the pain and returned to his job a week after the surgery. Foraminal disc herniations cause fierce leg pain and are often intractable to conservative treatment. Selection of the surgical approach is often a matter of debate. The paraspinal transpars approach was effective and a less invasive surgical method in that it can preserve the facet joint. A three-dimensional printed bone model was useful in determining the minimal resection range of the pars interarticularis.

**Key words:** Foraminal disc herniation, Transpars approach, Three-dimensional printed bone model

Lateral lumbar disc herniations are defined as disc herniations outside of the spinal canal and are further classified into 2 subtypes: foraminal disc herniations (FDH) and extraforaminal disc herniations<sup>2,6,9,10</sup>.

FDHs are the ones confined within an area between the medial and lateral borders of the upper adjacent pedicle. They account for 3-5% of all herniated lumbar discs requiring surgery<sup>1,6,11</sup>. The dorsal root ganglion of exiting nerve root is prone to offence by FDHs and patients frequently present with severe leg pain. This excruciating pain is often resistant to conservative treatments and may influence not only the patients' daily activities but also their sleep<sup>2,4,10</sup>. There is no general consensus regarding imaging diagnosis and optimal surgical approach for FDHs as the lesion is small and hidden behind important bony structures, viz pedicles and the facet joint<sup>10</sup>. We report a case of FDH successfully treated via the facet-preserving transpars approach and discuss the imaging diagnosis and

surgical strategy for this lesion.

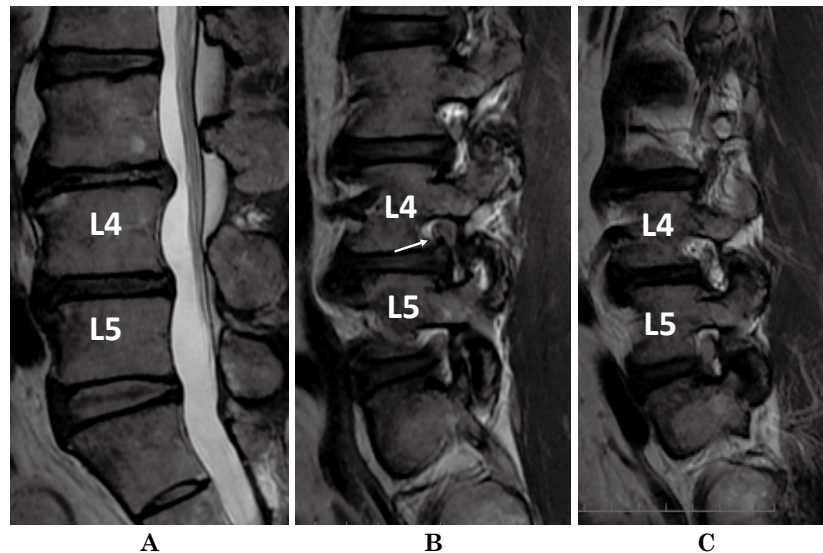
### CASE REPORT

A 61-year-old man presented with severe pain in the right lower extremity. Even a short distance walk provoked agonizing pain. The pain radiated from lateral thigh to medial shin and was aggravated by lateral bending to the affected side. These physical findings strongly suggested right L4 radiculopathy. Sagittal T2-weighted MR images revealed no culpable lesion in the spinal canal but a defect in a high-intensity signal area corresponding to the fat tissue in the right L4-5 intervertebral foramen (Fig. 1). Coronal section of fat-suppressed T1-weighted MR image after Gd-DTPA administration revealed a hypo-intensity signal defect within the enhanced foramen (Fig. 2). These findings implied FDH compressing the right L4 nerve root. Conservative treatment with analgesics, steroids, and nerve root block did not effectively relieve his severe

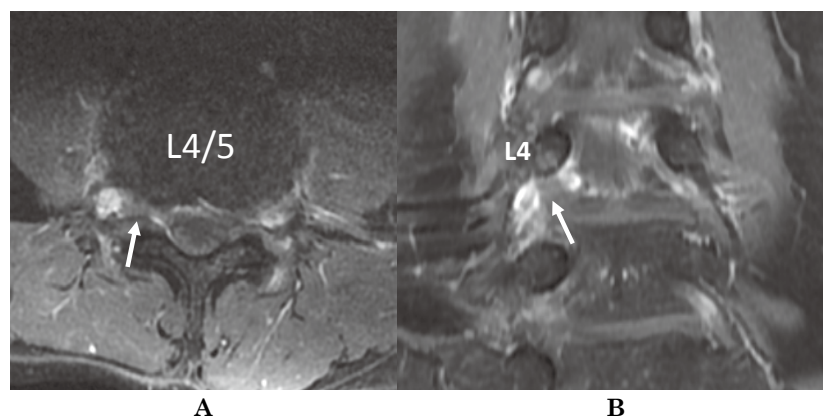
\* The corresponding author: Satoshi Yamaguchi

Department of Neurosurgery, Institute of Biomedical and Health Sciences, Hiroshima University, 1-2-3 Kasumi, Minami-ku, Hiroshima, 7348551, Japan

Tel: +81-82-257-5227, Fax: +81-82-257-5229, E-mail: satjp02@gmail.com



**Fig. 1.** Preoperative midsagittal T2-weighted magnetic resonance (MR) images revealed no culpable lesion in the spinal canal (A). Parasagittal sections at L4-5 intervertebral foramen revealed a less prominent high intensity signal area corresponding to the fat tissue on the right (B, white arrow) compared with the left (C).



**Fig. 2.** Axial (A) and coronal (B) sections of post-contrast fat-suppression T1-weighted magnetic resonance image showing a defect in the signal intensity amidst the enhanced area within the foramen (white arrows). These findings suggested foraminal disc herniation.

pain. The pain rendered the patient sleepless and absent from his job compelling him to undergo surgery. To preserve the facet joint, we simulated the minimal range of resection of the pars interarticularis (the pars, in short) on a 3-dimensional (3D) printed lumbar spine model generated from CT images of the patient (Fig. 3A).

With the patient in a prone position, the right side of the L4 lamina was exposed via the paraspinous intermuscular approach. The lateral edge of the pars was resected in accordance with the preoperative simulation. After removing the ligamentum flavum, we confirmed the fragmented discs dorsal to the dorsal root ganglion of L4 nerve root. Removal of these fragments achieved adequate decom-

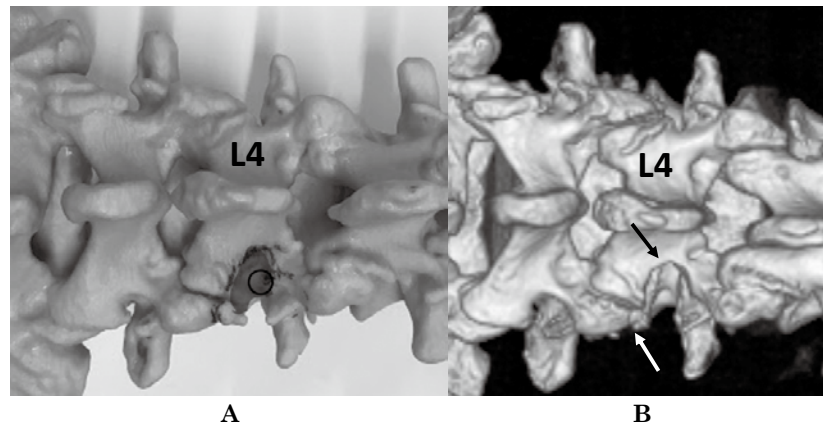
pression of the nerve root.

The patient's lower limb pain dramatically subsided immediately following the surgery and he returned to his job a week after surgery. A postoperative 3D-CT image revealed complete preservation of the facet joint (Fig. 3B).

## DISCUSSION

### *Magnetic resonance imaging of foraminal disc herniation*

Before the advent of MR imaging, the intervertebral foramen was described as "the hidden zone" because this area is out of the reach of the contrast media in myelography<sup>10</sup>. MR images have enabled



**Fig. 3**

**A:** A photograph of a 3-dimensional (3D) printed lumbar spine model generated from CT images of the patient. The circle shows the location of foraminal disc herniation. Shaded area indicates simulated minimal range of resection of the pars interarticularis.

**B:** Postoperative 3D computed tomography image confirmed the part of pars interarticularis removed in accordance with the preoperative planning (black arrow). Note the facet joint is completely preserved (white arrow).

visualization of this hidden zone. The difference in signal intensity between the nerve root and the surrounding fat tissue on MR image is useful to detect intraforaminal lesions: the nerve root is depicted as a low intensity signal and the fat as a high intensity signal on both T1- and T2-weighted images. When a disc herniation is present in the foramen, the circle of fat tissue enclosing the nerve is incomplete or distorted<sup>4,10</sup>. A post-contrast MR image showing enhancement of the venous plexus around the nerve root might be advantageous for detecting small lesions<sup>8</sup>. In the present case, a post contrast image showed herniated disc as a defect in the signal intensity amidst the enhanced area within the foramen.

#### ***Surgical treatment of foraminal disc herniation in the lumbar spine***

Various surgical approaches and their modifications have been advocated for the treatment of lateral lumbar disc herniations<sup>2-4,11</sup>. The most familiar procedure is a midline approach with hemilaminectomy and medial facetectomy. However, it only provides access to the proximal foraminal region. Total facetectomy with partial laminectomy technique provides maximal exposure, not only of the inside but also the outside of the intervertebral foramen. Mandatory subsequent spinal fixation demands careful selection from the cases, like a large disc hernia bridging over intra- and extra-canalicular spaces. As to a FDH like our case, the transpars approach is a good choice because of its lesser invasiveness to the facet joint. In this approach, paraspinal intermuscular exposure of the lamina is followed by partial resection of the lateral margin

of the pars. Resection of lateral 1/3 to 1/4 of the pars exposes intraforaminal lesion and enables near total preservation of the interior facet<sup>1,2,4</sup>. Delayed fracture of remaining lamina is a possible consequence of this approach. Ivanov et al. examined stress distribution after partial resection of the pars by the finite element method and concluded that resection of a lateral 1/4 of the pars has minimal influence on the durability of the remaining vertebral arch<sup>5</sup>. In the present case, a postoperative 3D CT image showed that the extent of the resection exceeded laterally one fourth of the pars. Close follow-up is mandatory even if the patient has not shown any evidence of delayed spinal fracture so far.

#### ***Utility of 3-dimensional printed bone model in preoperative simulation***

Recent articles have reported the usefulness of a 3D printed bone model for preoperative simulation in complicated spinal cases. Yang et al reported the positive effect of preoperative simulation on a 3D printed model in adolescent scoliosis surgery. They achieved reduction of many parameters such as operative time, the volume of blood loss, and the number of screw misplacements<sup>7,12</sup>. Although the surgery for foraminal disc herniation is not as complicated as surgery for scoliosis, the bone model was also useful in the present case. The main motive of patients in opting for surgery was prompt resumption of work. We determined the minimal range of resection of the pars from MR images and a 3D bone model. Resection of the pars in accordance with the simulation precisely exposed migrated fragmented discs over the nerve root verifying the

effectiveness of this planning. Less invasive surgery and complete preservation of the facet joint contributed to the patient's early return to the job.

### CONCLUSION

The authors report a case of foraminal disc herniation. Although selection of surgical approach is often a matter of debate for this relatively rare type of disc herniation, the paraspinal transpars approach is an effective and less invasive surgical method. A three-dimensional printed bone model was useful in determining minimal resection range of the pars interarticularis.

(Received January 30, 2017)

(Accepted February 2, 2017)

### REFERENCES

1. **De Bonis, P., Mongardi, L., Pompucci, A., Ricciardi, L., Cavallo, M.A., Farneti, M., et al.** 2016. Transpars Microscopic Approach for the Treatment of Purely Foraminal Herniated Lumbar Disc: A Clinical, Radiological Two-Center Study. *Spine (Phila Pa 1976)*. [Epub ahead of print]
2. **Epstein, N.E.** 2002 Foraminal and far lateral lumbar disc herniations: surgical alternatives and outcome measures. *Spinal Cord*. **40**: 491-500.
3. **Garrido, E. and Connaughton, P.N.** 1991. Unilateral facetectomy approach for lateral lumbar disc herniation. *J. Neurosurg.* **74**: 754-756.
4. **Hitchon, P.W., Awe, O.O., Close, L. and Sukkarieh, H.G.** 2015. Minimally invasive pars approach for foraminal disc herniation. *J. Clin. Neurosci.* **22**: 1128-1132.
5. **Ivanov, A.A., Faizan, A., Ebraheim, N.A., Yeasting, R. and Goel, V.K.** 2007. The effect of removing the lateral part of the pars interarticularis on stress distribution at the neural arch in lumbar foraminal microdecompression at L3-L4 and L4-L5: anatomic and finite element investigations. *Spine (Phila Pa 1976)*. **32**: 2462-2466.
6. **Lejeune, J.P., Hladky, J.P., Cotton, A., Vinchon, M. and Christiaens, J.L.** 1994. Foraminal lumbar disc herniation. Experience with 83 patients. *Spine (Phila Pa 1976)*. **19**: 1905-1908.
7. **Li, C., Yang, M., Xie, Y., Chen, Z., Wang, C., Bai, Y., et al.** 2015. Application of the polystyrene model made by 3-D printing rapid prototyping technology for operation planning in revision lumbar discectomy. *J. Orthop. Sci.* **20**: 475-480.
8. **Lohr, M., Lebenheim, L., Berg, F., Stenzel, W., Hescheler, J., Molcanyi, M., et al.** 2014. Gadolinium enhancement in newly diagnosed patients with lumbar disc herniations are associated with inflammatory peridiscal tissue reactions-evidence of fragment degradation? *Clin. Neurol. Neurosurg.* **119**: 28-34.
9. **Maroon, J.C., Kopitnik, T.A., Schulhof, L.A., Abla, A. and Wilberger, J.E.** 1990. Diagnosis and microsurgical approach to far-lateral disc herniation in the lumbar spine. *J. Neurosurg.* **72**: 378-382.
10. **McCulloch, J.A. and Young, P.H.** 1998. Foraminal and extraforaminal lumbar disc herniation, p.383-428. *In* J.A. McCulloch and P.H.Young(eds.), *Essentials of Spinal Microsurgery*. Lippincott-Raven, Philadelphia, PA.
11. **Siebner, H.R. and Faulhauer, K.** 1990. Frequency and specific surgical management of far lateral lumbar disc herniations. *Acta Neurochir (Wien)*. **105**: 124-131.
12. **Yang, M., Li, C., Li, Y., Zhao, Y., Wei, X., Zhang, G., et al.** 2015. Application of 3D rapid prototyping technology in posterior corrective surgery for Lenke 1 adolescent idiopathic scoliosis patients. *Medicine (Baltimore)*. **94**: e582.