

Unilateral Vaso-occlusive Retinopathy in Quiescent Condition of Systemic Lupus Erythematosus

Seiji HAYASAKA, Nanako FURUSE, Michiko KANAMORI and Tomoichi SETOGAWA

Department of Ophthalmology, Shimane Medical University, 89-1 Enya, Izumo, Shimane 693, Japan

ABSTRACT

A 24-year-old woman with systemic lupus erythematosus had decreased visual acuity, retinal cotton-wool spots, venous dilations, and multiple arteriolar occlusions around the optic disc in her left eye. The right eye showed good visual acuity and a few small retinal hemorrhages. Although abnormal serologic findings and systemic manifestations quieted with corticosteroid therapy, the retinopathy in the left eye progressed. After treatment with focal argon laser photocoagulation, progression of the retinopathy stopped.

Key words: *Retinopathy, Systemic lupus erythematosus, Vaso-occlusion, Photocoagulation*

Systemic lupus erythematosus (SLE), an immune-complex mediated disease, demonstrates various manifestations in multiple organs. Ocular findings of SLE include cotton-wool spots, retinal edema and hemorrhages, retinal artery or venous occlusions, preretinal neovascularization, and optic neuritis^{3-13,15,17-19}. Inflammation in SLE is probably initiated with the deposition of soluble circulating immune complexes in vessel walls¹. Ocular lesions also may cause immune complex deposition² and may closely parallel the patient's systemic condition. Retinopathy resulting from SLE usually occurs in seriously ill patients with acute systemic disease^{8,10}. Severe retinal vaso-occlusive disease in SLE is commonly associated with central nervous system involvement¹⁰. Although circulating immune complexes are thought to affect both eyes equally, a few patients exhibit unilateral involvement of the central retinal artery or venous occlusion, or optic neuritis^{4,6,10,13,15}. We recently treated a patient with SLE who developed a unilateral vaso-occlusive retinopathy while her systemic condition remained quiescent.

CASE REPORT

In January 1986, a 24-year-old woman complained of a malar rash which resolved spontaneously a few weeks later. In October 1986, she complained of fever and pain in both knee joints. These too subsided spontaneously within a few days, but recurred in November. At that time, she consulted her family physician and she was given analgesic tablets. Despite transient improvement, the patient later reported general fatigue, dyspnea, and oral ulcers. She was referred to Shimane Medical University Hospital and was admitted in December 1986.

Her systemic condition and laboratory test results fit the diagnosis of SLE, according to the revised

criteria of the American Rheumatism Association¹⁶. Malar rash, oral ulcer, arthritis, pleuritis, persistent proteinuria, cellular casts, hemolytic anemia, leukopenia, positive LE cells, and increased levels of anti-DNA antibody (126 μ /ml; normal, less than 15 μ /ml), antibody to Sm nuclear antigen, and antinuclear antibody were found. The diagnosis was unequivocal, despite an absence of discoid rash, photosensitivity, and neurologic disorder. Raynaud's phenomenon and alopecia were not evident. Her blood pressure, fasting blood glucose level, and blood urea nitrogen value were within normal range. She did not take oral contraceptives or any drug that might induce an SLE-like syndrome.

In early January 1987, the patient began receiving oral doses of prednisolone, 60 mg/day. In response to the corticosteroid treatment, the systemic inflammatory signs quieted, and the laboratory test results reached normal or nearly normal levels: the anti-DNA antibody level was 16 μ /ml. In late January, the oral prednisolone was decreased to 40 mg/day. A few days later the patient noticed decreased vision in the left eye.

An ophthalmic examination on January 27, 1987, showed her visual acuity was 1.0 with myopic correction (-1.25 D) OD and 0.4 with myopic correction (-0.75 D) OS. The intraocular pressures were 12 mm Hg OU. Lacrimation, as tested with the Schirmer method, was mildly decreased in both eyes. Eye position and movement were normal bilaterally. The cornea, anterior chamber, and vitreous body were clear bilaterally, but blue punctate opacities were noted in both lenticular cortex.

In the right eye, a small hemorrhage was found near the optic disc; otherwise, the fundus appeared normal. The left fundus disclosed a normal optic disc, a few cotton-wool spots, and small hemor-

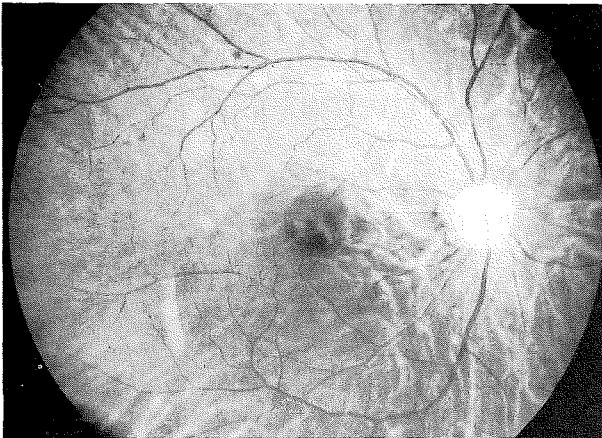


Fig. 1. In May 1987, the right fundus demonstrates a few small hemorrhages in the superotemporal retina.

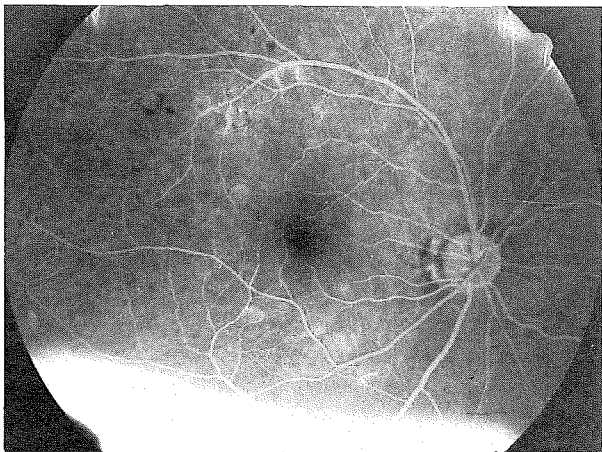


Fig. 2. In May 1987, fluorescein angiogram of the right fundus exhibits a few microaneurysms. Angiography was performed after the patient received an intravenous injection of 1.0 ml of 10% fluorescein sodium.

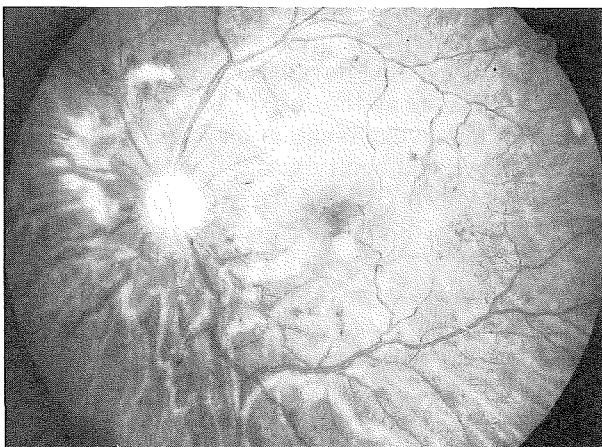


Fig. 3. In May 1987, the left fundus shows arteriolar obstruction, venous dilation, multiple dot hemorrhages, and cotton-wool spots.

rhages around the optic disc. A fluorescein angiogram demonstrated multiple arteriolar occlusions, venous dilations, and capillary nonperfusion around the optic disc in the left eye. Visual fields tested with Goldmann perimetry showed normal findings in the right eye and a relative central scotoma in the left. The dosage of oral prednisolone was increased to 60 mg/day.

In February, the visual acuity remained good OD, but deteriorated to 0.1 OS. The small retinal hemorrhage in the right eye disappeared. In the left fundus, the area of capillary nonperfusion extended gradually, particularly in the macula, despite quiescence of the systemic condition.

In March, a trial consisting of a left retrobulbar injection of dexamethazone, 2 mg/day, was given for one week. This therapy failed to cease the progression of the retinopathy in the left eye.

In April, oral prednisolone was reduced to 30 mg/day because the patient had abdominal pain, but systemic inflammatory signs were absent.

In May, her visual acuity decreased to 0.06 OS. In the right fundus, a few small hemorrhages were noted in the superotemporal midperiphery (Fig. 1). A few microaneurysms were also present, but arteriolar occlusion or capillary nonperfusion was absent in the right fundus on the fluorescein angiogram (Fig. 2). The left fundus showed multiple arteriolar occlusions, venous dilation, multiple dot hemorrhages, and cotton-wool spots (Fig. 3). A fluorescein angiogram of the left fundus revealed multiple arteriolar occlusions, vein dilations with that leaked dye, an enlarged area of capillary nonperfusion, an increase in the number of microaneurysms, and dilated capillaries around the optic disc and in the macula (Fig. 4).

On June 6, 1987, the patient received 96 spots of focal argon laser photocoagulation on the nasal and inferior retina. This area corresponded to the region of capillary nonperfusion detected by fluorescein angiography in the left eye. After photocoagulation treatment, microaneurysms, cotton-wool spots and retinal hemorrhages diminished, but the poor visual acuity remained. Systemic doses of prednisolone were tapered.

In August, oral prednisolone, 10 mg every other day, was maintained to stop the progression of retinopathy. When the patient was discharged from the hospital, her visual acuity was 1.0 OD and 0.06 OS.

In June 1988, her visual acuity remained unchanged. Capillary dilations were visible in the left macula (Fig. 5). Cotton-wool spots, retinal hemorrhages, arteriolar occlusions, and venous dilations had disappeared.

The patient had no systemic inflammatory signs and nearly normal laboratory test results since January 1987. The retinopathy had not progressed during $1\frac{1}{2}$ year of follow-up after the photocoagu-

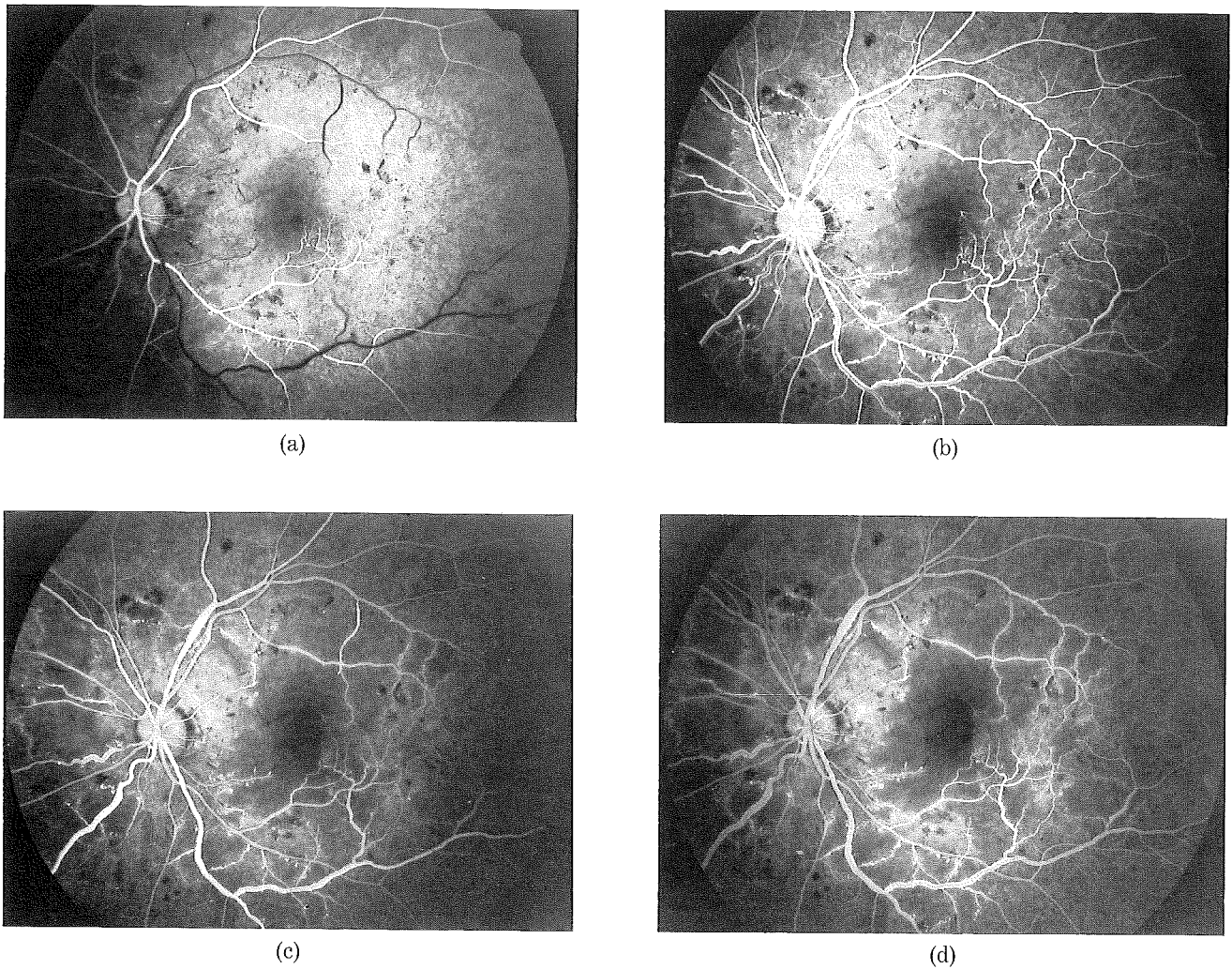


Fig. 4. In May 1987, fluorescein angiograms of the left fundus exhibit (a) arterial occlusions, microaneurysms, and capillary dilations in the arterial phase; (b) venous occlusions and dilation, capillary nonperfusion and dilations in the early arteriovenous phase; (c) capillary nonperfusion in the nasal retina and the macula in the arteriovenous phase; and (d) leakage of dye in the late arteriovenous phase. Angiography was performed as the legend of Fig. 2.

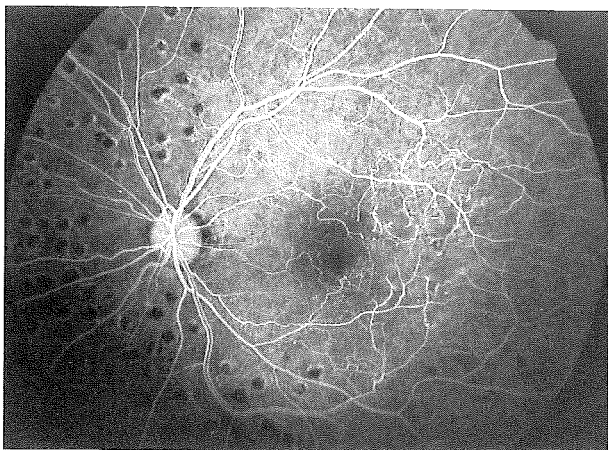


Fig. 5. In June 1988, the fluorescein angiogram of the left fundus reveals capillary dilations in the macula. Photocoagulation scars are also visible. Angiography was performed as the legend of Fig. 2.

lation treatment. No cerebral manifestations were noted. The blood pressure, fasting blood glucose level, and blood urea-nitrogen value were within normal range throughout the follow-up period. Pulsations were noted bilaterally in the upper extremities.

DISCUSSION

The described patient with SLE showed a few small hemorrhages in the right fundus and severe vaso-occlusive retinopathy in the left. The retinopathy in the left eye progressed despite quiescence of the systemic condition with corticosteroid therapy, and subsided after treatment with focal argon laser photocoagulation.

Multiple retinal arterial occlusions in one eye of a patient with active systemic SLE are uncommonly reported^{10,17}. Unilateral involvement of multiple arteriolar occlusions during the remission of the systemic condition, as found in our patient, may be

rare. Pathogenesis of unilateral vaso-occlusive retinopathy in a disease process that results from the deposition of soluble circulating immune complexes is difficult to understand. A local alteration in microvasculature system of one eye such as the result from antecedent ocular trauma or unilateral vascular anomalies had been suggested to explain the pathogenesis¹⁷. No such history or findings, however, were apparent in our patient.

Preretinal neovascularization and vitreous hemorrhage are known as rare complications of SLE¹⁸. After focal argon laser photocoagulation was applied to the ischemic retina, the progression of the retinopathy ceased in our patient. Our rationale for the use of photocoagulation was based on its successful results in other ischemic retinal diseases such as diabetic retinopathy and branch retinal vein occlusion¹⁴. Although the exact mechanism is unclear, focal photocoagulation may alter in part the course of retinopathy in our patient.

We believe that this patient represented a rare case of unilateral multiple arteriolar occlusions in SLE retinopathy despite quiescence of the systemic condition.

(Received November 24, 1988)

(Accepted January 23, 1989)

REFERENCES

1. **Agnello, V., Koffler, D. and Kunkel, H.G.** 1973. Immune complex systems in the nephritis of systemic lupus erythematosus. *Kidney Int.* **3**: 90–99.
2. **Aronson, A.J., Ordonez, N.G., Diddie, K.R. and Ernest, J.T.** 1979. Immune complex deposition in the eye in systemic lupus erythematosus. *Arch. Intern. Med.* **139**: 1312–1313.
3. **Bishko, F.** 1971. Retinopathy in systemic lupus erythematosus. A case report and review of the literature. *Arthritis Rheum.* **15**: 57–63.
4. **Cinefro, R.J. and Frenkel, M.** 1978. Systemic lupus erythematosus presenting as optic neuritis. *Ann. Ophthalmol.* **10**: 559–563.
5. **Coppeto, J. and Lessell, S.** 1977. Retinopathy in systemic lupus erythematosus. *Arch. Ophthalmol.* **95**: 794–797.
6. **Dougal, M.A., Evans, L.S., McClellan, K.R. and Robinson, J.** 1983. Central retinal artery occlusion in systemic lupus erythematosus. *Ann. Ophthalmol.* **15**: 38–40.
7. **Gold, D.H., Morris, D.A. and Henkind, P.** 1972. Ocular findings in systemic lupus erythematosus. *Br. J. Ophthalmol.* **56**: 800–804.
8. **Gold, D., Feiner, L. and Henkind, P.** 1977. Retinal arterial occlusive disease in systemic lupus erythematosus. *Arch. Ophthalmol.* **95**: 1580–1585.
9. **Graham, E.M., Spalton, D.J., Barnard, R.O., Garner, A. and Russell, R.W.R.** 1985. Cerebral and retinal vascular changes in systemic lupus erythematosus. *Ophthalmology* **92**: 444–448.
10. **Jabs, D.A., Fine, S.L., Hochberg, M.C., Newman, S.A., Heiner, G.G. and Stevens, M.B.** 1986. Severe retinal vaso-occlusive disease in systemic lupus erythematosus. *Arch. Ophthalmol.* **104**: 558–563.
11. **Kayazawa, F. and Honda, A.** 1981. Severe retinal vascular lesions in systemic lupus erythematosus. *Ann. Ophthalmol.* **13**: 1291–1294.
12. **Lanham, J.G., Barrie, T., Kohner, E.M. and Hughes, R.V.** 1982. SLE retinopathy, evaluation by fluorescein angiography. *Ann. Rheum. Dis.* **41**: 473–478.
13. **Laroche, L. and Saraux, H.** 1984. Unilateral central retinal vein occlusion in systemic lupus erythematosus. *Ophthalmologica* **189**: 128–129.
14. **Little, H.L.** 1988. Photocoagulation of vascular disease. p. 1071–1091. *In* S.R. Walt, R.H. Keates, C.S. Hoyt, B.R. Frueh, J. Herschler and D.M. Carroll (eds.), *Surgery of the Eye*, Churchill Livingstone, New York.
15. **Silverman, M., Lubeck, M.J. and Briney, W.G.** 1978. Central retinal vein occlusion complicating systemic lupus erythematosus. *Arthritis Rheum.* **21**: 839–843.
16. **Tan, E.M., Cohen, A.S., Fries, J.F., Masi, A.T., McShane, D.J., Rothfield, N.F., Schaller, J.G., Talal, N. and Winchester, R.J.** 1982. The 1982 revised criteria for the classification of systemic lupus erythematosus. *Arthritis Rheum.* **25**: 1271–1277.
17. **Terhorst, D.R., Campo, R.V. and Abrams, G.W.** 1983. Unilateral systemic lupus erythematosus retinopathy. *Am J. Ophthalmol.* **95**: 840–841.
18. **Vine, A.K. and Barr, C.C.** 1984. Proliferative lupus retinopathy. *Arch. Ophthalmol.* **102**: 852–854.
19. **Wong, K., Ai, E., Jones, J.V. and Young, D.** 1981. Visual loss as the initial symptom of systemic lupus erythematosus. *Am. J. Ophthalmol.* **92**: 238–244.