

Rupture of Pararenal Pseudocyst in a Patient with Down's Syndrome

Koichi ISHIGAME¹⁾, Machiko KAWAMURA¹⁾, Takashi SATO¹⁾, Norio KUBO¹⁾, Kazuo KIDANI¹⁾, Noriaki SANDA²⁾, Chikao MASU²⁾ and Yoshikazu NISHI³⁾

1)Department of Pediatrics, Chugoku Rosai Hospital, 1-5-1 Hirotagaya, Kure-shi, Hiroshima 737-01, Japan

2)Department of Urology, Chugoku Rosai Hospital, Kure-shi, Hiroshima 737-01, Japan

3)Department of Pediatrics, Hiroshima Red Cross Hospital, 1-9-6 Senda-machi, Naka-ku, Hiroshima 730, Japan

ABSTRACT

A rare case of Down's syndrome with spontaneous rupture of a pararenal pseudocyst has been reported. The rupture of the pararenal pseudocyst was treated nonsurgically. The presence of this cyst in conjunction with Down's syndrome may be due, in part, to muscular hypotonia.

Key words: Pararenal pseudocyst, Down's syndrome

Pararenal pseudocyst is an uncommon condition caused by renal trauma, in which there is an encysted collection of urine lying outside the renal pelvis and parenchyma. Following a tear in the renal pelvis or upper ureter, treatment is determined according to the status of the renal parenchyma and/or ureter. The two main choices are those of drainage or partial nephrectomy. We report here the rare association of an apparent spontaneous rupture of a kidney and development of a pararenal pseudocyst in an infant with Down's syndrome.

CASE REPORT

The patient, a one month old girl with Down's syndrome (47, xx chromosomes) was admitted to our hospital for evaluation of poor suck, vomiting, and tachypnea. There was no history of trauma or urinary symptoms. She had no fever. Her pulse rate was 150/min, blood pressure 75/50 mmHg and respiration 60/min. The hemoglobin was 15.1 g/dl and the white blood cell count was 10,300/mm³. A midstream urine sample showed low specific gravity (1.005) and was without protein or bacteria. Pertinent laboratory results were: blood urea nitrogen, 114 mg/dl; creatinine, 4.9 mg/dl; potassium, 8.3 mEq/L; sodium, 121 mEq/L; serum total protein, 7.5 g/dl, and CRP, 0.3 mg/dl. The chromosome analysis was 21 trisomy (47, xx). A chest x-ray showed an abnormal large shadow on the right side. A thoracentesis was performed and 82 ml of fluid was aspirated, greatly reducing the size of the abnormal x-ray finding. The aspirate contained protein 92 mg/dl and 200 red blood cells per high power field in the sediment and was sterile. An ultrasonic examination revealed bilateral hydronephrosis with thin matrix and enlarged pelvis. A renal CT scan revealed bilateral hydro-

nephrosis and a collection of fluid surrounding the right kidney by excretory urogram (Fig. 1. A).

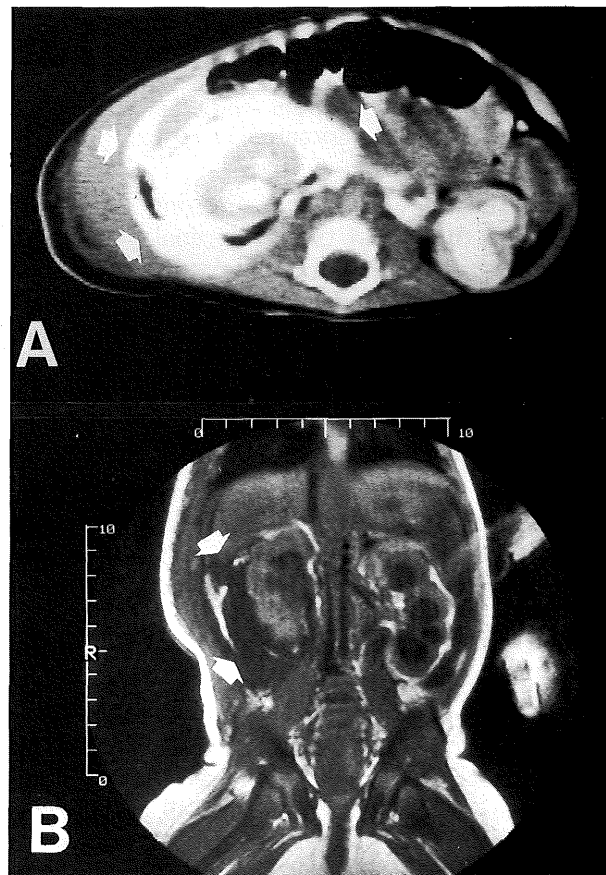


Fig. 1. A. Renal CT scan shows a collection of fluid surrounding the right kidney (arrow) by excretory urogram.

B. Coronal magnetic resonance imaging (MRI) shows the rupture of the right renal pseudocyst (arrow) and urinary leakage.

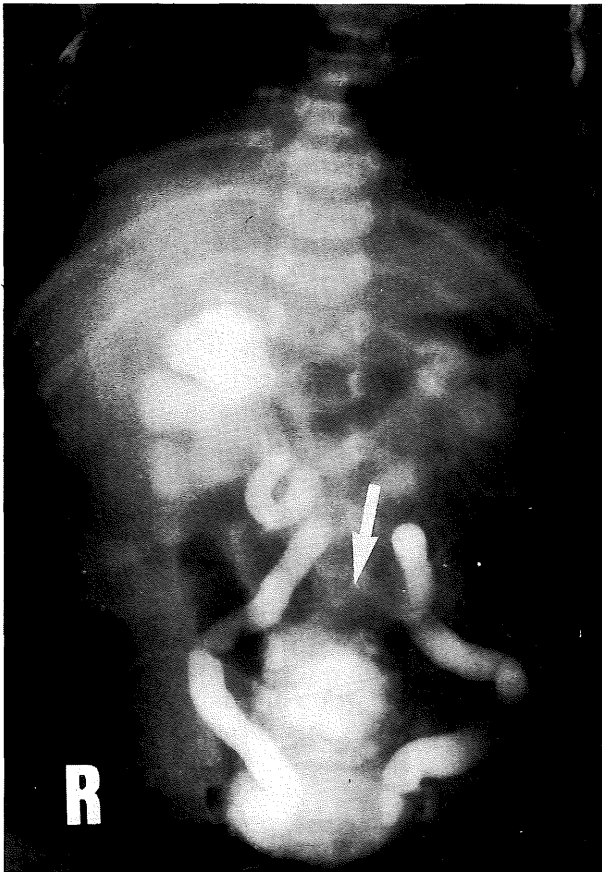

Fig. 2. Retrograde cystogram shows the deformity of bladder (arrow) and vesicoureteral reflux.

Coronal magnetic resonance imaging (MRI) confirmed the rupture of the right renal parenchyma and the presence of a pararenal pseudocyst and urinary leakage (Fig. 1. B). A retrograde cystogram showed a neurogenic bladder and vesicoureteral reflux (VUR) with deformity of the bladder (Fig. 2). A trochar and cannula were inserted into both the bladder and the renal pelvis and 1,000 ml of amber fluid was aspirated. Having thus deflated the bladder and cyst, it became apparent that both kidneys were mesh-like and the left kidney functioned poorly. The patient has been free of any leakage for one year and is now improving in health.

DISCUSSION

Pararenal pseudocyst is now recognized as a perinephric extravasation of urine. The clinical entity was named by Sauls and Nesbit³⁾ and the pathogenesis of this condition has been well discussed. In 1972, Arnold reviewed 43 cases including one of his own investigation¹⁾. A history of trauma was observed in 39/43 cases (90%). Of the 4 cases without a history of trauma, spontaneous rupture of the pelvis was reported in the case of a 15-month-old child. Spontaneous rupture of the

kidney is rare and always associated with chronic renal disease such as urinary tract stone. The time intervals from injury to presenting complaints ranged from 3 weeks to 5 months and it was emphasized that the duration after the formation of the pseudocyst and the degree of the injury were important factors in the fate of the kidney⁵⁾. It was also found that progressive hydronephrotic atrophy of the kidney might follow within a few weeks or months¹⁾. Razzaboni succeeded in creating a traumatic pseudocyst in animals from the 1st day to the 62nd day after experimental injury to the ureter²⁾.

In the present case the VUR was secondary to a neurogenic bladder which is indeed the most frequent cause of reflux. Perinephric extravasation of urine, secondary to reflux, might produce a fibroblastic response with subsequent formation of a pararenal pseudocyst with a well developed wall. Since our patient was only one month old the pararenal pseudocyst was considered to be congenital in origin. According to Sullivan, Purcell, and Gregory, radiological follow-up showed that improvement of pediatric VUR occurred in 48% of cases treated by catheterization and in 100% of cases treated by reimplantation of ureters⁴⁾. We observed and successfully prevented upper urinary tract infection by intermittent catheterization and conservative management.

A number of characteristic features have been reported in patients with Down's syndrome but renal complication is uncommon. To our knowledge this is the first case reported. The cause of the unusual complication of a pseudocyst in conjunction with Down's syndrome can not be fully explained, but it would appear to relate to muscular hypotonia of this syndrome or pararenal lesion of an uncertain nature.

(Received October 18, 1990)

(Accepted January 30, 1991)

REFERENCES

1. **Arnold, E.P.** 1972. Pararenal pseudocyst. *Brit. J. Urol.* **44**: 40-46.
2. **Razzaboni, G.** 1922-23. Ricerche sperimentali sulla pseudo-idronefrosi. *Arch. Ital. Chir.* **6**: 365-403.
3. **Sauls, C.L. and Nesbit, R.M.** 1962. Pararenal pseudocysts: A report of four cases. *J. Urol.* **87**: 288-296.
4. **Sullivan, T., Purcell, M.M. and Gregory, J.G.** 1981. The management of vesicoureteral reflux in the pediatric neurogenic bladder. *J. Urol.* **125**: 65-66.
5. **Thompson, I.M., Ross, G.Jr., Ezzard, J., Habib, H. and Amoury, R.A.** 1976. Experiences with 16 cases of pararenal pseudocyst. *J. Urol.* **116**: 289-292.