

Granular Cell Tumor of the Breast: Report of a case

Toshihiko KOHASHI¹⁾, Tsuyoshi KATAOKA¹⁾, Rumi HARUTA¹⁾, Keizo SUGINO¹⁾,
Seiji MARUBAYASHI¹⁾, Hiroshi YAHATA¹⁾, Toshimasa ASAHARA¹⁾, Seiji FUJII²⁾,
Koji ARIHIRO²⁾ and Kiyohiko DOHI¹⁾

1) Second Department of Surgery, Hiroshima University School of Medicine, 1-2-3 Kasumi, Minami-ku, Hiroshima 734-8551, Japan

2) Second Department of Pathology, Hiroshima University School of Medicine, 1-2-3 Kasumi, Minami-ku, Hiroshima 734-8551, Japan

ABSTRACT

A case of granular cell tumor of the breast in a 43-year-old woman is described. The patient presented with a painless mass in the upper-outer quadrant of her right breast. Mammography showed a spiculated tumor and ultrasonography demonstrated a hypoechoic mass with an irregular border. Magnetic resonance (MR) mammography revealed a homogeneous enhanced mass in T1-weighted images using Gd-DTPA and a ringed high-intensity area around the mass in T2-weighted images. Fine-needle aspiration cytology failed to show any malignant cells. A partial resection of the breast was performed and histological examination revealed a granular cell tumor.

Granular cell tumors are generally always benign, but they may be misdiagnosed as malignant tumors because of their mammographic and ultrasonographic findings. MR mammography did not reveal a typical breast cancer in either T1- or T2-weighted images in the present case. This case illustrates the need for care in preoperative examinations in order to avoid overdiagnosis of breast cancer.

Key words: Granular cell tumor, Breast tumor, Magnetic resonance mammography

The granular cell tumor is an uncommon benign tumor that may occur in a wide variety of cutaneous and visceral sites, but does not commonly involve the breast. However, this tumor may be misdiagnosed as a malignant breast tumor because of its physical, mammographic and ultrasonographic features.

The magnetic resonance (MR) mammography findings of granular cell tumors have been reported in only one case previously. Therefore, we present the MR mammographic findings of another case of granular cell tumor of the breast, including the data obtained from more detailed examinations.

CASE REPORT

A 43-year-old Japanese woman presented with a painless mass in the upper-outer quadrant of her right breast. Physical examination revealed a hard tumor, 2 cm in diameter, without fixation to the skin or the pectoral muscle. There was no swelling of the regional lymph nodes.

Mammography showed a spiculated mass without microcalcification, measuring $1.8 \times 1.7 \times 1.6$ cm (Fig. 1). Ultrasonography revealed a hypoechoic mass with an irregular border (Fig. 2). Doppler echo showed three vessels with high blood flow into the tumor, suggesting tumor hyper-vascularity. Fat-suppressed MR mammography

revealed a homogeneous enhanced mass with spiculation in T1-weighted images using Gd-DTPA

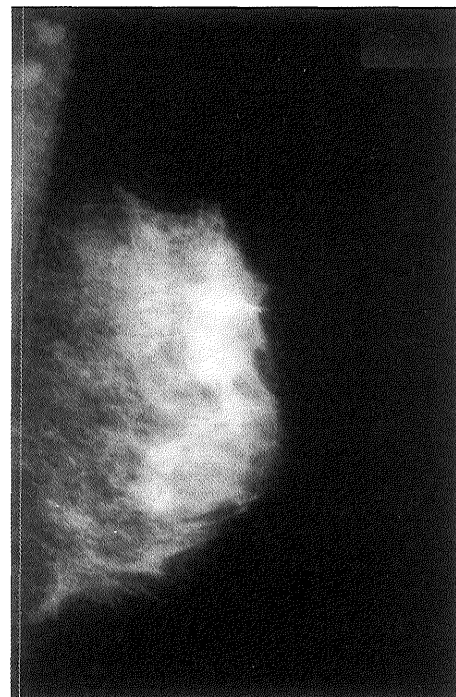


Fig.1. Mammography showed a spiculated mass without microcalcification in the upper-outer quadrant of the right breast.

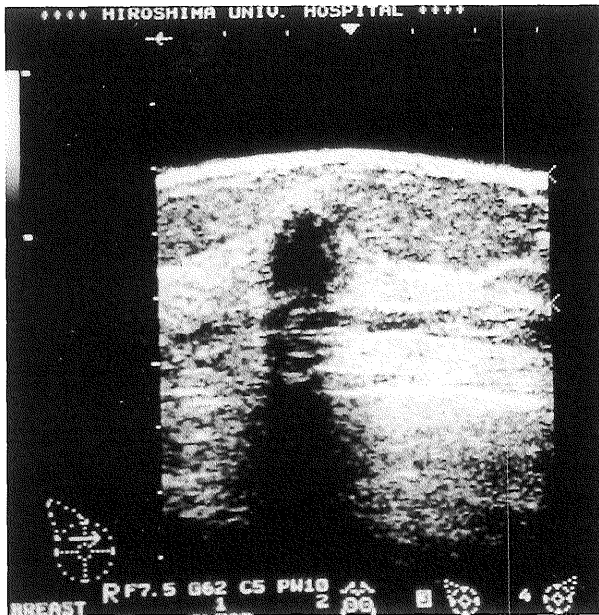


Fig. 2. Ultrasonography showed a hypoechoic mass with an irregular border.

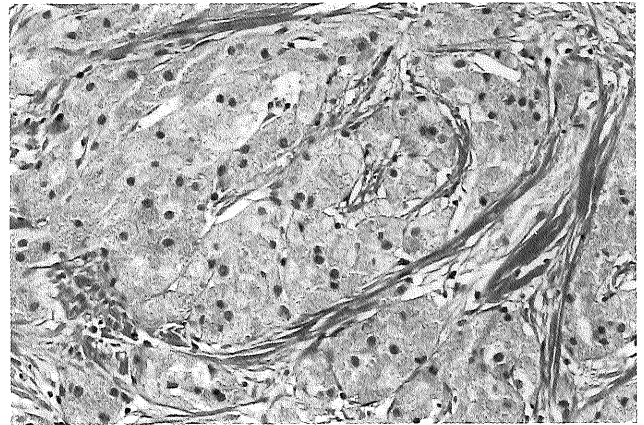
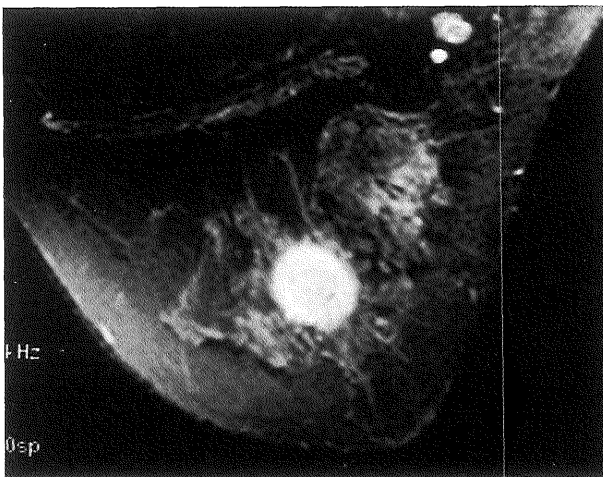
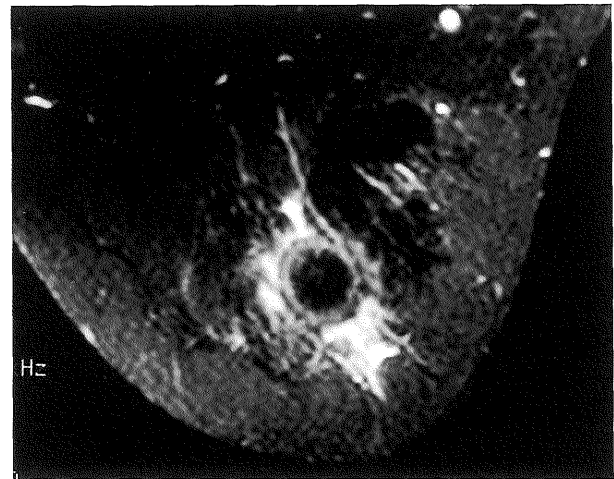


Fig. 4. Histological examination revealed many large eosinophilic cells with abundant granular cytoplasm.



3a

Fig. 3a. T1WI MR mammography enhanced by Gd-DTPA showed a homogeneous enhanced mass with spiculation.



3b

Fig. 3b. T2WI MR mammography showed a mass with a ringed high-intensity area.

(Fig. 3a) and a ringed high-intensity area around the mass in T2-weighted images (Fig. 3b).

The serum level of carcinoembryonic antigen (CEA) and carbohydrate antigen 15-3 (CA15-3) were both within the normal range at 1.0 ng/ml and 8.4 U/ml, respectively. Physical examination, mammography and ultrasonography findings suggested breast cancer, but the MR mammography data led us to suspect an uncommon neoplasm of the breast. Furthermore, fine-needle aspiration cytology showed a large number of apocrine-like cells but failed to show any malignant cells.

We diagnosed this tumor as a breast cancer and performed a partial resection of the breast, but did not dissect the axillary lymph nodes because frozen sections suggested a benign tumor, most

probably a granular cell tumor of the breast.

Histological examination revealed many large eosinophilic cells with abundant granular cytoplasm which were separated by thin, fibrotic tissue. The tumor cells infiltrated the adjacent fat tissue, but there were no features of malignancy, and therefore the tumor was diagnosed as a benign granular cell tumor (Fig. 4).

DISCUSSION

The granular cell tumor was first described by Abrikossoff in 1926 as a "myoblastic myoma"¹⁾. This tumor occurs commonly in the tongue, oral cavity, skin and subcutaneous tissue⁶⁾. However, 4.6% of all cases arise in the breast⁴⁾. These rare tumors account for about one in every 1000 breast

cancers⁵). The origin of this tumor from the Schwann cell is now generally accepted, based primarily on its immunohistochemical positivity for S-100 protein².

Mammography reveals an ill-defined density with tendril-like extensions into the adjacent mammary tissue. These features are highly suspicious of malignancy⁴. In the present case, mammography demonstrated a spiculated mass without microcalcification.

The ultrasonographic features of this tumor have rarely been described in detail. Ohnishi et al reported two cases that were demonstrated as an ill-defined, solid mass with an acoustic shadow, and a hypoechoic mass with a large width-depth ratio⁷. However, Scatarige et al considered that an acoustic shadow was clearly not a sign specific for breast malignancy¹⁰. Our tumor was imaged as an irregular, hypoechoic mass with an acoustic shadow.

Mammography and ultrasonography suggested a malignant tumor, but aspiration cytology failed to show malignant cells. Placidi et al reported that the cells of this tumor were immunostained for S-100 protein and CD 68 (Kp-1)⁹. In addition, Sirgi et al demonstrated that apocrine metaplasia may appear coarsely granular, resembling the appearance of granular cell tumor, and that immunostaining for CD 68 (Kp-1) is useful for discriminating apocrine metaplasia from other granular cell lesions¹¹. In the present case, the cells of the tumor were immunostained for S-100 protein diffusely but we did not use CD 68 (Kp-1).

MR mammography in the present case showed a spiculated, homogeneous mass in fat-suppressed T1-weighted images with Gd-DTPA and a ring-enhanced mass in T2-weighted images. The former suggested hypervascularity, and the latter the presence of a capsule around the tumor. These findings did not indicate malignancy, although the presence of spicula suggested that the tumor had infiltrated the adjacent mammary tissue. Okada et al reported the use of dynamic MR mammography to distinguish between benign and malignant breast tumors⁹, but we did not perform this technique.

As the granular cell tumor is almost always benign, partial resection of the breast is a sufficient treatment, and total mastectomy would be regarded as over-treatment. However, some cases of malignant granular cell tumor have been reported previously³. Therefore postoperative histological diagnosis should be done carefully.

In summary, the clinical findings of granular cell tumor of the breast are similar to those of breast

cancer. MR mammography may be an essential preoperative examination. It is necessary to diagnose this tumor accurately on the basis of MR mammographic findings and cytology and to avoid oversurgery.

(Received November 30, 1998)

(Accepted February 12, 1999)

REFERENCES

1. **Abrikossof, A.** 1926. Uber Myome, ausgehand von der quergestreiften willkurlichen Muskulature. *Virchows. Archiv. A. Pathol. Anat.* **260**: 215-235.
2. **Armin, A., Connelly, E.M. and Rowden, A.** 1983. An immunoperoxidase investigation of S-100 protein in granular cell myoblastoma: Evidence for Schwann cell derivation. *Am. J. Clin. Pathol.* **79**: 37-44.
3. **Chetty, R. and Kalan, M.R.** 1992. Malignant granular cell tumor of the breast. *J. Surg. Oncol.* **49**: 135-137.
4. **Damiani, S., Koerner, F.C., Dickersin, G.R., Cook, M.G. and Eusebi, V.** 1992. Granular cell tumor of the breast. *Virchows. Archiv. A. Pathol. Anat.* **420**: 219-226.
5. **Gordon, A.B., Fisher, C., Palmer, B. and Greening, W.P.** 1985. Granular cell tumour of the breast. *Eur. J. Surg. Oncol.* **11**: 269-273.
6. **Khansur, T., Balducci, L. and Tavassoli, M.** 1987. Granular Cell Tumor. *Clinical Spectrum of the Benign and Malignant Entity. Cancer* **60**: 220-222.
7. **Ohnishi, H., Nishihara, K., Tamae, K., Mitsuyama, S., Abe, R., Toyoshima, S. and Abe, E.** 1996. Granular cell tumors of the breast: A case report of two cases. *Surg. Today (Jpn.J.Surg.)* **26**: 929-932.
8. **Okada, K., Ozeki, K., Ishida, T., Isomoto, I., Matsuo, T. and Mochinaga, N.** 1988. Granular cell tumor of the breast: A case report describing dynamic MR mammography. *Breast Cancer* **5**: 179-182.
9. **Placidi, A., Aversa, A., Foggi, C.M., Foggi, P., Ricci, G. and Salvatori, V.** 1995. Granular cell tumor of breast in young man preoperatively diagnosed by fine needle aspiration (FNA) cytology. *Cytopathology* **6**: 343-348.
10. **Scatarige, J.C., Hsiu, J.G., Torre, R., Cramer, M.S., Siddiky, M.A. and Jaffe, A.H.** 1987. Acoustic shadowing in benign granular cell tumor (myoblastoma) of the breast. *J. Ultrasound. Med.* **6**: 545-547.
11. **Sirgi, K.E., Sneige, N., Fanning, T.V., Fornage, B.D., Ordonez, N.G. and Swanson, P.E.** 1996. Fine-needle aspirates of granular cell lesions of the breast: Report of three cases, with emphasis on differential diagnosis and utility of immunostaining for CD68 (KP1). *Diagn. Cytopathol.* **15**: 403-408.