

Treatment of Iliac Artery Rupture During Percutaneous Transluminal Angioplasty: A report of three cases

Katsutoshi SATO^{1,*}, Kazumasa ORIHASHI², Yoshiharu HAMANAKA¹,
Shinji HIRAI¹, Norimasa MITSUI¹ and Naru CHATANI¹

1) Department of Thoracic Surgery, Hiroshima Prefectural Hospital, Hiroshima, Japan

2) Department of Cardiovascular Surgery, Hiroshima University Hospital, Hiroshima, Japan

ABSTRACT

We report three cases of iliac artery rupture during percutaneous transluminal angioplasty (PTA). In all three cases, bleeding was temporarily controlled by inflating an angioplasty balloon at the site of bleeding. Two patients underwent subsequent surgical revascularization, and one underwent endovascular stent grafting but ultimately required a surgical bypass. Arterial rupture is a rare but potentially fatal complication of PTA. Although stent grafts for peripheral arteries are not yet covered by Japanese medical insurance, it is a useful treatment for arterial injury during PTA.

Key words: Percutaneous transluminal angioplasty; PTA, Iliac artery rupture, Stent graft

The Trans-Atlantic Inter-Society Consensus (TASC) II⁹ recommends percutaneous transluminal angioplasty (PTA) for treatment of type A and B lesions in the iliac artery. Although the indications for PTA have been expanded to include chronic iliac artery occlusion, and early results have been favorable⁷, the risk of complications may increase with PTA of this artery. If arterial rupture occurs, emergency treatment is required. We report three cases of iliac artery rupture caused by PTA that occurred in our hospital in the past 12 years, and discuss the management of this complication.

CASES

Case 1

An 86-year-old female with a previous history of angina pectoris and cerebral infarction suffered from non-healing foot ulcers caused by chronic total occlusion of the left external iliac artery (EIA), which was type C in the TASC II classification. Owing to these risk factors, PTA was indicated for the surgery.

Under intravenous sedation and local anesthesia, a guide wire (0.014 inch, Cruise™, St. Jude Medical, St. Paul, MN) was successfully passed through the occluded lesion via the right common femoral artery (CFA). Following pre-dilatation of the EIA with a PTA balloon (5 mm by 20 mm: Fox Plus™, ABBOTT Vascular, Chicago, IL), a stent (8 mm

by 100 mm: SMART CONTROL™, Cordis, Miami Lakes, FL) was deployed. After post-dilatation with the balloon up to 15 atm, the systemic blood pressure suddenly dropped and arteriography revealed extravasation of contrast media around the EIA. Hemodynamic stability was restored by rapid intravenous fluid infusion and total obliteration of the bleeding site by a long PTA balloon (8 mm by 80 mm, manufacturer as above) at 2 atm. She was immediately transferred to the operating room with the balloon catheter in place.

Under general anesthesia, a mid-abdominal incision was made, and the left EIA was exposed. There was a longitudinal tear of the EIA (20 mm long), through which the inflated balloon catheter and stent were visible. Replacement of the EIA with a vascular prosthesis was difficult due to severe calcification, so the EIA was ligated proximally and distally followed by a femoro-femoral bypass with a 6 mm vascular prosthesis (Gelsoft™, VASCUTEK, Scotland, UK). She recovered well postoperatively, and there was adequate healing of her foot ulcers (Fig. 1).

Case 2

A 70-year-old male with a previous history of angina pectoris and transient ischemic attack suffered from claudication and underwent PTA to treat chronic occlusion of his left EIA, which was type C in the TASC II classification, due to these

* Corresponding Author: Katsutoshi Sato

Address: 1-5-54 Ujinakanda, Minami-ku, Hiroshima 734-8530, Japan

Tel: +81-82-254-1818, Fax: +81-82-253-8274, E-mail: satoktts@hiroshima-u.ac.jp

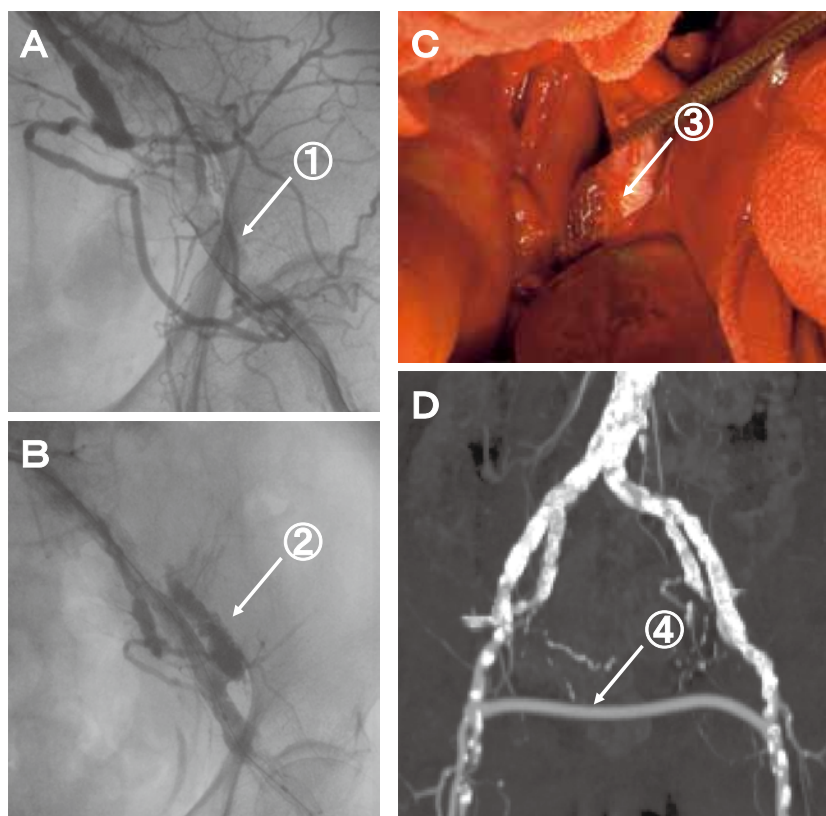


Fig. 1. Diagnostic images and findings in Case 1.

A: Arteriogram showing total occlusion of left external iliac artery (arrow 1). B: Extravasation of contrast media following deployment of stent (arrow 2). C: A 20 mm longitudinal tear at the external iliac artery (arrow 3). D: Postoperative computed tomogram demonstrating patent femoro-femoral bypass (arrow 4).

risk factors for the surgery.

Under local anesthesia, a guide wire (0.014 inch, Transend™, Boston Scientific, Natick, MA) was advanced through the occluded portion from the right CFA. The EIA was dilated with a PTA balloon (8 mm by 40 mm: Sub-4™, Meditech, Westwood, MA) up to 8 atm. At this point, the patient complained of severe left lower back pain and became hypotensive. Arteriography showed extravasation of contrast media around the EIA. Bleeding was temporarily blocked by reinflation of the angioplasty balloon to 2 atm, and he was immediately transferred to the operating room.

Under general anesthesia, the left EIA was approached through a retroperitoneal incision. Because the tear was difficult to repair due to substantial calcification around the rupture site, the injured portion was excised; and a bypass was performed from the left common iliac artery (CIA) to the EIA with an 8 mm vascular prosthesis (Gelsoft™, VASCUTEK, Scotland, UK). After the operation, the patient recovered without complications.

Case 3

A 76-year-old male patient was scheduled for carotid artery stenting (CAS) for a severe stenosis in

the internal carotid artery causing recurrent ischemic attacks. Under local anesthesia, a 9-Fr sheath (25 cm, XEMEX Introducer™, Zeon Medical, Tokyo, Japan) was inserted from the right CFA. Due to severe stenosis, it could not be passed through the right EIA, which was type A in the TASC II classification. A stent (10 mm by 60 mm: SMART CONTROL™, Cordis, Miami Lakes, FL) was placed in the stenotic lesion and was post-dilated with a PTA balloon (9 mm by 40 mm: Submarine Plus™, INVATEC, Roncadelle, Italy) up to 9 atm. However, the patient became hypotensive and complained of severe right lower back pain. Angiography showed extravasation of contrast media around the EIA. Bleeding was instantly controlled by reinflation of the angioplasty balloon to 1 atm, and intravenous fluid infusion restored hemodynamic stability. Fifty mg of carbazochrome sodium sulfonate hydrate (ADONA Injection™, Mitsubishi Tanabe Pharma Corporation, Osaka, Japan) was administered, and the balloon remained inflated for 10 min. However, subsequent angiography revealed extravasation of contrast media.

We obtained informed consent for the off-label use of self-expandable stents covered with silicon (Covered Biliary Wallstent™, Boston Scientific,

Natick, MA³). A PTA balloon (9 mm by 20 mm: Submarine Plus™, INVATEC, Roncadelle, Italy) was inserted from the left CFA, and the right CIA was occluded proximally. Following removal of the previous balloon catheter, covered stent grafts (10 mm by 80 mm and 40 mm: Covered Biliary Wallstent™, Boston Scientific, Natick, MA) were deployed from the right CIA to the EIA. Subsequent arteriography showed patent arteries without extravasation of contrast media. Although the internal iliac artery was occluded, he had no symptom related to it. CAS was postponed due to this event.

He had received 200mg of ticlopidine (Panaldine™; sanofi-aventis K.K., Tokyo, Japan) and 100 mg of aspirin (Bayaspirin™; Bayer Health Care, Osaka, Japan), orally every day. Two mg of warfarin potassium (Warfarin™; Eisai Co., Ltd. Tokyo, Japan) was added postoperatively. Four days later, however, the patient complained of pain at rest in his right leg. Arteriography was performed via right CFA access and revealed thrombosis in the entire portion of covered stent grafts. We aspirated the thrombus and administered urokinase via continuous infusion into the stent graft for three days, but there was incomplete resolution of the thrombus.

Under general anesthesia, he underwent femoro-femoral bypass with an 8 mm vascular prosthesis (Gelsoft™, VASCUTEK, Scotland, UK). He had a good postoperative course without complications. Computed tomography revealed occlusion of the stent graft, but the distal arteries and femoro-femoral bypass graft were patent (Fig. 2).

DISCUSSION

Arterial perforation or rupture following PTA and stenting for the iliac artery is rare, occurring in only 0.3% or 0.4% of cases, respectively¹⁰. We experienced 3 cases of iliac artery rupture among a total of 599 cases in the last 12 years (0.5%), a comparable percentage to those reported in the literature.

Since it is difficult to predict such a rare event, it is important to take practical measures to prevent vascular injury. In case 1, intraoperative inspection revealed that the stent was deployed in the subintimal space (Fig. 1C). Intravascular ultrasound (IVUS) might have been helpful for visualizing the vascular structure⁶, directing the guide wire into the true lumen and determining the optimal size of the angioplasty balloon and stent². In case 3, the size of balloon was determined according to the size of the artery. However, disruption of the severely calcified wall might have led to extravasation despite the fact that the balloon was not excessively large. In these lesions, staged expansion in vascular size might have been useful to prevent the arterial rupture.

However, rupture can occur despite careful procedures. Although surgical treatment was eventually successful in all three cases, we are not satisfied with the strategies in this series. An increasing number of patients who undergo PTA and/or stenting are older, are receiving anti-coagulant or antiplatelet therapy or have a history of laparotomy for other diseases. In such situations, surgical repair of vascular injury⁴ is not necessarily the optimal strategy.

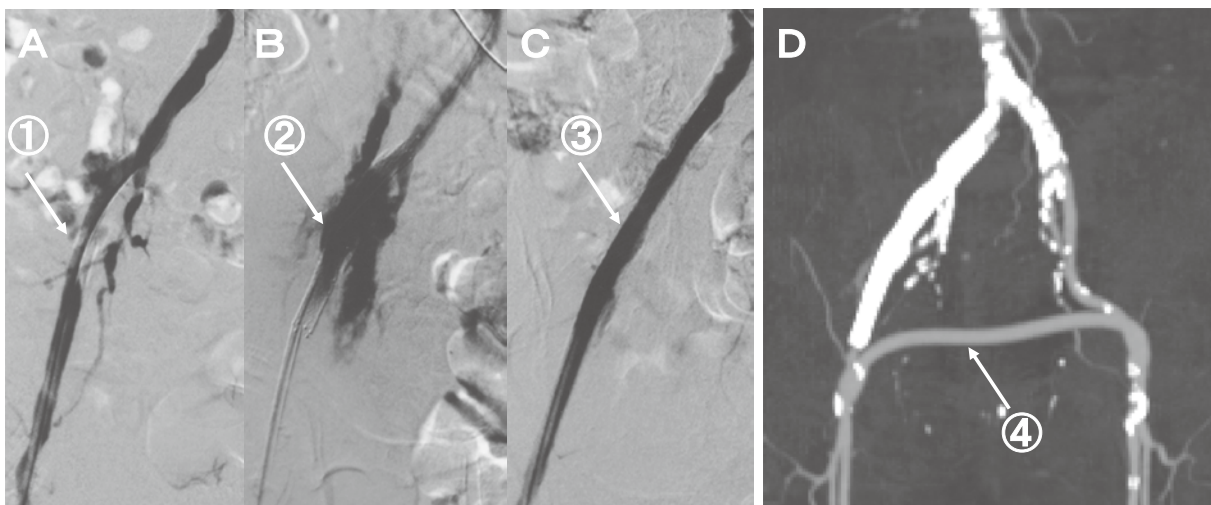


Fig. 2. Diagnostic images and findings in Case 3.

A-C: Serial arteriogram showing severe stenosis in the external iliac artery (arrow 1), extravasation of contrast media following PTA (arrow 2) and stent-grafting (arrow 3). D: Postoperative computed tomogram demonstrating patent femoro-femoral bypass (arrow 4).

Recently, endovascular stent grafting has been reported to seal the rupture site in the iliac artery and maintain blood flow¹⁰. In cases 1 and 2, balloon occlusion was effective to minimize bleeding until the iliac artery was exposed. Although Joseph et al reported that balloon occlusion was sufficient for permanent hemostasis⁹, additional measures such as surgical repair may be necessary in cases of major rupture. Case 3 demonstrated that the use of stent grafts avoided emergent surgery by successful sealing of the bleeding site. Early occlusion of the stent graft despite adequate anticoagulation was most likely due to the material of the stent graft.

Non-surgical strategies are limited by the availability of devices for treatment. We faced a dilemma in the three cases in this report because stent grafts are not covered by medical insurance, and that forced us to select surgical repair. There are several commercially available stent grafts in Japan such as Niti-S stent (Taewoong Medical, Kyunggi-do, Korea) and Fluency plus Vascular Stent Graft (Bard, Tempe, AZ). Although they have been used as vascular stent grafts in other countries, they are approved only for use in bile ducts in Japan. A part of the stent graft for abdominal aortic aneurysm, such as Excluder (W. L. Gore & Associates, Flagstaff, AZ) or Zenith (Cook, Bloomington, IN), can be used for iliac arteries under the cover of Japanese medical insurance in approved hospitals. Although the use of homemade stent grafts has been reported⁸ (and these may be reimbursed by medical insurance in Japan) it is not practical to stock homemade stent grafts of various sizes for such a rare complication.

Bosiers et al reported the use of a covered stent graft for treating occlusive diseases in the iliac arteries with excellent results¹. If a covered stent graft is primarily used for the PTA of an occluded or severely stenotic lesion with heavy calcification, bleeding can be avoided if the artery is injured.

In the case of high-risk patients who would poorly tolerate a major operation, endovascular treatment is needed. Therefore, the establishment of safe procedures and acute treatment for unexpected vascular injuries is strongly desired.

CONCLUSION

Three cases of iliac artery rupture following PTA and subsequent surgical treatment were reported. A PTA balloon catheter was useful for hemostasis of the arterial rupture during the PTA procedure. The potential benefit of stent grafting to avoid surgical treatment was suggested, although Japanese medical insurance does not yet cover stent grafting in peripheral arteries.

(Received August 23, 2011)

(Accepted September 27, 2011)

REFERENCES

1. **Bosiers, M., Iyer, V., Deloose, K., Verbist, J. and Peeters, P.** 2007. Flemish experience using the Advanta V12 stent-graft for the treatment of iliac artery occlusive disease. *J.Cardiiovasc.Surg.* **48**: 7-12.
2. **Chong, W.K., Cross, F.W. and Raphael, M.J.** 1990. Case report: Iliac artery rupture during percutaneous angioplasty. *Clin. Radiology* **41**: 358-359.
3. **Hausegger, K.A., Thurnher, S., Bodendörfer, G., Zollikofer, C.L., Uggowitzner, M., Kugler, C. and Lammer, J.** 1998. Treatment of malignant biliary obstruction with polyurethane-covered Wallstents. *Am. J.Roentgenol.* **170**: 403-408.
4. **Jensen, S.R., Voegeli, D.R., Crummy, A.B., Turnipseed, W.D., Acher, C.W. and Goodson, S.** 1985. Iliac artery rupture during transluminal angioplasty: treatment by embolization and surgical bypass. *Am. J.Roentgenol.* **145**: 381-382.
5. **Joseph, N., Levy, E. and Lipman, S.** 1987. Angioplasty-related iliac artery rupture: Treatment by temporary balloon occlusion. *Cardiovasc. Intervent.Radiol.* **10**: 276-279.
6. **Kumakura, H., Kanai, H., Araki, Y., Koizumi, A., Kasama, S., Sumino, H. and Ichikawa, S.** 2009. Effects of antiplatelet agents and other factors on neointimal proliferation in iliac artery stenting: Intravascular ultrasound analysis. *Ann. Vasc. Dis.* **2**: 100-108.
7. **Leville, C.D., Kashyap, V.S., Clair, D.G., Bena, J.F., Lyden, S.P., Greenberg, R.K., O'Hara, P.J., Sarac, T.P. and Ouriel, K.** 2006. Endovascular management of iliac artery occlusions: extending treatment to TransAtlantic Inter-Society Consensus class C and D patients. *J.Vasc.Surg.* **43**: 32-39.
8. **Marin, M.L., Veith, F.J., Cynamon, J. Panetta, T.F., Bakal, C.W., Kerr, A. and Parodi, J.C.** 1994. Transfemoral endoluminal repair of a penetrating vascular injury. *J.Vasc.Interv.Radiol.* **5**: 592-594.
9. **Norgren, L., Hiatt, W.R., Dormandy, J.A., Nehler, M.R., Harris, K.A. and Fowkes, F.G.** 2007. Inter-society Consensus for the management of peripheral arterial disease (TASC II). *J.Vasc. Surg.* **45**: S5-67.
10. **Nyman, U., Uher, P., Lindh, M., Lindblad, B., Brunkwall, J. and Ivancev, K.** 1999. Stent-graft treatment of iatrogenic iliac artery perforations: Report of three cases. *Eur.J.Vasc.Endovasc. Surg.* **17**: 259-263.