

## Three-dimensional bone architecture around submerged commercially pure titanium implant after bone healing in monkeys

Limin Guan, Yuuji Sato\*, Masayoshi Wadamoto\*, Kazuhiro Tsuga\*,  
Yasumasa Akagawa\* and Zhi Qing Chen

(Received for publication, March 12, 1997)

### INTRODUCTUION

Since Brånemark et al.<sup>1)</sup> demonstrated bone anchorage termed as osseointegration could be maintained adequately around loaded commercially pure (CP) titanium dental implant, the bony interface of the implant has been well recognized to be the most essential for the predictable long-term success for the implant. This osseointegrated implant has been widely used not only in the field of dentistry but also in orthopedics<sup>2,3)</sup> and otolaryngology<sup>4,5)</sup> and special attention has been paid to clarify the aspect of osseointegration. In terms of clarification of osseointegration, numerous histological and histomorphometrical evaluations with interfacial bony profile and percentage of bone contact length fraction or affinity index have been well reported<sup>4,6-15)</sup>. However, results from these studies have been derived from the analysis of only several two-dimensional histologic specimens and comprehensive knowledge on bone structure around the osseointegrated implant is still lacking.

Recently, initial three-dimensional bony interfaces of hydroxyapatite (HA)-coated osseointegrated implants have been introduced and such interfacial bone was structured to be direct contact to the implant in any directions with some variations<sup>16-18)</sup>. However, these findings are only available for the use of HA-coated implant and there is a need for more detailed information on the

bone structure around the CP titanium implant which has been more commonly used today.

The present study was, therefore, designed to evaluate visually and quantitatively the three-dimensional bone architecture around submerged CP titanium implant after three months of insertion into the edentulous mandible of monkeys without any loading, and to compare the results with those of HA-coated implant previously reported<sup>18)</sup>.

### MATERIALS AND METHODS

Three CP titanium screw implants (Goei Inc., Akitsu-Hiroshima, Japan) were used in this study. Each implant possessed a diameter of 4 mm and a length of 9 mm with one longitudinal groove (1 mm in width and 1 mm in depth) for better bone retention (Fig. 1).

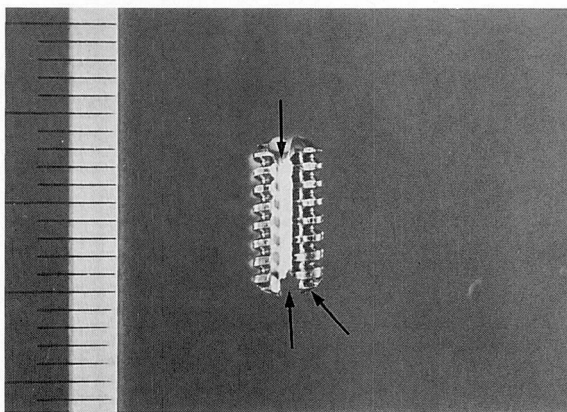
Edentulous area for implant placement was prepared in the mandible of three female adult monkeys (*Macaca fuscata*), where first, second premolars and first molar were extracted and the site was allowed to heal for three months. After 3 months of tooth extraction, an implant was inserted into the edentulous area of each monkey. The insertion site was randomly assigned among 3 monkeys to minimize the different bone quality of the edentulous area among the animals. One implant was inserted at the second premolar and first molar area on the left side (designated as implant # T1), another at the second premolar and first molar area on the right side (designated as implant # T2) and the other at the first and second premolar area on the left side (designated as implant # T3) in three monkeys. The surgical operations were done under intramuscular anesthesia with 5 mg/kg of ketamine hydrochloride, 0.05 mg/kg of atropine sulfate and 0.5 mg/kg of chlorpromazine hydrochloride. A mucoperiosteal flap was raised at the edentulous area and then, a bone threaded socket was made by use of the sequential drills

---

College of Stomatology, West China University of Medical Sciences, Department of Dental Materials (Chairman; Professor Zhi Qing Chen)

\* Hiroshima University School of Dentistry, Department of Removable Prosthodontics (Chairman; Professor Yasumasa Akagawa)

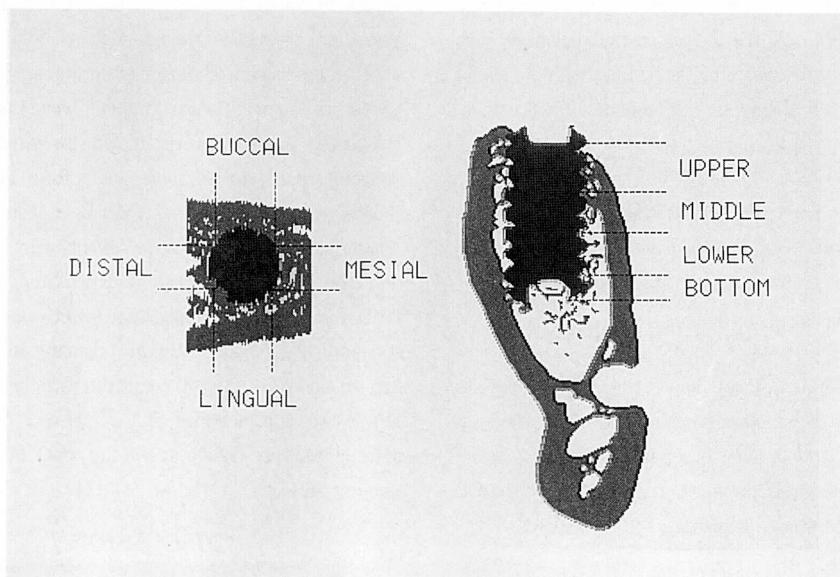
This study was supported by the Ministry of Education, Science and Culture, Japan, grant No. 03454450.



**Fig. 1** A CP titanium screw implant used in this study. It is 4 mm in diameter and 9 mm in length. A longitudinal groove (arrow) and horizontal grooves at the bottom (2 arrows) were designed for better bone retention.

with 1.6 mm, 2.2 mm, 3.1 mm and finally threaded by a manual screw-stock with a diameter of 3.8 mm. To minimize surgical trauma to the bone tissue, low speed and pressure on the drilling instrument and outer cooling with physiologic saline were applied during bone preparation. The implant was inserted into the threaded socket by manual tapping and then this was completely covered by oral mucosa. After three months of implant insertion, the animals were perfused with 10% neutral formalin and then the mandibles were removed. The tissue block

containing the implant was dehydrated through a series of graded ethanol and cleared with styrene monomer and embedded in polyester resin (Rigolac resin, Oken, Tokyo). The block was trimmed at 1 mm from the mesio-distal implant surface and the distal surface of the block was glued to the plastic plate for placement fixation. The block was then ground automatically at 75  $\mu$ m intervals in the bucco-lingual direction by use of a grinding machine (Exakt Micro-Grinding System, Exakt Apparatebau, Norderstedt, Germany). Then each ground surface



**Fig. 2** Computer graphics of bone and a CP implant. A graphic (left) is illustrated at four portions in horizontal direction and a graphic (right) at four portions in bucco-lingual direction. Note that osseointegration is achieved around the implant surface with some variations.

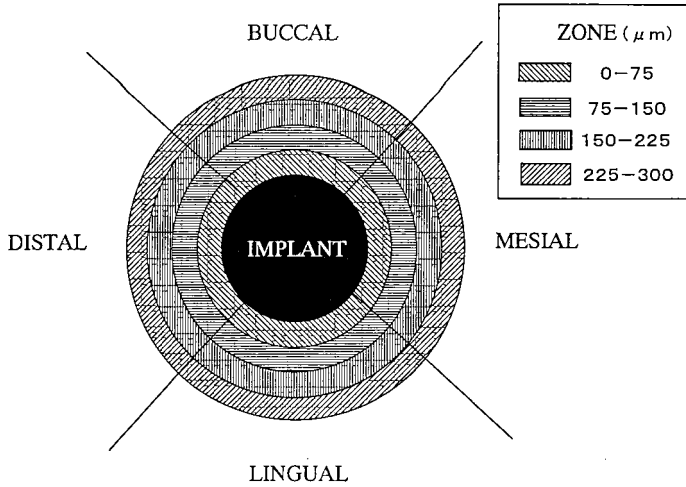


Fig. 3 Four zones for the calculation of the bone volume ratio around the implant. The zone is  $300\ \mu\text{m}$  apart from the surface of the implant with an interval of  $75\ \mu\text{m}$ .

was stained with toluidine blue and placed on a profile projector (V-16E, Nikon, Tokyo). Bone architecture around the implant was traced at a magnification of  $\times 10$  and each trace was digitized on the digitizer (Gradimate SQ-3000, OSCON, Osaka). This procedure was repeated to obtain total 80 figures of ground surface. After completion of this procedure, these figures were serially accumulated in the computer to produce three-dimensional (3D) computer graphics by use of originally programmed software.

Sectional graphics in any directions were obtained and the bone contact ratio (BCR) around the implant at each area (Fig. 2) was calculated by the formula with the use of this computerized 3D graphics of bone architecture.

$$\text{BCR} = \frac{\text{area contacted by bone}}{\text{all area of the implant}} \times 100 (\%)$$

The bone volume ratio (BVR) was also calculated to evaluate the bone volume around the implant at the zone  $300\ \mu\text{m}$  apart from the surface of the implant (Fig. 3).

$$\text{BVR} = \frac{\text{volume filled by bone}}{\text{total volume of the zone}} \times 100 (\%)$$

Mann-Whitney U-test was used to analyze the results statistically and these were compared with the values of HA-coated implants previously reported<sup>18)</sup> to evaluate the difference of the interfacial bone structure around the CP titanium and HA-coated implants.

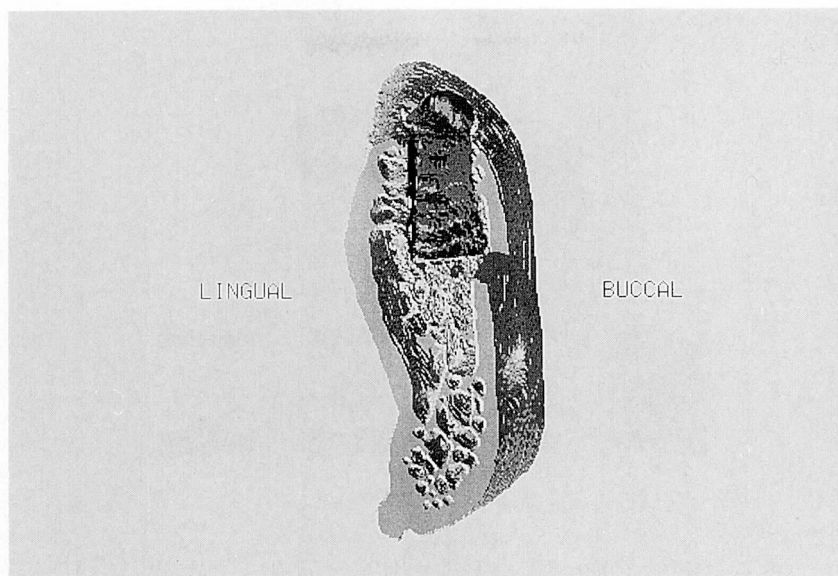
## RESULTS

The three-dimensional graphic of bone architecture around one implant (# T1) is illustrated (Fig. 4). The

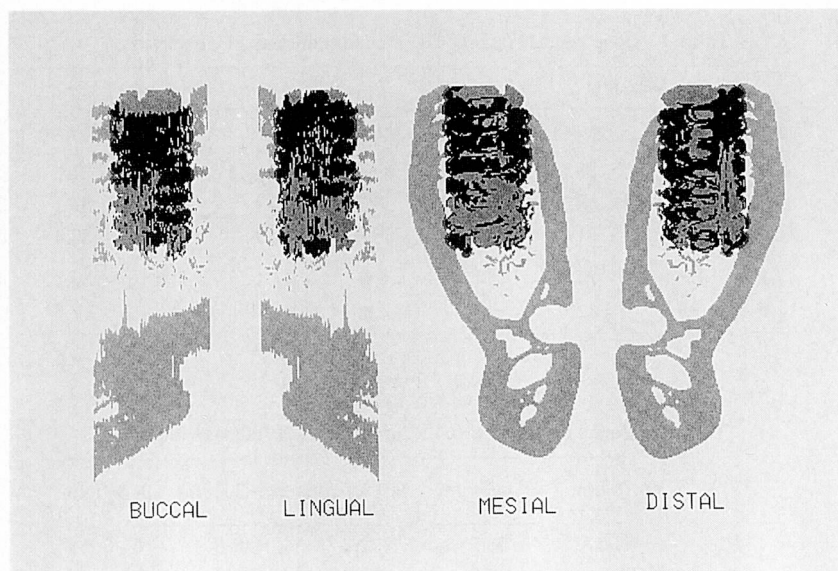
bony architecture around the implant in bucco-lingual, mesio-distal directions and at four horizontal portions are shown respectively (Fig. 5 and 6). Variation of bony contact was quite obvious among directions and portions of the implant. Values of BCR and BVR of each implant are shown in Table 1 and 2. Although differences were detected among the directions and portions in each implant, total BCR values in three implants ranged between 38.0 and 52.0% and total BVR ( $0-300\ \mu\text{m}$ ) did between 51.6 and 57.5%. Figure 7 shows the comparison of the values between the CP titanium and HA-coated implants<sup>18)</sup>. In the CP titanium implants, BCR values were lowered gradually from upper to bottom portions, and the lowest was seen at mesial direction, while these values of HA-coated implants were shown to be similar at all portions (upper, middle, lower and bottom) and directions (buccal, mesial, distal and lingual). Moreover, in all directions, BCR values of the CP titanium implant were detected lower than those of HA-coated implant. In BVR, the CP titanium implant had lower values at the near zones ( $0-75\ \mu\text{m}$  and  $75-150\ \mu\text{m}$ ) than the far zones ( $150-225\ \mu\text{m}$  and  $225-300\ \mu\text{m}$ ) compared with the values of the HA-coated implant (Fig. 8). However, no significant differences were shown at the far zones between these two implants.

## DISCUSSION

In this study, the three-dimensional bony architecture around unloaded CP titanium implant was clarified. Histomorphometrical data indicated that BCR values of the



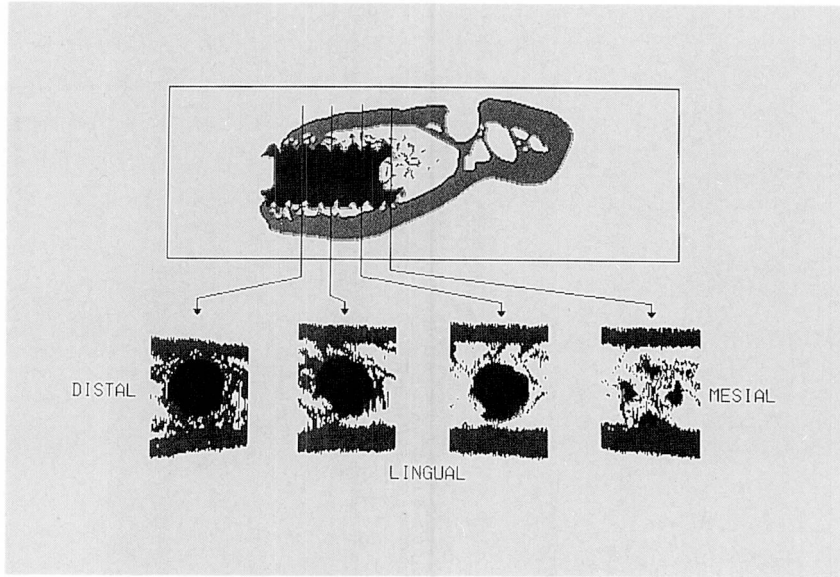
**Fig. 4** A three-dimensional computer graphics of bone around a titanium implant. To access the implant visually, bone at mesio-buccal direction was removed.



**Fig. 5** Bone architecture around the implant at buccal, lingual, mesial and distal directions in one implant. Variation of bone contact with the implant is clearly shown. Bone apposition to the surface of the implant in mesial direction is less than those in other three directions.

CP titanium implant were lower than those of the HA-coated implant except for the upper portion and the BVR values of CP titanium implant were especially lower than those of HA-coated implant. In the literature, BCR values around the titanium screw implants have been

documented to be 50% or more in monkeys<sup>19</sup>, while 40 to 70% in dogs<sup>15,20</sup> and 50 to 75% in rabbits<sup>14,21</sup>. The results of total BCR values (38 to 52%) in this study are well accorded with the values in a monkey reported by Lum<sup>19</sup>. Moreover, in this study, the three-dimensional



**Fig. 6** Bone architecture around implant in one bucco-lingual section (upper) and at the four portions of the horizontal direction of that bucco-lingual section (lower). It is evident that more bone contact with the implant at upper and middle portions, whereas less bone contact at lower and bottom portions.

**Table 1** Bone contact ratio (BCR) around the CP titanium implant

Implant No.	Direction				Portion				Total
	Buccal	Lingual	Mesial	Distal	Upper	Middle	Lower	Bottom	
T1	53.7	53.2	38.4	49.0	69.9	63.3	32.0	27.8	52.0(%)
T2	25.2	54.2	13.9	34.4	36.3	33.9	24.4	32.1	38.0
T3	44.4	61.5	31.0	49.9	66.6	44.9	40.9	32.4	50.5
Mean	41.1	56.3	27.8	44.4	57.6	47.4	32.4	30.8	46.9
±SD	±14.5	±4.5	±12.6	±8.7	±18.5	±14.9	±8.3	±2.6	±7.8

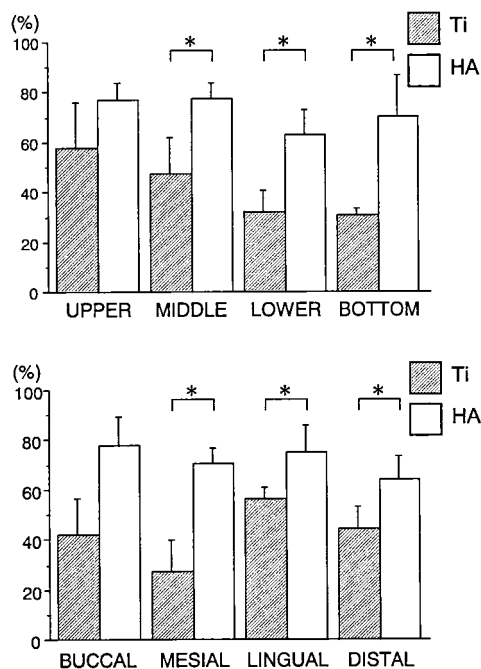
**Table 2** Bone volume ratio (BVR) around the CP titanium implant

Implant No.	0–75 $\mu\text{m}$	75–150 $\mu\text{m}$	150–225 $\mu\text{m}$	225–300 $\mu\text{m}$	0–300 $\mu\text{m}$
T1	52.0	53.5	52.2	48.8	51.6(%)
T2	38.0	59.2	66.6	66.0	57.5
T3	50.5	58.0	60.8	60.6	57.5
Mean	46.9	56.9	59.9	58.5	55.5
±SD	±7.8	±3.0	±7.2	±8.8	±3.4

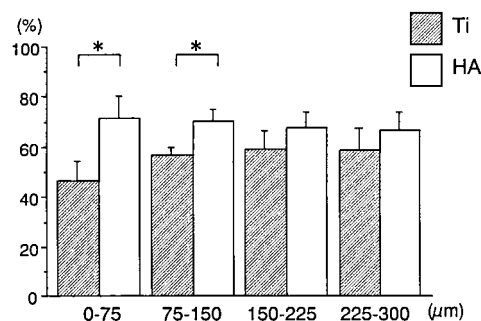
morphometric analysis showed the whole aspect of BCR clearly with a quite variation among the portions and directions.

The difference of BCR values around the CP titanium

implant existed among directions and portions due to the difference of bone structure in the implant site. Cortical bone is generally more dense and easier to be healed around an implant than spongy one is<sup>8,14</sup>. It may well



**Fig. 7** Bone contact ratio (BCR) around the CP titanium (Ti) and HA-coated implants (HA)<sup>18)</sup>  
\*:  $P < 0.05$



**Fig. 8** Bone volume ratio (BVR) around the CP titanium (Ti) and HA-coated implants (HA)<sup>18)</sup>  
\*:  $P < 0.05$

be understood that higher BCR of each CP titanium implant observed in lingual direction and at upper portion was due to more cortical bone contact and lower BCR of each implant in mesial direction and at lower and bottom portions was due to more spongy bone contact. On the other hand, in terms of HA-coated implant the differences of BCR values were previously reported not to be detected<sup>18)</sup>. It is well recognized that bone apposition to the HA-coated implant was achieved even around the

poor trabecular bone due to high osteoconductivity of HA. The different ability of osteoconduction between CP titanium and HA may cause the results of BVR. Bone formation around the CP titanium implant was not well performed in near zones than far zones, while fully achieved bone formation was observed even near zone around HA-coated implant. These findings suggest that bone structure at insertion site around the CP titanium implant is more critical to achieve predictable initial osseointegration during the healing period.

Clinically, it is quite important to diagnose bone quality and to make the treatment planning of implant insertion under the consideration of the direction of insertion, implant diameter and length. The 3D morphometric method used in this study can provide not only the graphics of bone architecture around the implant but also quantitative analysis of bone quality. Since the bone-implant interface may be altered as bone remodeling by functional loading<sup>17)</sup>, further studies are needed to evaluate the three-dimensional bone architecture around the implant after long-term of loading.

## REFERENCES

- 1) Brånemark, P.-I.: Osseointegration and its experimental background. *J. Prosthet. Dent.* 50, 399-410, 1983.
- 2) Caniggia, M., Maniscalco, P., Pagliantini, L. and Bocchi, L.: Titanium anchors for the repair of rotator cuff tears: preliminary report of a surgical technique. *J. Orthop. Trauma.* 9, 312-317, 1995.
- 3) Crawford, H.V., Unwin, P.S. and Walker, P.S.: The CAD/CAM contribution to customized orthopaedic implants. *Proc. Inst. Mech. Eng. H.* 206, 43-46, 1992.
- 4) Timothy, M.H., Bruce, B.B., Michael, J.S., Michael, J.M., Scott, L.S. and Thomas, E.V.D.: Evaluation of titanium dental implant osseointegration in posterior edentulous areas of micro swine. *J. Oral Implantol.* 17, 118-124, 1991.
- 5) Tjellström, A., Yontchev, E., Lindström, J. and Brånemark, P.-I.: Five year's experience with bone-anchored auricular prostheses. *Otolaryngol Head Neck Surg.* 93, 366-372, 1985.
- 6) Ko, C.C., Kohn, D.H. and Hollister, S.J.: Micromechanics of implant/tissue interface. *J. Oral Implantol.* 18, 220-230, 1992.
- 7) Arvidson, K., Bystedt, H. and Ericsson, I.: Histometric and ultrastructural studies of tissues surrounding astra dental implants in dog. *Int. J. Oral Maxillofac. Implants.* 5, 127-134, 1990.
- 8) Deporter, D.A., Watson, P.A., Pilliar, R.M., How-

- ley, T.P. and Winslow, J.: A histological evaluation of a functional endosseous, porous-surfaced, titanium alloy dental implant system in the dog. *J. Dent. Res.* **67**, 1190-1195, 1988.
- 9) Deporter, D.A., Watson, P.A., Pilliar, R.M., Chipman, M.L. and Valiquette, N.: A histological comparison in the dog of porous-coated vs. threaded dental implants. *J. Dent. Res.* **69**, 1138-1145, 1990.
  - 10) Hayashi, K., Matsuguchi, K., Uenoyama, T., Kanemaru, T. and Sugioka, Y.: Evaluation of metal implants coated with several types of ceramic as biomaterials. *J. Biomed. Mater. Res.* **23**, 1247-1259, 1989.
  - 11) Hayashi, K., Uenoyama, K., Matsuguchi, N. and Sugioka, Y.: Quantitative analysis of *in vivo* tissue responses to titanium-oxide- and hydroxyapatite-coated titanium alloy. *J. Biomed. Mater. Res.* **25**, 515-523, 1991.
  - 12) Hipp, J.A., Brunski, J.B., Cochran, G.V.B. and Higuchi, K.W.: Investigation of "osseointegration" by histomorphometric analyses of fixture-bone interfaces. *J. Dent. Res.* **66** (special issue), 186, 1987.
  - 13) Kohn, D.H.: Overview of factors important in implant design. *J. Oral Implantol.* **18**, 204-218, 1992.
  - 14) Sennerby, L., Thomsen, P. and Ericson, L.E.: A morphometric and biomechanic comparison of titanium implants inserted in rabbit cortical and cancellous bone. *Int. J. Oral Maxillofac. Implants.* **7**, 62-71, 1992.
  - 15) Weinlaender, M., Kenney, E.B., Lekovic, V., Beumer, J. III. and Moy, P.K.: Histomorphometry of bone apposition around three types of endosseous dental implants. *Int. J. Oral Maxillofac. Implants.* **7**, 491-496, 1992.
  - 16) Akagawa, Y., Wadamoto, M., Sato, Y. and Tsuru, H.: The three-dimensional bone interface of an osseointegrated implant: A method for study. *J. Prosthet. Dent.* **68**, 813-816, 1992.
  - 17) Sahin, S., Akagawa, Y., Wadamoto, M. and Sato, Y.: The three-dimensional bone interface of an osseointegrated implant. II: A morphometric evaluation after three months of loading. *J. Prosthet. Dent.* **76**, 176-180, 1996.
  - 18) Wadamoto, M., Akagawa, Y., Sato, Y. and Kubo, T.: The three-dimensional bone interface of an osseointegrated implant. I: A morphometric evaluation in initial healing. *J. Prosthet. Dent.* **76**, 170-175, 1996.
  - 19) Lum, L.B., Beirne, O.R., Dillinges, M. and Curtis, T.A.: Osseointegration of two types of implants in non-human primates. *J. Prosthet. Dent.* **60**, 700-705, 1988.
  - 20) Ericsson, I., Johansson, C.B., Bystedt, H. and Norton, M.R.: A histomorphometric evaluation of bone-to-implant contact on machine-prepared and roughened titanium dental implants. A pilot study in the dog. *Clin. Oral Impl. Res.* **5**, 202-206, 1994.
  - 21) Gottlander, M. and Albrektsson, T.: Histomorphometric studies of hydroxylapatite-coated and uncoated CP titanium threaded implants in bone. *Int. J. Oral Maxillofac. Implants.* **6**, 399-404, 1991.