

## Castleman's Disease Arising in the Cervical Region: A Case Report

Köksal YUCA<sup>1)</sup>, Mustafa KÖSEM<sup>2)</sup>, Hakan ÇANKAYA<sup>1)</sup>, Ahmet KUTLUHAN<sup>1)</sup>  
and Muzaffer KIRIS<sup>1)</sup>

1) Department of Otorhinolaryngology, Yüzüncü Yıl University Medical Faculty, Van, Turkey

2) Department of Pathology, Yüzüncü Yıl University Medical Faculty, Van, Turkey

### ABSTRACT

Castleman's disease (CD) (angiofollicular lymph node hyperplasia) is a rare lymphoproliferative disease of unknown etiology. On rare occasions it is the cause of a solitary neck mass. Definitive diagnosis and treatment is possible with complete surgical resection. This report describes a case of this disorder of the hyalinovascular type as a solitary neck mass in a 35-year-old woman. The patient was treated by surgical excision.

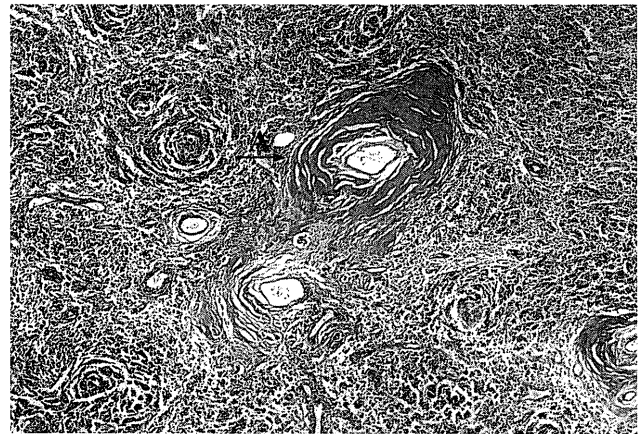
**Key words:** Castleman's disease, Angiofollicular lymph node hyperplasia, Neck mass

Castleman's disease (CD), also known as giant lymph node hyperplasia, was first described by Castleman et al in 1954 as a localized mass of mediastinal lymphoid follicles<sup>1)</sup>. CD was found to be histologically characterized by lymphoid follicle hyperplasia. The etiology and pathogenesis remain unclear, and it is proposed that either a chronic inflammatory process or a hamartomatous lesion is involved in this rare disease. The diagnosis must be made on the basis of histopathologic consultation and interpretation. Two histological subtypes with differing clinical features have been demonstrated: the hyaline-vascular type and the plasma cell type<sup>5)</sup>. In this paper, we report a case of CD of hyalinovascular type in a 35-year-old woman. The lesion was localized in the left side of the neck.

### CASE REPORT

A 35-year-old woman presented to the ENT department with a 10-year history of a mass in the left side of her neck, which had slowly increased in size. On physical examination a large, firm, mobile, non-tender mass 5 × 4 × 3 cm in dimension was found under the sternocleidomastoid muscle on the left side. The remainder of the physical examination was normal.

The routine laboratory tests (hematology, urinalysis, biochemistry), electrocardiogram studies and a chest X-ray were within normal limits. Serological tests for HIV and hepatitis B were negative. Fine needle biopsy was inconclusive. An ultrasonography of the neck showed a large, soft-tissue solid mass without any cystic component. Panendoscopic examination was normal, and the mass was totally excised under general anesthe-



**Fig. 1.** Hyaline type CD. The capillaries show hyalinisation of their walls and concentrating layering of small lymphocytes around a compact germinal center giving an 'onion ring appearance'. (Please see the arrow) (H-E X 125).

sia. Histopathologic examination of the mass showed a hyperplastic lymph node. The follicles showed prominent vascular proliferation and hyalinization in the central portion. There was a tight concentric layering of lymphocytes at the periphery of the follicles, resulting in an onion-skin appearance (Fig. 1). The case was reported as the hyalinovascular type of CD. No recurrence was noted in the postoperative.

### DISCUSSION

CD is characterized by a massive growth of lymphoid tissue. It has also been called giant lymph node hyperplasia, lymph node hamartoma, follicular lymphoreticuloma, angiofollicular mediastinal

Address for correspondence: Köksal Yuca, M.D.

Yüzüncü Yıl University, Faculty of Medicine, Department of Otorhinolaryngology, VAN/TURKEY

Telephone: 0+90-(432) 216 47 08 Fax: 0+90-(432) 216 65 63

E-mail:koksalyuca@hotmail.com

lymph node hyperplasia, angiomatous lymphoid hamartoma, and benign giant lymphoma. It is an unusual condition of unknown etiology and pathogenesis<sup>7,8,10,12</sup>. Some authors have suggested a viral infectious process or chronic inflammatory reaction or angiomatous lymphoid hamartoma or lymphoid choristoma<sup>5,10</sup>. Excessive production of interleukin-6 by the hyperplastic lymph node has also been implicated in the pathogenesis of this disease<sup>4</sup>.

CD usually affects young people as a single, asymptomatic mediastinal or hilar mass<sup>4</sup>. Our patient was a 35-year-old woman.

With 70% of cases occurring before age 30, an age range of eight to 66 years has been reported<sup>4</sup>. Of the masses reported, 86% of lesions were found in the mediastinum and only 6% were located in the neck. The head and neck is the second commonest site for this lesion<sup>1,5,8,12</sup>. In our case, a large, firm, mobile, non-tender mass 5 × 4 × 3 cm in dimension was found under the sternocleidomastoid muscle on the left side of the neck.

Two main histologic types have been defined: the hyaline-vascular type (90% of cases) and the plasma cell type (10% of cases)<sup>4</sup>. A finding of an intermediate (mixed) type is assumed to be a transitional lesion<sup>2</sup>. Histopathologic examination of the lymph node in our case showed it to be a similar hyaline-vascular type. The hyaline-vascular type accounts for 91% of cases of giant lymph node hyperplasia, and is characterized by large fibrous masses in the perivascular area with interspersed areas of plasma cells. The capillaries often show hyalinisation of their walls and are surrounded by sheets of lymphocytes giving them an 'onion-skin' appearance<sup>10</sup>. The majority of lesions in the neck are of the hyaline-vascular type and they commonly present as an asymptotically enlarging mass<sup>10</sup>. Systemic manifestations, including fever, anemia, elevated erythrocyte sedimentation rate and hypergammaglobulinemia, occur frequently in patients with the plasma cell type<sup>10</sup>. In our case the patient presented with a 10-year history of a mass in the left side of her neck which had slowly increased in size and the routine laboratory tests were within normal limits.

Macroscopically, Castleman's disease tissue usually appears as well-circumscribed, firm, ovoid masses ranging from 3 to 8 cm in maximum diameter. The hyaline vascular type of the disease generally involves one lymph node; however, the plasma cell type is frequently distributed to several lymph nodes<sup>5</sup>. In our patient, histopathological diagnosis of the mass (5 × 4 × 3 cm in dimension) showed it to be the hyaline vascular type CD.

The differential diagnosis of cervical nodal enlargements include lymphoma, neurogenic tumor, hemangioma, thymoma, metastatic disease, sarcoma, etc.<sup>2,10,11</sup>. Pre-operative radiographic studies and fine needle aspiration

cytology are typically non-diagnostic but can aid in eliminating other diagnoses<sup>9</sup>. CD may mimic granulomatous, inflammatory and metastatic lymph nodes or lymphoma with its nonspecific imaging findings<sup>9</sup>.

Definitive diagnosis and treatment is possible with complete surgical resection and histopathologic evaluation of the excised specimen. Surgical resection is the treatment of choice for CD in the head and neck, with a 100% control rate for the hyaline-vascular type<sup>2-4,6,9,10</sup>. There are no reported recurrences of the hyaline-vascular type<sup>8,12</sup>. Sanz et al reported the only case of a plasma cell type in the head and neck, which recurred after 11 months<sup>11</sup>. In our case no recurrence was noted during about 13 months of follow-up.

(Received January 1, 2003)

(Accepted April 1, 2003)

## REFERENCES

1. **Castleman, B., Iverson, L. and Menendez, V.P.** 1956. Localized mediastinal lymph node hyperplasia resembling thymoma. *Cancer* **9**: 822–830.
2. **Gaba, A.P., Stein, R.S., Sweet, D.L. and Variakojis, D.** 1978. Multicentric giant lymph node hyperplasia. *Am. J. Clin. Pathol.* **69**: 86–90.
3. **Grzybowska, L.** 1997. Angiofollicular lymph node hyperplasia (Castleman's disease) in an adult woman. *Pol. Merkurizus. Lek.* **2**: 219–220.
4. **Hsu, S.M., Waldron, J.A., Xie, S.S. and Barlogie, B.** 1993. Expression of interleukin-6 in Castleman's disease. *Hum. Pathol.* **24**: 833–839.
5. **Keller, A.R., Hochholzer, L. and Castleman, B.** 1972. Hyaline-vascular and plasma-cell types of giant lymph node hyperplasia of the mediastinum and other locations. *Cancer* **29**: 670–683.
6. **Kim, J.E., Kim, C.J., Park, I.A., Kim, W.H., Seo, J.W., Jang, J.J., Kim, C.W., Park, S.H., Lee, H.S., Chi, J.G., Kim, Y.I. and Ham, E.K.** 2000. Clinicopathologic study of Castleman's disease in Korea. *J. Korean Med. Sci.* **15**: 393–398.
7. **Kumar, B.N., Jones, T.J. and Skinner, D.W.** 1997. Castleman's disease: an unusual cause of a neck mass, *ORL. J. Otorhinolaryngol.* **59**: 339–340.
8. **Osma, U., Cureoglu, S., Yaldiz, M. and Topcu, I.** 2001. Castleman's disease (giant lymph node hyperplasia) of the neck: a case report. *Eur. Arch. Otorhinolaryngol.* **258**: 42–44.
9. **Poyanli, A., Genc, F.A., Sencer, S., Yanar, H. and Kapran, Y.** 2000. Cervical Castleman's disease: imaging findings. *Eur. Radiol.* **10**: 1190–1192.
10. **Raut, V., Cullen, J. and Hughes, D.** 2001. Giant lymph node hyperplasia: a diagnostic dilemma in the neck. *Auris Nasus Larynx* **28**: 185–188.
11. **Sanz, S., Sierra, J., Cobarro, J., Avellaneda, R., Monsterrat, E. and Rozman, C.** 1992. An unusual case of Castleman's disease restricted to the neck, *ORL. J. Otorhinolaryngol.* **54**: 331–333.
12. **Yi, A.Y., de Tar, M., Becker, T.S. and Rice, D.H.** 1995. Giant lymph node hyperplasia of the head and neck (Castleman's disease): a report of five cases. *Otolaryngol. Head Neck Surg.* **113**: 462–466.