

## Accepted Manuscript

Bilateral capital physeal dysplasia in a ferret (*Mustela putorius furo*) treated with femoral head ostectomy

Matthew Swaffield BSc(Hons) BVSc(Hons) MANZCVS(Small animal surgery) MRCVS,  
 Joanna Hedley BVM&S DZooMed(Reptilian) DipECZM(Herpetology) MRCVS,  
 Nadene Stapleton BVSc MRCVS ,  
 Simon Priestnall BSc Vet Path(Hons) BVSc PhD, PCG(VetEd) FHEA FRSB DipACVP FRCPATH MRCVS ,  
 Alejandro Suárez-Bonnet DVM PhD(Hons) MRCVS ,  
 Vicki Baldrey BVSc BSc(Hons) DZooMed(Avian) MRCVS



PII: S1557-5063(19)30111-9  
 DOI: <https://doi.org/10.1053/j.jepm.2019.05.003>  
 Reference: JEPM 50231

To appear in: *Journal of Exotic Pet Medicine*

Please cite this article as: Matthew Swaffield BSc(Hons) BVSc(Hons) MANZCVS(Small animal surgery) MRCVS , Joanna Hedley BVM&S DZooMed(Reptilian) DipECZM(Herpetology) MRCVS , Nadene Stapleton BVSc MRCVS , Simon Priestnall BSc Vet Path(Hons) BVSc PhD, PCG(VetEd) FHEA FRSB DipACVP FRCPATH MRCVS , Alejandro Suárez-Bonnet DVM PhD(Hons) MRCVS , Vicki Baldrey BVSc BSc(Hons) DZooMed(Avian) MRCVS , Bilateral capital physeal dysplasia in a ferret (*Mustela putorius furo*) treated with femoral head ostectomy, *Journal of Exotic Pet Medicine* (2019), doi: <https://doi.org/10.1053/j.jepm.2019.05.003>

This is a PDF file of an unedited manuscript that has been accepted for publication. As a service to our customers we are providing this early version of the manuscript. The manuscript will undergo copyediting, typesetting, and review of the resulting proof before it is published in its final form. Please note that during the production process errors may be discovered which could affect the content, and all legal disclaimers that apply to the journal pertain.

**Bilateral capital physal dysplasia in a ferret (*Mustela putorius furo*) treated with femoral head ostectomy**

Matthew Swaffield BSc(Hons) BVSc(Hons) MANZCVS(Small animal surgery) MRCVS<sup>a</sup>, Joanna Hedley BVM&S DZooMed(Reptilian) DipECZM(Herpetology) MRCVS<sup>a</sup>, Nadene Stapleton BVSc MRCVS<sup>a</sup>, Simon Priestnall BSc Vet Path(Hons) BVSc PhD, PCG(VetEd) FHEA FRSB DipACVP FRCPath MRCVS<sup>b</sup>, Alejandro Suárez-Bonnet DVM PhD(Hons) MRCVS<sup>b</sup>, Vicki Baldrey BVSc BSc(Hons) DZooMed(Avian) MRCVS<sup>a\*</sup>

<sup>a</sup>Beaumont Sainsbury Animal Hospital, Royal Veterinary College, Royal College Street, London, NW1 0TU.

<sup>b</sup> Dept. Pathobiology & Population Sciences, Royal Veterinary College, Hatfield, AL9 7TA

\*Corresponding author email: [ybaldrey@rvc.ac.uk](mailto:ybaldrey@rvc.ac.uk), tel: +44 7974 264435

Matthew Swaffield email: [mswaffield@rvc.ac.uk](mailto:mswaffield@rvc.ac.uk)

Joanna Hedley email: [jhedley@rvc.ac.uk](mailto:jhedley@rvc.ac.uk)

Nadene Stapleton email: [nstapleton@rvc.ac.uk](mailto:nstapleton@rvc.ac.uk)

Simon Priestnall email: [spriestnall@rvc.ac.uk](mailto:spriestnall@rvc.ac.uk)

Alejandro Suarez-Bonnet email: [asuarezbonnet@rvc.ac.uk](mailto:asuarezbonnet@rvc.ac.uk)

Vicki Baldrey email: [ybaldrey@rvc.ac.uk](mailto:ybaldrey@rvc.ac.uk)

## Abstract

A six-month-old male entire ferret presented for investigation of atraumatic bilateral pelvic limb lameness. Radiographic and subsequent histopathological assessment of the femoral heads following bilateral femoral head ostectomy was consistent with capital physeal dysplasia. At six-months postoperatively, pelvic limb function was deemed normal with no evidence of ongoing discomfort. This is the first report of capital physeal dysplasia in the ferret and femoral head ostectomy appears to be an appropriate intervention in the management of these patients.

## Keywords

Ferret; physis; dysplasia; femoral; lameness; orthopedic

A six-month-old male entire ferret (*Mustela putorius furo*) was presented for investigation of bilateral pelvic limb lameness, with intermittent dragging of both pelvic limbs. The owner reported no history of trauma; however, two other ferrets from the same litter had demonstrated similar clinical signs.

Initially, the referring veterinarian had prescribed oral meloxicam 0.1mg/kg once daily and recommended strict rest. Conservative management had been attempted for four weeks prior to referral, with further deterioration in pelvic limb function observed over this time period.

On initial physical examination the ferret was bright and alert, with intermittent dragging of both pelvic limbs observed; lameness score fluctuated between 7-10/10. A full orthopaedic assessment was unrewarding as manipulation of the pelvic limbs was poorly tolerated; however, crepitus was detected on palpation of both hips. The ferret was deemed to be clinically obese. Physical examination was otherwise unremarkable.

Under general anaesthesia, ventrodorsal and lateral pelvic radiographs were obtained (Figure 1), suggesting slipped or fractured capital femoral epiphyses bilaterally. Capital physeal incongruity was observed, with subluxation of the femoral head on the right side and acetabular infilling. Sclerosis of the base of the femoral neck on right side and femoral neck resorption on the contralateral side with mild dorsal drift of the greater trochanter relative to the femoral head was also noted.

Bilateral femoral head ostectomy (FHO) was performed via standard craniolateral approaches [1]. The ferret was anaesthetised with medetomidine (Domitor, Vetoquinol UK Ltd) 0.05mg/kg and ketamine (Ketavet, Zoetis UK Limited) 5mg/kg intramuscularly. General anaesthesia was maintained with isoflurane (Isoflo, Zoetis UK Limited) delivered in oxygen via spontaneous breathing through a 2mm uncuffed endotracheal tube. Analgesia was provided with methadone (Comfortan, Dechra Veterinary Products) 0.3mg/kg intravenously and meloxicam (Metacam, Boehringer Ingelheim) 0.2mg/kg subcutaneously. A fracture line was discovered on the left femoral neck at the anticipated ostectomy site. The bone of the right femoral neck was found to be grossly abnormal and friable. Ostectomies were performed using a rongeur. Following FHO the joint capsule was sutured over the acetabulum using 3-0 polydioxanone (PDS II, Ethicon) in a simple interrupted pattern. Closure was performed in three layers, with musculature closed using 3-0 polydioxanone (PDS II, Ethicon) in a simple continuous pattern, subcutis closed using 3-0 poliglecaprone-25 (Monocryl, Ethicon) in a simple continuous pattern, and skin closed using 3-0 poliglecaprone-25 (Monocryl, Ethicon) in a continuous intradermal pattern. Postoperative radiographs (Figure 2) were satisfactory. Both femoral epiphyses were fixed in 10% neutral-buffered formalin and submitted for histopathological evaluation.

Recovery from surgery was uneventful. Postoperative analgesia was provided with buprenorphine (Buprecare, Animalcare UK) 0.02mg/kg intramuscularly every 8 hours for 48 hours, continued orally for 48 hours after discharge from hospital, and meloxicam (Loxicom, Norbrook Laboratories Ltd, UK) 0.2mg/kg orally once daily for 10 days. The ferret was also treated with famotidine (Famotidine, Summit

Veterinary Pharmaceuticals, UK) 0.5mg/kg orally once daily for 5 days. The ferret was discharged 48 hours after surgery.

Following decalcification, multiple sections of each femoral capital epiphysis were examined extending from the articular surface, composed of unremarkable hyaline cartilage, through normal epiphyseal bone, to the physis. Bilaterally the physes were disorganised with clusters of devitalised chondrocytes and portions of remodelled bone with occasional devitalised osteons, empty lacunae and abundant basophilic matrix (Figures 3 and 4). Low numbers of osteoclasts were present at the distal border (proximal margins of the physal cleavage site), which was covered by a moderately thick layer of fibroblasts suggesting callus formation.

At the five-day postoperative recheck appointment, intermittent attempts at normal ambulation were observed, with a lameness score fluctuating from 6-10/10. Mild swelling and crusting was noted over both incision sites, with the owner reporting some interference with the wounds had occurred. The ferret was also coughing, with the owner reporting that an in contact ferret was being treated for an upper respiratory tract infection. A course of oral potentiated amoxicillin and clavulanic acid was prescribed (Synulox palatable drops, Zoetis UK), 12.5mg/kg orally twice daily for 7 days.

Twelve-days postoperatively ambulation had continued to improve, with lameness score fluctuating between 4-10/10. Swelling over the left FHO site had not resolved, with purulent material expressed. The antibiotic course was extended to 14 days at this point.

At the one-month postoperative recheck the owner reported an initial return to normal ambulation, with a subsequent dragging of the pelvic limbs over the previous ten-days. Swelling over the left FHO site had persisted, although no overt signs of infection were present. Oral meloxicam was reinstated, and a further four-week course of oral potentiated amoxicillin and clavulanic acid was dispensed. The ferret was reviewed again two-months postoperatively as normal pelvic limb function had not fully returned. Intermittent dragging of both pelvic limbs was still observed (lameness score fluctuating between 3-10/10), with a more organised area of firm tissue palpable over the left FHO site. No overt discomfort was noted on manipulation of the pelvic limbs; however, muscle wastage was evident, and the ferret remained overweight. Lateral and ventrodorsal pelvic radiographs were obtained under sedation (Figure 5); these showed no obvious cause for persistent pelvic limb disuse. An aspiration of the swelling was consistent with normal adipose tissue, with no bacteria or inflammatory cells observed. The owner was advised to encourage weight loss, and perform regular physiotherapy and hydrotherapy to facilitate return to normal function.

Telephone follow up with the owner at six-months and one-year postoperatively revealed that normal pelvic limb function had returned, with no evidence of ongoing discomfort.

## **DISCUSSION**

Capital physeal dysplasia resulting in atraumatic separation of the femoral capital epiphysis is a well-recognised syndrome in the cat [2,3], with up to 90% of affected cats in one study showing bilateral disease [4]. Histopathologically, lesions display

“an intact epiphysis consisting of viable bone with an unusually wide physis containing irregular clusters of chondrocytes in an abundant extracellular matrix and necrotic cartilage at the cleavage site” [2]. The disease appears to be analogous to slipped capital femoral epiphysis (SCFE) in humans, with adolescent, obese males overrepresented in both species [2,5,6]. The underlying pathogenesis of the disease in humans is not fully understood, although endocrine disorders, and altered insulin metabolism secondary to obesity have been cited as possible causes [7,8]. Capital physeal dysplasia has also been described in the dog [9,10] and coypu (*Myocastor coypus*) [11]. This condition has not previously been reported in the ferret.

Craig [2] reports uneventful recoveries and good limb function following FHO in 11 of 13 cats with capital physeal dysplasia, consistent with the outcome in this case. In the dog, simultaneous bilateral femoral head and neck ostectomy has been demonstrated to be a viable option for painful bilateral hip disease [12]. Bilateral surgery was elected in this case due to the severity of lesions. Early implementation of weight loss and physiotherapy or hydrotherapy may have resulted in a faster return to function in this case, although the surgical site infection is likely to have slowed the recovery time. In the dog, implementation of any method that encourages early weight bearing results in optimal functional recovery [1].

Visual assessments of lameness in quadruped animals is challenging as the human eye cannot fully and accurately assess motion. Objective analysis of gait following FHO in the dog using kinetic and kinematic evaluations has been demonstrated as a superior method of assessing return to normal function [13]. At present, no standardised method of lameness assessment in the ferret exists. In this case, video



clips were requested but unfortunately not provided by the owner. Lameness scoring by the owner is limited by their lack of veterinary knowledge and is subjective to the individual. One study of dogs and cats reported 96% owner satisfaction in gait following FHO, despite only 38% of these animals having functional gait rated as good [13].

In the dog, a minimal and normal rate of surgical infection of 1% to 2% is recorded [1]. Peri- or postoperative antibiotics were not administered in this case as the duration of surgery was under 90 minutes and this was considered a clean procedure; however, it is challenging to prevent self trauma and therefore surgical site infections in ferrets as E-collars and dressings are not well tolerated. In this case the persistent surgical site infection necessitated an extended course of a broad-spectrum antibiotic, which successfully resolved the infection. Culture and sensitivity was offered to the owner; however, no bacteria or neutrophils were seen on in house examination of quick-stained smears of the aspirates and the owner was reluctant for further testing on financial grounds. Amoxicillin-clavulanate was chosen as a first line antibiotic as it is well tolerated by ferrets, has good soft tissue penetration and a broad spectrum of activity.

In cats, risk factors associated with capital physal dysplasia include gender, age, neuter status and body condition. Male cats, those over 1 year old, in overweight or obese body condition, and those neutered at an early (prepubertal) age have been shown to be at increased risk of developing the disease [6]. Neutering has been demonstrated to result in delayed physal closure [14,15]. Similar epidemiological factors were present in this ferret (male, obese, prepubertal); however, he had not

been neutered before the onset of clinical signs. Physeal closure in the ferret has been reported between four and seven months [16].

There is some evidence that this condition may be familial in humans [5] and a genetic aetiology is also suggested in cats [2]. It is interesting that litter mates of this ferret demonstrated similar clinical signs; however, a diagnosis was not confirmed by histopathology in these cases, so further conclusions cannot be drawn.

Capital physeal dysplasia appears to occur naturally in ferrets, and may have a similar aetiology, epidemiology, and histopathology to the condition reported in cats and humans with SCFE. It should be considered a differential diagnosis in young ferrets with hindlimb lameness. Femoral head ostectomy appears to be an appropriate intervention and to be associated with a good prognosis.

#### **Conflict of interest**

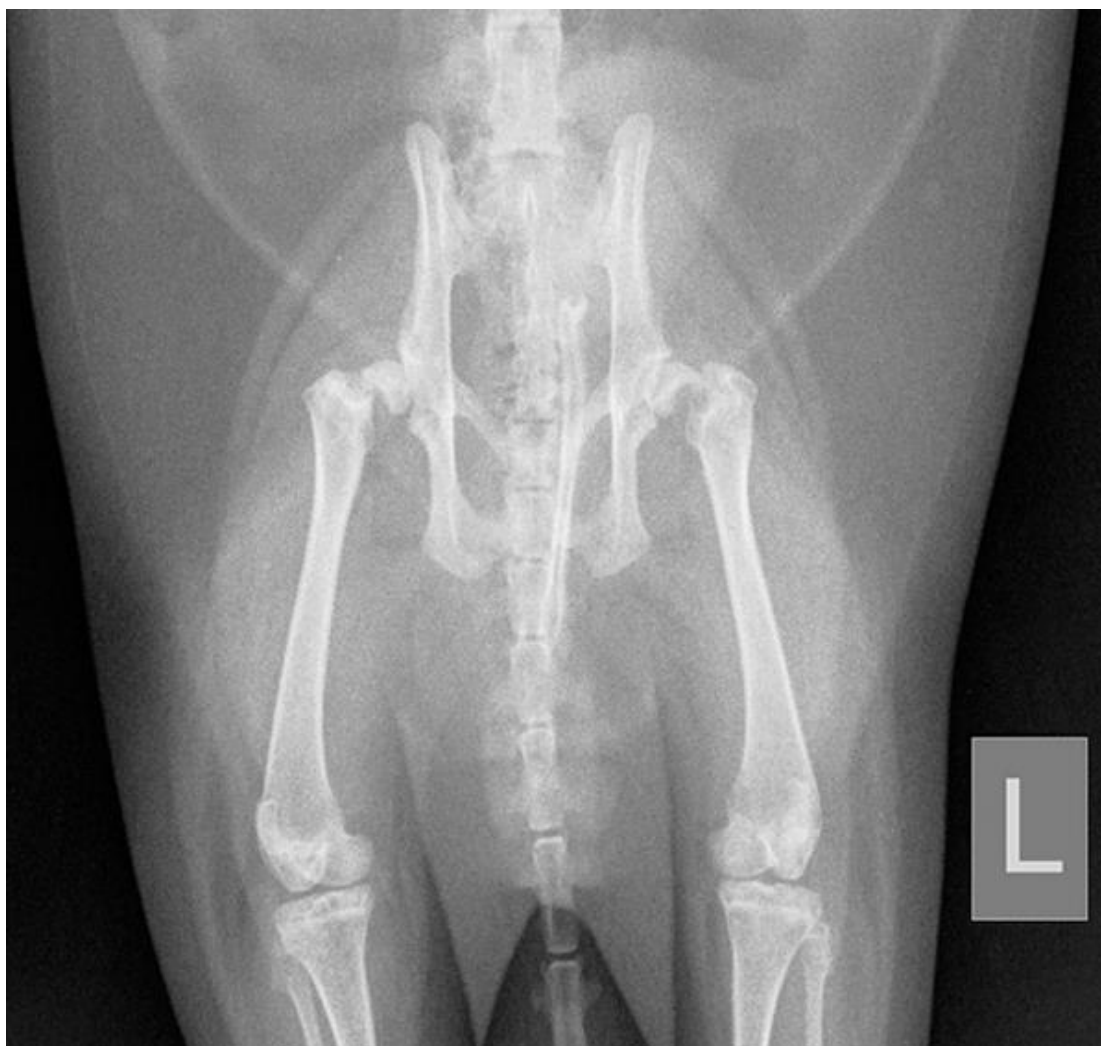None of the authors of this article has a financial or personal relationship with other people or organizations that could inappropriately influence or bias the content of the paper.

**References**

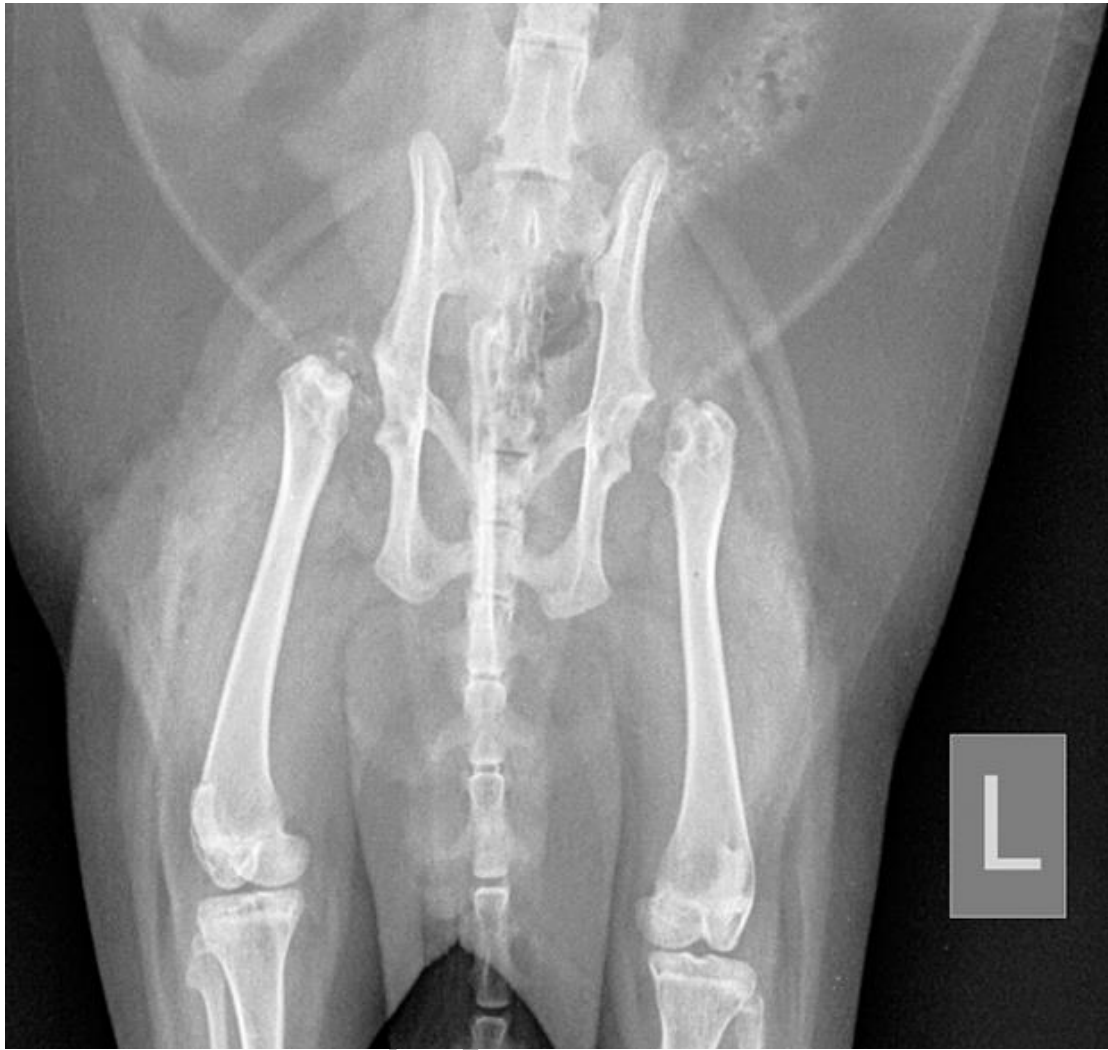1. Roush JK, Surgical therapy of canine hip dysplasia, in: Tobias KM, Johnston SA (Eds.), *Veterinary Surgery: Small Animal*, Elsevier Saunders, Missouri, 2012, pp. 856-857.
2. Craig LE: Physeal dysplasia with slipped capital femoral epiphysis in 13 cats. *Vet Pathol* 38:92-97, 2001.
3. Perez-Aparicio FJ, Fjeld TO: Femoral neck fractures and capital epiphyseal separations in cats. *J Small Anim Pract* 34:445-449, 1993.
4. Forrest LJ, O'Brien RT, Manley PA: Feline Capital Physeal Dysplasia syndrome. *Veterinary Radiol Ultrasound* 40:672, 1999.
5. Loder RT, Aronssen DD, Dobbs, MB et al: Slipped capital femoral epiphysis. *J Bone Joint Surg Am* 82:8:1170-1188, 2000.
6. McNicholas WT Jr, Wilkens BE, Blevins WE et al: Spontaneous femoral capital physeal fractures in adult cats: 26 cases (1996-2001). *J Am Vet Med Assoc* 221:1731-1736, 2002.
7. Nicolai RD, Grasemann H, Oberste-Berghaus C et al: Serum insulin-like growth factors IGF-I and IGFBP-3 in children with slipped capital femoral epiphysis. *J Pediatr Orthop B* 8:2:103-106, 1999.

8. Orth MW: The regulation of growth plate cartilage turnover. *J Anim Sci* 77:183-189, 1999.
9. Dupuis J, Breton L, Drolet R: Bilateral epiphysiolysis of the femoral heads in two dogs. *J Am Vet Med Assoc* 210:1162-1165, 1997.
10. Moores AP, Owen MR, Fewes D et al: Slipped capital femoral epiphysis in dogs. *J Small Anim Pract* 45:602-608, 2004.
11. Holmes RG: Separation of the upper femoral epiphysis in the coypu (*Myocastor coypus*). *Vet Rec* 80:405-407, 1967.
12. Rawson EA, Aronsohn MG, Burk RL: Simultaneous Bilateral Femoral Head and Neck Osteotomy for the Treatment of Canine Hip Dysplasia. *J Am Anim Hosp Assoc* 41: 166-170, 2005.
13. Off W, Matis U: Excision arthroplasty of the hip joint in dogs and cats. *Vet Comp Orthop Traumatol* 23(05): 297-305, 2010.
14. May C, Bennett D, Downham DY: Delayed physeal closure associated with castration in cats. *J Small Anim Pract* 32:326-328, 1991.
15. Perry KL, Fordham A, Arthurs G: Effects of neutering and breed on femoral and tibial physeal closure times in male and female domestic cats. *J Feline Med Surg* 16:149-156, 2013.
16. Mackey MS, Stevens ML, Ebert DC et al: The ferret as a small animal model with BMU-based remodeling for skeletal research. *Bone* 17:191-196, 1995.

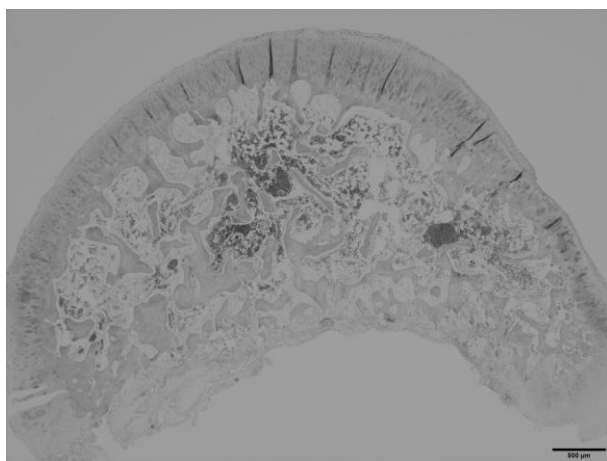
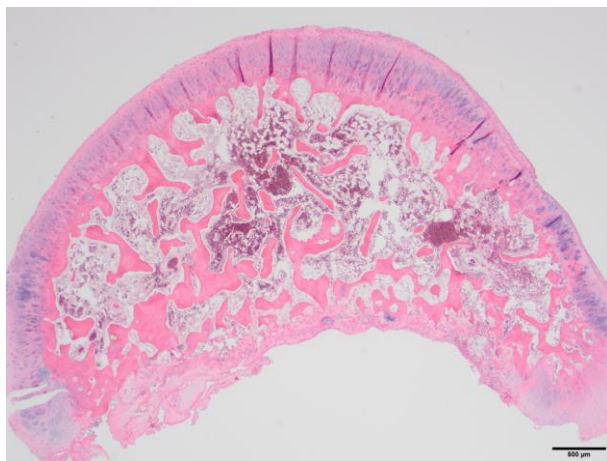
## FIGURE LEGENDS



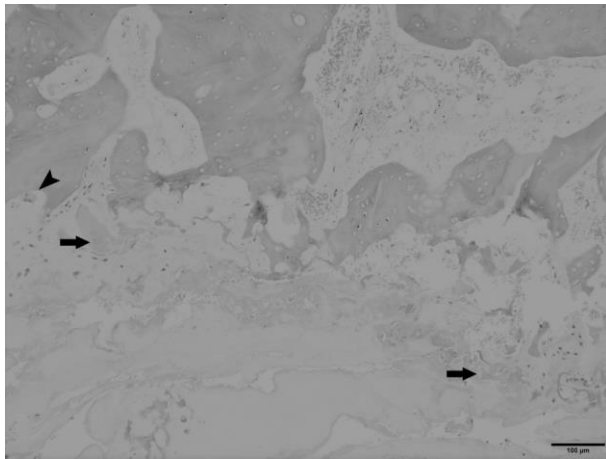
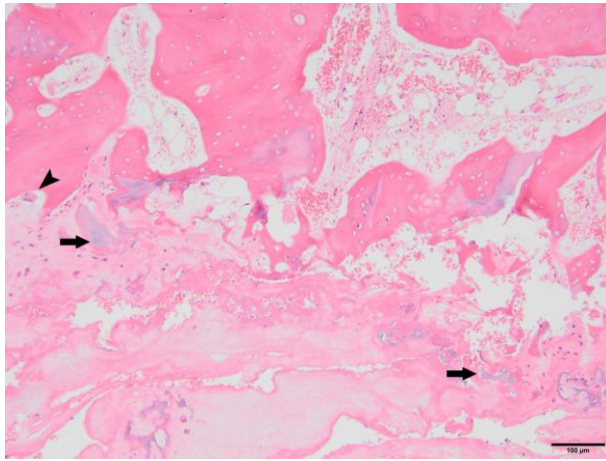
**Figure 1:** Preoperative ventrodorsal radiograph of the pelvis suggesting bilateral slipped or fractured capital femoral epiphyses. Note bilateral capital physeal incongruity, subluxation of the right femoral head with sclerosis of the base of the femoral neck, and resorption of the left femoral neck with mild dorsal drift of the greater trochanter relative to the femoral head.



**Figure 2:** Immediate postoperative ventrodorsal radiograph demonstrating successful bilateral FHO.

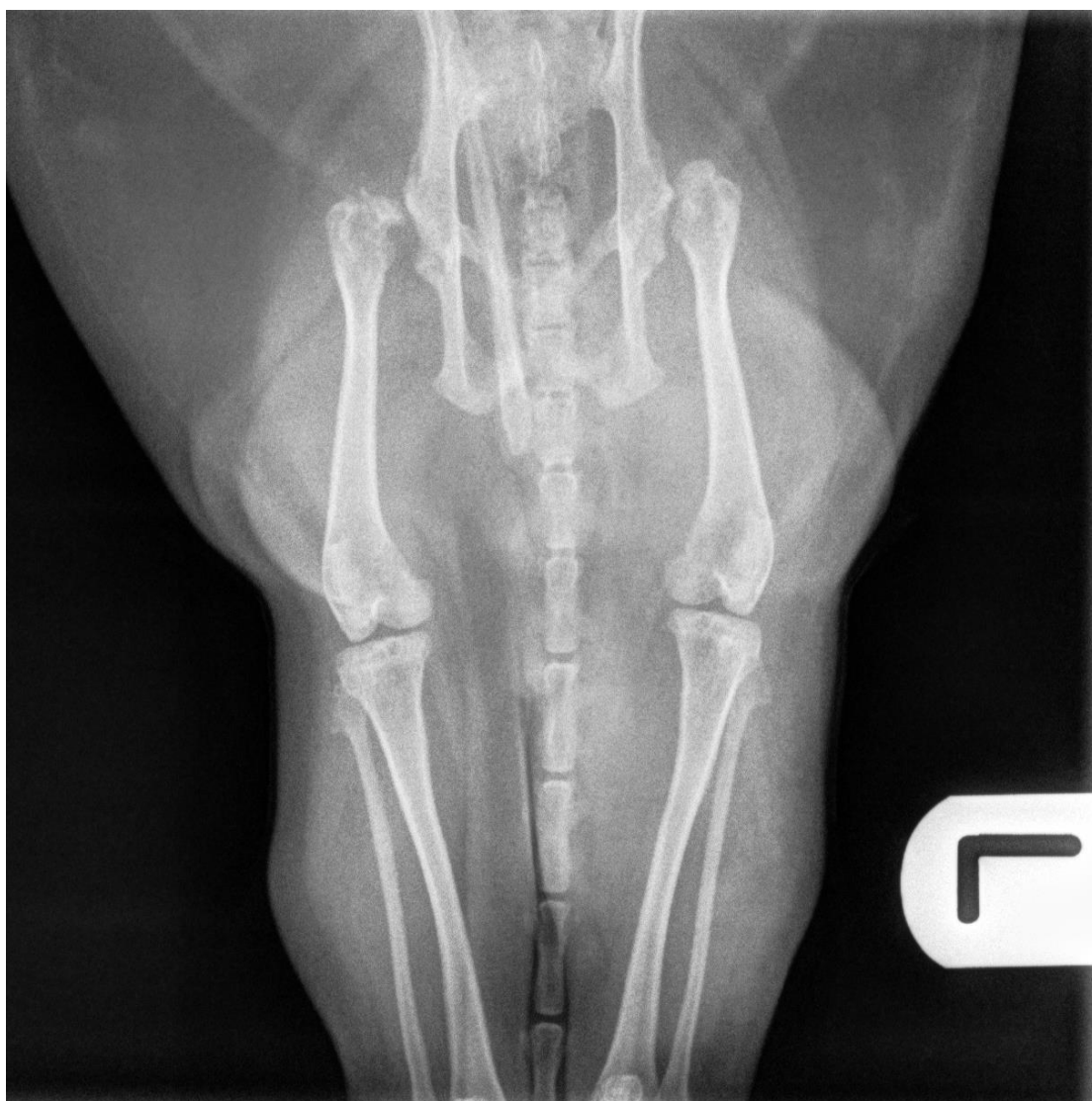

**Figure 3:** Femoral capital epiphysis with fracture through the physis. The articular surface is unremarkable but the physeal surface is markedly irregular and lined by devitalised chondrocytes and fragments of necrotic bone. H&E x 20.



**Figure 4:** Femoral capital epiphysis with fracture through the physis. Fragments of devitalised cartilage (arrows), admixed with necrotic bone, haemorrhage and occasional osteoclasts (arrowhead). H&E x 100.





**Figure 5:** Two month postoperative ventrodorsal radiograph of the pelvis. Mild bony proliferations are evident of the left limb, and marked bony proliferations are present on the right. Ossifications following FHO are a common finding in cats and dogs, with no correlation between osteophyte formation and functional outcome.