

ORIGINAL ARTICLE, MEDICINE

The Role of Taylor Spatial Frame in the Treatment of Blount Disease

Haridimos Tsibidakis¹, Artemisia Panou², Antonios Angoules³, Vassilios I. Sakellariou⁴, Nicola Marcello Portinaro², Julian Krumov⁵, Anastasios D. Kanellopoulos⁶

¹ Orthopaedic Clinic and Ilizarov Unit, Hospital A. Manzoni, Lecco, Italy

² Department of Pediatric Orthopaedics and Neuro-orthopaedics, University of Milan, Humanitas Research Hospital, Rozzano (Milan), Italy

³ Department of Medical Laboratories, Technological Educational Institute of Athens, Athens, Greece

⁴ Department of Orthopaedics, Mediterraneo Hospital, Glifada, Greece

⁵ Orthopaedic and Traumatology Clinic, Military Medical Academy Hospital of Varna, Bulgaria

⁶ Pediatric Orthopaedics, Iaso Children's Hospital, Athens, Greece

Correspondence:

Haridimos Tsibidakis, Orthopaedic Clinic and Ilizarov Unit, Hospital A. Manzoni, Via Eremo 9/11, 23900 Lecco, Italy
E-mail: tsibidakis@hotmail.com
Tel: +393270572793

Received: 23 June 2017

Accepted: 10 Aug 2017

Published Online: 23 Sept 2017

Published: 30 June 2018

Key words: Blount's disease, external fixation, tibial osteotomy, children, multiplanar deformity

Citation: Tsibidakis H, Panou A, Angoules A, Sakellariou VI, Portinaro NM, Krumov J, Kanellopoulos AD. The role of Taylor spatial frame in the treatment of Blount disease. *Folia Med (Plovdiv)* 2018;60(2):208-15.
doi: 10.1515/fomed-2017-0082

Background: Alteration of the posteromedial part of the proximal tibia is the main characteristic of Blount's disease and if left untreated, leg alignment and normal development of the lower limbs may be compromised.

Aim: To report treatment outcomes in children with Blount's disease using the Taylor Spatial Frame (TSF).

Materials and methods: From January 2007 to December 2014, 16 young children (24 tibia) with a mean age of 7.5 years (range of 3-14 yrs) and severe Blount's disease were treated using TSF. Preoperative long standing radiographs were performed and anatomic medial proximal tibial angle (MPTA), diaphyseal-metaphyseal tibial angle (Drennan), femoro-tibial angle and leg length discrepancy (LLD) were measured.

Results: Post-operative improvement of all measurements was observed. MPTA increased from a mean of 71.8° (58° - 79°) to 92.5° (90° - 95°), the Drennan decreased from 16.6° (14° - 18°) to 3.6° (0° - 6°), the F-T angle changed from 15.4° (10° - 25°) of varus to 5.9° (2° - 10°) of valgus and the LLD decreased from 208 mm (150-320) to 69 mm (0- +120). Mean follow-up was 45.6 months. According to Paley's criteria pin track infection was present in 6 tibiae, while in 5 patients software changes were necessary. Recurrence was observed in 3 patients (triplets). Complete restoration of the mechanical axis was obtained at the end of the treatment.

Conclusions: In the last decades, different surgical treatments have been proposed for Blount's disease (tension band plate, staples, osteotomies using external or internal fixation). External fixation using the TSF allows gradual safe correction of multiplanar deformities and is a well-tolerated technique by patients with Blount's disease.

BACKGROUND

Blount's disease is a rare disorder characterized by a dysfunction of the cartilage of the posteromedial part of the proximal tibia. A marked genu varum secondary to proximal tibial varus, tibial procurvatum, internal rotation of the tibia and a depression of the medial tibial plateau are frequently observed in Blount's disease, as well as their combination (varus, procurvatum, and internal tibial torsion) resulting in a complex 3-D deformity.^{1,2} In children with Blount's disease the lower legs remain bowed or bow further outwards, which can lead to

future problems with walking. The infantile type is frequently bilateral (less than 4 yrs old) and, in general, is noticed when the child begins to walk. The juvenile type (5-11 yrs) is usually unilateral, while the adolescent type occurs in children aged 11-14 yrs.

Various treatments options for leg alignment restoration of normal development of the tibia have been proposed, such as tibial osteotomies with internal or external fixation²⁻⁵, hemiplateau elevation with or without epiphyseal distraction⁶⁻⁹, double elevating osteotomies¹⁰, epiphyseal stapling¹¹ and

hemi-epiphysiodesis.¹²

AIM

We report in the present study the treatment outcomes in young patients with monolateral and bilateral Blount's disease using the Taylor Spatial Frame (TSF), which addresses all aspects of the deformity.

MATERIALS AND METHODS

During a 7-year period (January 2007 - December 2014), 16 children with severe Blount's disease (9 males and 7 females, 24 tibias) were treated using the TSF. The mean age was 7.5 years (range: 3-14 yrs) and BMI of 24.2 (range: 18-29.7). An acknowledgement of the hospital IRB was granted and parents' informed consent was obtained for all children recruited in the study.

Varus deformity and leg length discrepancy were present in all patients. Eight patients presented unilateral deformity while the other eight patients had bilateral involvement of the posteromedial part of the proximal tibia. Two patients, both with bilateral deformity, had previously been treated by an unsuccessful proximal tibial osteotomy.

Preoperative long-standing radiographs were performed for all patients. Measurements, according to Paley's criteria¹⁰, of the anatomic medial proximal tibial angle (MPTA), the femoro-tibial angle (F-T angle), diaphyseal-metaphyseal tibial angle (Drennan) and leg-length discrepancy (L-L-D) were performed. These radiological measurements were chosen because they have been used in studies on Blount's disease by other authors.

Bilateral correction was performed simultaneously and a 3-4-day hospitalization was required for each patient. Caregivers were trained on how to clean TSF and to follow instructions given by the software program before returning home. All patients were encouraged to ambulate and return to their activities as tolerated.

At the end of treatment new standing radiographs were performed to confirm healing of the osteotomy. Dynamization of the frame was performed before TSF removal.

Clinical parameters assessed were knee pain, range and stability of knee movement, lateral thrust when walking and rotational deformity.

Radiological measurements, surgical procedures and the latest follow up were performed by a single orthopaedic surgeon (ADK), to avoid interobserver bias.

OPERATIVE TECHNIQUE

With the patient supine and under general anesthesia a thigh tourniquet was applied. Fibula's osteotomy was performed first through a longitudinal skin incision made on the lateral side of the fibula, just below the fibular head to 15 cm distally. After the sub-periosteal exposure of the fibula Linston bone scissors or oscillating saw were used, according to the diameter of the bone.

Two K-wires were inserted to mark the tibias osteotomy level under guidance of an image intensifier.

First, one ring was attached perpendicularly to the long axis of the tibia with the 3 half-pins placed at 5 mm parallel to the joint line in anteroposterior and mediolateral planes. A second ring-frame was applied distally and attached with 3 half-pins (5 mm). The 2 rings were then connected by 6 telescopic struts at special universal joints.

Frame was extended distally with half ring, including the foot, to avoid development of equinovarus deformity. The foot ring was removed within 40 days from surgery, when soft tissues had already gained sufficient length, permitting ankle joint motion.

The multiple drill hole technique (De Bastiani's osteotomy) was applied for tibial osteotomy in line with the K-wires. Osteotomy was tested clinically and checked radiologically by the image intensifier.

Distraction, by moving the distal fragment, was started 7 to 9 days after surgery. Using specific computer software, personalized time schedule and information regarding structures at risk and rate of correction were obtained. Parents were instructed by a responsible health care professional.

RESULTS

One-way analysis of variance (ANOVA) was used to assess the effect of multiple factors and level of significance was set at $p < 0.05$ (the paired t-test).

Patient demographics are shown in **Table 1**, pre- and postoperative measurements of MPTA, Drennan, F-T angle and LLD are shown in **Table 2**. The mean follow-up was 45,6 months (range: 36-72 months).

Statistically significant differences between pre and post-operative values of all radiographic measurements were observed. In the specific, MPTA increased from a mean of 71.8° (range: 58° - 79°) to over correction of 92.5° (range: 90° - 95°) (Mean -21.9, SD=6.05, $p=0.000001$); Drennan angle decreased from 16.6° (range: 14°-18°) to 3.6° (range: 0° - 6°) (Mean 12.9, SD=1.86, $p=0.000001$); F-T

angle changed from 15.4° of varus (range: 10°- 25°) to 5.9° of valgus (range: 2°-10°) (Mean 9.5, SD=2.7, p=0.000001); LLD decreased from 208 mm (range: 150-320) to 69 mm (range: 0 - +120) (Mean 1.24, SD=0.555, p=0.000001).

No statistically significant difference was found between patients with unilateral and bilateral disease.

According to Paley's criteria for problems, pin track infection was observed in 6 cases (4 patients - 2 unilateral and 2 bilateral). Pin track infection was treated by oral antibiotics (cephalosporin 20 mg/Kg once a day) for 10 days. In other 5 patients (unilateral disease tibia) needed further personalized time schedule calculation during the first year of the study.

Regarding obstacles, recurrence of deformity was observed in 3 patients with initial bilateral deformity (triplets - age: 4 yrs); for two of the triplets recurrence was unilateral (left side) and a second TSF was applied 8 months after the end of the treatment. For the remaining one, recurrence (left side) occurred after 10 months of TSF removal and an 8-plate tension band device (Orthofix) was used for the treatment, as per request of the parents.

No peroneal nerve palsy or compartmental syndrome were observed. No complications according to Paley's criteria were observed during our follow-up.

The 2 children, both with bilateral deformity and previously treated with another osteotomy, did not present any type of problems or complications during treatment.

Immediately after frame removal, knee's range of motion (ROM) was from 0°-110° of flexion in all patients, except for 2 patients who had knee flexion 10°- 90° and slight knee tenderness, yet completely restored by the time of the latest follow-up.

None of our patients presented rotational deformity or recurvatum. No breakage of the TSF components was observed during treatment.

DISCUSSION

The aim of our study was to evaluate the TSF in the treatment of the Blount's disease in children. Early surgical treatment is recommended in these patients^{2,12,15,16} because of the high rate of recurrence reported for them (up to 55%).³

Hemiepiphyodesis techniques using staples, transphyseal screws and 8-plate tension band devices have been proposed for the treatment of angular deformities of the knee. All these offer the advantage of being reversible, but they present some problems. Transphyseal screws may disturb growth because they

Table 1. Patients (P), gender (M: males; F: females), age (y: years), BMI and time in frame (m: months; d: days)

Patients (P)	Gender	Age (y)	BMI	Time in Frame
P1	M	9	26.6	3m 18d
P2	M	8	25.7	4m 0d
P3	M	3	18.2	3m 18d
P4	F	3	18.5	4m 2d
P5	F	4	19.3	3m 21d
P6	M	12	29.7	3m 22d
P7	M	9	23.4	4m 1d
P8	F	11	29.5	3m 20d
P9	F	11	26.9	4m 4d
P10	M	12	27.4	3m 21d
P11	M	4	18.1	4m 2d
P12	M	4	18	3m 22d
P13	M	4	18.2	4m 1d
P14	F	9	25	4m 2d
P15	F	4	18.3	3m 21d
P16	F	14	28.3	3m 22d
Mean values		7.56	24.2	3.4m 12.3d

cross within the physis and the fulcrum of correction is centralized. Studies regarding the use of staples demonstrated some serious problems like breakage, difficulty of removal and migration with a high risk of limitation in growth potential after their removal. The 8-plate device is a valid treatment option and offers the possibility of a gradual correction around the knee. However, many studies have reported a high rate of failure concerning the device or a lack of correction when 8 plates are used for the treatment of Blount's disease. In some cases deformity does not improve, but remains stable, thus a future osteotomy can be performed after physeal closure, avoiding recurrence.¹¹⁻¹⁴ In our study none of the children treated had breakage of the TSF device and tibial axis was completely restored before the removal of the device.

Table 2. Pre- (pre-op) and post operative (post-op) measurements of α MPTA, Drennan, F-T angle and LLD

Patients	α MPTA		Drennan		F-T angle		LLD	
	Pre-op	Post-op	Pre-op	Post-op	Pre-op	Post-op	Pre-op cm	Post-op cm
P1	72	93	16	1	24	10	2.1	1
P2	79	95	19	4	25	9	2.2	0.8
P3	59	90	14	0	10	2	1.7	0
P3	58	91	16	1	11	1	1.7	0
P4	63	92	16	5	12	6	1.8	0.7
P4	77	93	17	6	16	6	1.8	0.7
P5	78	93	18	6	16	5	1.9	0.5
P5	73	95	18	5	17	4	1.9	0.5
P6	75	92	18	3	14	7	3.2	1.2
P7	74	94	15	2	17	8	1.5	1
P8	69	90	17	6	16	7	1.7	0.6
P8	74	91	15	2	17	8	1.7	0.6
P9	72	94	17	4	16	5	1.9	0
P10	75	92	18	3	14	7	3.2	1
P11	66	93	14	3	11	4	1.7	0.6
P11	63	92	16	5	12	6	1.7	0.6
P12	63	92	16	5	12	6	1.8	0.7
P12	66	93	17	6	17	6	1.8	0.7
P13	77	93	17	6	18	6	1.9	0.5
P13	79	94	16	4	18	5	1.9	0.5
P14	81	94	17	0	15	6	1.6	0.8
P15	77	93	17	6	16	6	1.9	0.5
P16	75	90	18	13	14	7	3.2	1.1
P16	79	90	16	2	12	6	3.2	1.1
mean	71.8	92.46	16.58	3.62	15.42	5.96	2.08	0.69

Various methods of acute or gradual correction, using internal or external fixation, have been proposed.^{1,2,6,16,17,23} Most patients with adolescent Blount disease are obese, as the majority of the patients included in our study, with a relative contraindication to internal fixation due to increased complication rates.^{2,16,18,29}

Osteotomy for infantile and adolescent tibia vara was proposed by different authors to correct the

deformity, equalize limb lengths, and ameliorate symptoms.³ Acute corrective osteotomy may often become complicated by peroneal nerve palsy, compartment syndrome, residual deformity, limb length inequality, delayed union, and failure of fixation.¹⁸

Price et al.⁸ described the use of a uniplanar dynamic fixator for 34 osteotomies of tibia vara (25 patients). They had 6 tibias with residual varus, 2 patients with a postop neuropraxia, and 9 with pin-

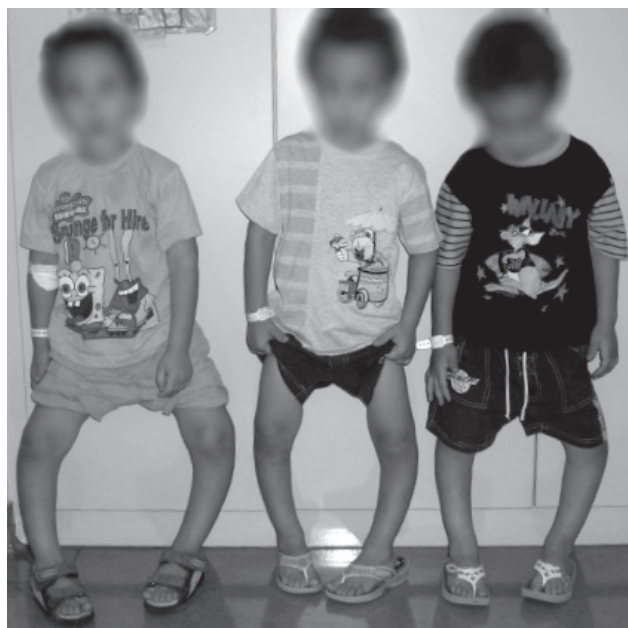

Figure 1 A.

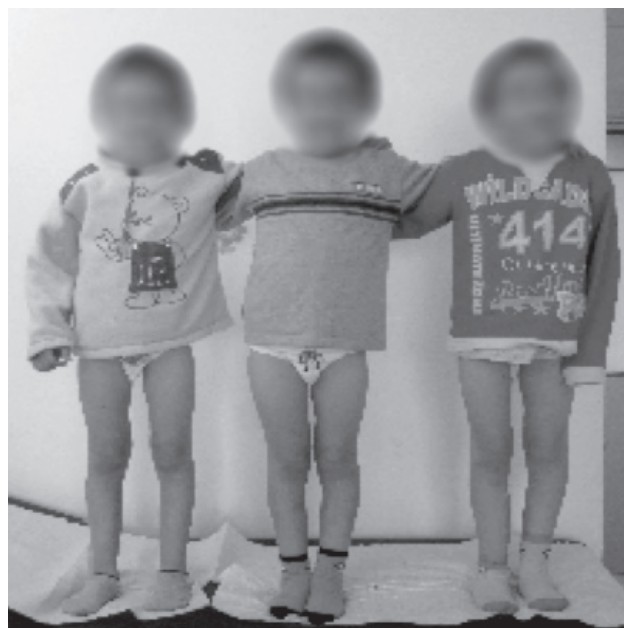

Figure 1 B.



Figure 1 C.

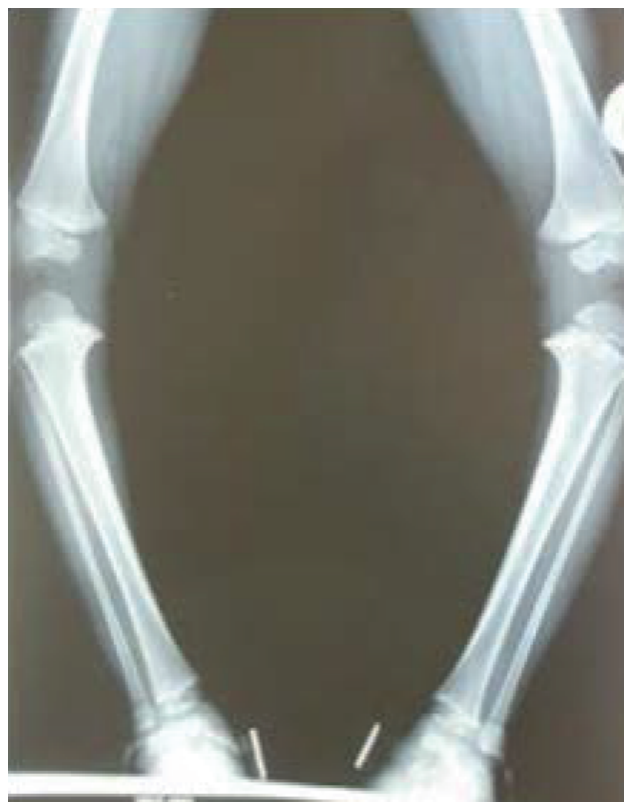

Figure 1 D.

tract infections. Pinkowski and Weiner¹⁹ also reported 11% complications in 37 cases of proximal tibia osteotomies, which included 1 delayed union and 3 superficial infections, without any neurovascular

complications. Ilizarov's device was proposed for the treatment of tibia vara, but due to the presence of multiple deformities, including translation and angulation, rotation correction may not be achieved

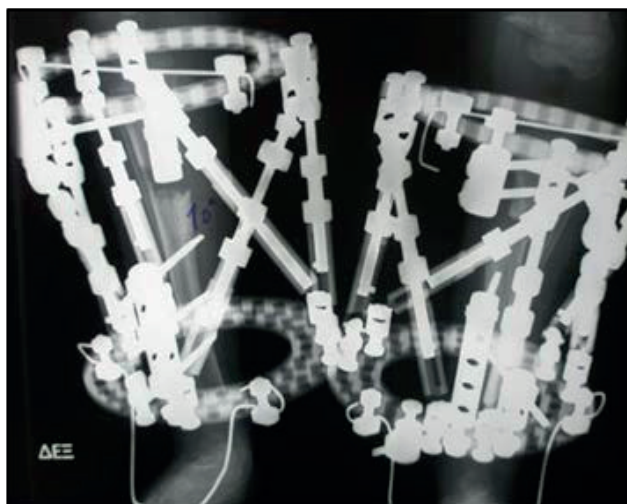


Figure 1 E.

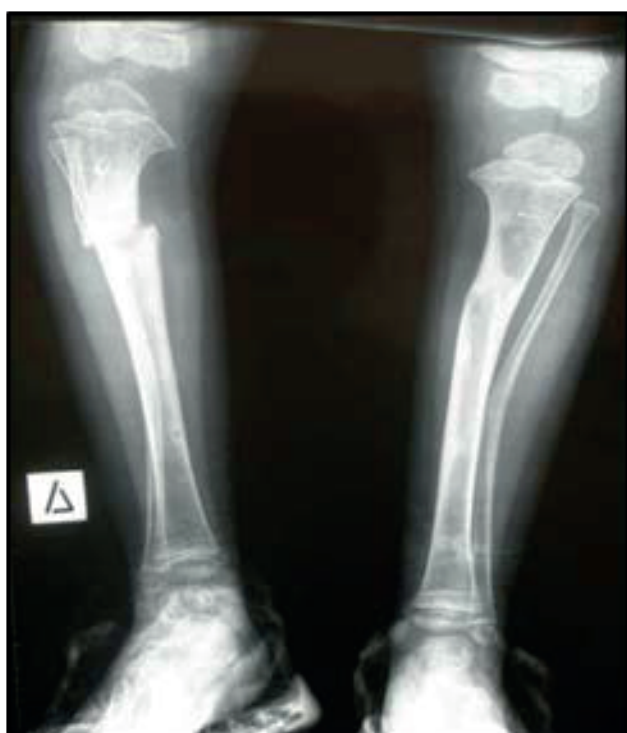

Figure 1 F.

Figure 1.

Clinical aspect of the triplets enrolled in the study: before surgery (A), after 3 years (B) and after 7 years (C). Radiograms on one of the triplets are also shown: before (D), during (E) and after frame's removal (F).

and a second surgery may be necessary.²⁰

Regarding fibular osteotomy some studies identify a danger zone between 6 and 13 cm distally to the fibula's head, where the peroneal nerve and the

extensor hallucis longus lie close to the fibula.^{21,22,28} For this reason, fibula's osteotomy is recommended to be performed through a lateral incision at the junction of the middle and distal third of the fibular shaft. However, injury of the superficial peroneal nerve and palsy of the extensor hallucis longus have been reported, even when osteotomy is performed at the safe zone.²⁶ According to our results, no neurovascular complications and problems were observed after fibular osteotomy.

Risk of pin track infection is common when external fixation is performed. Gordon et al²⁴ used a daily shower for pin-site care with no physical cleansing in children, but those with inflamed or infected pin-sites were treated with oral antibiotics (cephalosporin). The rate of infection was the same when either half pins or wires were used, but infection in the diaphyseal area was much less common than that in the peri-articular region. Pin track infection observed in our patients was 4.16% (6 pin track infected, 4 of them were periarticular, for a total of 144 pin/K-Wire used), similar to that reported in other studies.

Deformity recurrence was observed in 12.5% and the 3 patients involved were triplets (age: 4 yrs). At 8 months after TSF removal, two of the triplets presented unilateral recurrence (left tibia) and a second TSF was applied. However, at 10 months after TSF removal the last triplet, also presented a unilateral recurrence (left tibia) and an 8-plate was applied. The cause of these recurrences may be due to these children's young age at the time of surgery, but a genetic involvement should also be considered (Fig. 1A-B).

The TSF, based on the same principle of distraction osteogenesis as the Ilizarov's system, uses a 6-axis deformity analysis incorporated within a computer program, to establish a virtual hinge in space, around which multiple deformities including translation, angulation, rotation, and shortening are corrected. By adjusting only strut lengths, one ring can be repositioned with respect to the other, and the multiple angles and translations of a given deformity can be addressed simultaneously.^{25,26}

Deformity correction in children can be achieved by various methods. The use of external fixation offers advantages of postoperative adjustment and simultaneous lengthening, when indicated. External fixation has certain advantages in these patients, allowing excellent stability and early weight-bearing. TSF, in respect to other external fixators, has the advantage to correct gradually multiplanar deformi-

ties like angulation, translation, rotation, and shortening, thus minimizing these complications.^{6,19,20,30}

Our study presents some limitations such as the small number of patients enrolled. However, our results encourage us to continue with the use of the TSF for the treatment of children affected by Blount's disease.

Our results are similar to those reported by other studies. TSF is a simple frame construct with easy application whereby a single-stage correction of multi-axial deformities is possible. The technique is simple, accurate, and reproducible.^{27,30} In case of residual deformity correction required can be achieved without surgical means, improving the morbidity rate for the patient and off-loading the surgeon's workload.

CONCLUSION

Our opinion is that TSF allows safe gradual correction and is an accurate and well-tolerated method for the treatment of the Blount disease at any age.

REFERENCES

- Alekberov C, Shevtsov VI, Karatosun V, et al. Treatment of tibia vara by the Ilizarov method. *Clin Orthop Relat Res* 2003;409:199-208.
- Gordon JE, Heidenreich FP, Carpenter CJ, et al. Comprehensive treatment of late-onset tibia vara. *J Bone Joint Surg Am* 2005;87:1561-70.
- Langenskiold A. Tibia vara: osteochondritis deformans tibiae. *Clin Orthop* 1981;158:77-82.
- Schoenecker PL, Meade WC, Pierron RL, et al. Blount's disease: a retrospective review and recommendations for treatment. *J Pediatr Orthop* 1985;5:181-6.
- Laurencin CT, Ferriter PJ, Millis MB. Oblique proximal tibial osteotomy for the correction of tibia vara in the young. *Clin Orthop Relat Res* 1996;327:218-24.
- Coogan PG, Fox JA, Fitch RD. Treatment of adolescent Blount disease with the circular external fixation device and distraction osteogenesis. *J Pediatr Orthop* 1996;16:450-4.
- Wilson NA, Scherl SA, Cramer KE. Complications of high tibial osteotomy with external fixation in adolescent Blount's disease. *Orthopedics* 2007;30:848-52.
- Price CT, Scott DS, Greenberg DA. Dynamic axial external fixation in the surgical treatment of tibia vara. *J Pediatr Orthop* 1995;15:236-43.
- Storen H. Operative elevation of the medial tibial joint surface in Blount's disease. One case observed for 18 years after operation. *Acta Orthop Scand* 1969;40:788-96.
- Janoyer M, Jabbari H, Rouvillain JL, et al. Infantile Blount's disease treated by hemiplateau elevation and epiphyseal distraction using a specific external fixator: preliminary report. *J Pediatr Orthop B* 2007;16:273-80.
- Van Huyssteen AL, Hastings CJ, Olesak M, et al. Double elevating osteotomy for late-presenting infantile Blount's disease: the importance of concomitant lateral epiphysiodesis. *J Bone Joint Surg Br* 2005;87:710-5.
- Bardier M, Senie JN, Fabre J, et al. Temporary epiphyseal stapling of the lower limbs in children suffering from Blount's disease. An experimental study based on a hundred and sixty cases. *Ann Chir* 1982;36:396-401.
- Stevens PM. Guided growth for angular correction: a preliminary series using a tension band plate. *J Pediatr Orthop* 2007;27:253-9.
- Loder RT, Johnston CE. Infantile tibia vara. *J Pediatr Orthop* 1987;7:639-46.
- Ferriter P, Shapiro F. Infantile tibia vara, factors affecting outcome following proximal tibial osteotomy. *J Pediatr Orthop* 1987;7:1-7.
- Smith SL, Beckish ML, Winters SC, et al. Treatment of late-onset tibia vara using Afghan percutaneous osteotomy and orthofix external fixation. *J Pediatr Orthop* 2000;20:606-10.
- Eidelman M, Bialik V, Katzman A. Correction of deformities in children using the Taylor spatial frame. *J Pediatr Orthop B* 2006;15:387-95.
- Henderson RC. Tibia vara: a complication of adolescent obesity. *J Pediatr* 1992;121:482-6.
- Pinkowski JL, Weiner DS. Complications in proximal tibial osteotomies in children with presentation of technique. *J Pediatr Orthop* 1995;15:307-12.
- Stanitski DF, Dahl M, Louie K, et al. Management of late-onset tibia vara in the obese patient by using circular external fixation. *J Pediatr Orthop* 1997;17:691-4.
- Kirgis A, Albreicht S. Palsy of the deep peroneal nerve after proximal tibial osteotomy: an anatomical study. *J Bone Joint Surg Am* 1992;74(8):1180-5.
- Elgafy H, Ebraheim NA, Shaheen PE, et al. Extensor hallucis longus innervation: an anatomic study. *Clin Orthop Relat Res* 2002;398:245-51.
- Dilawaiz Nadeem R, Quick TJ, Eastwood DM. Focal dome osteotomy for the correction of tibial deformity in children. *J Pediatr Orthop B* 2005;14:340-6.
- Gordon JE, Kelly-Hahn J, Carpenter CJ, et al. Pin site care during external fixation in children: results of a nihilistic approach. *J Pediatr Orthop* 2000;20:163-5.
- Rozbruch SR, Fragoman AT, Ilizarov S. Correction of tibial deformity with use of the Ilizarov-Taylor spatial frame. *J Bone Joint Surg Am* 2006;88(4):156-174.

26. Taylor JC. Correction of general deformity with Taylor Spatial Frame 2002. Available at: www.jcharlestaylor.com. Accessed 2007 June;10.
27. Tsibidakis H, Kanellopoulos AD, Sakellariou VI, et al. The role of Taylor Spatial Frame for the treatment of acquired and congenital tibial deformities in children. *Acta Orthop Belg* 2014;80:419-25.
28. Sachs O, Katzman A, et al. Treatment of adolescent Blount disease using taylor spatial frame with and without fibular osteotomy: is there any difference? *J Pediatr Orthop* 2015;35:501-6.
29. Li Y, Spencer SA, Hedequist D, et al. Proximal tibial osteotomy and Taylor Spatial Frame application for correction of tibia vara in morbidly obese adolescents. *J Pediatr Orthop* 2013;33:276-81.
30. Mayer SW, Hubbard EW, Sun D, et al. Gradual deformity correction in Blount disease. *J Pediatr Orthop* 2016; doi: 10.1097/BPO.0000000000000920.

Роль ПРТ – пространственной рамы Тэйлора – для лечения болезни Блаунта

Харидимос Тсибидакис¹, Артемисия Пану², Антониос Ангулес³, Василиос И. Сакелариу⁴, Никола Мачело Портинаро², Юлиан Крумов⁵, Анастасиос Д. Канелопулос⁶

¹ Клиника ортопедии и отделение „Илизаров“, Больница А. Манзони, Леко, Италия

² Кафедра педиатрической ортопедии и нейроортопедии, Университет Милана, Гуманитарная исследовательская больница, Розано (Милан), Италия

³ Кафедра медицинских лабораторий, Технологический образовательный институт, Афины, Греция

⁴ Кафедра ортопедии, Больница „Медитеранео“, Глифада, Греция

⁵ Клиника ортопедии и травматологии, Больница при Военно-медицинской академии, Варна, Болгария

⁶ Кафедра детской ортопедии, Детская больница Ясо, Афины, Греция

Адрес для корреспонденции:

Харидимос Тсибидакис, Клиника ортопедии и отделение „Илизаров“, Больница А. Манзони, ул. Еремо 9/11, 23900, Леко, Италия
E-mail: tsibidakis@hotmail.com
Tel: +393270572793

Дата получения: 23 июня 2017

Дата приемки: 10 августа. 2017

Дата онлайн публикации: 23 сентября 2017

Дата публикации: 30 июня 2018

Ключевые слова: болезнь Блаунта, внешняя фиксация, остеотомия большеберцовой кости, дети, множественная дисплазия

Образец цитирования:

Tsibidakis H, Panou A, Angoules A, Sakellariou VI, Portinaro NM, Krumov J, Kanellopoulos AD. The role of taylor spatial frame in the treatment of Blount disease. *Folia Med (Plovdiv)* 2018;60(2):208-15. doi: 10.1515/fomed-2017-0082

Введение: Изменение остеомиалярной части проксимальной большеберцовой кости является основной характеристикой болезни Блаунта, и если не будет проведено своевременное лечение, выравнивание ноги и нормальное развитие нижних конечностей могут быть нарушены.

Цель: Отчёт о результатах лечения детей с болезнью Блаунта с помощью пространственной рамы Тэйлора.

Материалы и методы: С января 2007 года по декабрь 2014 года 16 детей младшего возраста (24 большеберцовые кости), средний возраст которых составлял 7,5 лет (в диапазоне: 3-14 лет) с тяжелой формой болезни Блаунта прошли лечение с использованием ПРТ. Были проведены предоперационные рентгенографические исследования и были измерены анатомический медиальный ближний угол большеберцовой кости (МБУБК), диафизарно-метафизарный угол большеберцовой кости (угол Levin–Drennan), бедренно-большеберцовый угол и несоответствия длины ног (НДН).

Результаты: Установлено послеоперационное улучшение всех измерений. МБУБК увеличился в среднем с 71,8° (58° - 79°) до 92,5° (90° - 95°), диафизарно-метафизарный угол большеберцовой кости уменьшился с 16,6° (14° - 18°) до 3,6° (0° - 6°), бедренно-большеберцовый угол изменился с 15,4° (10° - 25°) на варус до 5,9° (2° - 10°) на вальгус и НДН снизилось с 208 мм (150-320) до 69 мм (0-120). В среднем период наблюдения составил 45,6 месяца. Согласно критериям Палея инфекция в результате введения игл установлена в 6 случаях, в то время как у 5 пациентов необходимо было изменение методики лечения. Рецидив установлен у 3 пациентов (тройня). Полное восстановление анатомической оси было получено в конце лечения.

Заключение: За последние десятилетия были предложены различные хирургические методы лечения болезни Блаунта (пластины для фиксации, скобы, остеотомия с использованием внешней или внутренней фиксации). Внешняя фиксация с использованием ПРТ позволяет поэтапно и безопасно корректировать множественные дисплазии и является хорошо переносимым методом лечения болезни Блаунта.