

Sygnatura: © Pol J Radiol, 2007; 72(4): 44-49

Otrzymano: 2007.03.19  
 Zaakceptowano: 2007.09.30

## Virtual planning of dental implant placement using CT double-scan technique – own experience

Wadim Wojciechowski<sup>1</sup>, Patryk Kownacki<sup>2</sup>, Stanisław Kownacki<sup>2</sup>, Andrzej Urbanik<sup>1</sup>

<sup>1</sup> Department of Radiology, Collegium Medicum, Jagiellonian University, Cracow, Poland

<sup>2</sup> Private Specialist Dental Clinic KOWDENT, Cracow, Poland

**Author's address:** Wadim Wojciechowski, Department of Radiology, Collegium Medicum, Jagiellonian University, Kopernika 19, 31-501 Cracow, Poland, e-mail: [wwadik@poczta.onet.pl](mailto:wwadik@poczta.onet.pl)

### Summary

**Background:**

The correctness of CT performed with the use of a double-scan technique is the basis for achieving proper quality of 3D reconstructions of the maxilla or mandible and subsequent virtual planning of dental implant placement. The aim of this study was the presentation of the methodology of computed tomography scanning and own experience with the use of the double-scan technique.

**Material/Methods:**

The study group included 26 individuals who underwent MDCT with a double-scan technique using a MDCT scanner SOMATOM Sensation (Siemens, Germany). The parameters of the examination: slice-collimation 10x0.75 mm, slice-thickness 0.75 mm. The first CT scan in the procedure was the scan of the patient wearing a radiological prosthesis and occlusal index, which was followed by a separate scan of the radiological prosthesis. These two CT scans were copied and transferred to PC with Procera Software program (Nobel Biocare, Sweden) where dental implant placement was virtually planned.

**Results:**

In all 26 patients, precise three-dimensional reconstructions of the anatomical structure were obtained. In 11 patients, on the basis of the virtual planning, the implant placement was performed, 5 patients were referred to preparatory procedures, that is, restoration of the alveolar process, otolaryngological treatment of the maxillary sinuses. The remaining 10 patients did not qualify to the procedure because of unfavorable anatomical conditions.

**Conclusions:**

Correct computed tomography with double-scan technique enables virtual planning of dental implant placement, on the basis of which the real procedure of implantation can be performed.

**Key words:**

Implants • Computed tomography • Preoperative planning • 3D imaging.

**PDF file:**

<http://www.polradiol.com/fulltxt.php?ICID=510496>

### Background

Among the imaging modalities available for contemporary medicine, computed tomography (CT) has found a specific application in planning of dental implant placement.

In visualization of potential implant placement sites, CT is an important supplement to clinical examination. Quantitative and qualitative assessment of the bone structure allows to ensure implant stability. Three-dimensional imaging option in CT allows also precise assessment of the adjacent anatomic structures. Such a possibility is provided

by a new method of quick object prototyping, referred to as stereolithography. It is a technique involving 3D prototype model reconstruction based on geometry generated by the computer (CAD – Computer Aided Design).

Spectacular progress has been achieved in CAD during the recent years. Nobel Biocare company presented during the international scientific conference held in Las Vegas in 2003 a system of virtual visualization of implants – NobelGuide, which became available to implantologists all over the world, including Poland, in 2005. The innovative character of NobelGuide project lies in precise diagnostics with the

aim to minimize the risk of failure associated with the procedure. Additionally, this technique allows to eliminate the necessity of impression taking immediately after implant placement, which enables prosthetic reconstruction of the teeth directly after the procedure [1].

Virtual planning is assisted by NobelGuide software, specially developed for this purpose, which allows to present the imaging data obtained from CT. It is possible to regulate bone image transparency to visualize the maxillary sinuses, the nasal cavity, the mental and incisor foramina and the mandibular canal course. The assessment of condition of the bone tissue and adjacent structures in three dimensions allows very precise planning of the sites, axial orientation, size and number of implants.

The quality of CT scans and appropriate format of source files is essential for preoperative planning. Incorrect performance of the CT scan makes it difficult or even impossible to obtain computer visualization.

The aim of this study is to present the methodology of computed tomography scanning and own experience with the use of the double-scan technique in planning of implant placement assisted with NobelGuide computed navigation system.

## Materials and methods

The study was carried out in a group of 26 patients, including 9 women and 17 men aged 32-55 years, who underwent CT examinations performed using the double-scan technique as a preparatory procedure before dental implant placement. The CT scans were performed using a 10-row SOMATOM Sensation 10 scanner (Siemens) with the following parameters used: kV – 120, mAs – 90, feed/rotation – 6 mm, collimation – 10 x 0.75 mm, slice thickness – 0.75 mm, recon increment – 0.5 mm, filters – H60f sharp and H30f smooth. All the scans were performed using the „Care Dose” option to reduce the exposure of the patients to radiation.

When the scanning was completed, the images were recorded on a CD-ROM in the DICOM format and transferred to a PC equipped with NobelGuide software (Nobel Biocare, Sweden), which was used for virtual planning of implant placement procedures. After data import, 3D reconstructions of the

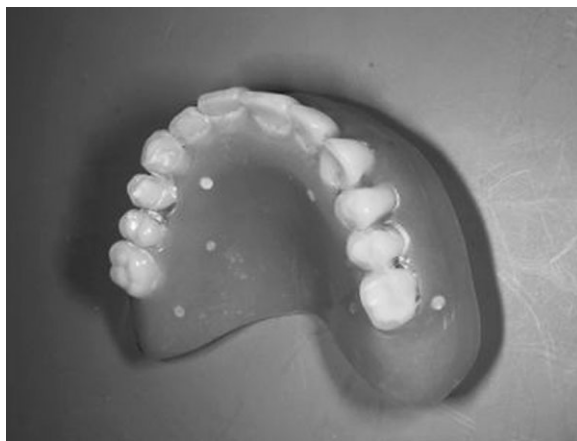

Figure 1. Radiographic guide.

facial portion of the skull and of the radiographic template, as well as virtual planning of the implantation procedure, were prepared for all the patients. The methodology of the CT scans providing the basis for correct planning, essential in this technique, is presented below.

## Methodology of double-scan CT

The patient coming for a CT scan should bring the radiographic template with markers and the occlusal index.

The methodology of double-scan CT involves two image acquisitions:

1. Scanning of the patient with the radiographic template and occlusal index in his/her mouth.
2. The second phase involving taking a separate scan of the radiographic template, placed in the scanner gantry precisely in the same position as in the patient's mouth.

In case of adontia or many teeth missing, a well-fitted denture currently used by the patient serves as the radiographic template. If the denture is damaged or ill-fitted, the dentist orders a new one to be used as the radiographic template, simulating the condition of the patient's teeth and soft tissue surfaces during the scanning procedure (Fig. 1).

During the first scan, the presence of the markers made of biopolymers (gutta-percha) on the radiographic template should be checked. These markers (recommended number 6-8) make correct transformation of the imaging data possible (Fig. 2). Simultaneously with preparation of the radiographic template, the occlusal index is prepared. The occlusal index, usually made of silicone, ensures proper placement of the radiographic template in the patient's mouth during the scan (Fig. 3).

## CT examination technique

### The first scan

1. The radiographic template and the occlusal index are placed in the patient's mouth and the patient should bite on the template and the occlusal index with moderate

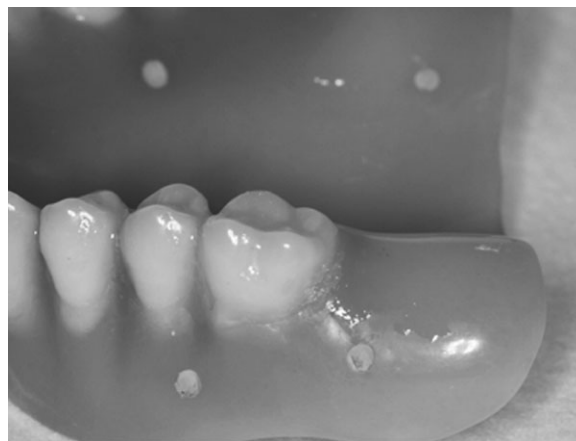

Figure 2. Markers in the radiographic guide.

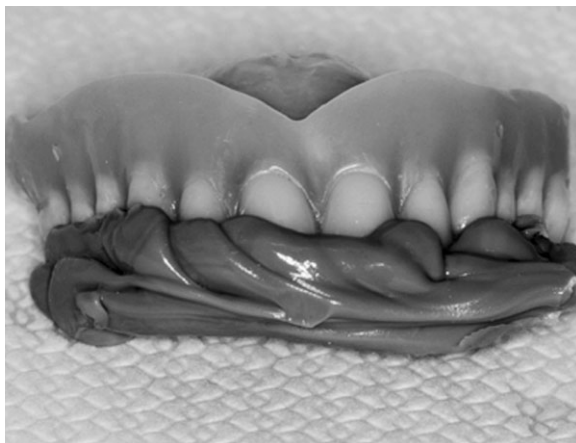
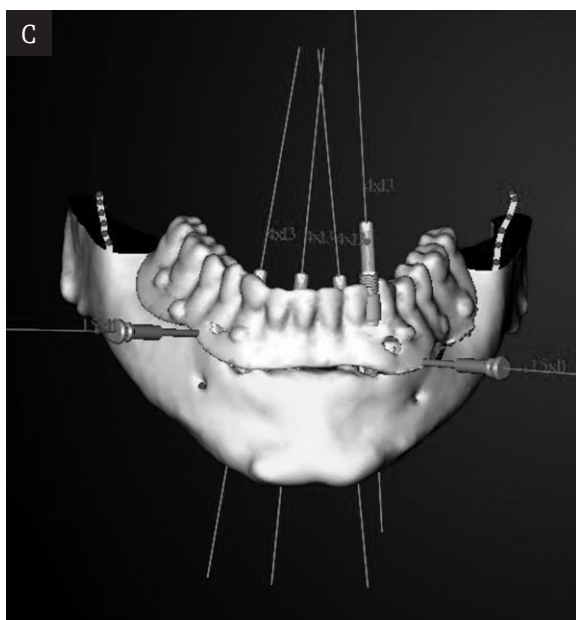
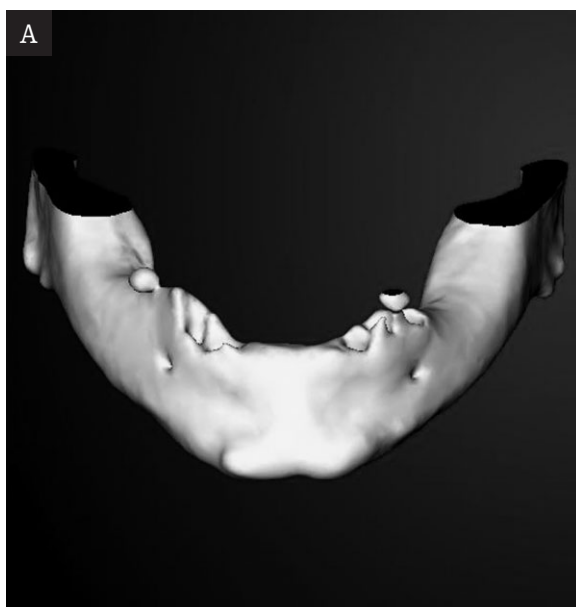

Figure 3. Occlusal index.



strength, because excessive strength causes mucosal deformation and may lead to further inaccuracy in planning of the procedure. At the same time, it should be remembered that the template must adhere closely to the mucous membrane, leaving no air bubbles between the two surfaces.

2. The patient should lie in a comfortable position, such as for head examination.
3. It should be taken into consideration, that if metal denture or crown elements are present, they may generate band-like artifacts resulting from hardening of the radiation beam. Thus, the examination should be planned so as to omit these elements, if possible.
4. During the examination, the patient should neither swallow the saliva nor move.
5. In the next phase, the previously defined double scan protocol was selected.

The examples of protocols for single-row and multi-row detector CT scanners recommended by Nobel Biocare are presented below [2]:

1. Helical, single-row detector CT scan

kV – 120

mAs – 90

Feed/rotation value – 1 mm

Slice thickness – 1 mm

Recon increment – 0.5 mm

Lamp rotation time – 1/sek.

Filters – sharp, bone type

2. Helical, multi-row detector CT scan

kV – 120

mAs – 90

Collimation – lowest possible in the given system

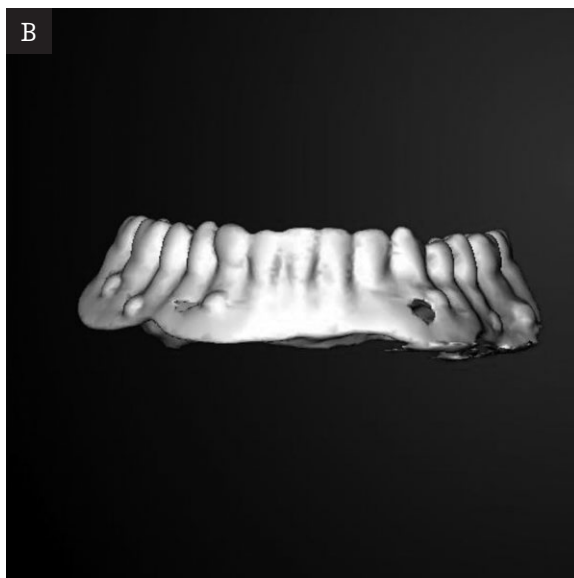


Figure 4. Implants planning. **A.** 3D reconstruction of the craniofacial bone structure. **B.** 3D reconstruction of the radiographic guide. **C.** Virtual implants in the 3D reconstruction.

Feed/rotation value – dependent on the used collimation and lamp rotation time  
 Slice thickness – 100% of collimation  
 Recon increment – most frequently 50% of detector thickness (usually 0.3 or 0.5 mm)  
 Filters – sharp, bone type

In single-row detector CT scanners, the lowest possible slice thickness should be used – most often 1 mm, whereas in multi-row detector CT scanners the manufacturers of the equipment use various detector systems and sometimes specify different variables for the examination protocols. Therefore, the protocols of the most popular manufacturers are presented below on the basis of data provided by Nobel Biocare guide [2] with slight own modifications.

Planning the examination, it should be remembered that with optimal setting of the parameters the lowest possible radiation dose should be used.

GE	Siemens
LightSpeed 16	Sensation 16
kV – 120	kV – 120
mAs – 90	mAs – 90
Collimation – 16 x 0.625 mm	Collimation – 16 x 0.75 mm
Slice width – 0.625 mm	Slice width – 0.75 mm
Pitch – 0.9375	Feed/rotation – .6 mm
Recon increment – 0.3 or 0.5 mm	Recon increment – 0.5 mm
Rotation time – 1 s	Rotation time – 0.75 s
Reconstruction kernel – Bone	Reconstruction kernel – H60f
Philips	Toshiba
Mx*8000 IDT	Aquilon Multi 16
kV – 120	kV – 120
mAs – 120	mAs – 120
Collimation – 16 x 0.75 mm	Collimation – 16 x 0.5 mm
Slice width – 0.75 mm	Slice width – 0.5 mm
Pitch – 0.75	Feed/rotation – 6 mm
Recon increment – 0.5 mm	Recon increment – 0.3 mm
Rotation time – 0.75 s	Rotation time – 0.75 s
Resolution: standard	Reconstruction kernel – Bone
Reconstruction kernel – D	

The scope of the CT scan is planned on the basis of a previously prepared topogram, with such adjustment of the gantry angle, if necessary, as to ensure that the hard palate is in the scanning plane.

In case of mandibular CT scans, the scanning plane should be horizontal to the central part of mandible base at the level of premolars.

### The second scan

When the first scanning procedure is completed, the patient takes the radiographic template out of his/her mouth and leaves the room. The occlusal index is not scanned in the second phase. During the second phase, when a separate scan of the radiographic template is taken, it should be placed in the scanner gantry exactly in the same position as in the patient's mouth. To achieve that, fixing the template on the bolster placed under the patient's head during the first scan with adhesive plaster, or using a container



Figure 5. Surgical guide.

developed for this purpose, made of material characterized by low absorption of radiation (foamed polystyrene or even paper) is recommended. The second scan is performed using the same parameters as during the first one.

When the scanning is completed, the CT images should be recorded on a CD-ROM in the DICOM format. It should be remembered that the data stored in this format must not be compressed with zip, arj type packers. Doing this would make subsequent transfer to the NobelGuide console impossible.

In the authors' own studies, the images obtained in both phases of CT were transferred to a PC with NobelGuide software (Nobel Biocare, Sweden) installed, which was used for virtual planning of the implantation procedures.

First, a 3D model of the patient's facial skeleton was generated (Fig. 4a), followed by development of a 3D model of the radiographic template (Fig. 4b). The next planning phase involved placement of virtual implants in this model (Fig. 4c).

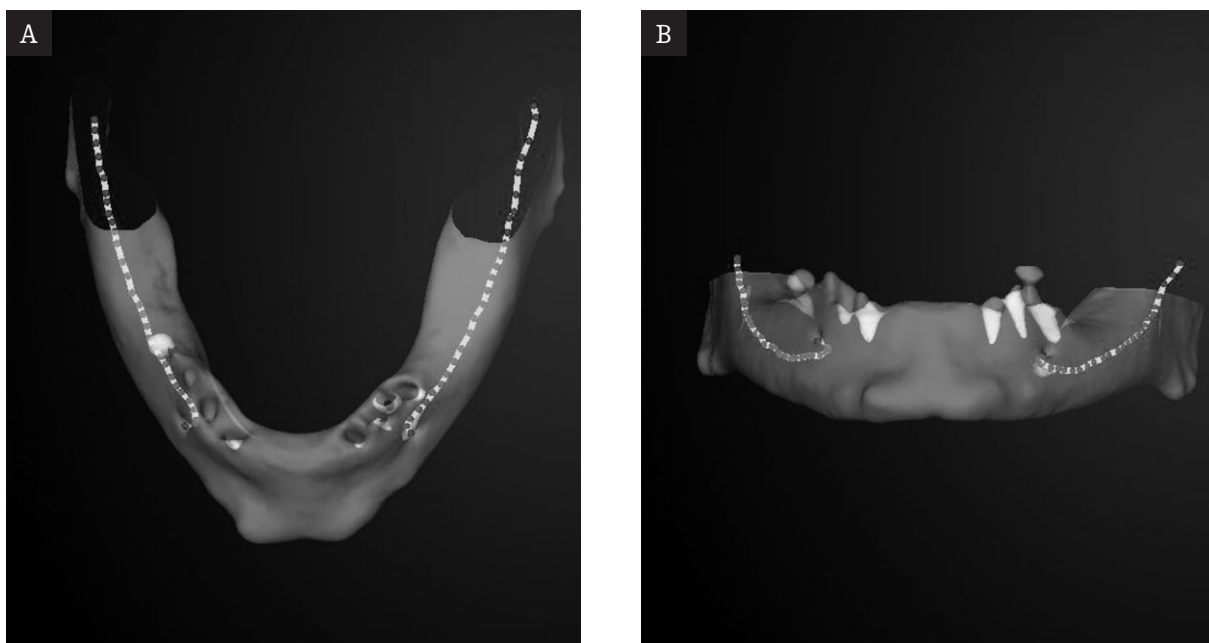
The ultimate goal of the planning procedure was to prepare a joint model of the facial skeleton, prosthesis and implants, which, in the case of patients qualified for implant placement, served as a basis for preparation of a surgical template (Fig. 5). This template is created as a result of stereolithography and serves as a guide for reamer insertion for precise placement of the implants, utilizing the simulated implant dimensions, such as width, insertion angle and depth in practice.

## Results

In all 26 patients, precise 3D reconstructions of maxillary or mandibular structures were obtained, making use of an additional option involving indication of alveolar recesses and maxillary sinuses with markers, and in case of mandibular CT indication of the mandible canal with a line and additional markers (Fig. 6). Such procedure facilitates considerably further virtual planning of implantation surgery and protects the patients from potential complications.

Implantation based on the planning procedure was performed in 11 cases, 5 patients were referred for preparatory procedures (alveolar process restoration or otolaryngological treatment of the maxillary sinuses). The remaining 7 patients





**Figure 6.** Markers in the mandible canal. **A.** Occlusal view. **B.** Frontal view.

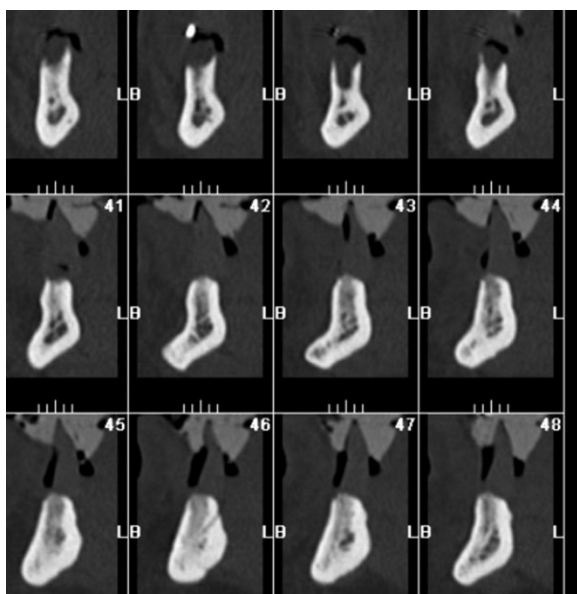
were disqualified from the procedure, which was impossible because of unfavorable anatomical conditions, and 3 withdrew their consent for the procedure at the last stage of preparation.

After implant placement, all the patients have been under regular follow-up. The longest observation time is 8 months. To date, no complications associated with implantation procedures planned on the basis of double-scan CT have been observed.

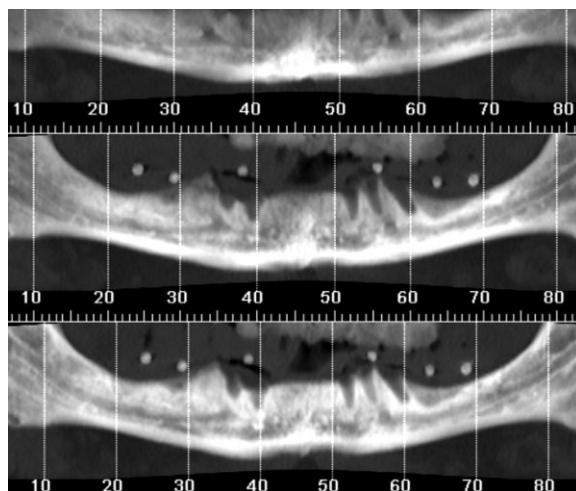
**Discussion**

The role of computed tomography in dental surgery, namely, planning of implantation procedures has markedly increased

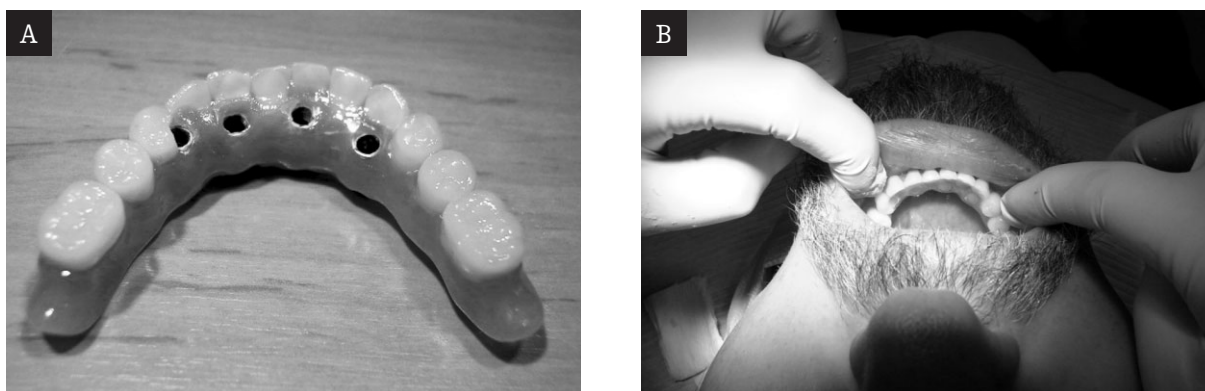
during the last five years [3-5]. Axial and two-dimensional views generated in different planes in computed multiplanar reconstruction process (MPR) allow to present precisely the anatomical conditions. They are most frequently used in the patients with many teeth missing or complete adontia, in whom treatment involving placement of multiple implants is considered [6]. Additional use of software designed for special data processing allows to obtain reconstructions appropriately adjusted to the dental arch and the curvature of each jaw [7]. As a result of such processing, pantomographic reconstructions are generated. Also 3D reconstructions can be obtained [4]. Such reconstructions allow precise presentation of the anatomical features of facial skeletal structures; in particular, the integrity of compact bone layer and spongy bone structures of the maxilla or mandible can be assessed. Additionally, the location of such structures as the incisor canal or mandible canal can be visualized to avoid potential complications, both intra- and



**Figure 7.** Paraxial reconstruction.



**Figure 8.** Pseudopantomographic reconstruction.



**Figure 9.** Dental implant surgery. A. Prosthetic appliances before dental implant surgery. B. Patient after dental implant surgery. Immediately loaded dental implants.

postoperative, which may occur as a result of variations in their course and dimensions [8]. The assessment includes precise linear measurements of bone structures of the maxillary or mandibular alveolar process, evaluation of the presence and grade of osteoporosis (CT makes it possible to assess density of the cortical layer and spongy bone), as well as localization of the adjacent structures important for planning of dental implant placement. As a result of secondary processing, involving generation of transsectoral (Fig. 7) and pseudopantomographic reconstructions (Fig. 8) the images are usually presented on films in actual dimensions (scale 1:1). With NobelGuide software, interactive presentation of 3D reconstructions is possible. Simulation of the procedure is presented on the screen, and the implants are placed in the pre-planned sites. Then their location and spatial relations with the surrounding anatomical structures is assessed. Measurements can be taken at any stage of the planning procedure. Such precise planning of the surgery enabled Nobel Biocare company to develop the „Teeth-in-an-hour” concept. This method is becoming increasingly popular and is closely connected with double-scan CT technique.

The presence of artifacts originated by tooth fillings, usually made of amalgamate, or metal elements of previously placed dentures may make 3D reconstructions more difficult [9], whereas movement-related artifacts have been

practically eliminated owing to the introduction of helical multi-row detection CT scanners, which has considerably reduced the image acquisition time and created better opportunities for generation of secondary reconstructions.

In the authors' work, no technical problems associated with double-scan CT were encountered. There were no errors in transfer of the data from the CT console to the NobelGuide terminal. The program retrieved and processed data recorded on CD-ROM directly on the Siemens console. It was also compatible with the MagicView device (Siemens).

The H60f Sharp filters recommended by Nobel Biocare were observed to cause image sharpening to such extent that in 3 cases a few artifacts were generated, interpreted by NobelGuide software at the later stages of planning as gutta-percha markers. Therefore, additional reconstructions with H30F Smooth filters used were obtained for all the patients in postprocessing.

## Conclusions

Computed tomography performed correctly using the double-scan technique enables virtual planning of dental implant placement, which provides the basis for the real implantation procedure (Fig. 9).

## References:

- Łomżyński L., Mierzwińska-Nastalska E. Natychmiastowe obciążenie implantów z zastosowaniem technologii NobelGuide. *Protetyka Stomatologiczna* 2006; LVI 2: Marzec-Kwiecień, 63-67.
- Nobel Biocare. Concept Radiologist, Clinicians, Laboratories and other working with NobelGuide. Procedures and Products – powered by ProCera NobelGuide 2005; I: 39-42.
- Casap N, Wexler A, Lustmann J. Image-guided navigation system for placing dental implants. *Compend Contin Educ Dent* 2004; 25: 783-786.
- Cavalcanti MG, Ruprecht A, Vannier MW. 3D volume rendering using multislice CT for dental implants. *Dentomaxillofac Radiol* 2002; 31: 218-223.
- Granz SD, Presurgical planning with CT-derived fabrication of surgical guides. *J Oral Maxillofac Surg* 2005; 63: 59-71.
- Friedland B. Implant radiography. *J Mass Dent Soc* 2003; 51: 14-17.
- Kupeyan HK, Schaffner M, Armstrong J. Definitive CAD/CAM-Guided Prosthesis for Immediate Loading of Bone-Grafted Maxilla: A Case Report. *Clinical Implant Dentistry and Related Research* 2006; 8: 161-167.
- Mraiwa N, Jacobs R, Van Cleynenbreugel J, et al. The nasopalatine canal revisited using 2D and 3D CT imaging. *Dentomaxillofac Radiol* 2004; 33: 396-402.
- Link TM, Berning W, Scherf S, et al. CT of metal implants: reduction of artifacts using an extended CT scale technique. *J Comput Assist Tomogr.* 2000 Jan-Feb; 24(1): 165-72.