

# Early severe coronary heart disease and ischemic heart failure in homozygous familial hypercholesterolemia

## A case report

Hongyu Kuang, BM<sup>a,b</sup>, Xue Zhou, BM<sup>a,b</sup>, Li Li, BM<sup>c</sup>, Qijian Yi, MD<sup>a,b</sup>, Weinian Shou, PhD<sup>d</sup>, Tiewei Lu, MD<sup>a,b,\*</sup>

### Abstract

**Rationale:** Familial hypercholesterolemia (FH) is a common inherited cause of coronary heart disease (CHD) and premature death in an early age. Nevertheless, an ischemic heart failure (IHF) associated with FH seems to be rare, and an early diagnosis and therapy could influence the prognosis.

**Patient concerns:** In this 13-year-old girl, multiple xanthomas began to develop from the first day of birth. Until June, 2017, she was admitted to our center due to edema, oliguria, and dyspnea during exertion, which was attributed to a recent respiratory infection.

**Diagnosis:** Homozygous FH (HoFH), CHD, and IHF.

**Interventions:** The patient has been treated with statin, ezetimibe, aspirin, and traditional heart failure (HF) medications. In addition, the beta-blocker was simultaneously administered.

**Outcomes:** Genotypes of this proband indicated homozygous mutations of low-density lipoprotein receptor (LDLR) and some co-segregated mutations, such as von Willebrand factor (VWF) and fibroblast growth factor receptors. At 6-month follow-up, we found a decreased level of plasma lipid profile, in addition to a significant improvement in 6-minute walk distance and functional class. Echocardiography indicated nonsignificant improvements in the structure and function of the heart.

**Lessons:** This case report indicates that HoFH can lead to dramatically progressive endothelial damages and ventricular remodeling, severe atherosclerosis, even IHF. Genetic outcomes indicate IHF with HoFH could possibly result from LDLR mutations and some co-segregated mutations influencing endothelial function and cardiovascular remodeling. In a short-term follow-up, a combination of statins, ezetimibe, aspirin, and traditional HF agents is safe and effective for IHF with HoFH, and there is a need for further identification of drugs to ameliorate endothelial function and cardiovascular remodeling which may play an important role in long-term treatment.

**Abbreviations:** BNP = B-type natriuretic peptide, CHD = coronary heart disease, FC = functional class, FGFR = fibroblast growth factor receptor, FH = familial hypercholesterolemia, HF = heart failure, HoFH = homozygous FH, IHF = ischemic heart failure, LDL-C = low-density lipoprotein cholesterol, LDLR = low-density lipoprotein receptor, LVEF = left ventricular ejection fraction, VWF = von Willebrand factor PCSK-9 = protein convertase subtilisin kexin type 9.

**Keywords:** coronary heart disease, familial hypercholesterolemia, ischemic heart failure, low-density lipoprotein receptor

Editor: N/A.

The authors have no conflicts of interest to disclose.

<sup>a</sup> Department of Cardiology, Children's Hospital of Chongqing Medical University, Ministry of Education Key Laboratory of Child Development and Disorders,

<sup>b</sup> China International Science and Technology Cooperation Base of Child Development and Critical Disorders, Chongqing Key Laboratory of Pediatrics,

Chongqing, <sup>c</sup> Department of Cardiology, West China Affiliated Second University Hospital, Sichuan, China, <sup>d</sup> Riley Heart Center, Herman B Wells Center for Pediatric Research, Indiana University School of Medicine, Indianapolis, IN.

\* Correspondence: Tiewei Lu, Zhongshan 2nd Street, Yuzhong District, Chongqing, China (e-mail: [ltw200145@163.com](mailto:ltw200145@163.com)).

Copyright © 2018 the Author(s). Published by Wolters Kluwer Health, Inc.

This is an open access article distributed under the Creative Commons Attribution-NoDerivatives License 4.0, which allows for redistribution, commercial and non-commercial, as long as it is passed along unchanged and in whole, with credit to the author.

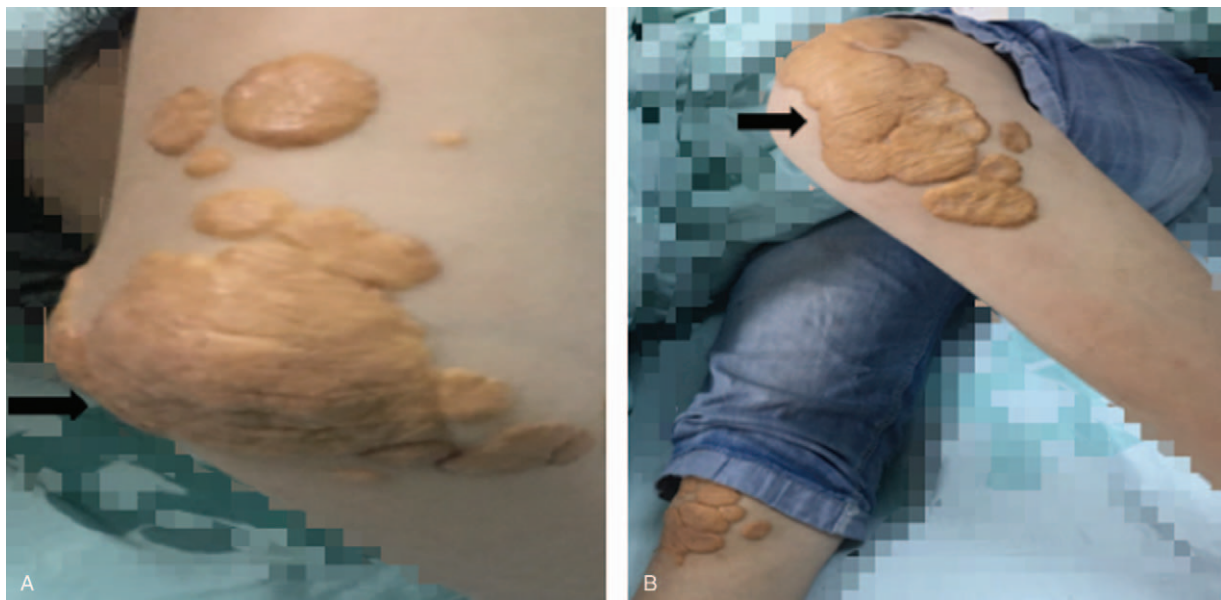Medicine (2018) 97:42(e12869)

Received: 12 May 2018 / Accepted: 28 August 2018

<http://dx.doi.org/10.1097/MD.0000000000012869>

## 1. Introduction

Familial hypercholesterolemia (FH) has been identified as an autosomal dominant disorder that leads to predisposing accelerated atherosclerosis and premature coronary heart disease (CHD). FH may be caused by mutations in the low-density lipoprotein receptor (LDLR), resulting in an extreme elevation of low-density lipoprotein cholesterol (LDL-C) levels.<sup>[1]</sup> Most people with FH are diagnosed based on high cholesterol levels because they present no visible symptoms. Additionally, heterozygous FH is a frequent monogenic hereditary disorder in the general population with a prevalence of approximately 1/200 subjects; conversely, homozygous FH (HoFH) is a rare condition with a prevalence of approximately 1/1,000,000.<sup>[2–4]</sup> Symptoms including multiple xanthomas in the tendons, skin, and eyelids, and rarely the arcus cornea are specific to FH. The clinical diagnosis mainly is based on cholesterol levels. Endothelial dysfunction begins from conception in FH patients, particularly in HoFH individuals; it progressively causes



**Figure 1.** Multiple xanthomas in elbows (A) and pateller (B).

premature aortic valvular stenosis and coronary atherosclerosis, and even early death. We are highlighting this case because there were no symptoms of acute myocardial ischemia, but the patient experienced chronic heart failure (HF). Currently, a 13-year-old girl with severe CHD and ischemic HF (IHF) was admitted to the Department of Cardiology, Children's Hospital of Chongqing Medical University in June, 2017, for a history of edema, oliguria, and dyspnea; she had never previously exhibited any chest pain or discomfort or palpitation. Eventually, the patient obtained a good prognosis using a combined therapeutic strategy of high-dose statins, ezetimibe, and drugs for HF. The patient has provided informed consent for the publication of this report.

## 2. Case report

A 13-year-old girl from a city in western China had a history of edema, oliguria, and dyspnea during exertion for 9 days, which was attributed to a recent respiratory infection. Surprisingly, the child had experienced multiple xanthomas from the first day of birth, with a progressive expansion. The first-degree relatives (parents, the little brother, and the elder sister) were free from similar nodular xanthomas, and no specific family history of CHD was notable.

Currently, she is 151 cm tall and weighs 41 kg (body mass index 18.0). Her baseline exercise capacity was assessed: she was classified as functional class (FC) III, which is associated with a 6-minute walk distance of 212 to 240 m. A physical examination revealed the following data: T: 36.8°C; P: 122 beats per minute; R: 29 times per minute; blood pressure: 106/64 mm Hg. There were multiple xanthomas around the tendons of her feet, hands, elbows, patellar, and buttocks, with a maximum diameter of 55 mm (Fig. 1). On cardiac examination, the apex beat was detected in the left intercostal space 3 mm outside the middle of the clavicle, with a limited beating range. Mild to moderate edema was present in the lower limbs.

Examinations revealed high levels of C-reactive protein (59 mg/L) and procalcitonin (1.138 ng/mL). Furthermore, a significant elevation of her plasma lipid profile was detected and is shown in Table 1 and Fig. 2. B-type natriuretic peptide (BNP) was elevated to 558.73 pg/mL, which is in accordance with a clinical diagnosis of HF. Electrocardiograph marked apparent ST segment changes, and echocardiography indicated a diffuse ventricular and atrial hypertrophy, which is associated with a significant decrease of left ventricular ejection fraction (LVEF) as 31%. Diffuse atherosclerotic burden and stenosis, and calcified changes were detected in computed tomography (CT) and CT

**Table 1**

**Lipid profile of index case compared with the standard of normality and FH concentration.**

Case	Total cholesterol, mmol/L	Triglyceride, mmol/L	LDL-cholesterol, mmol/L	HDL-cholesterol, mmol/L
Index case	14.73	1.41	13.44	0.59
Father	9.16	2.79	7.64	0.88
Mother	6.85	0.81	5.41	1.24
Sister	6.57	0.51	5.06	1.54
Brother	5.13	0.59	3.76	1.16
Normal range	2.7–5.5	0.3–1.8	0–3.1	0.91–2.27
Pediatric FH*	>6.7	—	>4.0	—

Plasma lipid was examined by homogeneous enzyme immunoassay with HDL-Cholesterol plus 3rd generation (HDL-C3), triglycerides (TRIGL), LDL-Cholesterol plus second generation (LDL-C). FH=familial hypercholesterolemia, HDL=high-density lipoprotein, LDL=low-density lipoprotein.

\* According to Simon Broome familial hypercholesterolemia register diagnostic criteria for familial hypercholesterolemia (FH).<sup>[6]</sup>

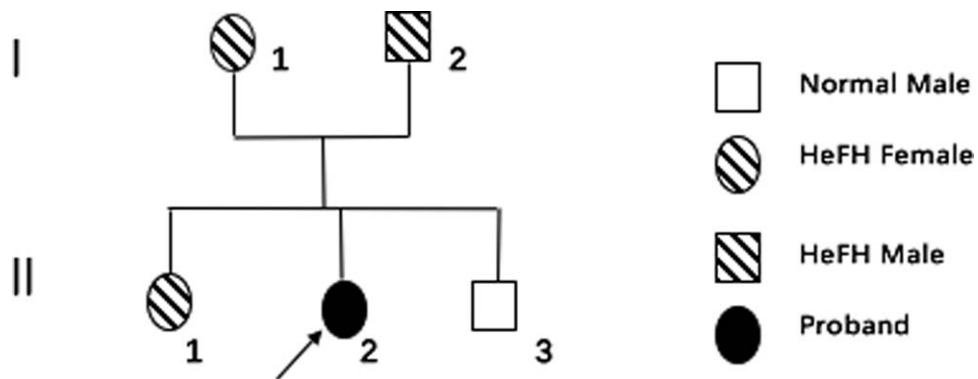


Figure 2. The chart of the proband and affected kindred based on phenotypes).

angiography in the ascending aorta, descending aorta, and coronary arteries, as shown in Fig. 3. A fatal stenosis was present in 93% of the main trunk in the left coronary artery, 65% in the left anterior descending (LAD) branch, and 42% in the right coronary artery (RCA), which was caused by atherosclerosis.

Genomic DNA samples were sheared and then hybridized to enrich the exonic DNA. Consent was obtained from the patient and her parents. In addition, an ethics committee (Children’s Hospital Medical University) approved this study. The DNA libraries were tested for enrichment using qPCR and for size

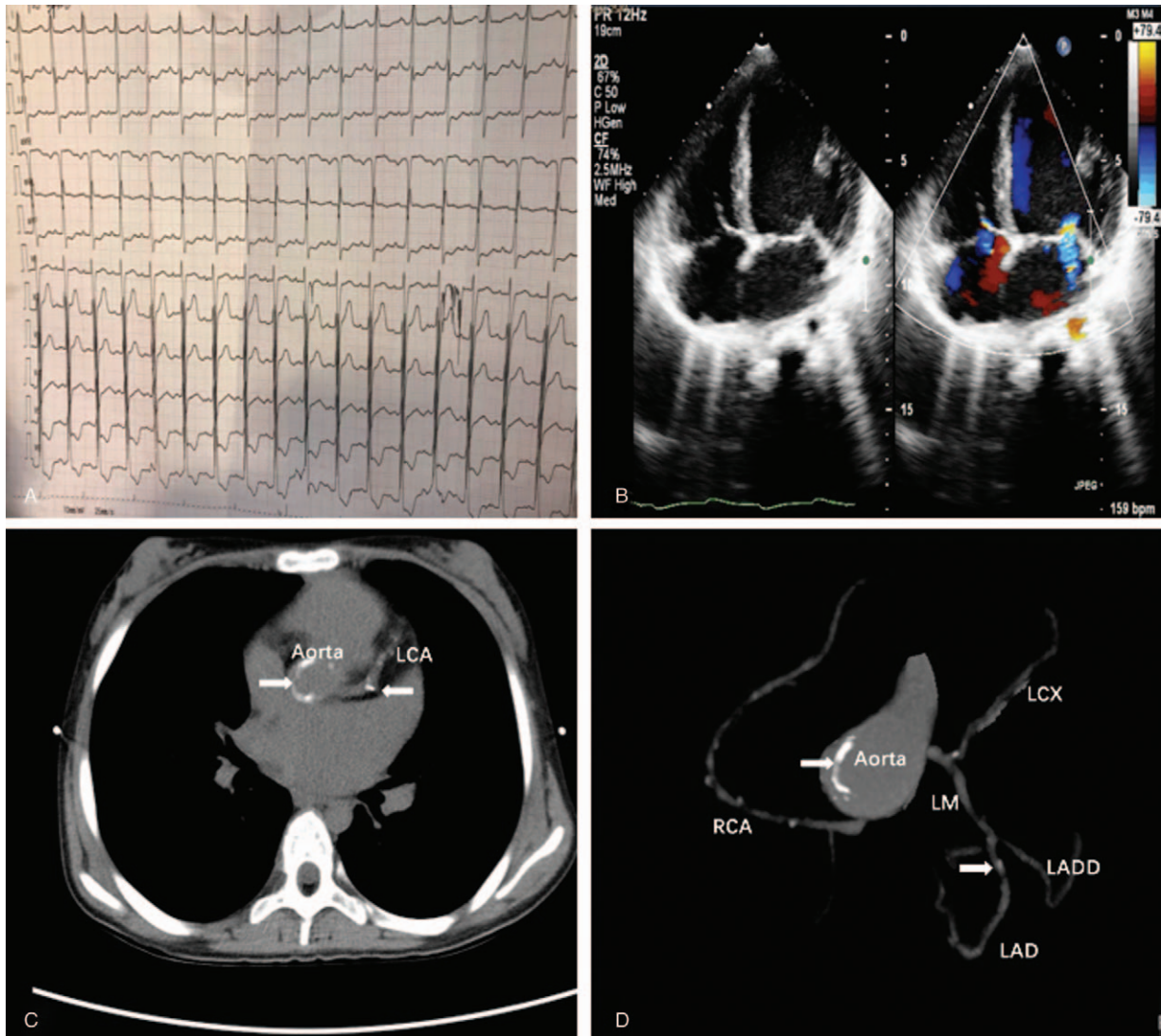


Figure 3. Imaging characteristics of the proband, including ECG (A), echocardiogram (B), and CT (C and D) (arrow: the calcification changes in multiple arteries). CT=computed tomography.



**Table 2**  
**Phenotype and genotypes of affected kindred.**

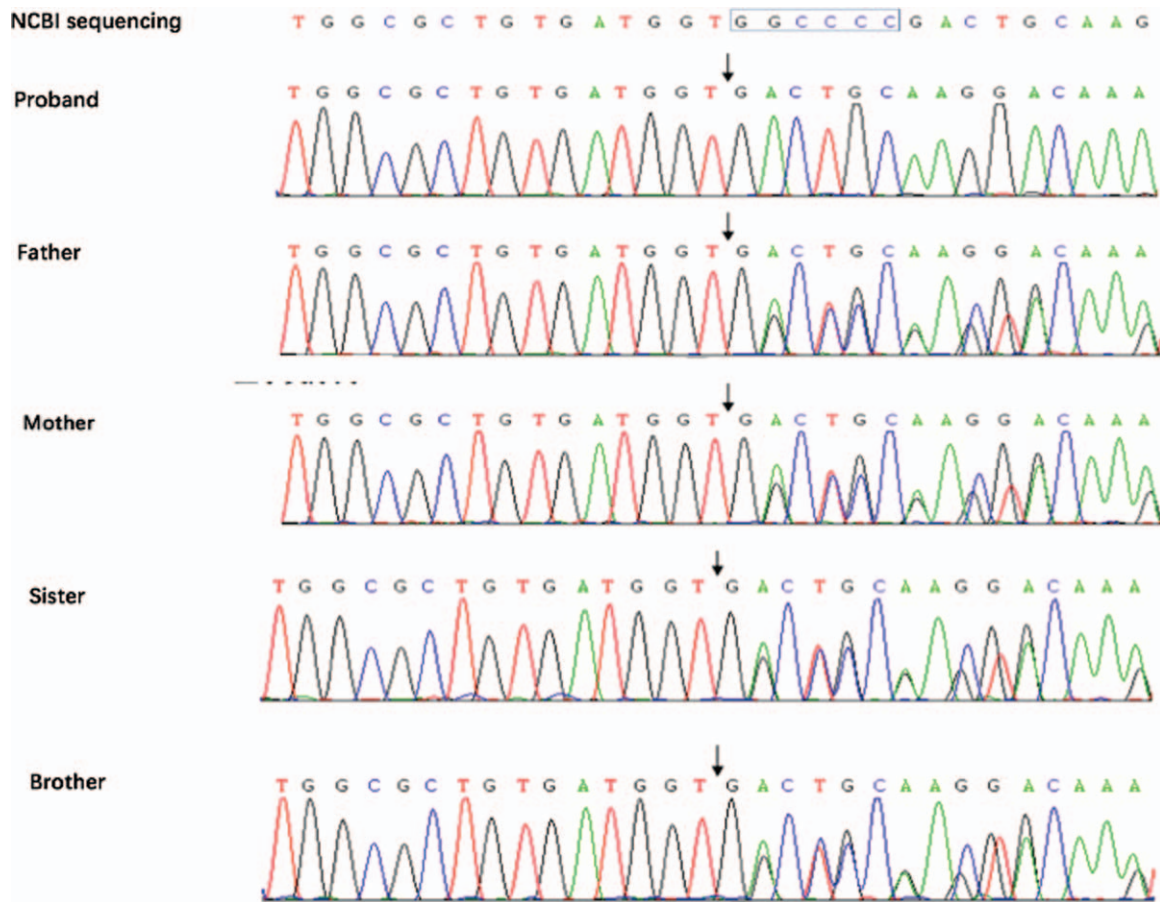
	Age (y)	Mucocutaneous	Phenotype*	Genotype
Index case	13.7	Xanthomas	Ho FH	LDLR AA
Father	52	Normal	He FH	LDLR Aa
Mother	42	Normal	He FH	LDLR Aa
Brother	11	Normal	Basically Normal	LDLR Aa
Sister	20	Normal	He FH	LDLR Aa

FH=familial hypercholesterolemia, HeFH=heterozygous FH, HoFH=homozygous FH, LDLR=low-density lipoprotein receptor.  
\*Based on the clinically diagnostic guideline respectively in adults and children.

distribution and concentration using an Agilent Bioanalyzer 2100. Then, exon-enriched DNA was sequenced by the Illumina HiSeq2500 platform following the manufacturer’s instructions (Illumina). Raw image files were processed using BclToFastq (Illumina) for base calling and generating the raw data. The low-quality variations were removed using a quality score  $\geq 20$  (Q20). The sequencing reads were aligned to the NCBI (www.ncbi.nlm.nih.gov) human reference genome (hg19) using BWA. Sanger sequencing was used to confirm the mutated genes of the proband. The genotypes of the proband and affected kindred are shown in Table 2. The homozygous form (2 mutated alleles) was indicated in the proband’s genotype, and the heterozygous form (unilateral mutated allele) was indicated in the proband’s first-grade relatives for the LDLR function chr-19: 11216237–11216242, c.655 (exon4)\_c.660 (exon4)delGGCC-

CCC, p.219Ala\_220Prodel; rs879254617 (Fig. 4); these genes were possibly tightly linked to some co-segregated mutations influencing endothelial function and cardiovascular remodeling. Six genetic mutations displayed this phenotype: fibroblast growth factor receptor (FGFR)-2 (chr-10:123353406–123353406, c.75 (exon2) C>T, rs41287990), von Willebrand factor (VWF) (chr-12, 6647238- 6647238, c.6644 (exon17) C>T, rs201703764), DCHS1 (chr-11, 6103273–6103273, c.6353 (exon37) G>A, rs375779188), TTN (chr-2, 179640101–179640101, c.6490 (exon28) G>A, rs56285559), VHL (chr-3, 10183649–10183649, c.118 (exon1) C>G) and DNAJB6 (chr-7, 157178324–157178324, c.710 (exon8) G>A, rs199612810).

The proband patient was administered atorvastatin (20 mg/d), ezetimibe (20 mg/d), and traditional HF medications, such as digoxin, diuretics, and angiotensin-converting enzyme inhibitor



**Figure 4.** The mutation site of the FH proband and proband’s first-grade relatives (Proband: sequence of the homozygous mutation (c.655 (exon4)\_c.660 (exon4) delGGCCCC; Father/Mother/Sister/Brother: sequence of the heterozygous mutation (c.655 (exon4)\_c.660 (exon4)delGGCCCC). FH=familial hypercholesterolemia.

(ACEI). She was simultaneously treated with aspirin. Additionally, beta-blockers were administered to prevent ventricular remodeling. After 6 months, her total cholesterol levels decreased by approximately 11.7% (from 14.73 to 13.0 mmol/L), her LDL-C levels decreased by 14.3% (from 13.44 to 11.52 mmol/L), and her high-density lipoprotein cholesterol levels increased from 0.59 to 0.73 mmol/L. Clinically, her exercise capacity and FC significantly improved. When assessing cardiac structure, echocardiography indicated nonsignificant improvements in cardiac hypertrophy (left ventricular dilation 64 vs 61 mm) and cardiac function (LVEF 43% vs 31%).

### 3. Discussion

Familial hypercholesterolemia is a disease characterized by lifelong elevated cholesterol levels; therefore, it is a potential cause of premature CHD.<sup>[5]</sup> There are 3 well-known international criteria regarding FH diagnosis, and the Simon Broome standard was applied in the current case, which includes the family history, clinical signs, the cholesterol concentration levels, and genotype.<sup>[6]</sup> Mutations in the LDLR, apolipoprotein B, and protein convertase subtilisin kexin type 9 genes have been noted in patients with FH. As mentioned above, a point mutation in the LDLR gene is commonly identified, and more than 1600 mutations have been documented worldwide. The LDLR gene consists of 18 exons, and the encoding key proteins are involved in the LDLR endocytic and recycling pathways<sup>[1,7-9]</sup>.

A defective LDLR has been noted with elevated cholesterol concentrations, especially LDL-C, which impairs endothelial function and leads to premature CHD. Coronary arterial stenosis and acute myocardial infarction are the most common complications threatening FH cases; moreover, the genotype identified as HoFH in LDLR mutations could lead to progressive cardiovascular impairments and chronic HF. Clinically, the patient manifested edema and exercise dyspnea as an inducer of recent respiratory infection; there was no history of chest pain or acute ischemic damages. A series of laboratory and imaging findings identified chronic HF with an elevated BNP, enlarged ventricular and damaged LVEF. Proofs indicated that IHF was possibly caused by severe CHD at early stages and other potential factors. The pathological mechanism may be related to the dysfunctional endothelial cells and cardiomyocytes that lead to cardiac ischemia and reperfusion, progressive remodeling of cardiomyocytes, and cardiac dysfunction.<sup>[10]</sup> Unlike previous cases of HoFH, the cardiovascular lesions may have resulted from the cosegregated mutations influencing endothelial function and cardiovascular remodeling linked to LDLR mutations. VWF, which was first described in the 1900s, is proposed as a risk factor of cardiovascular diseases. It is selectively produced in ECs implicated in the pathogenesis of atherosclerosis, further promoting localized inflammation and inducing plaque formation. Also, a mutation of VWF could lead to a decrease level of plasma VWF, which would contribute to a tendency of bleeding.<sup>[11]</sup> Moreover, House et al<sup>[12]</sup> have demonstrated the essential role of FGFR-2 in endothelial cells for vascular remodeling after ischemic injury. FGFRs were shown to be an essential part of vascular calcification, arteriosclerotic plaque formation, ischemia-reperfusion, and myocardial energy metabolism characterized by the apoptosis of vascular smooth muscle cells and cardiac cells.

The pharmacological recommendations include an adequate dose of statins to reduce the LDL-C concentrations to below approximately half the baseline level for adults with FH, if

tolerated. If not tolerated, additional drugs such as ezetimibe should be considered. For children, statins and ezetimibe are also the first-line choice for HoFH to regulate LDL-C levels; however, the average life expectancy of patients with HoFH is less than 18 years. In this case, a combination therapy of statins and ezetimibe is efficient to decrease the risk of severe cardiovascular events; however, this therapy cannot reverse the vascular stenosis, calcified changes, and chronic ischemic lesions. For such symptoms of HF induced by respiratory infection, which has been considered the most common factor, early traditional medications could relieve symptoms and improve cardiovascular disorders clinically, and an amelioration of exercise tolerance and FC grade was reported during a short-term follow-up. However, nonsignificant improvements in ventricular enlargement and ejection function were detected, which required a further treatment and follow-up.

Hence, the current study provides further support that HoFH can lead to dramatically elevated plasma cholesterol concentrations and cardiovascular events, even IHF, at an early age. However, a good prognosis during a short-term follow-up is possible with a combination therapy of statins, ezetimibe, aspirin, and drugs for HF. Furthermore, it is identified that beta-blockers can delay the progress of structural and functional cardiovascular changes. Additionally, the co-segregated mutations in VWF and FGFR-2 may aggravate the endothelial lesions and cardiovascular remodeling, causing IHF eventually. Consequently, the drugs to modulate the VWF levels and ameliorate nutrition for vascular smooth muscle cells and cardiac cells could be considered for patients with HoFH and IHF. When necessary, plasma exchange and a heart-liver transplantation are further options for HoFH with refractory CHD.

### Acknowledgments

On behalf of all co-authors, Professor Lu and Miss Kuang state thank to the contributions from Mrs Xiang in Echocardiology Room and Mr Feng in the Department of Radiology, for a provision of technical supports in imaging diagnosis.

### Author contributions

**Conceptualization:** Hongyu Kuang.

**Data curation:** Hongyu Kuang, Xue Zhou, Li Li, Tiewei Lu.

**Formal analysis:** Hongyu Kuang.

**Methodology:** Weinian Shou.

**Supervision:** Tiewei Lu.

**Writing – original draft:** Hongyu Kuang.

**Writing – review & editing:** Hongyu Kuang, Qijian Yi, Weinian Shou, Tiewei Lu.

### References

- [1] Nordestgaard BG, Chapman MJ, Humphries SE, et al. Familial hypercholesterolaemia is underdiagnosed and undertreated in the general population: guidance for clinicians to prevent coronary heart disease: Consensus Statement of the European Atherosclerosis Society. *Eur Heart J* 2013;34:3478–13478.
- [2] Onorato A, Sturm AC. Heterozygous Familial Hypercholesterolemia. *Circulation* 2016;34:13–24.
- [3] Deswal S, Kapoor A, Sibal A, et al. Homozygous familial hypercholesterolaemia in two boys aged 5 and 10 years. *Paediatr Int Child Health* 2016;36:308–11.
- [4] Widhalm K, Benke IM, Fritz M, et al. Homozygous familial hypercholesterolemia: summarized case reports. *Atherosclerosis* 2017; 257:86–9.

- [5] Martin AC, Gidding SS, Wiegman A, et al. Known and unknowns in the care of paediatric familial hypercholesterolaemia. *J Lipid Res* 2017;jr.S074039.
- [6] Singh S, Bittner V. Familial hypercholesterolemia: epidemiology, diagnosis, and screening. *Curr Atheroscler Rep* 2015;17:1–8.
- [7] Usifo E, Leigh SE, Whittall RA, et al. Low-density lipoprotein receptor gene familial hypercholesterolemia variant database: update and pathological assessment. *Ann Hum Genet* 2012;76:387–1387.
- [8] Santos PC, Pereira AC. Type of LDLR mutation and the pharmacogenetics of familial hypercholesterolemia treatment. *Pharmacogenomics* 2015;16:1743–50.
- [9] Gill PJ, Harnden A, Karpe F. Familial hypercholesterolaemia. *BMJ* 2012;344:e3228–13228.
- [10] Heusch G, Libby P, Gersh B, et al. Cardiovascular remodelling in coronary artery disease and heart failure. *Lancet* 2014;383:1933–43.
- [11] Gagnano F, Sperlongano S, Golia E, et al. The role of von Willebrand factor in vascular inflammation: from pathogenesis to targeted therapy. *Mediators Inflamm* 2017;1–7.
- [12] House SL, Castro AM, Lupu TS, et al. Endothelial fibroblast growth factor receptor signaling is required for vascular remodeling following cardiac ischemia-reperfusion injury. *Am J Physiol Heart Circ Physiol* 2016;310:H559–1559.