

BRIEF REPORT



OXFORD

Double Infection With *Leishmania tropica* and *L. major* in an HIV Patient Controlled With High Doses of Amphotericin B

Asma Al Balushi,¹ Faryal Khamis,¹ Corné H. W. Klaassen,² Jean-Pierre Gangneux,³ Jaap J. van Hellemond,² and Eskild Petersen¹

¹Department of Infectious Diseases, The Royal Hospital, Muscat, Sultanate of Oman; ²Department of Medical Microbiology and Infectious Diseases, Erasmus MC University Medical Center, Rotterdam, the Netherlands; ³Centre Hospitalier Universitaire Pontchaillou, Rennes, France

We present a unique case of disseminated Leishmaniasis in an HIV patient. Two different *Leishmania* species were identified by genomic sequencing in both bone marrow and skin. The *Leishmania* infection could be suppressed but not cured, despite a high dose of amphotericin B of nearly 65 g over more than 6 years.

Keywords. Leishmaniasis; HIV-coinfection; amphotericin B; CD4 cell count; relapse.

Leishmania–HIV coinfection is considered a major threat to the lives of HIV-infected patients [1]. It can present as a cutaneous, muco-cutaneous, or visceral Leishmaniasis depending on the species. Those who are severely immunocompromised with CD4 T-cell counts <200 cells/ μ L may present with atypical features. Managing such patients is a challenge [2]. We present a case of combined muco-cutaneous and visceral Leishmaniasis with 2 different *Leishmania* species requiring repeated high doses of amphotericin B for more than 6 years to be controlled but without cure.

CASE REPORT

Our case was a 40-year-old Omani male, an intravenous drug user with a history of extended travel in the Mediterranean region in 1989; he traveled to Oman and southern Yemen, where he stayed for 30 days, then crossed the Red Sea to the Suez Canal. From there, he had different stops in European countries including the United Kingdom, France, Italy, Portugal, Spain,

and Gibraltar; he stayed for at least 20 to 30 days in each country. In 1990, he visited Pakistan for 4 weeks.

He presented with oral candidiasis and cystic brain lesions in August 2010. He was found to be HIV-positive with cerebral toxoplasmosis. His initial HIV viral load was 300 000 copies/mL with a CD4 T-cell count of 6 cells/ μ L. He was started on efavirenz 600 mg, zidovudine 600 mg, and lamivudine 300 mg once daily and received pneumocystis carinii pneumonia (PCP) prophylaxis. He was coinfecting with hepatitis C virus, genotype 1B, for which interferon and ribavirin treatment was started. He failed therapy due to noncompliance, but later, in 2016, he responded well to ledipasvir/sofosbuvir treatment.

In 2012, he presented with 5 nodular skin lesions, each <1 cm, brownish to purple in color, involving the forehead, fingers, and left lower limb. A skin biopsy from the forehead showed macrophages in the dermis loaded by Leishman Donovan bodies, and cutaneous Leishmaniasis (CL) was diagnosed. The biopsy was negative for HHV-8, dysplasia, and malignancy.

He was managed initially with topical paromomycin, but a few months later, his condition progressed to disseminated muco-cutaneous (MCL) and visceral Leishmaniasis (VL) with new nodular lesions on the limbs, ears, and nose, with nasal bridge destruction, or “saddle nose.”

He had hepatosplenomegaly and an inguinal lymph node of 1.2 \times 1.0 cm confirmed on computed tomography. The patient had pancytopenia, with a hemoglobin level of 7.3 g/dL, thrombocytopenia of 30×10^9 /L, leukopenia of 1.3×10^9 WBC/L, and neutropenia of 0.3×10^9 /L.

A bone marrow aspirate and biopsy showed *Leishmania* parasites that were also seen in the inguinal lymph node and gastric biopsies.

Compliance was an issue. His antiretroviral therapy (ART) regimen was changed to emtricitabine 200 mg, tenofovir disoproxil fumarate (DF) 300 mg, and efavirenz 600 mg once daily. In 2015, his HIV viral load was suppressed, and his absolute CD4 count stabilized to between 30 and 80 cells/ μ L (Table 1).

The patient was managed initially with liposomal amphotericin B, 5 mg/kg for 14 days, and was placed on a maintenance dose of 5 mg/kg every 3 weeks for 3 to 5 days. During the first year, he showed a good response but then experienced frequent relapses. Compliance to the ART and to the Leishmaniasis treatment was an issue. Several regimens were used to control the relapses, including a combination of liposomal amphotericin and fluconazole to enable shortening treatment duration and prolonging the intervals; however, all were unsuccessful. With subsequent improvement in ART compliance, his viral load was persistently undetectable. However, the CD4 T-cell count remained below 80 cells/ μ L. In 2017, he was started on paromomycin orally 500 mg twice a day but did not tolerate

Received 4 July 2018; editorial decision 6 September 2018; accepted 4 December 2018; published online December 7, 2018.

Correspondence: Asma Al Balushi, MD, Department of Infectious Diseases, The Royal Hospital, P.O. Box 1331, 111 Muscat, Sultanate of Oman (thebrightsoul2@gmail.com)

Open Forum Infectious Diseases®

© The Author(s) 2018. Published by Oxford University Press on behalf of Infectious Diseases Society of America. This is an Open Access article distributed under the terms of the Creative Commons Attribution-NonCommercial-NoDerivs licence (<http://creativecommons.org/licenses/by-nc-nd/4.0/>), which permits non-commercial reproduction and distribution of the work, in any medium, provided the original work is not altered or transformed in any way, and that the work is properly cited. For commercial re-use, please contact journals.permissions@oup.com DOI: 10.1093/ofid/ofy323

Table 1. Doses of Liposomal Amphotericin B and Patient's Virological and Immunological Response

Year	2010	2011	2012	2013	2014	2015	2016	2017	2018
Highest CD4 T-cell count, cells/ μ L	6	169	108	305	288	76	67	49	
HIV viral load, copies/mL	316 018	30–109	0–1 367 727	88–3479	<20–545 285	0–568	<20	<20	
Total dose of liposomal amphotericin B, g	0	0	0	3.5	13.3	1.95	14.7	19.8	10.5

The table demonstrates the highest CD4 T-cell count for our patient per year, along with the range of the HIV viral load during that year. It also shows the total dose of liposomal amphotericin B the patient received each year.

it. Currently, he is on a high maintenance dose of liposomal amphotericin B 5–7.5 mg/kg for 5 days every 3 weeks. He is responding well except if he misses doses.

The latest bone marrow biopsy performed in 2016 showed sparse *Leishmania* parasites; 2 skin biopsies in 2016 and 2017 showed abundant *Leishmania* parasites (Figure 1).

Genomic Testing of *Leishmania* Species

One bone marrow and 2 skin biopsy specimens tested positive in the *Leishmania* genus-specific real-time polymerase chain reaction assay [3]. The *Leishmania* species was determined by amplification of the HSP70 (N-terminal fragment) and mini-exon loci and sequencing [4]. Sequence analysis demonstrated the presence of a mixture of DNA of *L. major* and *L. tropica* in the bone marrow specimen, which could be explained by either an infection by a hybrid species or by a simultaneous infection by 2 distinct *Leishmania* species. Subsequent analysis of 2 skin biopsy specimens demonstrated the presence of *L. tropica* only, which excludes the possibility that the patient was infected by a single hybrid species, as the skin biopsy specimens should have contained this hybrid species as well. Therefore, the patient was simultaneously infected by 2 *Leishmania* species: *L. major* and *L. tropica*.

DISCUSSION

Leishmaniasis is a protozoal infection transmitted by the bite of female *Phlebotomine* sand fly. Amastigotes replicate in the

macrophages of the host, causing muco-cutaneous or visceral Leishmaniasis depending on the *Leishmania* species [5].

Genomic sequencing of species isolated from the bone marrow and the skin of our patient showed 2 different species, *L. tropica* and *L. major*, and the patient probably had *Leishmania* infection before becoming infected with HIV. Although an infection with both these *Leishmania* species normally results in cutaneous Leishmaniasis, in severely immunocompromised patients, both *Leishmania* species can disseminate, which we believe happened in this patient. Dissemination of “cutaneous *Leishmania* species” has been previously described in immune-compromised patients, but to the best of our knowledge, this is the first case in which 2 cutaneous *Leishmania* species could be detected in bone marrow [3, 4].

Oman is a nonendemic area for Leishmaniasis with only sporadically reported cases in mainly the 1980s and 1990s. The main species involved were *L. tropica* and *L. infantum* [6].

L. tropica and *L. major* are reported to cause CL in Yemen, Pakistan, Egypt, and Morocco. In the 1990s, France, Italy, Portugal, and Spain reported the most cases of *Leishmania*–HIV coinfection in the Mediterranean region, predominantly *L. infantum*, but with introduction of ART in 1997, these reported cases decreased drastically [7].

Leishmaniasis reactivation can occur many years after initial infection in immune-compromised patients, which was seen in

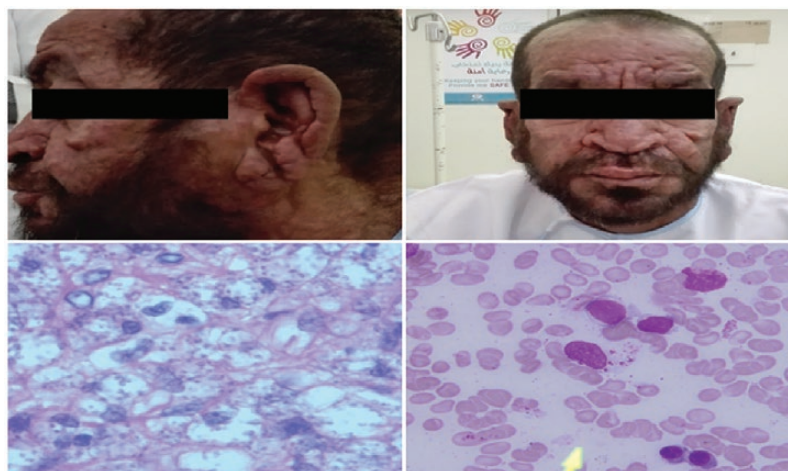


Figure 1. A and B, Cutaneous lesions with nodules and destruction of the nasal bridge. C, Skin biopsy with multiple *Leishmania* parasites (hematoxylin and eosin stain, magnification $\times 600$). D, Bone marrow aspirate with sparse *Leishmania* parasites (Giemsa stain, magnification $\times 600$).

our patient, who was probably infected 22 years before developing clinical Leishmaniasis [5, 7].

In severely immunocompromised HIV-infected individuals with CD4 T-cell counts <200 cells/uL, atypical presentations of cutaneous Leishmaniasis and visceralization are common [5, 7, 8]. Our patient had lymphadenopathy, hepatosplenomegaly, and gut and bone marrow involvement.

Serological tests for Leishmaniasis have low sensitivity in HIV patients and are therefore less reliable [5, 7, 8]. Finding amastigotes in bone marrow or spleen tissue is considered a highly sensitive method for the diagnosis of VL [8], and we did not perform serology.

Management of VL-HIV coinfection is challenging. In HIV patients, higher relapse rates and treatment failure occur more frequently, especially in severely immunocompromised individuals with CD4 T-cell counts <200 cells/uL [5, 7, 8].

The World Health Organization (WHO) has recommended liposomal amphotericin B with a total cumulative dose of 20–40 mg/kg (equal to 2 g in our patient) as the preferred agent to treat VL in HIV-coinfected patients [7–9]. Despite having good cure rates ranging from 42% to 85%, frequent relapses are seen in HIV-infected patients [9]. This patient responded to high-dose liposomal amphotericin B 5–7.5 mg/kg but needed frequent, repeated administration daily for 5 days every 3 weeks to maintain the status quo.

The patient received far more amphotericin B than recommended in the WHO guideline [9], with an estimated 15–20 g per year, and altogether he has received close to 65 g over the past 6 years. The latest Infectious Diseases Society of America (IDSA) guidelines recommend follow-up treatment in immunocompromised patients with relapse but do not state for how long or with which doses [10].

Combination therapies with pentamidine, paromomycin, fluconazole, or allopurinol are recommended in cases with multiple relapses. This approach can lead to better response and reduced relapse rates [7–9] but has higher toxicity profiles [9]; our patient tolerated amphotericin B well.

Several studies have demonstrated that miltefosine is a well-tolerated drug even in long-term use for treatment of VL-HIV coinfection, with better safety profiles [7–9, 11], but we do not have access to miltefosine. A combination of amphotericin B and miltefosine is a possibility in cases like this patient.

Response to treatment depends on the virulence of the causative *Leishmania* species [8, 11], and most of previous studies were carried out in Europe and Ethiopia involving *L. infantum* and *L. donovani*, respectively [8, 13]. More studies are needed to assess the efficacy of those drugs in patients infected with other *Leishmania* species. The IDSA guidelines recommend genotyping of the *Leishmania* species, and treatment efficacy may vary

depending on the *Leishmania* genotype; however, treatment recommendations do not consider different genotypes [10].

Despite starting ART and having good viral suppression, the patient failed to have good immunological recovery. Visceral Leishmaniasis hinders immunological recovery and increases HIV viral replication. This is attributed to sharing the same immunological mechanism involving dendritic cells, specific T-helper type I cells, and macrophages [5, 7, 8, 11]. Starting ART can reduce the incidence of VL-HIV coinfection and the rate of relapses, but relapses can still occur with an improved CD4 count and an undetectable HIV viral load [7, 11, 12, 14].

Our patient failed to maintain immunological recovery and is probably going to require lifelong treatment with amphotericin B if more efficient treatment of his *Leishmania* infection is not available.

Acknowledgments

We thank Florence Robert-Gangneux for help and assistance with the isolation of the nucleic acids from the biopsy specimens. We also thank Christophe Ravel from the French Reference Center of Leishmaniasis (University of Montpellier) for his help with the hypothesis of the hybrid.

Potential conflicts of interest. All authors: no reported conflicts of interest. All authors have submitted the ICMJE Form for Disclosure of Potential Conflicts of Interest. Conflicts that the editors consider relevant to the content of the manuscript have been disclosed.

References

- Pagliano P, Esposito S. Visceral leishmaniasis in immunocompromised host: an update and literature review. *J Chemother* **2017**; 29:261–6.
- Ponte-Sucré A, Gamarro F, Dujardin JC, et al. Drug resistance and treatment failure in leishmaniasis: a 21st century challenge. *PLoS Negl Trop Dis* **2017**; 11:e0006052.
- Wortmann G, Sweeney C, Houg HS, et al. Rapid diagnosis of leishmaniasis by fluorogenic polymerase chain reaction. *Am J Trop Med Hyg* **2001**; 65:583–7.
- Van der Auwera G, Ravel C, Verweij JJ, et al. Evaluation of four single-locus markers for *Leishmania* species discrimination by sequencing. *J Clin Microbiol* **2014**; 52:1098–104.
- Lindoso JA, Cunha MA, Queiroz IT, Moreira CH. Leishmaniasis-HIV coinfection: current challenges. *HIV AIDS (Auckl)* **2016**; 8:147–56.
- Alvar J, Vélez ID, Bern C, et al; WHO Leishmaniasis Control Team. Leishmaniasis worldwide and global estimates of its incidence. *PLoS One* **2012**; 7:e35671.
- Monge-Malio B, Norman FE, Cruz I, et al. Visceral Leishmaniasis and HIV coinfection in the Mediterranean region. *PLoS Negl Trop Dis* **2014**; 8:1–6.
- van Griensven J, Carrillo E, López-Vélez R, et al. Leishmaniasis in immunosuppressed individuals. *Clin Microbiol Infect* **2014**; 20:286–99.
- Monge-Malio B, Lopez-Vélez R. Treatment options for visceral leishmaniasis and HIV coinfection. *AIDS Rev* **2016**; 18:32–43.
- Aronson N, Herwaldt BL, Libman M, et al. Diagnosis and treatment of leishmaniasis: clinical practice guidelines by the Infectious Diseases Society of America (IDSA) and the American Society of Tropical Medicine and Hygiene (ASTMH). *Clin Infect Dis* **2016**; 63:1539–57.
- Alvar J, Aparicio P, Aseffa A, et al. The relationship between leishmaniasis and AIDS: the second 10 years. *Clin Microbiol Rev* **2008**; 21:334–59, table of contents.
- Cota GF, de Sousa MR, Rabello A. Predictors of visceral leishmaniasis relapse in HIV-infected patients: a systematic review. *PLoS Negl Trop Dis* **2011**; 5:e1153.
- Diro E, Ritmeijer K, Boelaert M, et al. Long-term clinical outcomes in visceral leishmaniasis/human immunodeficiency virus-coinfected patients during and after pentamidine secondary prophylaxis in ethiopia: a single-arm clinical trial. *Clin Infect Dis* **2017**; 66:444–51.
- Alemayehu M, Wubshet M, Mesfin N. Magnitude of visceral leishmaniasis and poor treatment outcome among HIV patients: meta-analysis and systematic review. *HIV AIDS (Auckl)* **2016**; 8:75–81.