

**THE USE OF HYDROXYAPATITE-COATED
COLLARS ENHANCES OSTEOINTEGRATED
EXTRA-CORTICAL BONE FORMATION AND
IMPROVES LONG TERM SURVIVAL OF DISTAL
FEMORAL ENDOPROSTHESES**

VINEET BATTA

SUBMITTED FOR THE DEGREE OF DOCTORATE IN
MEDICINE – MD (Res)

March 2018

CENTRE FOR BIOMEDICAL ENGINEERING
INSTITUTE OF ORTHOPAEDICS AND
MUSCULOSKELETAL SCIENCE
UCL
UNITED KINGDOM

Declaration

I, Vineet Batta, confirm that the work presented in this thesis is my own. Where information has been derived from other sources, I confirm that this has been indicated in the thesis.

Abstract

The fixation of massive segmental prostheses is more problematic than standard joint replacements. The aims of this study are: 1) To evaluate the long-term survival of cemented and uncemented distal femoral bone tumour endoprostheses in adults and skeletally immature patients. 2) To investigate the relationship between the degree of osteointegration onto the hydroxyapatite (HA) coated collar located at the bone-implant junction and relate this to aseptic loosening (ASL) of these endoprostheses. The hypothesis is that a hydroxyapatite collar at the shoulder of bone and implant junction enhances osteointegration and extra-cortical bone formation, reducing aseptic loosening of the endoprostheses.

Three separate studies to evaluate the long-term survival of distal femoral endoprosthetic replacements (DFR) implanted at our institute since 1992 were carried out. The first included 61 adult patients with cemented DFR, the second study involved 69 uncemented DFR in adults and the third comprised 24 cemented, non-invasive and expandable DFR in skeletally immature patients. For the first time, the degree of osteointegration at the bone-implant junction was evaluated and the amount of extra-cortical bone formation was evaluated. Finally the effect of osteointegration of the HA collar on the rate of aseptic loosening (ASL) and on implant survival was investigated.

Uncemented, custom made distal femoral endoprotheses have a higher rate of aseptic loosening compared to cemented fixation but this was associated with early loosening and implants that survived for greater than two years, were well fixed for the duration of follow-up. Initial fixation of uncemented DFR is crucial as most cases of loosening occur early.

The use of grooved HA coated collar located at the shoulder of distal femoral massive protheses resulted in increased formation and attachment of the extra-cortical bone and showed a reduced rate of revision due to aseptic loosening. However in cases where osteointegration could not be identified on radiographs, the loosening was higher than in those cases which were well osteointegrated. Survivorship at 10 and 15 years was 98% for those patients with well osteointegrated implants but only 75% for those without osteointegration.

In paediatric cases, the use of a HA collar reduces the progression of radiolucent lines and results indicate that implants with osteointegrated HA collars, inserted into adolescent patients remain more firmly attached to the skeleton than non-osteointegrated HA collars. This suggests that HA collars can enhance the survival of the prosthesis inserted when these patients achieve skeletally maturity.

These results suggest that HA collars are beneficial when they are osteointegrated as they allow load distribution onto the adjacent cortical bone in a more physiological

manner resulting in a reduced load on the intramedullary stem leading to a reduction of aseptic loosening.

Acknowledgement

I would like to express my sincere gratitude to my supervisors Dr. Melanie J Coathup and Prof. Gordon Blunn. I admire Dr. Coathup for her knowledge, keen observation, patience and enthusiasm. She was a constant source of inspiration during my research work and motivated me to overcome all the hurdles I encountered during the writing of my dissertation. I feel indebted to Prof. Blunn for his constructive criticism and valuable suggestions. His attention to detail and meticulous guidance have enabled me to complete this dissertation.

My heartfelt thanks go to Prof. Tim Briggs and Mr. Will Aston who provided me access to clinical notes and provided me guidance through this MD.

I would like to extend special thanks to the staff at the Biomedical Engineering Department who have all been so approachable and kind.

I wish to express my very profound gratitude to my parents Dr. Ashok Batta and Mrs. Indira Batta as well as my in laws Mr. Suresh Kumar Dewan and Mrs. Subhashni Dewan. Their unfailing support and continuous encouragement throughout my years of study and through the process of researching and writing this dissertation have been instrumental in completion of my dissertation.

I would also like to thank my sister-in-law Pooja Dewan, my sister Neha and brother-in-law Vikas Sareen, who have supported me throughout entire process. Vikas has time and again, answered my queries regarding data analysis.

This accomplishment would not have been possible without my wife Preeti and daughter Aarna. They excused me from all the home duties to give me time and energy to focus on my research. They were my pillars of strength especially in my trying times. I dedicate my dissertation to my loving wife Preeti.

Last but not the least, I sincerely express my gratitude to all the patients who consented to participate in this study.

Table of Contents

DECLARATION.....	2
ABSTRACT	3
ACKNOWLEDGMENTS.....	6
LIST OF FIGURES.....	11
LIST OF TABLES.....	13
LIST OF ABBREVIATIONS.....	14
CHAPTER 1: INTRODUCTION.....	15
1.1 Amputation versus Limb Salvage.....	16
1.2 Limb Salvage Surgeries.....	19
1.2.1 Allografts.....	19
1.2.2 Autografts.....	20
1.2.3 Rotationplasty.....	20
1.2.4 Endoprostheses.....	21
1.2.4.1 Modular Endoprostheses.....	23
1.2.4.2 Expandable Prosthesis.....	26
1.3 Failure of Endoprostheses.....	30
1.3.1 In Adults.....	30
1.3.1.1 Infection.....	31
1.3.1.2 Mechanical Failures.....	32
1.3.1.3 Aseptic Loosening.....	33
1.3.2 In Children.....	34
1.4 Implant Fixation - Extra-cortical Bone Bridging and Osteointegration.....	35
1.4.1 Porosity.....	42
1.4.2 Hydroxyapatite collars.....	47
1.4.2.1 HA Deposition Methods.....	50

1.4.3 Cemented versus Uncemented Fixation.....	52
1.5 Aims and Hypothesis.....	56
CHAPTER 2: HISTOLOGICAL AND RADIOGRAPHIC FOLLOW UP OF LONG-TERM SURVIVING CEMENTED DISTAL FEMORAL ENDOPROSTHESES WITH A HYDROXYAPATITE-COATED COLLAR.....	57
2.1 Introduction.....	58
2.2 Materials and Methods.....	59
2.2.1 Radiographic Analysis.....	63
2.2.2 Histological Analysis.....	64
2.2.3 Statistical Analysis.....	65
2.3 Results.....	66
2.3.1 Radiographic Analysis.....	69
2.3.2 Histological Analysis.....	70
2.4 Discussion.....	71
CHAPTER 3: UNCEMENTED, CUSTOM-MADE, HYDROXYAPATITE-COATED COLLARED DISTAL FEMORAL ENDOPROSTHESES.....	77
3.1 Introduction.....	78
3.2 Patients and Methods.....	79
3.2.1 Statistical Analysis.....	82
3.3 Results.....	83
3.4 Discussion.....	91
CHAPTER 4: ENHANCED FIXATION OF DISTAL FEMORAL REPLACEMENTS WITH HYDROXYAPATITE-COATED COLLARS IN SKELETALLY IMMATURE PATIENTS.....	96
4.1 Introduction.....	97
4.2 Patients and Methods.....	98
4.2.1 Radiographic Analysis.....	100
4.2.1.1 Osteointegration Score.....	101

4.2.1.2 Radiolucent Line Score.....	102
4.2.1.3 Cortical Bone Loss at the Bone-shoulder Implant Junction...	103
4.2.2 Statistical Analysis.....	104
4.3 Results.....	105
4.3.1 Radiolucent Line Score.....	105
4.3.2 Bone Loss at Transection Site.....	106
4.4 Discussion.....	108
CHAPTER 5: DISCUSSION.....	114
5.1 Current Concepts in Distal Femoral Replacements.....	126
5.2 Non invasive techniques of assessing implant stability.....	129
5.2 Scope for Future Studies.....	130
CHAPTER 6: APPENDIX.....	132
6.1 NHS R & D Response to Enquiry.....	133
6.2 NHS R & D Management Confirmation of Notification of Service Evaluation.....	134
6.3 Presentations at Conferences.....	135
CHAPTER 7: BIBLIOGRAPHY.....	136

List of Figures

Figure 1.1 A: A non-invasive growing implant that ‘grows’ the bone shortly after initial osteotomy.....	30
Figure 1.1 B: After growth has stopped 3 cm of new bone can be seen.....	30
Figure 1.2: Schematic diagram indicating area of extra-cortical bone-bridging overlying bone prosthetic junction.....	42
Figure 1.3: Major innovations in implant design since the inception of endoprosthetic replacements.....	55
Figure 2.1: A distal femoral massive prosthesis with a HA grooved ingrowth collar located at the implant-bone junction.....	62
Figure 2.2: An anteroposterior radiograph of distal femoral prostheses	65
Figure 2.3: Kaplan-Meier survival analysis of the distal femoral prostheses with respect to implant revision due to implant failure for any cause.....	67
Figure 2.4: Kaplan-Meier survival analysis, with respect to aseptic loosening, of the distal femoral prostheses with ingrowth into the hydroxyapatite (HA)-coated collar compared with those with no radiographic signs of ingrowth into the collar.....	71
Figure 2.5-A: A photomicrograph of a transverse section through a hydroxyapatite-coated ingrowth collar showing mature lamellar bone in direct contact with the implant surface.....	72
Figure 2.5-B: A magnified image of a single groove within the collar.....	72
Figure 3.1: Drawing of an uncemented distal femoral endoprosthetic replacement (HA, hydroxyapatite).....	80
Figure 3.2: Kaplan–Meier estimates of overall survivorship showing survival rates at 5, 10 and 15 years.....	83

Figure 3.3: Kaplan–Meier survival analysis with failure defined as aseptic loosening, showing survival rates at 5, 10 and 15 years.....	85
Figure 3.4: Receiver operating characteristic curve showing good predictability of aseptic loosening by resection length (%).....	88
Figure 3.5: Receiver operating characteristic curve showing good predictability of aseptic loosening by total prosthesis length/stem length ratio.....	89
Figure 3.6: Radiograph of a broken femoral component in a female patient aged 17 years without signs of aseptic loosening 169 months after surgery.....	89
Figure 3.7: Radiograph showing cortical remodelling of a well-fitted distal femoral replacement 24 months post-operatively in a 24-year-old male.....	90
Figure 4.1 Schematic Diagram of the radiolucent lines zones on AP and Lateral views.....	103
Figure 4.2 Cortical bone loss measured adjacent to the bone-implant junction.....	103
Figure 4.3: Radiolucent Line Score for the osteointegrated and non-osteointegrated Groups.....	106
Figure 4.4: Bone Loss at the transection site in the osteointegrated and non-osteointegrated groups.....	107
Fig 5.1 A- Proximal femoral implant.....	128
Fig 5.1 B- Implant porous shoulder.....	128
Fig 5.1 C- Porous Collar.....	128

List of Tables

Table 2.1: Patient diagnosis at the time of surgery	61
Table 2.2: Death, implant failure, and complications in patients cumulated throughout the two to eighteen-year follow-up period	69
Table 3.1: Diagnoses of the 69 patients treated with a uncemented distal femoral endoprosthetic replacement	80
Table 3.2: Mode of failure using the classification of Henderson et al., 2011	85
Table 3.3: Statistical analysis of factors that may have led to aseptic loosening.....	87
Table 4.1: Reasons for the 7 revision surgeries < 3 years post-op.....	99
Table 4.2: Correlation of Extra-cortical Bone Formation and Radiolucent Line Score.....	108

List of Abbreviations

ECB.....	Extra cortical bone
HA.....	Hydroxyapatite
DFP.....	Distal femoral prostheses
ASL.....	Aseptic loosening
DFR.....	Distal femoral endoprosthesis replacement
TLP.....	Total length of prostheses
SL.....	Stem length
CI.....	Confidence Intervals
OR.....	Odds Ratio
ROC.....	Receiver operating characteristic
OI.....	Osteointegration
RLL.....	Radiolucent Line

Chapter 1

Introduction

1.1 Amputation versus Limb Salvage

Bone sarcomas are an uncommon and diverse group of tumours which represent less than 1% of all adult and 15% of paediatric malignancies. Due to the advent of a multidisciplinary treatment approach, survival and quality of life of patients with a bone sarcoma has considerably improved([Gikas et al.](#)). Primary malignant and aggressive tumours like classic high grade osteosarcoma and giant cell bone tumours are often found at the distal femur([Rubio et al., 2013](#)).

In children, bone sarcomas are very different as compared to other cancers since they often require significant surgical interventions due to leg length discrepancies that can occur as the child ages and thus can considerably impact their function, mobility and body image, making patients and families face difficult decisions between limb-sparing procedures and amputation([Stokke et al., 2015](#)). Also, sarcomas weaken the bone, and have to be removed because they are highly metastatic and would lead to large numbers of secondary tumours.

The aims of the bone tumour surgeon are to improve survival and maintain optimal function of the patient which can be achieved by amputation or limb salvage([Gikas et al.](#)). Amputation would leave the patients with a lifelong requirement for an external prosthetic leg associated with an overall limited walking distance and while artificial limbs are much more sophisticated than those used in the past, phantom limb

sensations remain a substantial and unpredictable problem in the amputee. Also, complications with the stump socket interface such as stump overgrowth, bleeding, and infection, require further attention([Ottaviani et al., 2009](#)).

Over the past 30 years, limb salvage has replaced amputation as the preferred choice of surgical treatment because of improvements in diagnostic imaging techniques, current techniques of surgical reconstruction and the use of different chemotherapy regimes which allow for adequate surgical resection of the tumours with wide margins while preserving body integrity([Dominkus et al., 2001](#)).

Simon et al compared the results of limb-sparing surgery with those of amputation in patients with osteosarcoma and concluded that limb salvage does not compromise long-term survival although it may lead to an increased risk of local recurrence. Limb salvage has also been shown to be more cost-effective than amputation([Myers et al., 2007b](#), [Simon et al., 1986](#)).

The principles that govern surgical resection of bone and soft tissue tumours have remained unchanged despite an increase in the number of limb salvage surgeries undertaken for malignant tumours of the extremity. Limb salvage is recommended only if the ability to achieve adequate margins is not compromised and if the salvaged limb will provide function superior to that obtainable by a prosthetic limb after an amputation. An insensate salvaged limb with inadequate motor function defeats the

very purpose of limb salvage, which compared to amputations, aims at improving the patient's quality of life([Puri, 2014](#)).

The objectives of extremity reconstruction after oncologic resection include providing skeletal stability where necessary, optimising the aesthetic outcome, adequate wound coverage to allow early subsequent adjuvant therapy and preservation of functional ability with early return to function([Puri, 2015](#)).

Limb-salvage surgery in skeletally immature children is however a challenging problem for orthopaedic surgeons because of the need to minimize postsurgical complications, create a functional and durable reconstruction, and address the problem of potential limb length discrepancy([Staals et al., 2015](#)). Futani et al have reported a cumulative ten year survival rate of 82% in children after limb-salvage surgery of the femur([Futani et al., 2006](#)) which is similar to that reported by Schinhan et al([Schinhan et al., 2015](#)).

Starting in the early 1970s, with the development of antineoplastic drugs, orthopaedic physicians began to use chemotherapy for primary musculoskeletal tumours. The use of chemotherapy in orthopaedic oncology began as adjuvant therapy following removal of the primary tumour with promising results. This followed the hypothesis that chemotherapy would destroy any microscopic residual disease missed during surgery([Hwang et al., 2014](#)). Numerous studies have shown increased survival rates

in patients who received adjuvant chemotherapy following bone resection([Rosen et al., 1981](#), [Bleyer et al., 1982](#)). Physicians thus began to use chemotherapy in combination with custom-made endoprostheses in hopes of increasing survival while also salvaging the limb([Marcove, 1977](#)). Neoadjuvant chemotherapy is now standard, and allows for assessment of tumour responsiveness to chemotherapy while commonly shrinking the tumour, thus aiding surgical resection([Grimer, 2005](#)).

A successful limb salvage approach therefore depends upon understanding of tumour biology and assessment of tumour aggressiveness, advances in reconstructive techniques and the development of effective chemotherapy protocols for primary and secondary bone tumours([Barjaktarović et al., 2011](#)). Reconstruction after excision of the tumour can be achieved by using endoprosthetic replacements, rotationplasty, autografts, or massive allografts([Gikas et al.](#)).

1.2 Limb Salvage Surgery

1.2.1 Allograft

Allografts have been shown useful in the reconstruction of bone defects after tumour resection([Han et al., 2015](#)) since they can have a similar shape, strength, osteoconductive and osteoinductive properties as the host bone([Niu et al., 2007](#)). Although allograft reconstruction of the distal femur can provide long term survival and restore function, the risk of complications and their physical and monetary costs are a

significant cause of the reduced use of this treatment option([Toy et al., 2010](#)). Complications include non-union, fracture and infection which can manifest as early as the first year after surgery because the graft does not really incorporate and remains a dead piece of bone ([Bus et al., 2014](#)).

1.2.2 Autograft

Vascular fibular grafts are popular types of autograft that have also proven to be successful in a few cases after tumour resection of distal femoral tumours([Yu et al., 2014](#)) and can achieve satisfactory oncological and functional outcomes([Xu et al., 2013](#)). In spite of these favourable outcomes, the complication and recurrence rates are high and thus this method of treatment should be used with caution and patient selection must be done with strict surgical indication([Yang et al., 2015](#)).

1.2.3 Rotationplasty

Rotationplasty is the removal of a diseased portion of bone, turning the shortened leg bone through 180°, and reattachment of the limb is a completely different approach halfway between amputation and limb salvage. In 1950, van Nes and others used rotationplasty for children with proximal focal femoral deficiency which inspired this method of limb salvage surgery. In orthopaedic oncology, this technique has been modified to allow resection of a tumour around the knee by attachment of the healthy lower leg and foot to the upper thigh after rotation through 180° and preservation of

the sciatic nerve. The ankle thus acts as a knee joint and the patient is fitted with an artificial limb that functions like a below-knee amputation prosthesis([Kotz and Salzer, 1982](#)).

The advantages of this reconstruction are improved function, a fairly low risk of complications, and absence of phantom pain which is common after amputations. In young children the limb will continue to grow, thus avoiding the need for further surgery([Grimer, 2005](#)).

Rotationplasty, however, is not acceptable to some people since it has a substantial effect on their body image. The cosmetic appearance of the rotated foot can lead to psychological problems in some patients, but such issues are rare in those treated at centres that do many rotationplasties and in whom peer support and excellent functional outcome are enough to outweigh the perceived cosmetic problem([Grimer, 2005](#)).

1.2.4 Endoprostheses

Limb-sparing surgery using a massive endoprostheses has been accepted as the gold standard for treatment of most malignant bone tumours of the distal part of the femur ([Jeys et al., 2008](#), [Myers et al., 2007b](#), [Kawai et al., 1999](#)). In the last 30 years, the five- year survival rate, for patients who had endoprosthetic reconstruction for distal femoral bone tumours, has increased from 20% to 85%, with the majority of patients

maintaining good levels of knee function ([Jeys et al., 2008](#)). However, current evidence suggests that patients with low-grade disease and long-term survivors of high-grade localised disease should expect at least one or more revision procedures in their lifetime since the immense stress placed on the implant of young, active children and adults causes bone resorption leading to loosening([Schwartz et al., 2010b](#)).

Reliability, availability, a proven favourable cost-effectiveness ratio and enabling the patient to return to daily activities with full weight bearing are the numerous advantages that an endoprosthesis offers([Barjaktarović et al., 2011](#)). Although there was a growing interest in the use of endoprosthetic implants for limb salvaging, endoprosthesis were initially reserved as a palliative treatment for individuals who refused amputation([Hwang et al., 2014](#)) but is now the most common limb salvage procedure used.

During the early 1900s, multiple unsuccessful attempts were made to incorporate the use of metal implants in the body. The inability to find a suitable metal that could withstand corrosion from bodily fluids without causing an unfavourable reaction in soft tissues was the major reason for these failures([Hwang et al., 2014](#)). In 1943, Vitallium, an alloy of cobalt chrome, was used as the first metallic endoprosthesis in orthopaedic oncology and possibly, in the entire field of orthopaedics. Titanium and cobalt-chrome-molybdenum alloys were then used as were various acrylic polymers, which failed prematurely and were thus abandoned([Gkavardina and Tsagozis, 2014](#)).

1.2.4.1 Modular Endoprostheses

Prior to the development of modular systems, physicians were unable to provide an optimal-fitting prosthesis during surgery. In 1932, a cobalt–chromium alloy called Vitallium specifically for use in dental implants was created by Austenal Laboratories, which could withstand the corrosive effects of saliva. On further investigation, Venable et al discovered that this metal was inert to bodily fluids and soft tissue. Following these studies, Vitallium began to be used in the orthopaedic field as the preferred metal for creating plates and screws for internal fixation methods([Venable et al., 1937](#), [Venable and Stuck, 1941](#), [Venable and Stuck, 1943](#), [Venable and Stuck, 1948](#)).

These modular prostheses provided reconstruction of different leg lengths and joint lines, allowed adaption of tension in the knee extensor mechanism and immediate stability and weight bearing could be achieved([Windhager et al., 2016](#)). Modular systems provided patient-specific endoprostheses that could be modified during surgery without the cost and delay of a custom prosthesis, which allowed surgeons to use components of the best size and length for the individual. The components were then joined together in the operating room to create a unique and well-fitting endoprostheses([Hwang et al., 2014](#)).

Various types of prostheses have been developed and applied for the reconstruction of bone defects after tumour resection([Matsumine et al., 2011](#)). Examples are the

KMFTR™/HMRS™ (Kotz Modular Femur-Tibia Reconstruction System/Howmedica Modular Reconstruction System), HSS (Hospital for Special Surgery) modular-linked system™/FINN™ prosthesis, STANMORE™ prosthesis, GUEPAR™ prosthesis and newer developments like Orthogenesis LPS™ (Limb Preserving System), OSS™ (Oncology Salvage System) and MOST Options™([Heisel et al., 2006b](#)).

The current generic models of the prostheses used include a modular segment, a wrought stem, a circumferential porous coating around the prosthesis at the bone-prosthesis junction to encourage extra-cortical bone formation, and a loophole for soft tissue attachment([Matsumine et al., 2011](#)). The implants usually involve replacement of a joint and these components are similar to off-the-shelf implants. However due to resection of soft tissue, joints particularly around the knee and the shoulder are usually more constrained than those used for primary joint replacements. Specifically in cases where the knee joint is replaced, implant design has evolved from the monoblock and fixed hinge models to modular endoprostheses and rotating platforms, with improved geometry to enhance fixation and stability([Gkavardina and Tsagozis, 2014](#)).

In general, the requisites for a successful implant design are resistance to corrosion, high biocompatibility and resistance to fatigue fracture as well as potential for osteointegration and soft tissue ingrowth. Metallurgy and synthetic material industries are providing a variety of coatings (hydroxyapatite, porous tantalum, elemental silver)

and soft tissue attachment materials (polyester, polypropylene, carbon fiber, expanded polytetrafluoroethylene) to enhance osteointegration, reduce the incidence of infection and enable the attachment of soft tissues to implants([Gkavardina and Tsagozis, 2014](#)).

For limb salvage in cases of diaphyseal tumours, extraarticular (instead of intraarticular) resection of the entire knee en bloc should be done, which although favoured by patients, represents a challenging reconstructive problem because of the significant bony defects resulting from the en bloc excision of the tumour([Zwolak et al., 2011](#), [Hanna et al., 2010](#)). Extra-articular resections (EAR) have been reported to be associated with a higher complication rate and worse functional results, making management of sarcomas involving the knee joint a great challenge to oncology surgeons([Shahid et al., 2017](#)).

1.2.4.2 Expandable Prosthesis

The expandable prosthesis compensates for discrepancies in leg length which occur in skeletally immature patients with a fixed length implant([Gupta et al., 2006a](#)).

Children who undergo limb-sparing surgery for malignant bone tumours of the lower limbs will face various problems postoperatively as they grow([Yoshida et al., 2010](#)).

These prostheses, which are extended at operation, are good functionally and

psychologically, although every open procedure is accompanied by the risk of nerve damage, infection, and ankylosis, and in some cases amputation([Gupta et al., 2006a](#)).

Scales and Sneath first described the use of an expandable prostheses in the growing patient with a bone sarcoma([Goulding et al., 2014](#)). Developed at the Division of Biomedical Engineering in Stanmore, England, the extendible endoprosthesis managed to reconstruct the post-tumour resection defect and also address the problem of limb length discrepancy after physis excision([Groundland and Binitie, 2016](#)).

The prosthesis allowed a telescoping cylinder to increase the length of the implant when a screw was turned within the worm gear mechanism. This is done surgically by making a small incision where a screw driver is used to turn a key in the implant that drives the worm gear turning a screw that extends the implant, driving a tube to telescope out. This has to be done repeatedly as the child matures to keep pace with the growth of the normal side. Using this device, leg length discrepancy between the two limbs can be sustained in these children([Agarwal and Nayak, 2012](#), [Parry and Grimer, 2015](#)).

Most surgeons agree that an estimated leg-length discrepancy greater than 3 cm at maturity is the main indication for the use of an expandable endoprosthesis. For patients whose leg-length discrepancy is projected to be less than 3 cm, a normal

“adult-type” prosthesis that is either made longer at the time of tumour resection or accommodated with shoe modifications can be used. As a general rule, boys above 13 years or girls above 11 years do not require an expandable prosthesis because the remaining growth of the limb results in less than a 3-cm difference([Decilveo et al., 2017](#), [Abudu et al., 2006](#)).

The disadvantages of these expandable devices, however, are the possibility for failure of the prosthesis at maximal lengthening and failure of the expansion mechanism([Nystrom and Morcuende, 2010](#)). Also, the child has to undergo multiple surgical procedures for lengthening which means frequent admissions to hospital, anaesthesia and surgery, increasing the costs of treatment. Moreover, to minimise the number of operations required, more lengthening is done at each operation resulting in some pain, stiffness, and increased time to rehabilitate since the body does not adjust easily to the growth. Each surgery also increases the risk of infection which is estimated to be about 8% in the current literature([Abudu et al., 2006](#)).

These problems were addressed with the use of a non-invasive prosthesis. Minimally invasive growing prostheses can be used in patients where examination of local recurrence is expected to require MRI, where the device is accessed through a small incision and lengthened by a distraction screw([Parry and Grimer, 2015](#)). The original minimally invasive expandable prosthesis, Lewis Expandable Adjustable Prosthesis (LEAP), required additional surgeries for lengthening with a screwdriver. Although this

endoprosthesis is less expensive than the non-invasive prosthesis, it requires repeated open surgical procedures, which can result in infection([Decilveo et al., 2017](#), [Beebe et al., 2009](#)). In recent years, several companies, including Stryker and Biomet, have designed a modular minimally invasive expandable prosthesis with a durable lengthening mechanism to reduce complications such as hardware failure, yet these prostheses still require a surgical lengthening procedure, potentially leading to infection([Decilveo et al., 2017](#)).

The Phenix prosthesis (Phenix Medical, Paris, France), introduced in the 1990s, was the first design capable of non-invasive expansion. The lengthening in this prosthesis depends on the controlled melting of a polyethylene tube with a spring, using an external electromagnetic field. As the polyethylene tube melts, it allows controlled release of the spring's energy so that the prosthesis can extend. In practice, 6 mm to 15mm of lengthening is achievable at each expansion, depending on the patient, the state of soft tissues, the residual force of the spring and the location of the prosthesis([Gupta et al., 2006a](#)).

The non-invasive prosthesis made by Stanmore Implants Worldwide, U.K encompasses a magnetic motor activated by an external rotating magnetic field generated using copper coils applied in close proximity to the limb. The prosthesis has a very sophisticated mechanism sealed inside it which allows lengthening to happen with the help of an electromagnetic field. A rare earth magnet is placed along

with a gear system and a motor inside the prosthesis, whereby a coil from outside around the implant can generate an electromagnetic field to turn the motor. Through a system of miniature gears, the movement of the motor can allow the expansion of the implant by expanding a telescoping tube similar to the one described for the minimally invasive devices. This system overcomes the need for repeated surgical procedures for lengthening and hence the patient experiences no pain or stiffness, no requirement of multiple hospitalisations, and eliminates the risk of infection. This device therefore turns out to be cheaper than the minimally invasive implant in the long run. However, due to the irreparable damage that the magnetic motor sustains, patients with these devices cannot undergo additional MRI scanning([Agarwal and Nayak, 2012](#), [Parry and Grimer, 2015](#), [Grimer, 2005](#), [Picardo et al., 2012](#)). The other disadvantages of the non-invasive extendible prosthesis are that they require longer bone resection to achieve the same length of extension compared with minimally invasive prostheses and it cannot be used uncemented since forceful impaction of the prosthesis damages the magnetic lengthening device([Abudu et al., 2006](#)).

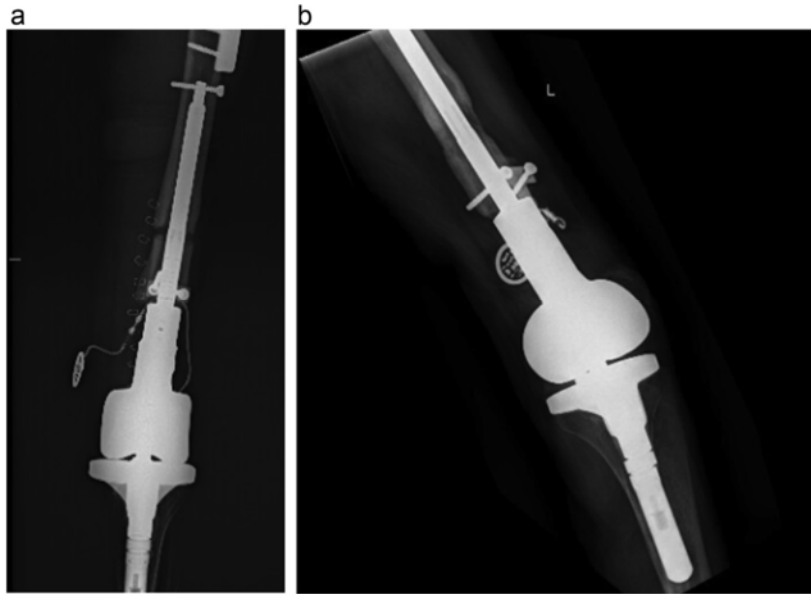


Fig 1.1 (a) A non-invasive growing implant that ‘grows’ the bone shortly after initial osteotomy (b) After growth has stopped 3 cm of new bone can be seen.

1.3 Failure of Endoprostheses

1.3.1 In Adults

Longevity of the reconstruction is therefore a major concern, especially in young and active patients who place high demands on their prostheses ([Farfalli et al., 2009](#)).

Causes of endoprosthetic failure have been classified according to Henderson et al. as soft tissue failure (Type 1), aseptic loosening (Type 2), structural fracture (Type 3), infection (Type 4), and local tumour recurrence (Type 5)([Henderson et al., 2011a](#)).

Poorer long-term results of the endoprostheses may be the result of many factors such as immunosuppression of patients with oncologic diagnoses, extensive resection of the bone and soft tissues, longer operative time and general patient condition([Pala et al., 2015](#)).

1.3.1.1 Infection

In the current literature, infection has been reported to be the most common mode of failure, ranging between 5% and 40% for endoprostheses, and has a significant effect on the ultimate patient outcome([Ahlmann et al., 2006a](#)). Immunosuppression caused by chemotherapy in those patients who receive drugs, the size of wound and length of time of the surgery have been known to increase the risk of infection in patients treated with endoprostheses([Pala et al., 2015](#)). Numerous studies have established several common features of deep infection of tumour endoprostheses which include the need for a considerably longer period of follow-up and infection monitoring for these patients, the dominant incidence of staphylococci as the infecting organism, the difficulty of conservative therapy for deep infection and the need for two or more surgical interventions in order to control the infection([Morii et al., 2013](#), [Hardes et al., 2006](#), [Jeys et al., 2005](#)). It is reported that early infections may be associated with discharge or pus at presentation, whereas late infections may be associated with prosthetic loosening([Hardes et al., 2006](#)).

1.3.1.2 Mechanical Failures

Mechanical failures account for about 50% of all failures associated with endoprostheses([Henderson et al., 2011a](#)). During treatment and under loading conditions, stresses are transmitted along a mechanical pathway from bone to bone,

through the endoprostheses. Mechanical failure may then occur through the implant itself, at the implant (or cement) bone interface or through the bone([Barut et al., 2015](#)).

The higher risk of fracture in tumour patients, even after minor trauma, is also the result of several biomechanical factors, including stress shielding, poor bone quality, fibrosis, thinning of the cortical bone, and subsequent bone reabsorption at the interface between the bone or cement and the prosthetic stem. The risk of fracture is also related to the absence of osteointegration at the bone–implant interface, to bone devascularization after reaming and cement heating, to the lack of hypertrophy of the loaded bone and to the increase of stress bypass of the host bone around a stiff intramedullary stem([Piccioli et al., 2015](#)). Patients operated on for musculoskeletal tumours often have factors that could lead to bone weakness such as underuse of the limb due to the main muscular and soft tissue resections. This has an impact on its functional impairment, bone loss resulting from chemotherapy or radiotherapy and muscular weakness which may all eventually lead to an increased risk of falls, ending in fracture([Davis et al., 1999](#)).

1.3.1.3 Aseptic Loosening

Aseptic loosening in endoprostheses is reported in the literature with a rate ranging from 2.4% to 15.4% for cemented stems and from 0% to 8% for cementless implants.

The authors of a retrospective study of Stanmore custom-made distal femoral endoprotheses reported aseptic loosening (ASL) as the principal mid-term mode of failure, with a 67.4% probability of a patient avoiding aseptic loosening for ten years ([Unwin et al., 1996b](#)). Young patients in whom a high percentage of the femur has been replaced had the poorest prognosis for implant survival. Other studies have also shown aseptic loosening to be the major complication, with rates of loosening of distal femoral prostheses reported to be between 2.9% and 28.6% at four to ten years ([Jeys et al., 2008](#), [Kawai et al., 1999](#), [Myers et al., 2007b](#), [Unwin et al., 1996b](#), [Gosheger et al., 2006](#), [Griffin et al., 2005](#), [Mittermayer et al., 2001](#), [Guo et al., 2008](#), [Torbert et al., 2005](#)). The factors causing aseptic loosening include poor cement fixation([Unwin et al., 1996b](#)), increased torque transmitted to the interface due to the use of constrained hinges ([Griffin et al., 2005](#)), longer resection length (more than 40 % femur) ([Mittermayer et al., 2001](#)), more intense physical activity in younger patients and poor shock attenuation by the prosthesis ([Flint et al., 2006](#), [Tanzer et al., 2005](#)).

A primary cause of aseptic loosening is implant micromotion due to gaps at the prosthesis-tissue interface. As orthopaedic prostheses are load-bearing implants, small amounts of micromotion may cause material deterioration over time with use, leading to further and greater micromotion and eventually causing implant failure. Gaps at the bone-implant interface can also lead to accumulation of implant debris, such as polymeric or metallic wear particles which can serve as a passage for wear

particles to flow along the length of the implant, building up at the interface, and preventing direct prosthesis-bone contact. These gaps can be prevented by increasing bone-implant contact, which will reduce the size and number of gaps surrounding the implant, stabilize the joint replacement prosthesis and reduce micromotion([Raphel et al., 2016](#)). Early aseptic loosening may result from poor bone growth or from the formation of a fibrous bone-implant junction in patients undergoing adjuvant chemotherapy for malignant bone tumour([Tang et al., 2016](#)).

1.3.2 In Children

Prosthetic failures in children are higher compared to adults however, infection rates have reduced to 8% with the minimally invasive expansion mechanism([Agarwal, 2007](#)) whereas loosening has increased by 50%([Decilveo et al., 2017](#)). Studies investigating the Stanmore noninvasive extendible prosthesis have reported major complications including infection (0%-18%), amputation (0%- 20%), and revision surgery (0%-18%)([Decilveo et al., 2017](#)). Problems associated with limb length discrepancy may occur, as well as complications commonly seen with orthopaedic implants such as infection, aseptic loosening, wear, breaks, and joint degeneration. In children, due to their high levels of physical activity and high biomechanical demand, the shelf life of the prosthesis is considerably reduced. In addition growth of the bone in children in particular the expansion of the endosteal cavity, may lead to the intramedullary stems becoming loose([Mendonça et al., 2008](#)).

1.4 Implant Fixation - Extra-cortical Bone Bridging and Osteointegration

Whichever endoprosthesis device is chosen, consideration should be given to the method of fixation of implant to bone. The technology of joint replacement has significantly improved and most are now based on more sophisticated prostheses with various methods of fixation([Myers et al., 2007a](#)).

Implant fixation is extremely important for pain-free function. Primary fixation is achieved during implantation and therefore the fixation is more mechanical, whereas secondary fixation is a result of repair and bone remodelling during the healing process making it a biological bonding process([Bosshardt et al., 2017](#), [Willert and Buchhorn, 1999](#)). Stress distribution caused by load transmission between bone and implant is the key problem of implant fixation. The closer the load transfer is to the original physiological situation, the easier the adaptation of the periprosthetic bone to the new biomechanical conditions after implantation and the safer is its long lasting fixation([Morscher et al., 2002](#)).

The concept of extra-cortical bone bridging, which is obtaining bone ingrowth at the junction of the body of the implant and the host bone, came from the observation that heterotrophic bone formation often occurs at this site after large bony resections. This concept has been explored with attempts to replace large segmental diaphyseal defects with porous-coated surface implants([Chao et al., 2004b](#)). Ideally, the bone

production should be driven and enhanced towards the implant surface such that this new bone binds the recipient implant to improve its stability([Saran et al., 2011](#)). The term 'bone ingrowth' refers in the literature mainly to bone formation within a porous surface structure of an implant, i.e ingrowth of any bone formation into the irregular depths of non-smooth surfaces([Kienapfel et al., 1999](#)).

Other benefits of extra-cortical bone bridging and ingrowth include the probable sealing effect of the fibro-osseous sleeve that theoretically prevents wear debris and joint fluid from entering the medullary canal, thereby, decreasing the risk of osteolysis at the bone-cement-implant interfaces([Saran et al., 2011](#)). There is also evidence that too much relative motion between the implant and host bone leads to ingrowth of fibrous connective tissue rather than bone and that the initial implant stability is important as it reduces relative motion between the implant and host bone([Kienapfel et al., 1999](#)). Therefore, the amount of bone ingrowth also depends on an optimal primary stability. From a clinical perspective, this primary stability can differ depending on; implantation technology variables such as accuracy of tools for rasping, reaming, drilling and sawing; implant design variables such as cross-sectional geometry, means of additional fixation and mismatch in implant and bone stiffness; surgical technique variables including the precision in the use of implantation technology; and patient variables that relate to bone quality and bone defects([Kienapfel et al., 1999](#)).

Studies in the early 1960s showed that the titanium chambers of the implant were inseparably incorporated within the bone tissue, which actually grew into very thin spaces in titanium, suggesting the possibility of osteointegration([Jayesh and Dhinakarsamy, 2015](#)).

Osteointegration as a concept for achieving long standing fixation of metal implants to bone without any interposing connective tissue was first described and documented by Brånemark et al([Brånemark, 1977](#)) and has been used for implant fixation in orthopaedic surgery, dentistry, plastic surgery, and otology([Möller et al., 2004](#)). In the late 1960s, Professor Andre Schroeder, started to examine the tissue integration of various implant materials, and his group was the first to document direct bone-to-implant contact for titanium implants in nondecalcified histologic sections([Schroeder et al., 1976](#)). Brånemark coined the term osteointegration which has been defined as “a direct structural and functional connection between ordered, living bone and the surface of a load-carrying implant, and this is considered a prerequisite for implant loading and long-term clinical success of all implants”([Bra-nemark et al., 1986](#)).

Implant osteointegration relies on two distinct requirements. The first is obtaining initial implant stability during surgery, which lays the groundwork for subsequent osteointegration of the implant as the patient heals and is thus mainly the responsibility of the surgeon and the surgical team. Even technological solutions to improve initial implant fit, including automated imaging and robotic arm assistance platforms only

manage to assist, rather than replace, the surgery team. The second requirement is the prevention of later-stage loosening of the implant. Loosening can be caused by a variety of factors which include; implant micromotion relative to the bone, lack of bone in-growth during healing, formation of implant wear particles, and adverse bone remodelling around the implant([Raphel et al., 2016](#)).

Successful implant osteointegration and its clinical longevity also depends on the way mechanical stresses are transferred to the surrounding bone or tissue. This transfer of force from the implant to the surrounding bone is influenced by the bone-implant interface (i.e., direct contact or a gap interface), the type of loading that occurs (i.e., intermittent, continuous), the implant shape, the length and diameter of the implant, the quality and quantity of the surrounding bone, and the surface texture of the implant. Thus, multiple factors influence successful osteointegration, including the need for limited early loading, resulting in minimal relative movement at the implant–bone interface and by understanding the most significant variables, implant stabilization can be optimized([Pilliar, 2005](#), [Leucht et al., 2007](#)).

In theory, osteointegration of extra-cortical bone growth to the shaft of the implant may be associated with a more advantageous biomechanical environment and improved stem fixation. This also may be associated with formation of a “purse string”, which prevents wear particles migrating between the stem-bone interface causing osteolysis([Batta et al., 2014](#), [Ward et al., 1997](#)).

Concerns about successful long-term fixation stimulated advancements in implant design ([Sim et al., 1995](#)) and it has been reported that extra-cortical bone (ECB) bridging and osteointegration at the shoulder of the implant may reduce the risk of aseptic loosening (ASL) by improving stress transfer within the cement mantle([Saran et al., 2011](#), [Chao et al., 2004b](#), [Chao and Sim, 1990b](#), [Tanzer et al., 2003](#), [Taylor et al., 1997a](#), [Chao and Sim, 1992](#)). Chao and Sim, 1990 used finite element analysis to show that ECB bridging and ingrowth reduced stresses on the stem and within the cement mantle([Chao and Sim, 1990b](#)).

Osteointegration may be even more important in skeletally immature patients where the implant is inserted into a growing bone. Due to the small size of the bone, the implant becomes undersized as the patient grows and the increase in the diameter of the endosteal cavity may lead to a loose implant. As the patient grows, loads also increase, making the stem too small to withstand the imposed loads, resulting in fracture([Fromme et al., 2017](#)).

A number of animal and clinical studies have shown that ECB bridging can occur at the shoulder of massive bone tumour implants ([Chao and Sim, 1990b](#), [Heck et al., 1986c](#), [Heck et al., 1986d](#), [Kuo et al., 1983a](#), [Okada et al., 1988b](#), [Ward et al., 1993b](#)).

Heck et al in their study reported that the bone bridging that occurred over the shoulder and conical coupling joint sections greatly improved the stability of the implant because of extra-cortical fixation which further assured the long-term performance of the conical

coupling used in the present modular prosthetic system. They also noted that the biologic response seemed to improve with time, and there were no signs of bone resorption in any regions at the implant-bone interface, regardless of whether the stem was porous-coated. They concluded that these important findings tend to support the concept of extra-cortical fixation as a means to achieve secure implant fixation that does not rely on intramedullary fixation([Heck et al., 1986c](#)).

Similar findings were reported by Okada et al who also suggested that extra-cortical bone-bridging and ingrowth were found to be effective in achieving secure fixation of both the titanium fibermesh-coated and cobalt-chromium-molybdenum bead-coated modular prostheses in dogs that were followed for twelve weeks([Okada et al., 1988b](#)).

However, in the absence of extra-cortical bone formation over the shoulder region, the stem would become the only load-carrying member of the system, and if the stem becomes weak, either because of its small diameter as restricted by the dimension of the cortical cavity and the minimal thickness of the porous layer or by the loss of material strength secondary to the sintering process, stem fracture may become a problem, especially in young and active patients([Heck et al., 1986c](#)).

Although osseous ingrowth within porous and fibermetal ingrowth surfaces has been demonstrated in animal models utilizing segmental bone replacements ([Kuo et al., 1983a](#), [Okada et al., 1988b](#), [Ward et al., 1993b](#)), however in humans, osteointegration

of the extra-cortical bone is limited([Tanzer et al., 2003](#)) and there is only one study that has confirmed ingrowth with direct extra-cortical bone-implant contact in bone tumour implants retrieved from humans([Coathup et al., 2013a](#)).

Extensive research on how the implant surfaces can be engineered to ensure a more robust bone healing response has been carried out over several decades with a view to enhancing osteointegration leading to faster bone healing allowing earlier rehabilitation and return of function ([Goodman et al., 2013](#)).

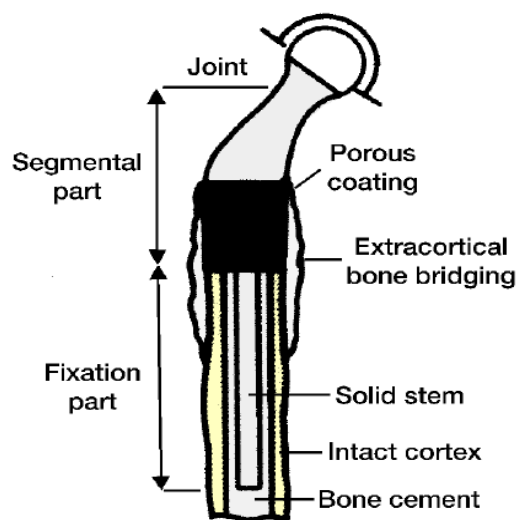


Fig 1.2: Schematic diagram indicating area of extra-cortical bone-bridging overlying bone prosthetic junction([Shin et al., 2000](#)).

1.4.1 Porosity

Successful integration of an implant is generally expected to rely on its surface characteristics such as chemical composition, morphology, and energy. Surface

morphology is an important factor to determine the long-term stability of the implant, especially when bone is osteopenic. Porous metals have been exploited for several decades to increase friction force between the implant and bone and promote initial and long-term stability through bone ingrowth. The advantage of porous materials is their ability to provide biological anchorage for the surrounding bone tissue via the ingrowth of mineralized tissue into the pore spaces. The optimal pore size for bone ingrowth ranges from 100 μm to 600 μm , and the pores must be interconnected to maintain the vascular system required for continuing bone development([Vasconcellos et al., 2010](#)).

In the last 20 years a variety of porous surfaces and materials has been used to obtain fixation of bone ingrowth in total hip and knee prostheses([Bobyn et al., 1999](#)). Highly porous metals, with over 65% interconnected porosity by volume, may be fabricated from a variety of elements including Tantalum (Ta), Titanium (Ti), Titanium Alloy (Ti6Al4V), and numerous other metals used to make alloys. High percentages of interconnected void spaces are important for osteointegration and vascular perfusion, and these materials have been used with considerable clinical success as an adjuvant treatment for implant fixation and bone defect management([Barbas et al., 2012](#), [Hanzlik et al., 2015](#), [Meneghini et al., 2010](#)).

Tantalum is a hard, ductile, highly chemically resistant material with good compatibility to human bone and has been successfully used in clinical applications as a biomaterial

since the 1940s, but because it is both expensive and difficult to machine, its use as a biomaterial has been limited([Wauthle et al., 2015](#)). A porous structure with high interconnecting porosity with a very regular pore shape and size, can be produced using chemical vapour deposition and made into complex shapes and used either as a bulk implant or as a surface coating([Bobyln et al., 1999](#)).

Porous titanium scaffolds show advantages of great connectivity, high surface area, appropriate mechanical strength, and elastic modulus and are thus promising for bone defect repair. Moreover, the porous structures at the presence of interconnected pores can promote nutrient diffusion and therefore facilitate newly formed bone growth into the scaffolds([Li et al., 2015](#)).

The most common material used to manufacture porous implants in orthopaedics is Titanium Alloy (Ti6Al4V) because it is a biocompatible material with a proven clinical track record with a very high strength to weight ratio safety and excellent mechanical properties([Wauthle, 2014](#)). Its excellent chemical inertness, corrosion resistance, re-passivation ability and biocompatibility are thought to result from chemical stability. However, titanium is a bio-inert material, and certain modifications are required to endow it with biomechanical stability, osteoconductive and osteoinductive properties as well as providing a favourable environment for neovascularization and bone regeneration([Yin et al., 2016](#)).

Osteoinduction is means that the primitive, undifferentiated and pluripotent cells are somehow stimulated to develop into the bone-forming cell lineage whereas osteoconduction means that bone grows on a surface that permits bone growth within pores, channels or pipes([Albrektsson and Johansson, 2001](#)).

One way to physically improve overall osteointegration is to increase the implants surface roughness at multiple spatial scales (macro-, micro-, and nanometer)([von der Mark and Park, 2013](#)). Previous studies suggest an optimal surface roughness for hard tissue osteointegration; however, there exists a trade-off between promoting osteointegration and preventing bacterial attachment. Curiously, these tradeoffs have not been thoroughly examined regarding pore size, or material-specific constraints that would promote a more desirable outcome([Lewallen et al., 2015](#)).

The importance of porosity for bone regeneration has been reviewed, however, it is still unclear which aspects of the pore architecture (such as pore size, porosity, and pore layer thickness) control the mechanical and biological properties of porous implants. Furthermore, the overall volume of porosity and its spatial distribution throughout the implant should be considered as a result of the inverse relationship between porosity and strength of porous structures([Torstrick et al., 2016](#)).

When designing porous metal orthopaedic implants, three factors that affect cellular health and are known to influence osteointegration, should be carefully considered.

Porosity determines the resulting strength and density of the bulk material. Depending on the percentage of porosity and porous construct geometry, the surface area available to cell adhesion is considerably influenced, as is the potential for vascularisation and perfusion. Second, pore sizes (macro-, micro-, and nanoscale) determine which cells and tissues will penetrate the material. Fibrous tissue grows into pore sizes of 10–75 μm ; unmineralized osteoid tissue grows into pores 75–100 μm ; mineralized bone tissue penetrates pores $>100 \mu\text{m}$; and optimal bone infiltration/osteointegration occurs in pores sized between 150 and 500 μm . Third, the pore interconnectivity (open vs. closed cell) can greatly influence the potential for osteointegration into an implant because the depth of tissue integration and perfusion of nutrients and oxygen throughout the ingrown tissue can become restricted when cell channels are sequestered or closed([Jones et al., 2009](#)). Understanding pore parameters therefore is of utmost importance to the design, utilization, chemistry, and biology of osteointegration into porous-coated and highly porous orthopaedic implant devices([Lewallen et al., 2015](#)).

The rationale for the porous coated collar was twofold; first, bridging callus growing into the collar provides load transfer from the stem to the bone and second, wear debris from the articulating surface of the endoprotheses migrates into the bone cement interface, inciting a biologic response which results in degradation of bone around the cement([Kaste et al., 1999](#), [Fukuroku et al., 2007](#)).

Based on the clinical outcome and histological evidence from retrieved implants, it is therefore clear that porous surfaces support tissue ingrowth or ongrowth and are generally effective for supplementing the stability of the implant by biological fixation([Boby et al., 1999](#)).

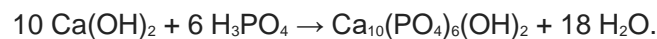
1.4.2 Hydroxyapatite Collars

Numerous biological substances are currently being used in experimental research to coat the surfaces of biomaterials to enhance osteointegration of implant to bone([Frosch and Stürmer, 2006](#)). RGD (arginine-glycine-aspartate) peptides([Dard et al., 2000](#), [De Giglio et al., 2000](#)), collagen([Röhlecke et al., 2001](#)), growth factors([Cole et al., 1997](#), [Lind et al., 2000](#)) fibronectin([Degasne et al., 1999](#)) or hydroxyl-apatite([Carlsson et al., 2005](#), [Cleries et al., 2000](#)) are some of the coatings presently being used, out of which Hydroxyapatite is the most widely used one.

There has been debate regarding the exact mechanism by which osteointegration is improved by hydroxyapatite (HA). Although studies have postulated the biochemical

similarity of HA to bone and that it is also a source of calcium and phosphate which enhances the deposition of a biological-like apatite on the implant surface and enhances osteoblastic activity, it has also been suggested that the microsurface topography of HA rather than its chemistry, promotes osteointegration([Saran et al., 2011](#)). Sintered HA can form tight bonds with living bone with little degradation of the HA layer([Goodman et al., 2013](#)). Regardless of the mechanism of action, many studies show improved bone ingrowth, mechanical strength, and osteointegration with its use([Soballe, 1993](#), [Saran et al., 2011](#), [Zhang et al., 2004](#)).

Synthetic HA is produced by the following chemical reaction:



Bone mineral is not stoichiometrically pure and natural HA has a number of substituted ions such as carbonate making bone formation possible.

Traditionally, HA coatings have been thought of as osteoconductive. However, calcium phosphate biomaterials with certain 3-dimensional geometries have been shown to bind endogenous bone morphogenetic proteins, and therefore some have designated these materials with osteoinductive properties for enhancement of bone formation on orthopaedic implants([Goodman et al., 2013](#)).

Hydroxyapatite coatings not only provide a mechanism to enhance osteointegration, but may also function to seal the interface from wear particles and macrophage associated periprosthetic osteolysis([Rahbek et al., 2001](#)).

The positive influence of a HA coating on bone ingrowth and implant anchorage has been repeatedly confirmed by histological and mechanical evaluations. At the light microscopic level, calcium phosphate has been shown to be non-toxic and non-inflammatory when inserted into bone tissue. At the ultrastructural level, no inflammatory cells have been detected around a HA-coated implant and electron microscopy examination of the bone-hydroxyapatite interface after 3 months in rat femurs revealed a direct chemical bonding between bone and HA without a unmineralized tissue layer at the interface. Therefore on the atomic scale, there is evidence that bone grows directly onto the surface of HA. The absence of an inflammatory reaction from surrounding tissues may be explained by the fact that HA is not considered as a foreign material which normally will be sequestered by fibrous encapsulation but rather as a physiological bone component because of its resemblance to bone ([Soballe, 1993](#)).

HA coatings have been shown to enhance new bone formation on an implant surface with a line-to-line fit and in situations where there are gaps of 1-2 mm between the coated implant and the surrounding bone. In canine studies, new bone formation was found even at distances of 400 μm from the HA surface, suggesting a gradient effect.

Furthermore, the presence of a HA coating prevents the formation of fibrous tissue that would normally result due to micromovement of an uncoated titanium implant([Goodman et al., 2013](#)).

HA is known to increase the attachment of metal implants to bone([Kroon and Freeman, 1992](#), [D'Antonio et al., 1992](#)). One study suggested that bone ingrowth appears to be well advanced by three months after implant placement([Bloebaum et al., 1991](#)), and another study has shown it to be more than 90% at eight months([Hayashi et al., 1991](#)). Numerous animal and clinical studies have demonstrated the osteoconductive properties of HA with excellent results at six to eight years([Gupta et al., 2006b](#)). An animal study showed that triplate fixation using three flexible slotted plates provided early stability and achieved consistent bony integration and fixation. They concluded that HA-coated plates enhance fixation and encourage integration of the plates within the load-bearing structure of the cortex([Coathup et al., 2000](#)).

Coathup et al (2015) reported that a grooved HA-coated ingrowth collar located at the shoulder of cemented distal femoral massive prostheses resulted in increased osteointegration of extra-cortical bone leading to a reduction in the number of progressive radiolucent lines adjacent to the intramedullary cemented stem([Coathup et al., 2015](#)). However, the osseoconductive properties of a hydroxyapatite coating can be highly variable depending on their morphological, chemical, and physical

characteristics. Crystallinity, solubility and stability, thickness and electrical polarization of the HA surface, can all vary with the method of deposition used([Daugaard et al., 2010](#)).

1.4.2.1 HA Deposition Methods

The method of HA deposition on the surface of implants is still an ongoing debate between surgeons. Plasma-sprayed hydroxyapatite coatings have been used as surface coatings on metallic implants since the mid 1980s. The advantages of this technique include stronger bonding between the host bone and the implant and faster fixation, and increased uniform bone ingrowth and/or ongrowth at the bone-implant interface([Sun et al., 2001](#)). This technique requires high temperatures to spray the coating, may cause partial decomposition with formation of heterogeneous calcium phosphates, has a potential risk of debonding from the implant surface, and usually creates an HA coating of heterogeneous structure and uneven thickness above 50 µm necessitating a thick layer to ensure complete coating especially on porous surfaces([Yang et al., 2009](#)).

As an alternative, electrochemical-assisted deposition have been proposed for HA deposition with bone bonding properties comparable to that of plasma-sprayed HA([Scemama et al., 2014](#)). Electrochemical is a process that uses oxidation and reduction to accumulate one material onto the surface of another material. The principle of the electrochemically-assisted calcium phosphate deposition on implants

is based on the pH-dependent solubility of calcium phosphate. Under cathodic polarization of the implant the hydrolysis of water leads to an increase of the pH close to the sample surface, so that the solubility limit is reached and calcium phosphate precipitation takes place([Daugaard et al., 2010](#)). The benefits of electrochemical-assisted deposition of HA on implants is it being three-dimensional in coverage evoking a complete topographical stimulus, more preservative of implant roughness, less thick thus reducing potential coating failure and third-body wear, higher crystallinity of about 70% and being simple and inexpensive in manufacturing([Rößler et al., 2003](#), [Wang et al., 2006](#)).

In an animal study with mechanical pull-out testing, Yang et al. (2008) showed that roughened titanium implants had better initial fixation to bone when they were coated with electrochemically deposited HA than when they only had roughened titanium on the surface([Yang et al., 2009](#)).

1.4.3 Cemented versus Uncemented Fixation

Development of cementless techniques of implant fixation that have a hydroxyapatite-coated prostheses or porous coating essentially sealing the medullary canal and implant bone interface from particulate wear generated at the bearing surface have led to excellent results, matched by the use of cemented fixation combined with a hydroxyapatite collar at the junction of the bone and prosthesis([Myers et al., 2007a](#), [Chao et al., 2004b](#)). Optimal fixation of the endoprosthetic construct continues to be

controversial with advocates of both cemented and noncemented fixation([Calvert et al., 2014](#), [Palumbo et al., 2011](#)). Historically, cemented prostheses were used due to their excellent early biomechanical interface with the host bone and immediate stability allowing for early weight-bearing([O'Donnell et al., 2014](#)). Immediate stability allows for full weight bearing after surgery and has been reported with excellent long-term outcomes. Although this may work well for many skeletally immature patients, the very young child may have a medullary diameter that is too small to allow for a stem with an adequate cement mantle. Press-fit stems, which may help preserve diaphyseal bone stock in the event of future revision reconstructions are also a preferred choice of fixation by other institutions([Levin et al., 2017](#)).

Critics of a cemented endoprosthetic reconstruction technique cite rates of aseptic loosening from 8.4% to greater than 30% as the main rationale for abandoning its use in favour of newer designs([Schwartz et al., 2010b](#)). Uncemented stems have evolved in the last 25 years and less is known about their results compared to cemented stems([Griffin et al., 2005](#)).

Cementless implants designed for biological fixation within bone came about due to unacceptably high rate of implant loosening reported in some centres through the 1960s and 1970s. This was as a result of less than ideal methods for cement use and intrinsic mechanical property limitations of the acrylic bone cement. Uncemented implants offer the advantage of fixation by direct bone-to-implant osteointegration,

where there is viable bone ingrowth into the porous coated implant, providing direct skeletal attachment with dynamic remodelling and repair capabilities, thereby avoiding the use of a synthetic intermediary material such as acrylic bone cement of limited mechanical strength([Pilliar, 2005](#), [Willie et al., 2010](#)).

Most uncemented implants use cylindrical, porous-coated stems for fixation relying on friction between the porous stem surface and the endosteal surface of the medullary canal for initial fixation([Calvert et al., 2014](#)). Uncemented prostheses, if well osseointegrated, were thought to provide durable biological fixation because of bone ingrowth, leading to reduced rates of aseptic loosening ([Flint et al., 2006](#), [Griffin et al., 2005](#), [Mittermayer et al., 2001](#), [Unwin et al., 1996b](#), [Wirganowicz et al., 1999](#), [Blunn et al., 2000](#), [Cristofolini et al., 1998](#), [Meding et al., 2004](#), [Wunder et al., 2001](#), [Farfalli et al., 2009](#)). Similarly, the late complications of cement fatigue failure can also be avoided ([Kinkel et al., 2010b](#)).

While debate exists regarding the optimal method of fixation of an endoprosthesis to the host bone, many surgeons now prefer using uncemented stems as they allow for biological fixation at the host-stem junction that can respond and change depending on the needs of the patient([Unwin et al., 1996b](#), [O'Donnell et al., 2014](#)). However, despite an attentive review of the literature, it remains unclear whether uncemented tumour prostheses have comparable survival and complication rates with cemented

prostheses, and there is no clear support regarding one method of fixation against another([Pala et al., 2013a](#)).

When designing custom made, short-stemmed endoprotheses, extra-cortical plates have also been used by bio-engineers in addition to HA collars to minimise the risk of aseptic loosening by supplementing fixation([Stevenson et al., 2017](#)). HA coated extra-cortical plates was first reported in animal models by Coathup et al who found out that the plates generated new bone formation that enhanced fixation and encouraged integration, offering an alternative to the use of intramedullary cemented stems in patients with only a short segment of bone remaining([Coathup et al., 2000](#)). This led to numerous in-vivo studies with excellent short-term results in small groups of patients([Gupta et al., 2006b](#), [Spiegelberg et al., 2009](#), [Cobb et al., 2005](#)).

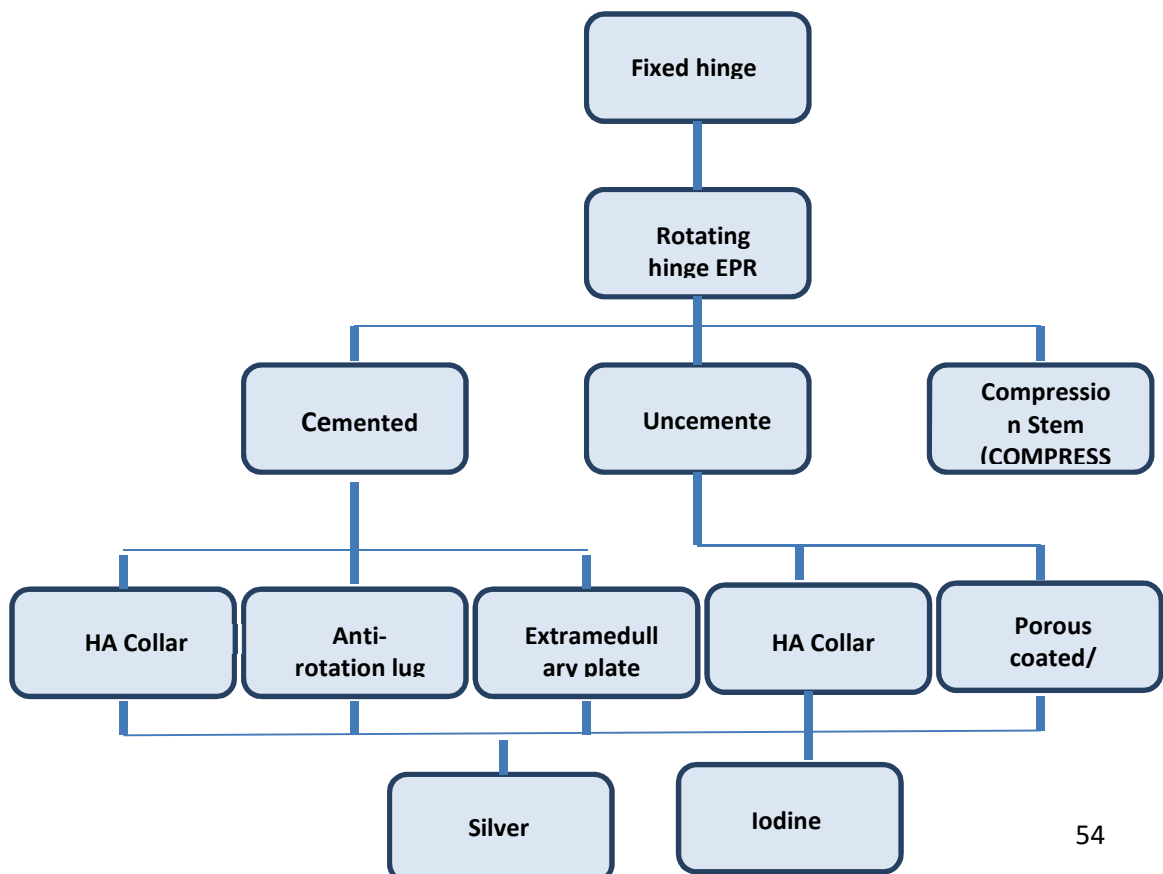


Fig 1.3: Major innovations in implant design since the inception of endoprosthetic replacements([Goulding et al., 2014](#))

1.5 Aims and Hypothesis

The aim of the thesis was to investigate implant survival of distal femoral bone tumour implants in adults and skeletally immature patients and to investigate the relationship between the degree of osteointegration within the hydroxyapatite (HA) coated ingrowth collar located at the bone-implant junction and aseptic loosening (ASL) within the intramedullary fixation.

Therefore it was hypothesised that:

1. HA collars cause increased osteointegration and extra-cortical bone formation between bone and implant.

2. Osteointegration at the collar of distal femoral endoprotheses would reduce aseptic loosening and need for revision surgery for these implant

Chapter 2

Histological and Radiographic follow up of Long-Term Surviving Cemented Distal Femoral Endoprotheses with a Hydroxyapatite-Coated Collar

2.1 Introduction

The aim of this study was to investigate the effect of a circumferential hydroxyapatite-coated grooved ingrowth collar in terms of increasing osteointegration at the shoulder of the implant. In this study, we hypothesized that the hydroxyapatite coated grooved collar at the shoulder of the implant would enhance osteointegration and the direct apposition of ECB to the implant surface, thereby improving implant fixation and reducing the rate of aseptic loosening.

The authors of a retrospective study of Stanmore custom-made distal femoral endoprotheses reported aseptic loosening (ASL) as the principal mid-term mode of failure, with a 67.4% probability of a patient avoiding aseptic loosening for ten years ([Unwin et al., 1996b](#)). Young patients in whom a high percentage of the femur has been replaced had the poorest prognosis for implant survival. Other studies have also shown aseptic loosening to be the major complication, with rates of loosening of distal

fem-oral prostheses reported to be between 2.9% and 28.6% at four to ten years ([Jeys et al., 2008](#), [Kawai et al., 1999](#), [Myers et al., 2007b](#), [Unwin et al., 1996b](#), [Gosheger et al., 2006](#), [Griffin et al., 2005](#), [Mittermayer et al., 2001](#), [Guo et al., 2008](#), [Torbert et al., 2005](#)).

A number of animal and clinical studies have shown that ECB bridging can occur at the shoulder of massive bone tumour implants ([Chao and Sim, 1990b](#), [Heck et al., 1986c](#), [Heck et al., 1986d](#), [Kuo et al., 1983a](#), [Okada et al., 1988b](#), [Ward et al., 1993b](#)).

Although osseous ingrowth within porous and fibermetal ingrowth surfaces has been demonstrated in animal models utilizing segmental bone replacements ([Kuo et al., 1983a](#), [Okada et al., 1988b](#), [Ward et al., 1993b](#)), we are not aware of any studies that have confirmed ingrowth with direct extracortical bone-implant contact in bone tumor implants retrieved from humans. Authors of clinical studies have used radiographs to determine whether bone ingrowth had occurred ([Tanzer et al., 2003](#)) reported that, although radiographic investigation suggested ingrowth at the collar of porous-coated implants in patients, histological analysis revealed no osteointegration and that only fibrous tissue was present within the porous coating.

2.2 Materials and Methods

From 1992 to 2001, 234 limb salvage procedures involving reconstruction with a cemented distal femoral endoprosthesis with a hydroxyapatite coated collar were

performed at the Royal National Orthopaedic Hospital (RNOH) in Stanmore, United Kingdom. Patients who received a distal femoral replacement because of failure of a total knee replacement (ninety-three patients) or a previous distal femoral endoprosthesis (ten patients) or because of a soft-tissue sarcoma secondarily invading bone (twenty-two patients) were excluded from this study, as were skeletally immature individuals following insertion of a primary or revision extendable implant (thirty patients) and individuals in whom the joint-sparing implant had been fixed with extra-cortical plates (fourteen patients). Four patients with a follow-up period of less than two years were excluded as well. Therefore, we investigated implant survival and bone growth into the collar in sixty-one patients (thirty-five female and twenty-six male) who had received a primary cemented distal femoral endoprosthesis for the treatment of bone cancer. The patients were operated by one of the three bone sarcoma surgeons working at RNOH, Stanmore. All patients were skeletally mature, confirmed by fused growth plates on the knee radiographs, at the time of the operation and had no metastasis. The mean patient age (and standard error of the mean) was 39.1 ± 2.3 years. The youngest patient was fourteen years old and the oldest, seventy-nine years of age. Patients were followed for a mean of 8.5 ± 0.5 years (range, two to eighteen years). Osteosarcoma was the most common diagnosis (41%) followed by malignant fibrous histiocytoma (21%) and chondrosarcoma (20%) (Table 2.1). Each patient received a unilateral implant; thirty-two were inserted into the right lower limb and

twenty-nine, into the left. All procedures were performed at a single institution, and no patients were recalled specifically for this study; all data were obtained from the medical records and the most recent radiographs.

Chondroblastoma	1
Chondrosarcoma	13
Fibrous histiocytoma	14
Giant cell tumour	8
Osteosarcoma	25

Table 2.1 Patient diagnosis at the time of surgery

All prostheses were designed by Stanmore Implants (Elstree, United Kingdom) and manufactured on a customized case-by-case basis. The shaft and intra-medullary stem were made from titanium alloy (Ti 318 [Ti-6Al-4V]), and, when indicated, the stem was shaped to follow the natural curvature of the bone. During the period of 1992 to 2001, a Stanmore Modular Individualised Lower Extremity System (SMILES) rotating hinge total joint replacement (Stanmore Implants), made from cast cobalt-chromium-molybdenum alloy, was used in all patients following resection of the knee joint. Following vacuum mixing and pulsatile lavage, pressurized injection of polymethylmethacrylate bone cement (Simplex P; Stryker, Kalamazoo, Michigan) was performed to cement both the tibial and the femoral intramedullary stem. The

hydroxyapatite-coated collar had circumferential and longitudinal grooves 1.5 mm deep, 1.0 mm apart, and 1.0 mm wide. A highly crystalline plasma-sprayed hydroxyapatite coating (>85% crystallinity and 50 µm thick; Plasma Biotal, Plasma Coatings, Tideswell, United Kingdom) was applied to each collar prior to surgery (Figure 2.1).

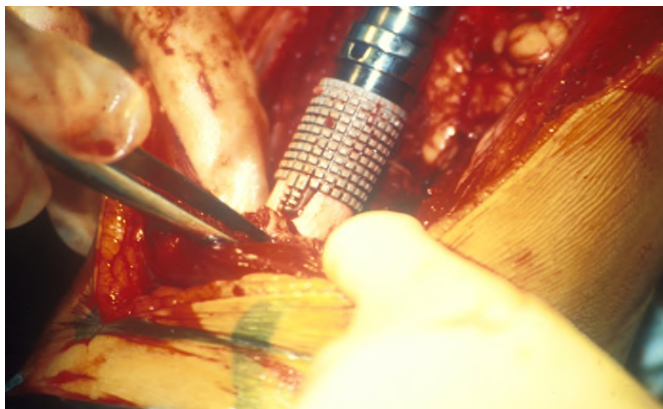


Figure 2.1 A distal femoral massive prosthesis with a HA grooved ingrowth collar located at the implant-bone junction

Surgery was performed with the patient lying supine. A longitudinal incision that excised the biopsy tract and deepened into a medial parapatellar approach to the knee was used. Surgical resection of the periarticular tumour involved the joint, metaphysis, and a part of the diaphysis. Third-generation cephalosporins were administered intraoperatively and for one to seven days postoperatively. When appropriate, patients received neoadjuvant chemotherapy, and all met the criteria for limb salvage([Simon et al., 1986](#)). Chemotherapy was given postoperatively, and partial weight-bearing was

allowed for the first six weeks after surgery, after which the patients slowly progressed to full weight-bearing. After six weeks, the patients returned for a period of intensive physiotherapy.

2.2.1 Radiographic Analysis

The ingrowth of extra-cortical bone at the bone-implant junction was scored on the last follow-up radiograph. The radiographs of four patients could not be located and therefore, no score was assigned in these cases. Extra-cortical bone growth into the grooved hydroxyapatite-coated collar was quantified radiographically in four zones (the medial and lateral aspects on anteroposterior radiographs and the anterior and posterior aspects on lateral radiographs). Extra-cortical bone that was separated from the implant by a clear radiolucent line was considered not in-grown, and was assigned a score of 0. A score of 1 represented extra-cortical bone (>5 mm thick and >1 mm long) in contact with the implant surface in any one of the four (anteroposterior and mediolateral) zones. The maximal score was 4, which represented extra-cortical bone growth in all four zones (Figure 2.2).

The radiographic scoring was performed by Prof Melanie Coathup and Mr Vineet Batta. For the eight patients whose specimens were retrieved at the time of surgery, the radiographic scoring correlated with extra-cortical bone formation seen on gross

examination of the collars. The amount of extra cortical bone formation was similar in length and thickness as seen on the most recent radiographs in these eight patients.

2.2.2 Histological Analysis

Four implants with a hydroxyapatite-coated collar were retrieved from patients who underwent amputation of the limb because of local recurrence at a mean of 3.75 ± 0.75 years (range, 3.0 to 6.1 years). Another four cemented distal femoral massive prostheses manufactured by Stanmore Implants with no collar and used to treat primary bone tumours were retrieved at autopsy before 1992 (at a mean of 3.23 ± 0.92 years [range, 1.4 to 5.8 years] after implantation). On retrieval, all implants with surrounding tissue were placed in 4% paraformaldehyde solution for five days before being processed for calcified histological analysis. After dehydration in serial dilutions of alcohol, specimens were embedded in hard-grade acrylic resin (LR White; London Resin Company, Reading, United Kingdom). Transverse and longitudinal thin sections ($\approx 60 \mu\text{m}$ thick) through the centre of each collar or of each collarless implant were prepared with use of grinding and polishing techniques (EXAKT, Norderstedt, Germany). Sections were stained with toluidine blue (soft tissue) and Paragon (bone).

Each implant was analyzed with use of transmitted light microscopy. The histological analysis was supervised by Prof Coathup.

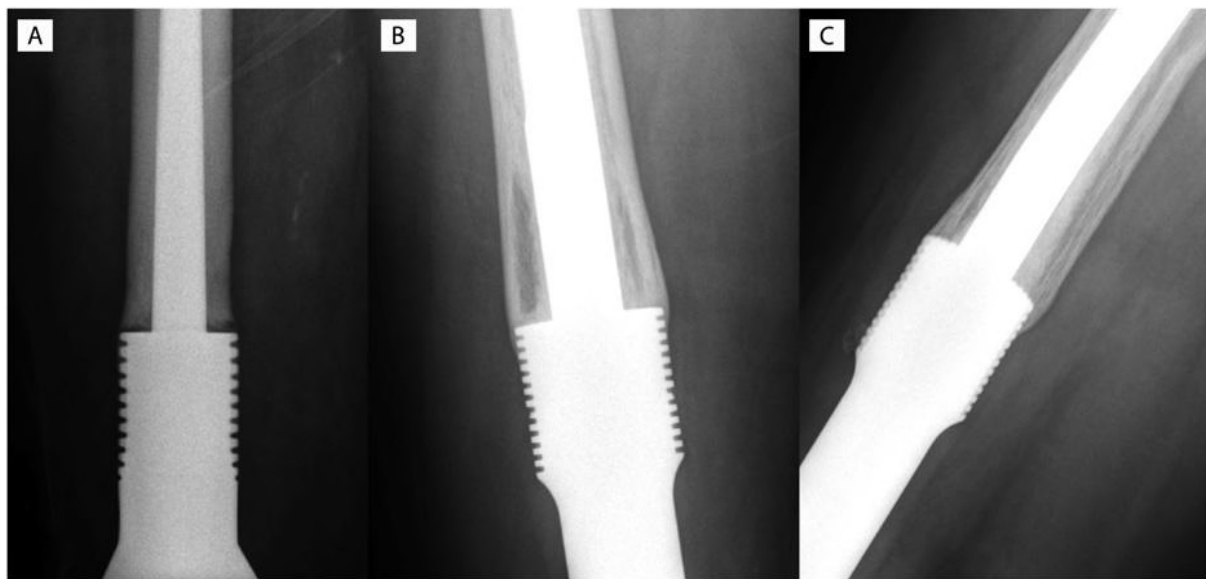


Figure 2.2-A An anteroposterior radiograph of a distal femoral prosthesis fifteen years after it was inserted to treat malignant fibrous histiocytoma in a forty-three-year-old female patient. No extra-cortical bone growth into the hydroxyapatite-coated collar is seen (and none was seen on the mediolateral radiograph), and the score for osseous ingrowth was 0. **Figure. 2.2-B** An anteroposterior radiograph of a distal femoral prosthesis eleven years after it was inserted to treat osteosarcoma in a twenty-seven-year-old man. Bone growth over the collar is seen in both the anterior and posterior regions, resulting in a score of 2. When that score was combined with a score of 1 derived from the lateral radiograph (**Figure 2.2-C**), this patient received a total score of 3 for osseous ingrowth.

2.2.3 Statistical Analysis

Endoprosthesis failure was defined as the need for complete revision of the cemented component and conversion to a different prosthesis. Amputation due to locally

recurrent disease was not included in the implant survivorship analysis as this is unrelated to the durability of the actual prosthesis. Replacement of mechanically worn parts (e.g., bushings for the hinge knee replacement) was counted as a complication and not as implant failure. Loosening secondary to infection was classified as failure due to infection. The duration of follow-up was calculated from the time of surgery to the time of the latest evaluation. Differences in the prevalence of complications were assessed with use of the chi-square test. Limb survival was calculated with Kaplan-Meier analysis starting from the date of the original surgery; prosthetic failure, failure due to infection, and aseptic loosening were the end points.

Cases without failure were censored either at the time of the patient's death or on the date of the last follow-up. Sex, age at the time of surgery, type of neoplasm, and duration of follow-up were assessed, with use of the chi-square test, in a univariate analysis for association with extra-cortical bone formation over the two to eighteen-year follow-up period. The Spearman rank coefficient was used to assess correlation between pairs of continuous variables. A p value of <0.05 was considered significant in all tests, which were performed with SPSS software (version 10.1; SPSS, Chicago, Illinois). The statistical analysis was supervised by Dr Suzie Cro who worked as a statistician at the Medical Research Council Clinical Trials Unit at UCL.

Institutional review board approval was granted by Royal National Orthopaedic Hospital for this study. Copy of approval letters have been attached in the appendix.

2.3 Results

Kaplan-Meier analysis showed that the probability of a cemented distal femoral massive endoprosthesis surviving without aseptic loosening for a mean of 8.5 years was 91.8% (95% confidence interval [CI], 5% to 13.8%). The results also showed that the probability of these implants surviving without revision for any reason for a mean of 8.5 years was 88.5% (Figure 2.3). Kaplan-Meier analysis with revision of the implant for any reason as the end point showed implant survival rates of 75.0%, 84.4%, and 88.5% at five, ten, and more than ten years, respectively. With aseptic loosening as the end point, the survival rates were 93.7%, 88.9%, and 91.8% at five, ten, and more than ten years, respectively. The risk of aseptic loosening was 6% at five years and 11% at ten years.

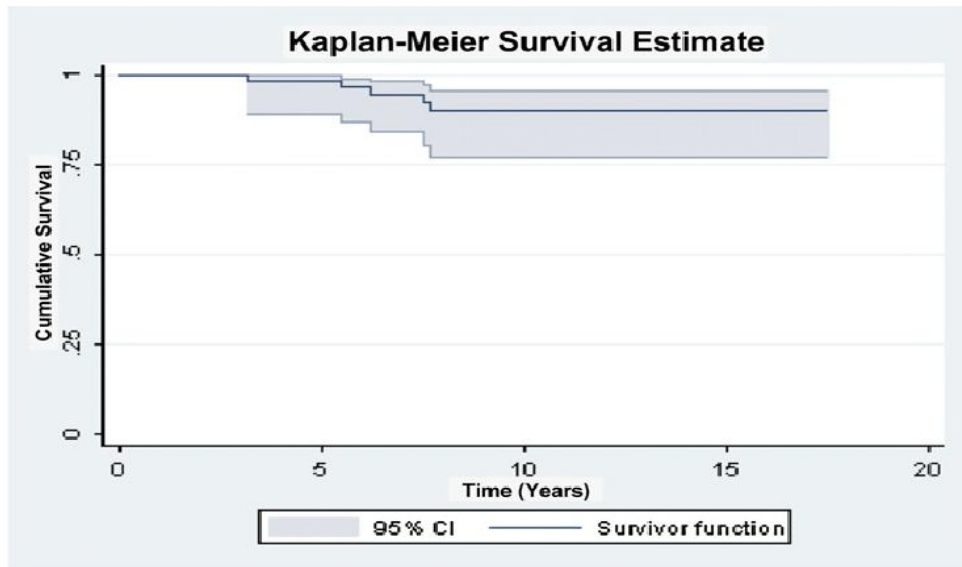


Figure 2.3 Kaplan-Meier survival analysis of the distal femoral prostheses with respect to implant revision due to implant failure for any cause.

Over the two to eighteen-year follow-up period, no complications were reported for twenty-nine (48%) of the sixty-one patients. However, ten of the sixty-one patients died (eight due to metastasis, one of other causes, and one following unknown circumstances), at a mean of 4.7 ± 0.7 years, resulting in an overall patient survival rate of 84%. Nine implants required revision, resulting in an overall implant survivorship of 85%. Of these nine implants that required revision, five (8% of the sixty-one) failed because of aseptic loosening (at a mean, 6.4 ± 1.3 years), two (3%) were revised because of infection (at a mean, 4.5 ± 0.5 years), and two fractured (at a mean, 4.0 ± 0.0 years). With regard to patient or implant complications (and not failures), six (10%) of the patients had the affected limb amputated (at a mean of 4.3 ± 0.9 years); all six of these amputations were performed because of tumour recurrence. Four

implants (7%) required replacement of bushings at a mean of 7.8 ± 1.7 years after implantation, and three patients were successfully treated for recurrence by local excision of the tumour and radiation therapy (Table 2.2). Wound-healing problems were observed in 13% of the patients.

Table 2.2 Death, Implant Failure, and Complications in Patients Cumulated Throughout the Two to Eighteen-Year Follow-up Period (N = 61)*

	5 Years (N = 16)	10 Years (N = 45)	11 to 18 Years (N= 61)	Total No. of Cases
No. of patient deaths	7 (44%)	10 (22%)	10 (16%)	10 (16.4%)
Implant failure				
Aseptic loosening	1 (6%)	5 (11%)	5 (8%)	5 (8%)
Implant fracture	2 (13%)	2 (4%)	2 (3%)	2 (3%)
Infection	2 (13%)	2 (4%)	2 (3%)	2 (3%)
Complications				
Bushing replacement	1 (6%)	4 (9%)	4 (7%)	4 (7%)
Amputation	4 (25%)	6 (13%)	6 (10%)	6 (10%)
Local excision of tumour	0 (0%)	3 (7%)	3 (5%)	3 (5%)
Total events				32 (52%)

*Thirty-two patients (52%) underwent revision or had complications. Sixteen patients were followed for five years only; forty-five, for ten years only; and sixty-one, in total. The chi-square test showed that age, sex, follow-up time, and diagnosis had no significant correlations with the incidences of infection, amputation, fracture, bushing replacement, loosening, or death.

2.3.1 Radiographic Analysis

Extra-cortical bone growth was measured, and the amount varied among the patients. Most bone formation occurred in the anteromedial aspect of the collar. The average extra-cortical bone ingrowth score was 1.68 ± 0.18 . The score was 0 (no extra-cortical bone had osteointegrated with the hydroxyapatite-coated collar) for seventeen (30%) of the fifty-seven patients with radiographs, 1 for seven patients (12%), 2 for fifteen (26%), 3 for thirteen (23%), and 4 (maximum) for five (9%). Forty (70%) of the collars showed radiographic evidence of osteointegration.

At the five-year follow-up interval, only two of fifteen patients scored 0 and thirteen of the collars had osteointegrated. At the ten-year follow-up interval, twenty-seven (66%) of forty-one patients had an osteointegrated collar. There was no significant association between osseous growth into the collar and age, sex, follow-up time, diagnosis, or reason for failure. Kaplan-Meier analysis showed that the rate of survival of implants with bone growth into the collar (98.0% at ten and fifteen years) was higher than that of implants with no bone ingrowth (75.0% at ten and fifteen years); however, the log-rank test showed no significant difference between these survival rates (Figure 2.4).

2.3.2 Histological Analysis

Macroscopic analysis of retrieved hydroxyapatite-coated collars showed extra-cortical bone growth over the shaft of the implant with osteointegration within the grooves of

the collar. Often, bone was seen deep within the grooves over a large area of the hydroxyapatite-coated collar. Light microscopy showed mature lamellar bone in direct contact with the implant surface (Figure 2.5). In many regions, osteoblasts were actively depositing osteoid. In contrast, every implant without a collar showed a layer of fibrous tissue separating the extra-cortical bone growth from the implant surface. Despite relatively good extra-cortical bone growth adjacent to the shaft of the collarless implants, no direct bone-implant contact was identified in any region in any of these specimens.

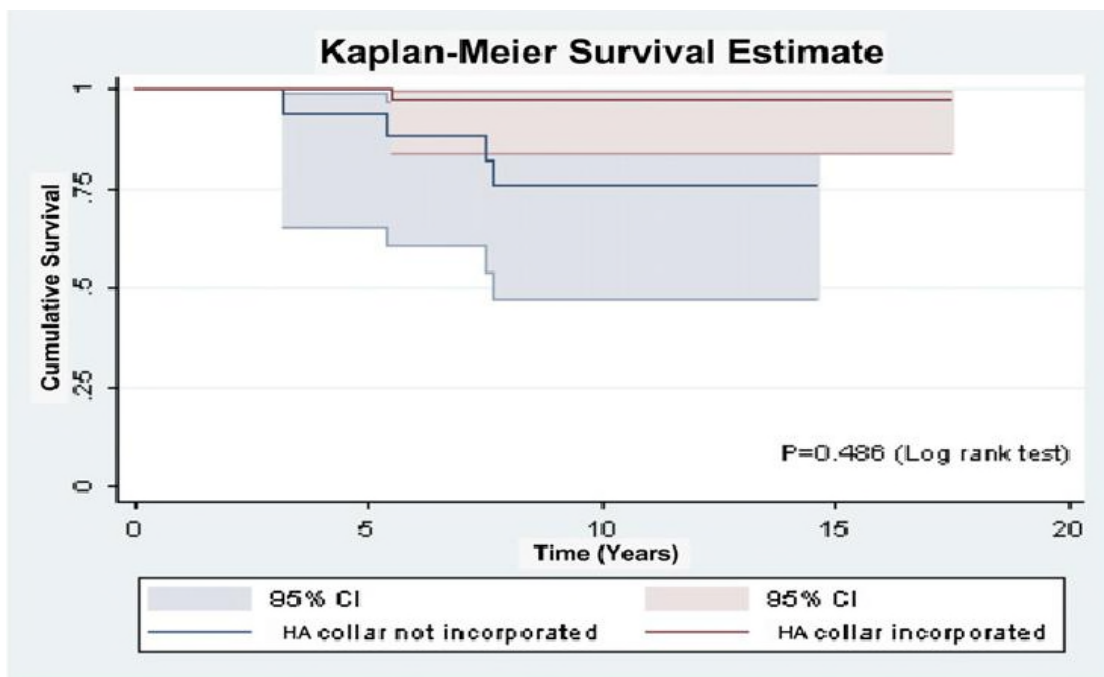


Figure 2.4 Kaplan-Meier survival analysis, with respect to aseptic loosening, of the distal femoral prostheses with ingrowth into the hydroxyapatite (HA)-coated collar compared with those with no radiographic signs of ingrowth into the collar.

2.4 Discussion

Tumours in the distal part of the femur continue to challenge patient survival, and the ability to achieve adequate long-term success with segmental massive endoprostheses is increasingly important. Although these implants are widely used, the rate of complications for any reason remains five to ten times higher than rates seen following routine total joint arthroplasties ([Gosheger et al., 2006](#), [Ahlmann et al., 2006b](#), [Sim et al., 2007](#)).

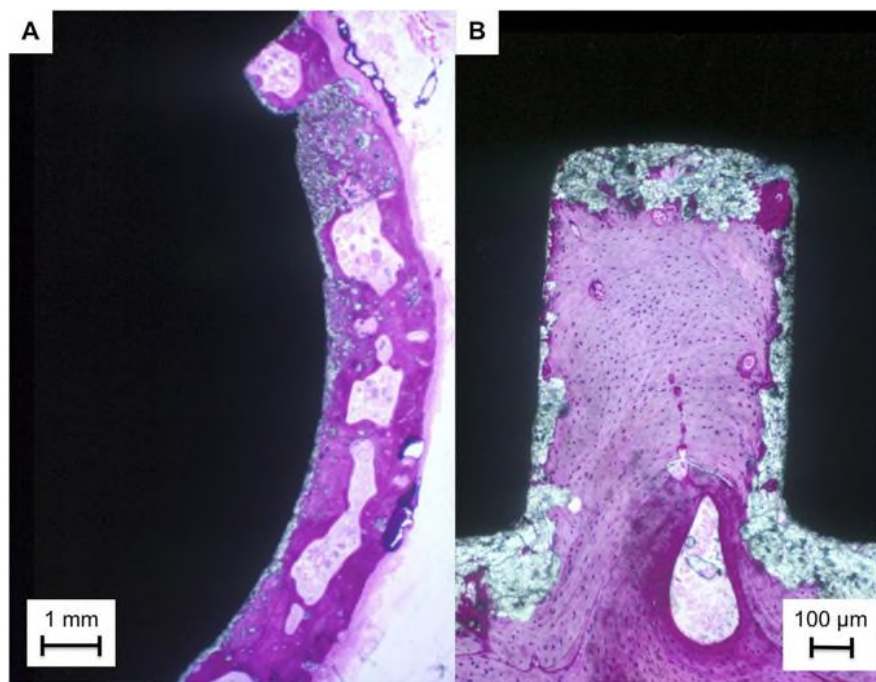


Figure 2.5-A A photomicrograph of a transverse section through a hydroxyapatite-coated ingrowth collar showing mature lamellar bone in direct contact with the implant surface. **Fig. 2.5-B** A magnified image of a single groove within the collar (Paragon and toluidine blue for both figures).

In theory, osteointegration of extra-cortical bone-bridging to the implant surface at the shoulder of massive bone tumour implants may be associated with a more

advantageous biomechanical environment and improved stem fixation([Chao and Sim, 1990b](#), [Taylor et al., 1997b](#), [Unwin et al., 1996b](#), [Ward et al., 1993b](#)). The aim of this study was to investigate the effect of a circumferential hydroxyapatite-coated grooved ingrowth collar in terms of increasing osteointegration at the shoulder of the implant. It was hypothesized that increased osseous attachment would decrease the rate of aseptic loosening of the cemented stem. Our study showed a low rate of revision due to aseptic loosening (8%) and demonstrated radiographic evidence of osteointegration of the collar in 70% of patients over a two to eighteen-year follow-up period. Histological analysis of four implants confirmed osseous ingrowth within the grooved collar with direct bone-implant contact.

There have been a number of clinical studies investigating methods of augmenting bone growth into the shoulder of the implant([Kuo et al., 1983a](#), [Okada et al., 1988b](#), [Ward et al., 1993b](#)). These have involved the use of fibermetal ([Heck et al., 1986c](#), [Kuo et al., 1983a](#)) or porous ingrowth surfaces with and without the use of autograft or allograft procedures ([Chao et al., 2004a](#), [Ward et al., 1993b](#)). Osteointegration was assessed radiographically in all of these studies, and all of the authors reported varying amounts of extra-cortical osseous bridging. In a human retrieval analysis, Tanzer et al ([Tanzer et al., 2003](#)) investigated osseous growth into a porous-coated collar in twenty patients in whom a bone tumour had been treated with a massive endoprosthesis. At a mean of 2.3 years postoperatively, radiographic assessment

demonstrated extra-cortical bone-bridging adjacent to most of the prostheses, but histological analysis showed fibrous tissue and not bone within the porous coating and no bone-implant contact was seen.

Histological analysis in our study showed that, when no collar was present, the extra-cortical bone that formed at the shoulder did not osteointegrate but was instead separated from the surface of the implant by a layer of fibrous tissue. In contrast, when a grooved hydroxyapatite-coated structure was used, direct bone contact with the surface of the implant was seen. To my knowledge, this is the first study that has confirmed osteointegration with direct contact between the extra-cortical bone and the shoulder of massive bone tumour endoprosthesis in patients.

Unwin et al([Unwin et al., 1996b](#)) reported on 493 distal femoral prostheses manufactured by Stanmore Implants without a hydroxyapatite-coated collar and inserted at the Royal National Orthopaedic Hospital, Stanmore, and at the Royal Orthopaedic Hospital, Birmingham, United Kingdom. They found the probability of an implant surviving without aseptic loosening to be 90.1% at five years and 67.4% at ten years. In my study, distal femoral implants with a hydroxyapatite-coated grooved collar had survival rates of 93.7% at five years, 88.9% at ten years, and 91.8% after a mean duration of follow-up of 8.5 years (range, two to eighteen years). There was a statistically insignificant trend for an increase in the survivorship of implants with

osteointegration of the collar compared with that of the implants in which no osteointegration was measured.

The rate of aseptic loosening in this study was also lower than that reported in several other studies with a similar follow-up period. Schwartz et al ([Schwartz et al., 2010a](#)) reviewed the cases of 186 patients who had undergone distal femoral endoprosthesis reconstruction and reported an aseptic loosening rate of 18.8% at a mean of 8.0 years (range, one to twenty-eight years). Bickels et al([Bickels et al., 2002](#)) evaluated 110 patients who had received a cemented distal femoral prosthesis and reported an aseptic loosening rate of 7.0% at five years and 12% at ten years. Ahlmann et al([Ahlmann et al., 2006b](#)) found a loosening rate of 25.0% at five years and 42.0% at ten years for modular distal femoral massive prostheses. Torbert et al([Torbert et al., 2005](#)) and Farfalli et al([Farfalli et al., 2009](#)) found loosening rates of 16.0% and 15.0%, respectively, at five years and 34.0% and 29.0% at ten years.

This study had several limitations. First, it was a retrospective and observational analysis of patients treated over a long period of time. Second, there was no control group with which to make direct comparisons regarding the effect of osteointegration on aseptic loosening. Histological assessment of extra-cortical osseous ingrowth in direct contact with the hydroxyapatite-coated collar in each patient was not possible. All retrieved implants with a hydroxyapatite-coated collar that underwent histological analysis also showed radiographic evidence of osteointegration. Similar findings were

seen on clinical radiographs, whereas the implants without a hydroxyapatite-coated collared showed a definite radiolucent line between the shaft and the new bone. However, it is possible that, although some implants showed radiographic evidence of osteointegration, direct osseous ingrowth had not occurred, as was reported by Tanzer et al([Tanzer et al., 2003](#)). Each surgical procedure differs for each patient with a bone tumour, with variations in the amount of bone and soft tissue resected. This could affect the durability and function of each implant, even in patients with identical diagnoses. In addition, there are wide variations in patients' height, weight, age, and dose of chemotherapy. In this study, the patients' age, sex, and diagnosis were investigated for any correlation with bone formation, and none were found. Their height, weight, level of resection, and dose of chemotherapy were not investigated, and these factors may all affect implant survival. In this study, variation was minimized because all implants were of a similar design and made by a single manufacturer. Surgical techniques and patient care were also consistent as all patients were treated at a single institution. While the limitations of this study do not allow us to conclude that extra-cortical bone growth into the hydroxyapatite-coated grooved collar is directly responsible for the low aseptic loosening rate observed, our results do confirm the ability of the ingrowth collar to increase bone-implant contact at the implant shoulder. This may have significant effects in terms of reducing the rate of aseptic loosening in patients who receive massive bone tumour prosthesis.

Chapter 3

Uncemented, custom-made, hydroxyapatite-coated collared distal femoral endoprostheses

3.1 Introduction

The optimum method of fixation of endoprostheses is still controversial. Both cemented and uncemented modes of implant fixation have been used to meet the need for long term success. Uncemented prostheses, if well osteointegrated were thought to have lesser incidence of aseptic loosening and hence a better long term survival than cemented prostheses([Abdulkarim et al., 2013](#)). A recent meta-analysis comparing cemented with uncemented THR, concluded that cemented THR is similar if not superior to uncemented THR and provides better short term clinical outcome. There is no such meta-analysis on endoprostheses, primarily because of the smaller number of patients in each study and also because of the several confounding factors like grade and spread of the tumour, variation in chemotherapy and radiotherapy protocols, and surgeon preference etc([Abdulkarim et al., 2013](#)).

In this study, we investigated the long term survival of uncemented, custom made and hydroxyapatite (HA) coated DFRs at follow-up of up to 18 years and compared it to our results of cemented DFR in adults.

Hypothesis : Uncemented HA-coated DFR have a equivalent survivorship as compared to cemented DFR.

3.2. Patients and Methods

Between 1994 and 2006, 90 patients underwent uncemented DFR surgery for malignant tumours of the distal femur. In order to decrease the number of confounding factors, patients with a soft-tissue sarcoma secondarily invading bone, haematological malignancies, metastatic cancers and non-oncological disease were excluded, leaving 69 patients in the study. There were 31 women and 38 men with a mean age at implantation of 16.5 years (five to 37). Data was retrieved retrospectively from clinical notes, from telephone consultations and following radiograph reviews. A total of 33 patients (48%) were skeletally immature and had a minimally-invasive or non-invasive, extendible endoprosthesis implanted. The mean follow-up period for all patients was 124.2 months (4 to 212).

In this study, all implants were HA coated and the extent of coating was determined by the location and length of the stem ([Scharschmidt et al., 2011](#)). Where the implant was fixed into a convergent canal, the stem was only partially coated and where the stem was implanted into a divergent canal it was fully coated. If the canal was neither divergent nor convergent then the stem was partially HA coated. In order to encourage bone growth to the shoulder and shaft of the implant (extra cortical bridging), the HA coating was extended over a grooved collar region located on the shaft (Figure 3.1).

The indications for surgery were typical of a series of distal femoral bone tumours with the most common cause being osteosarcoma (n = 51), which accounted for 73.9% of tumours in 69 patients (Table 3.1).

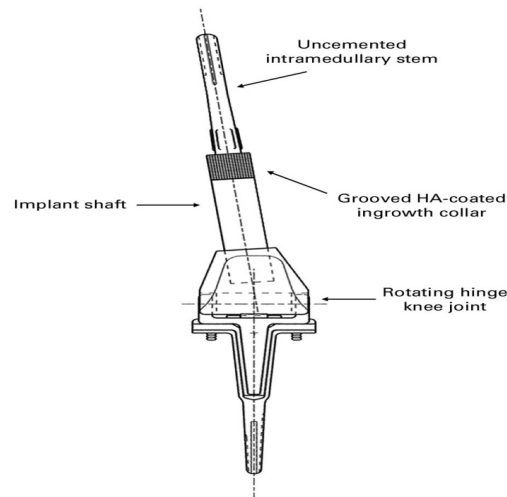


Fig 3.1: Drawing of an uncemented distal femoral endoprosthesis replacement (HA, hydroxyapatite).

Table 3.1 Diagnoses of the 69 patients treated with a cementless distal femoral endoprosthesis replacement.

Diagnosis	n (%)
Osteosarcoma	51 (74)
Giant cell tumour	9 (13)
Ewing's sarcoma	3 (4)
Chondrosarcoma	2 (3)
Chondroblastoma	2 (3)
Malignant fibrous histiocytoma	2 (3)

Standard techniques for tumour resection were used, with the principle of obtaining a wide surgical margin. A rotating hinge knee joint was used in all cases and all DFRs

were custom-made, based on pre-operative imaging. The intramedullary cavity was prepared using a custom-made non-flexible reamer. All intramedullary stems were manufactured straight and designed for interference within the canal through the addition of the HA coating, which was 0.15 mm thick on the diameter. A trial stem was used to assess the fit of the implant into the bone, and a cutter used to prepare the bone so that the shoulder of the implant was fully seated on the transection site. The trial stem was manufactured to the size of the intended implant but without the thickness of the HA coating. The mean length of femur resected was 19.6 cm (13 to 28), which represented a mean proportional resection of the femur of 40.2% (28% to 65%).

Implant failure was defined as the need for removal and/ or revision of the uncemented DFR([Flint et al., 2006](#)). Implant failures were identified and classified as five primary modes of endoprosthetic failure as defined by ([Henderson et al., 2011b](#)). Minor procedures such as bushing exchanges for the knee hinge axle and knee manipulation were not considered implant failure. Analysis to determine independent predictors of aseptic loosening were performed and included age, proportion of femur resected, ratio of the total length of prostheses (TLP)/stem length (SL), grade of the malignancy and use of chemotherapy. All radiographs were independently reviewed by two blinded individuals and analysed for the described parameters. Known dimensions of the implant components were used to verify image calibrations provided by the digital

calibrations using Picture Archive Communication System (PACS, Centricity, GE Healthcare, Buckinghamshire, UK).

3.2.1. Statistical Analysis

Analysis of time to failure was performed using the Kaplan–Meier survival method, with 95% confidence intervals (CI) defining failure firstly as any cause of DFR removal. Time was defined as the point at which failure occurred or last known follow-up time when failure had not occurred. The associations between the continuous factors of interest and aseptic loosening were assessed using an independent *t*-test. Associations between binary factors of interest and aseptic loosening were assessed using the Fisher's Exact test. Odds ratios (OR) with 95% CIs were calculated to quantify the relative odds of aseptic loosening.

To determine optimum cut-offs in order to predict aseptic loosening for the variables significantly associated with aseptic loosening, receiver operating characteristic (ROC) curves were plotted. The total area under the ROC curve plot represents the ability of the variable to differentiate between those who had aseptic loosening and those who did not. The closer the area is to one, the better the differentiation of the predictor variable. All statistical analysis was performed using Stata/IC v12.1 (StataCorp, College Station, Texas). A *p*-value < 0.05 was used to define significance.

Institutional review board approval was granted by Royal National Orthopaedic Hospital for this study.

3.3. Results

A total of 16 patients (23.2%) died of metastatic disease at a mean of 19.3 months (4 to 96) after primary surgery. One patient of the remaining 53 was lost to follow-up after four years but was asymptomatic at that time, leaving 52 patients followed up clinically and radiologically for a minimum of five years. The overall survival, including patients who died from metastatic disease or those who had complications necessitating endoprosthesis removal, was 72.7% (95% CI 58.7 to 82.6) at 5 years, 64.6% (95% CI 50.1 to 75.8) at 10 years and 54.8% (95% CI 36.8 to 69.6) at 15 years (Figure 3.2).

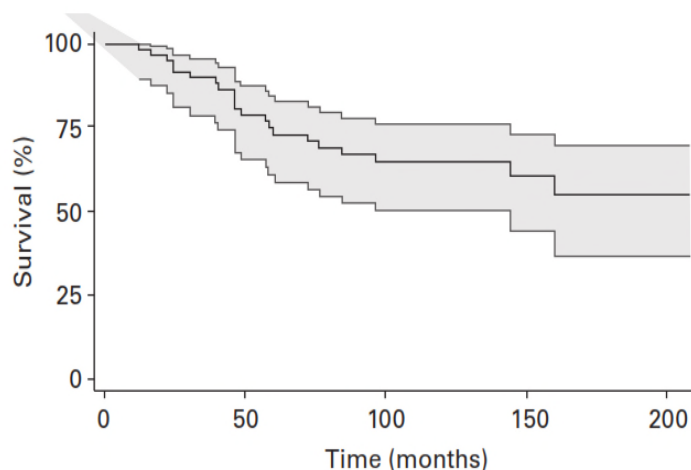


Figure 3.2 Kaplan-
Meier estimates of overall survivorship (with 95% confidence intervals) showing survival rates of 72.69% (95% CI 58.74 to 82.59), 64.57% (95% CI 50.06 to 75.84) and 54.78% (95% CI 36.79 to 69.62) at 5, 10 and 15 years, respectively.

Aseptic loosening was the most common mode of failure (Table 3.2). Only two patients developed post-operative aseptic wound dehiscence, requiring free muscle flap

coverage and one underwent patellar tendon reconstruction. Instability of the knee joint occurred in two patients, which resolved after exchange of the bushes and patella tendon realignment surgery. Analysis of time to failure was subsequently performed, defining failure as aseptic loosening only. Survival at 5, 10 and 15 years was 84.28% (95% CI 70.83 to 91.87), 82% (95% CI 68.06 to 90.27) and 82% (95% CI 68.06 to 90.27), respectively (Figure 3.3).

A total of nine patients (13%) showed clinical or radiological signs of aseptic loosening at a mean of 29.7 months (13 to 76). Subsequently seven patients were revised to a cemented DFR, one is still awaiting revision surgery and one died from metastatic disease. There were two patients who had an intra-operative fracture around the distal part of the femoral shaft, necessitating supplementary fixation with cables. In four patients, intra-operative technical difficulties with the custom-made reamers and prosthesis at the time of primary surgery, resulted in suboptimal press-fit fixation of the stem, with a gap of 3 mm to 6 mm identified between the collar and the distal end of the femur in two patients; all four developed early aseptic loosening. A retrospective review of the post-operative radiographs demonstrated inadequate press-fit fixation, which led to delay in the osteointegration of these implants and contributed to early loosening.

Table 3.2 Mode of failure using the classification of Henderson et al

[\(Henderson et al., 2011b\)](#)

Mode of failure	Description	Incidence (n, %)
Soft-tissue failure	Instability, tendon rupture or aseptic wound dehiscence	5 (7)
Aseptic loosening	Clinical and radiological evidence of loosening	9 (13)
Structural failures	Peri-prosthetic/prosthetic fracture or deficient osseous supporting structure	6 (10)
Infection	Infection about endoprosthesis necessitating removal of device	5 (7)
Tumour progression	Recurrence or progression of tumour with contamination of endoprosthesis	2 (4)

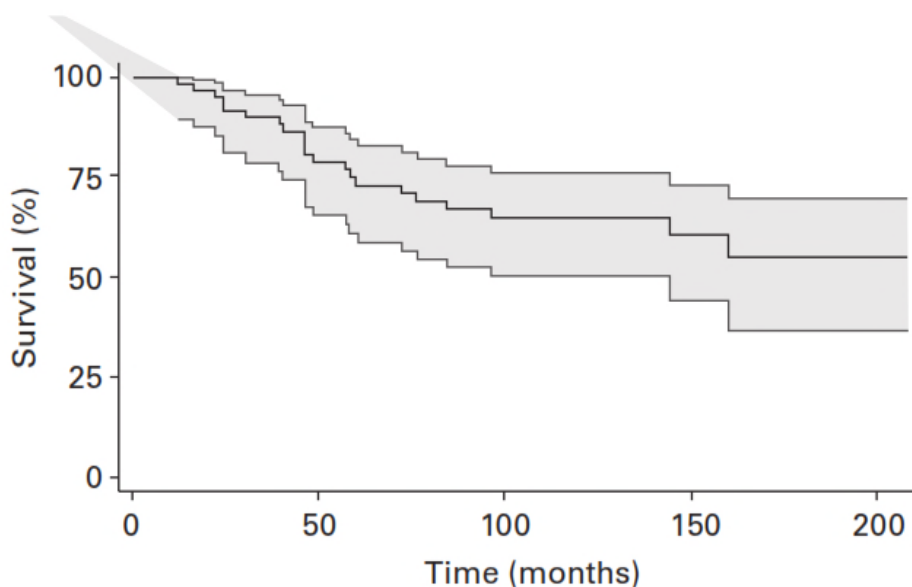


Figure 3.3 Kaplan–Meier survival analysis (with 95% confidence intervals) with failure defined as aseptic loosening, showing survival rates of 84.28% (95% CI 70.83 to 91.87), 82% (95% CI 68.06 to 90.27) and 82% (95% CI 68.06 to 90.27) at 5, 10 and 15 years, respectively.

We also found that following multivariate analysis (Table 3.3) and when the resection length of the femur exceeded 46%, there was a significantly higher rate ($p = 0.01$) of failure in terms of aseptic loosening and implant fracture. The independent t -test showed a significant difference in the mean resection length in patients with aseptic loosening and in those without aseptic loosening ($p = 0.008$). An OR of 1.16 (95% CI 1.03 to 1.31) complimented this result and showed that the odds of aseptic loosening increased as the length of bone resection increased. The independent t -test also demonstrated a significant difference in TPL/SL ratio in patients with aseptic loosening compared with patients without aseptic loosening ($p = 0.04$). An OR of 2.38 (95% CI 0.98 to 5.78) for a 0.1 unit increase in TPL/SL ratio showed that the relative odds of developing aseptic loosening increased as the TPL/SL ratio increased. ROC curves investigated the optimal resection length (%) and TPL/SL ratio that differentiated between those patients with aseptic loosening and those without (Figures 3.4 and 3.5). OC curves showed good predictability with an area under the curve of 0.79 and 0.74 (% resection length and TPL/SL respectively). The optimal cut-off point for resection length was identified as 46.5% and 1.43 for TPL/SL ratio.

There were four prostheses that fractured (structural failure) at a mean of 68.5 months (12 to 160). Of those, three fractured at the shaft of the femoral component and one at the shaft of the tibial component. Of the fractured femoral components, two demonstrated concomitant aseptic loosening of the femoral stem but one appeared to

be well osseointegrated, with no signs of aseptic loosening (Figure 3.6). In this prosthesis, the shaft had fractured through the growing mechanism which was replaced, leaving the stem *in situ*. Aseptic loosening appeared at 30 and 44 months, respectively, before the stems fractured. All these failed implants were revised to a cemented DFR.

Table 3.3 Statistical analysis of factors that may have led to aseptic loosening. Data is presented as mean (SD) for continuous variables and n (%) for binary variables. Odds ratios (OR) quantify the relative odds of aseptic loosening for a unit increase in the continuous variables or change in the level of the binary variables; CI, confidence interval.

Factor	Patients (n)	Aseptic loosening (n=9)	No aseptic loosening (n = 60)	p-value	OR (95% CI)
Mean (SD) age (yrs)	69	16 (8)	16 (11)	0.86	1.01 (0.93 to1.10)
Tumour grade (n, %)	69			0.35	0.40 (0.09 to1.87)
High		6 (9)	50 (72)		
Low		3 (5)	10 (14)		
Mean (SD) resection length (%)	54	46.5 (6.41)	39.5 (6.69)	0.01	1.16 (1.03 to1.31)
Mean (SD) TPL/SL ratio*	52	1.43 (0.08)	1.36 (0.09)	0.04	2.38* (0.98 to 5.78)
Chemotherapy (n, %)	69			0.47	2.18 (0.42 to 11.39)
Yes		7 (10)	37 (54)		
No		2 (3)	23 (33)		

* The OR is presented to quantify the odds of aseptic loosening for a 0.1 unit increase in the ratio of total prosthetic length/stem length (TPL/SL) ratio.

A total of five patients (7.2%) developed deep infection at a mean of 30.4 months (7 to 53) from the index procedure. Three underwent a two-stage revision to a cemented DFR and two underwent above the knee amputation.

All the patients were free of metastases at the time of initial diagnosis but 19 (27.5%) subsequently developed metastatic disease at a mean of 14.7 months (1 to 96) post-operatively. There were two cases of local recurrence of the tumour noted. One recurrence was successfully excised and the other patient underwent hip disarticulation.

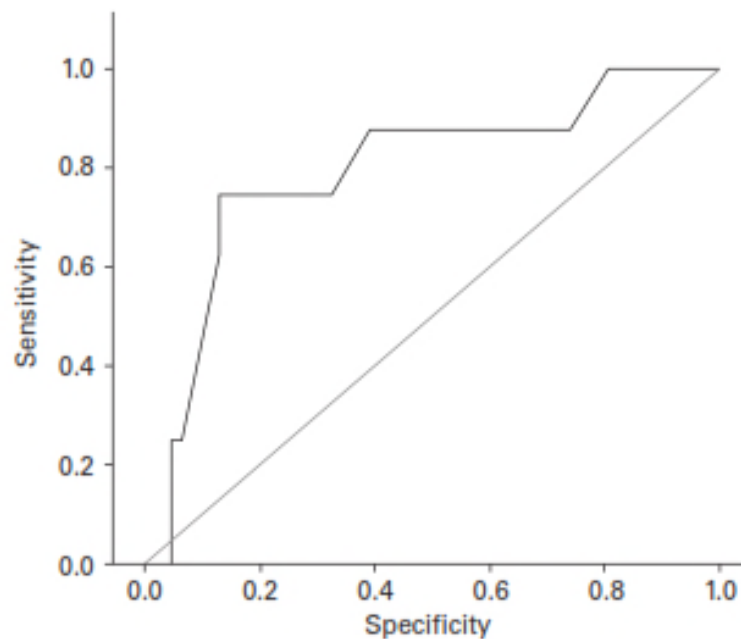


Figure 3.4 Receiver operating characteristic curve showing good predictability of aseptic loosening by resection length (%). The area under the curve is 0.795 and the optimal cut-off point was 45.5%.

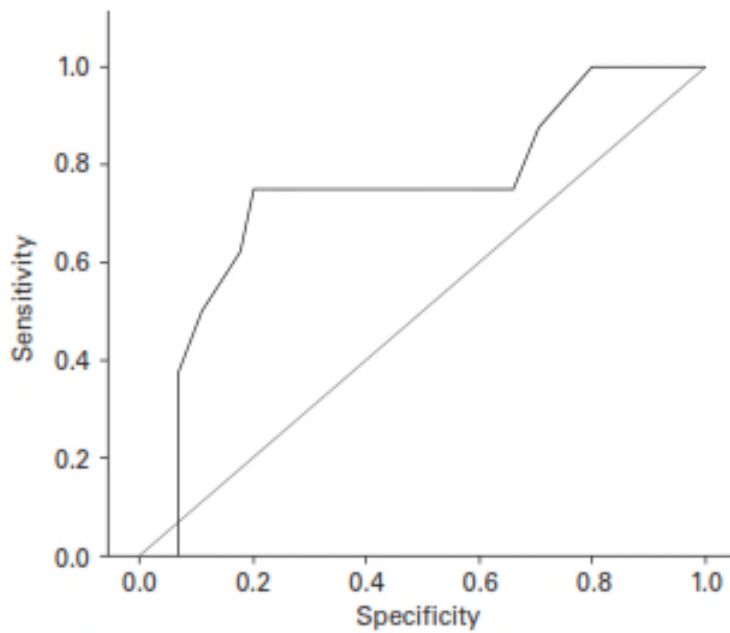


Figure 3.5 Receiver operating

characteristic curve showing good predictability of aseptic loosening by total prosthesis length/stem length ratio with an area under the curve of 0.74 and an optimal cut-off point of 1.41.

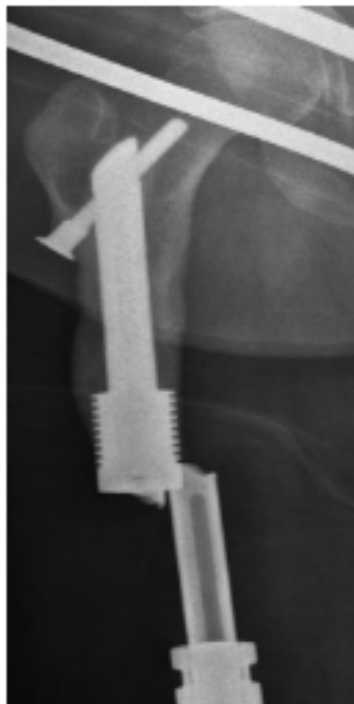


Figure 3.6 Radiograph of a broken femoral component in a female patient aged 17 years without signs of aseptic loosening 169 months after surgery.

The radiological analysis of remodelling of the cortical bone from surgery to final follow-up showed that well-fitted implants (with no radiolucent gap in the initial post-operative films) in patients who were able to bear full weight without any pain, tended to show proximal hyper-trophy near the tip of the stem, with more distal atrophy producing an hourglass appearance (Figure 3.7). Bone reabsorption was associated with loss of the outer cortex at the mid-stem level, but this did not progress after two years. Remodelling of the femoral shaft around the stem was first noted in radiographs at a mean of 7.3 months (4 to 15). Remodelling stabilised at a mean of 29.4 months (17 to 63). Hourglass formation was observed in 17 patients. For aseptically loose endoprotheses varying zones of hypertrophy and atrophy were observed without any obvious pattern. Loose stems generally had some cortical hypertrophy in the distal lateral region.

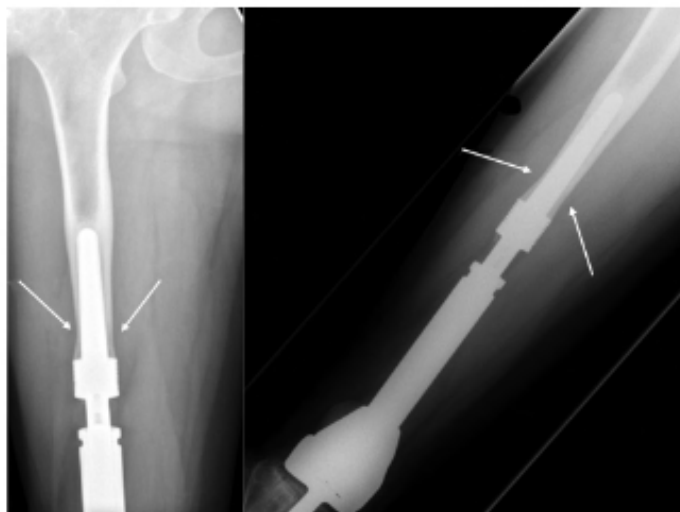


Figure 3.7 Radiograph showing cortical remodelling of a well-fitted distal femoral replacement 24 months post-operatively in a 24-year-old male. Arrows show the 'hour glass' appearance.

3.4. Discussion

Our uncemented DFRs had an incidence of aseptic loosening of 13.1% at 17.5 years follow-up, which is higher than that of our most recent 18-year follow-up of cemented DFRs at 7.7% ([Coathup et al., 2013b](#)). The Stanmore prosthesis was first implanted in 1949 ([Unwin et al., 1996b](#), [Unwin et al., 1993](#)) as a custom-made prosthesis with cemented fixation. Since 1991 a cementless version has been available. Unwin et al ([Unwin et al., 1996b](#)) reviewed 1001 cemented endoprostheses (49.3% distal femur, 26.3% proximal femur and 24.5% proximal tibia) with a mean follow-up of 46 months (3 to 287). The principal cause of failure was aseptic loosening with a rate of 9.9% at the distal femur, 6.5% at the proximal tibia and 2.3% at the proximal femur. Bradish et al ([Bradish et al., 1987](#)) and Roberts et al ([Roberts et al., 1991](#)) also reported low rates of revisions due to aseptic loosening (0% and 6% respectively) in their 16 year follow-up studies of cemented endoprostheses. For the HA coated cementless version the short-term results of 47 reconstructions reported only one case of aseptic loosening after a mean follow-up of 15 years (10 to 35) ([Jeys et al., 2008](#)).

Comparison of the results of cemented and cementless fixation of a DFR are confounded because of differences in implant design, the use of chemotherapy and local radiotherapy, the amount of bone and soft-tissue resected and fixation concepts. Proponents of uncemented DFR like Kinkel et al ([Kinkel et al., 2010b](#)) have reported an aseptic loosening rate of 25% in cemented *versus* 9% in uncemented using the

Modular Universal Tumour And Revision System[®] (MUTARS) (Implant cast, Buxtehude, Germany) DFR at a mean follow-up of 46 months (3 to 128). Similar favourable results for cementless prostheses have been reported with other cementless implants([Griffin et al., 2005](#), [Kawai et al., 1999](#), [Ilyas et al., 2001](#)). In contrast, Bickels et al ([Bickels et al., 2002](#)) favoured cemented prostheses and reported survival rates of 88% for 110 cemented DFRs inclusive of custom, modular and expandable implants at a median follow-up of 7.8 years (two to 16.5). Heisel et al ([Heisel et al., 2006a](#)) reported a prosthetic failure rate of 27% when Kotz Modular Femur Tibia Reconstruction Systems[®] (Howmedica, Rutherford, New Jersey, USA) were followed-up at 138 months, and a 40% failure rate when the Hospital for Special Surgery modular linked system[®] (Biomet Inc, Warsaw, Indiana, USA) was followed-up at 8.3 years.

Adequate primary stability and minimal micromotion (< 150 µm) are critical to the osteointegration of uncemented implants ([Unwin et al., 1993](#)). Bony ingrowth results in a stable and durable implant, with greater longevity and decreased risk of aseptic loosening. Without initial stability, excessive micromotion results in the formation of fibrous tissue, making the implant inherently unstable and vulnerable to future loosening ([Scharschmidt et al., 2011](#)). Biomechanical studies of press-fit stems cite rotational stresses as the primary obstacle to achieving effective initial stability ([Sugiyama et al., 1992](#)). A crucial factor in achieving adequate fixation of a press-fit

stem for distal femoral resections is fit of the stem both at the collar and at the proximal end of the stem ([Scharschmidt et al., 2011](#)).

The design of the uncemented stem greatly affects the stability of the DFR as reported in a biomechanical analysis by Scharschmidt et al ([Scharschmidt et al., 2011](#)), where a straight fluted stem was seen to provide the best initial resistance to rotational stresses.

In our series, the mean time to failure of the nine patients who had aseptic loosening was 29.7 months (13 to 76), possibly because of a poor fit resulting in failure of osteointegration. Our study showed that once biologically fixed, these stems did not fail. We also identified stress shielding, which was similar to that seen by Blunn et al([Blunn et al., 2000](#)), however this did not occur in all cases.

Results from our study showed that two factors significantly increased the rate of aseptic loosening and these were a femoral resection length of more than 46.5% and a TPL/ SL ratio of more than 1.43. This implies that uncemented stems should be long enough to fill the canal possibly to distribute the torsional stresses evenly. A similar finding was documented by Bergin et al([Bergin et al., 2012](#)) who suggested that large stems that fill the canal may have a mechanical advantage regardless of the method of fixation. In a review of uncemented press fit and Compress® (Biomet Inc, Warsaw,

Indiana, USA) DFRs, Farfalli et al ([Farfalli et al., 2009](#)) found that prosthetic–stem ratio (> 2.5) was highly sensitive and specific for predicting failure due to aseptic loosening.

Of the three implants that fractured in this study, two were extendible ‘growing’ endoprostheses implanted into nine and 13-year old patients. These implants fractured at 160 and 72 months (respectively) within the region of the growing telescopic component. It is possible that this is a zone of weakness in the design of this implant. The third implant that failed (at 104 months) was a non-growing DFR implanted into a patient who was 17 years of age and who led a highly active sporting lifestyle. The exact mechanism of implant fracture in each of these three cases is unknown, although a fatigue mechanism is probably likely.

As only 69 patients were included in this study, results obtained from both growing children and adults were combined. Younger patients are reported to have higher rates of aseptic loosening when compared with older patients ([Unwin et al., 1996b](#)). Our results of uncemented DFR revealed a higher aseptic loosening rate compared with the survivorship of cemented DFRs at up to 18 years’ follow-up ([Coathup et al., 2013b](#)). Our study indicates that cementless fixation of distal femoral bone tumour prostheses is not as successful as cemented fixation. However, the aseptically loosened uncemented prostheses reported in this paper occurred early and we suggest that this may be because of poor initial fixation due to inadequate press fit.

Many cemented distal femoral bone tumour prostheses with a hydroxyapatite-coated collar have been inserted into skeletally immature patients, who have a poor prognosis in terms of implant failure([Unwin et al., 1996b](#)). This may be related to the increase in the diameter of the intramedullary cavity as the patient grows([Blunn and Wait, 1991](#)). Bone growth into the hydroxyapatite-coated collar in these young patients may protect the fixation and prevent undue loading on the small-diameter intramedullary stems that were inserted when the patient was young.

This led me to study the use of HA-coated collars to enhance osteointegrated extra-cortical bone formation and improving long term survival of distal femoral endoprotheses in skeletally immature patients.

Chapter 4

Enhanced Fixation of Distal Femoral Replacements with Hydroxyapatite-Coated Collars In Skeletally Immature Patients

4.1 Introduction

Chapter 2 of this thesis looked at distal femoral replacements (DFRs) in non-adolescent patients with a HA-coated grooved collar which showed a high (70%) rate of ECB and osteointegration into the implant collar and a low (8%) rate of revision due to aseptic loosening.

To date, no studies have investigated the effect of osteointegration in patients who were skeletally immature at the time of their primary DFR. This cohort of patients may be more problematic than skeletally mature patients as their bone is still growing. A small stem is used at the time of implantation which may be undersized and unable to withstand the loads imposed on the implant by the time the patient reaches skeletal maturity. These considerations are important because the question remains as to the effectiveness of HA-coated collars in preventing aseptic loosening and intramedullary stem fracture in this cohort of patients.

The aim of this study was to quantify ECB in implants with a circumferential HA-coated ingrowth collar at the shoulder of distal femoral bone implants inserted into skeletally immature patients and to investigate if osteointegration at the shoulder of the implant prevented the development of radiolucent lines around the cemented interface as patients became skeletally mature.

Hypotheses: Extra-cortical bone growth onto the grooved HA (Hydroxy-apatite) collar prevents radiolucent line formation and aseptic loosening as these patients mature.

4.2 Patient and Methods

From 2001 to 2013, 70 paediatric limb salvage procedures involving reconstruction with an extendable, primary, cemented distal femoral endoprosthesis with a HA-coated ingrowth collar were performed at the Royal National Orthopaedic Hospital (RNOH) in Stanmore, United Kingdom. The inclusion criteria for this study were:

1. The patient was aged between 5 and 15 years at the time of operation.
2. The patient was implanted with a primary DFR with HA collar and cemented femoral component
3. A minimum of 3 years of radiographic follow up was required at the time of data collection.

Out of the 70 patients, 24 met the inclusion criteria for this study. The remaining 46 either had passed away within three years (19), had revision surgery within 3 years (7), had insufficient radiographic follow up (7), were inserted with an implant fixed using an extra-cortical plate (6), underwent non-HA coated primary DFR (3), were fixed using an uncemented intramedullary stem (3) or had developed chronic infection leading to amputation (1).

Table 4.1: Reasons for the 7 revision surgeries < 3 years post-op

1. Fractured Implant
2. Revision to accommodate further lengthening
3. Revised to a distal femoral non-invasive grower
4. Periprosthetic fracture
5. Aseptic Loosening after one year following primary implantation.
6. Implanted in 2009 and revised in 2011. Reason could not be found.
7. Revised within three years to an implant with an extra-cortical plate.

This study investigated osteointegration of the HA grooved ingrowth collar in 24 patients (10 female and 14 male) who had received a primary cemented distal femoral endoprosthesis for the treatment of bone cancer. All patients were aged between 8 and 15 years at the time of operation with a minimum of three years radiographic follow-up. The mean age of the patients at the time of operation was 12.21 years (Standard Deviation (SD) \pm 2.536, range, 8 – 15 years). Segmental replacement in the left limb was carried out in 11 patients (5 female and 6 male) and in the right limb in 13 patients (5 female and 8 male). The primary diagnosis in 22 patients was Osteosarcoma (9 female and 13 male), one Ewing's Sarcoma (male) and one Giant Cell tumour (female).

The prostheses used were the same that were used in chapter 2. Surgery was performed with the patient supine. A longitudinal incision that excised the biopsy tract

and deepened into a medial parapatellar approach to the knee was used. Surgical resection of the periarticular tumour involved the joint, metaphysis, and a part of the diaphysis. Third-generation cephalosporins were administered intraoperatively and one to seven days postoperatively. When appropriate, patients received neoadjuvant chemotherapy, and all met the criteria for limb salvage. Chemotherapy was given postoperatively, and partial weight-bearing was allowed for the first six weeks after surgery, after which the patients slowly progressed to full weight-bearing. After six weeks, the patients returned for a period of intensive physiotherapy.

4.2.1 Radiographic Analysis

The osteointegration of extra-cortical bone ingrowth to the HA collar and degree of bone loss at the bone-implant junction was radiographically scored. Radiographic analysis was performed by one observer and measurements (mm \pm SD) were made from antero-posterior (AP) and medio-lateral (ML) radiographs taken from each patient at a minimum of 6 months following primary implantation and at yearly intervals throughout their follow-up. The mean duration of follow-up was 77.2 months (SD \pm 33.67, range, 36 – 139 months). The number of radiographs analysed for each patient varied according to length of follow-up; however a mean of 5.25 (range, 1 to 9) radiographs were analysed per patient in the study. In total 123 radiographs were measured. Each of the radiographs was used to quantify: (1) the degree of extra-cortical osteointegration into the HA ingrowth collar; (2) the presence of radiolucent

lines around the cemented femoral stem fixation (3) the degree of bone loss immediately beneath the implant shaft at the bone-shoulder implant junction.

4.2.1.1 Osteointegration Score

Extra-cortical bone ingrowth into the HA grooved collar was quantified using the same scoring system that was used in chapter 2. Integration was quantified radiographically where the collar was divided into four equal zones (the medial and lateral aspect on AP radiographs and the anterior and posterior aspects on ML radiographs). Extra-cortical bone in contact with the grooved implant surface in any of the four zones was assigned a score of 1. Therefore the maximal score per radiograph was 4 and represented extra-cortical bone in all four zones). A score of 0 was assigned in cases where the extra-cortical bone was separated from the implant surface by a clear radiolucent line (non-integrated).

The degree of radiographic osteointegration within the HA collar was classified into 2 groups: osteointegration and no osteointegration. A score of 0 was classified as 'no osteointegration' and a score of ≥ 1 as 'Osteointegration'. The degree of osteointegration was analysed using the latest follow-up radiograph available for each of the 24 patients.

4.2.1.2 Radiolucent Line Score

Before analysis, radiographs were calibrated by measuring the known length of the femoral intramedullary stem on the radiograph, thereby producing a magnification factor. The calculation of the RLL score at the cement-bone interface adjacent to the intramedullary stem was quantified using a previously described scoring system by Coathup et al([Coathup et al., 2015](#)). The same AP and ML radiographs that were used to measure bony ingrowth into the HA collar were used. The medial and lateral aspects from the AP radiograph and the anterior and posterior aspects from the ML radiograph adjacent to the intramedullary stem were divided into six equidistant zones. A score of 1 was allocated to a radiolucent line observed in each zone. A maximum score of 12 could be obtained from each radiograph therefore producing a total radiolucent line score of 24. A score of 0 indicated that no radiolucent lines could be detected.

Identification of radiolucent lines in these growing patients was different from the appearance associated with a remodelling cortical bone. Radiolucent lines were thinner and more well-defined and progressed along the cement bone interface over

time compared with the lucent areas associated with an expanding endosteal cavity where on radiographs, these regions were more defuse and became wider over time.

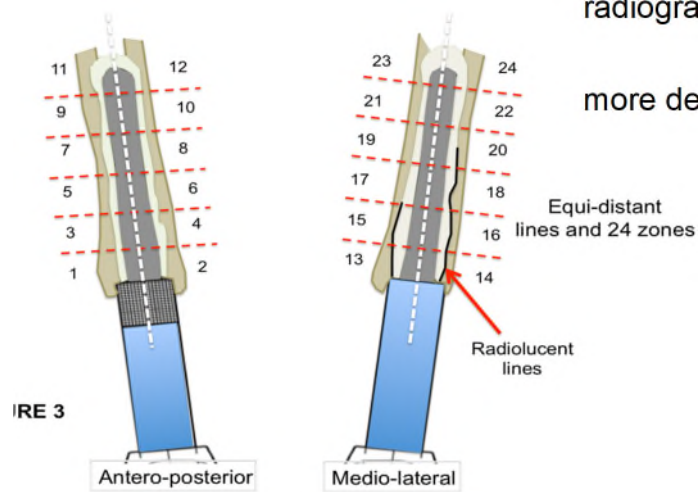


Fig 4.1 Schematic Diagram of the radiolucent lines zones on AP and Lateral views

4.2.1.3 Cortical Bone Loss at the Bone-shoulder Implant Junction

The distance separating bone from the shoulder of the implant at the transection site was measured on both AP and ML radiographs and a measurement calculated for the follow-up period for each of the 24 patients.

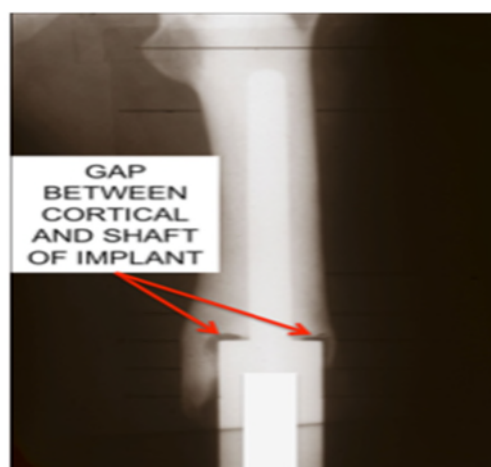

Fig 4.2 Cortical bone loss measured adjacent to the bone-implant junction

4.2.2 Statistical Analysis

The radiolucent line score, skeletal growth ratio and bone loss at the transaction site was compared between groups and the data analysed using SPSS-16 (Chicago IL, USA). A Mann-Whitney U test was applied to compare the distribution of skeletal growth ratio, bone loss at transaction site, and RLL score between the two groups. The Pearson's Correlation Coefficient was used to plot OI score against RLL score. The summarised data is presented as mean \pm SD and Median (inter-quartile range).

A box-whisker plot was created to display the median values between the groups. The box represents the inter-quartile value, where the lower line of the box is the 25th percentile and upper line represents the 75th percentile. The middle line is the 50th percentile range (25th to 75th), roughly indicating variation within the group. More length represents more variation. The graphs explain the symmetry of distribution and a rough method to test the Gaussian pattern of each group. If the median lies between the box and whiskers are at approximate equal length from the lower and upper box, it indicates symmetric distribution. The graphs also show outliers, if present. An outlier is a subject value that behaves differently when compared to other sample values and can distort the mean value. If an individual value is more than 1.5 of the box length value from the upper and lower end of the box, this value is considered as an outlier.

Institutional review board approval was granted by Royal National Orthopaedic Hospital for this study.

4.3 Results

Of the 24 patients in the study, 13 (54.2%) patients had radiographic evidence of osteointegration (a score of 1 or more) and 11 (45.8%) patients showed no evidence of osteointegration (a score of 0) on the final follow-up radiographs.

4.3.1 Radiolucent Line Score

The radiolucent line score observed in patients with osteointegration (mean, 3.93 ± 4.60 ; median, 3.0; range, 0.0–7.0) was lower compared to patients with no osteointegration (mean, 10.8 ± 6.22 ; median, 11.5; range, 4.0-16.0) and statistically significant with a p-value of 0.007.

The Box-Whisker Plot showed that the median value of the radiolucent line score was higher in the group of patients with no osteointegration compared to the group with osteointegration. Variation within the osteointegration group was less compared to the group with no osteointegration. The radiolucent line score in the group with no osteointegration of the collar was slightly above the mid value of the box while in the osteointegration group, it was seen to be in the middle, which showed that the data was approximately normal. No outliers were seen (Figure 4.3).

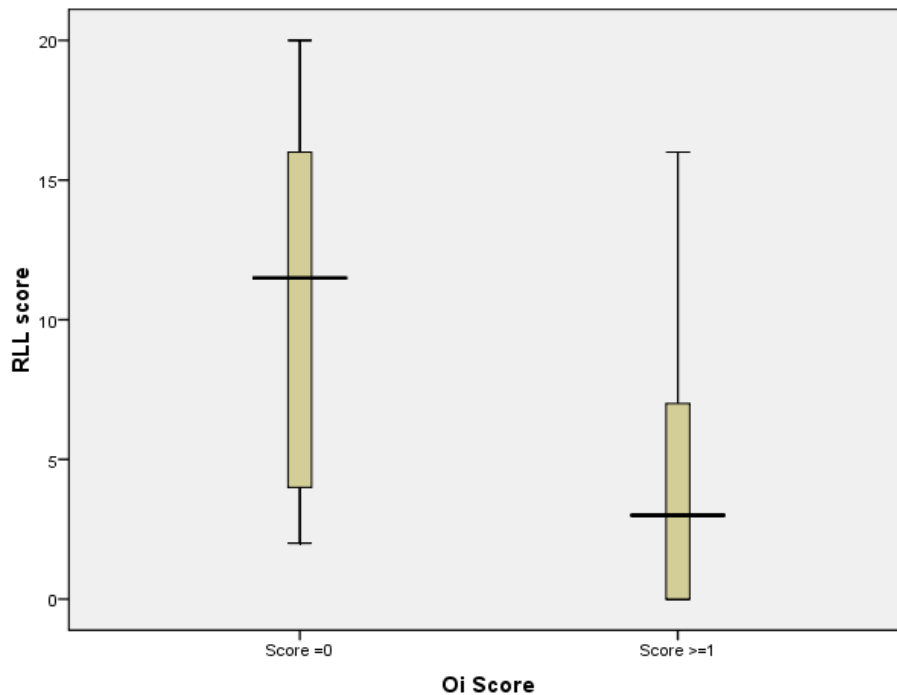


Fig 4.3 Radiolucent Line Score for the Osteointegrated and Non-Osteointegrated Groups

4.3.2 Bone Loss at Transection Site

The cortical bone loss observed in patients with osteointegration (mean, 0.40 mm \pm 0.73; median, 0.03; range, 0.0-0.58) was lower compared to those individuals without evidence of osteointegration (mean, 1.76 mm \pm 1.36; median, 1.13; range, 0.90-2.44) and this difference was statistically significant with a p-value of <0.001.

The Box-Whisker plot showed that the median value of bone loss was higher in the group with no evidence of osteointegration compared to the group with osteointegration. Bone loss in both groups was below the mid value of the box

indicating that both groups departed from 'normal'. Outliers were present in both groups (Figure 4.4).

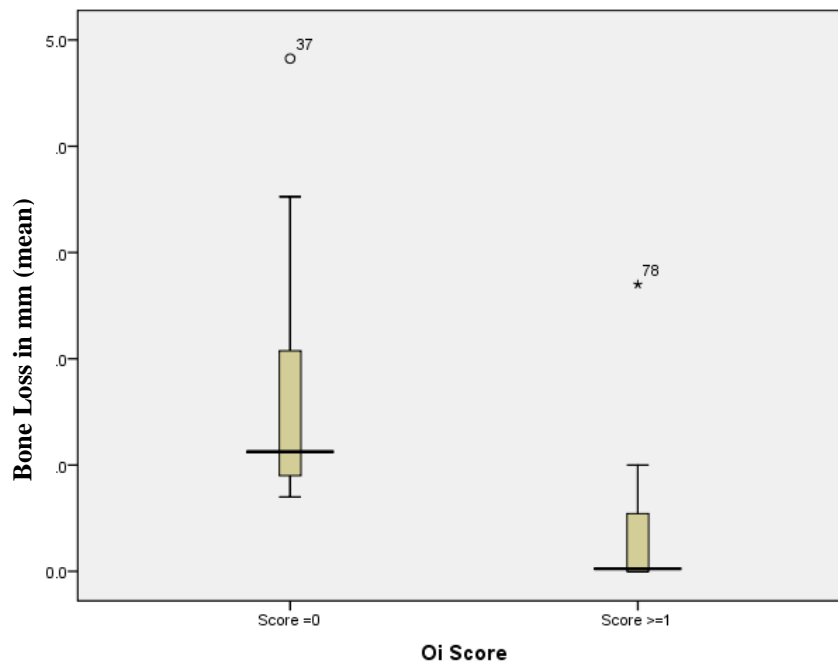


Fig 4.4 Bone Loss at the transection site in the osteointegrated and non-osteointegrated groups

A total of 123 radiographs were analysed and the osteointegration score and radiolucent line score was calculated for each one. A Pearson Correlation Score that investigated the relationship between the osteointegration score and radiolucent line score gave a coefficient of -0.252 ($p=0.005$) showing that a correlation exists where a higher osteointegration score resulted in a lower radiolucent line score (Table 4.1).

Table 4.2: Correlation of Extra-cortical Bone Formation and Radiolucent Line Score

	OI Score	RLL Score
OI Score	Pearson Correlation	1
	Sig. (2-tailed)	-.252**
	N	.005
RLL Score	Pearson Correlation	1
	Sig. (2-tailed)	-.252**
	N	.005
	123	123

** . Correlation is significant at the 0.01 level (2-tailed)

4.4 Discussion

A major cause of distal femoral prosthesis failure is aseptic loosening of the intramedullary stem. The only identifiable risk factors reported in the literature are age, bone resection length, and time of follow-up which is largely predetermined by oncologic requirements([Unwin et al., 1996a](#), [Tyler et al., 2009](#)). Tumours of the distal femur are more commonly found in the younger population and the patients who survive their disease often lead very active lives with near normal life expectancy. This

coupled with the mechanical limitation of anchoring a stem into a cylindrical medullary canal has been discussed as a possible element leading to aseptic loosening([Turcotte et al., 2017](#)).

Osteointegration of extra-cortical bone onto the shaft of the implant may be associated with a more advantageous biomechanical environment and improved stem fixation particularly in skeletally immature patients where the implant is inserted into growing bone([Batta et al., 2014](#), [Ward et al., 1997](#)). Due to the small size of the bone at the time of implantation, the implant becomes undersized as the patient grows and the increase in the diameter of the endosteal cavity may lead to a loose implant. The loading force on the stem will increase as the patient grows, which the small stem may be unable to withstand and may result in fracture([Fromme et al., 2017](#)).

Although osteointegration was seen in only 13 patients (54.2%), there was statistical significance when correlated to RLL formation and cortical bone loss at the transection site. Values for both RLL formation and bone loss were lower in the osteointegrated group compared to the non-osteointegrated group.

A number of animal and clinical studies have demonstrated that ECB bridging occurs at the shoulder of massive bone tumour implants([Chao and Sim, 1990a](#), [Heck et al., 1986a](#), [Heck et al., 1986b](#), [Kuo et al., 1983b](#), [Okada et al., 1988a](#), [Ward et al., 1993a](#)).

However, bone ingrowth with direct ECB-implant contact in bone tumour implants

retrieved from humans has only been identified in one study([Coathup et al., 2013a](#)).

Coathup et al. discovered that survival at ten years increased by more than 20% when osteointegration occurred onto the shaft of the prosthesis. Results also showed the probability of implant survival without revision for any reason at a mean of 8.5 years post-operatively, was 88.5% and the risk of aseptic loosening was 6% at five years and 11% at ten years. Radiographic evidence of osteointegration of the collar was found in 70% of patients over a two to eighteen- year follow-up and histological analysis of four implants confirmed osseous ingrowth within the grooved collar with direct ECB-implant contact. In these patients the success was 98% at 18 years, however, in patients where osteointegration did not occur, the failure rate was 25%. Histological analysis demonstrated that direct bone contact with the surface of the implant could be observed when a grooved HA-coated collar was used. However, when no HA-coated collar was present, ECB formed at the shoulder did not osteointegrate but was separated from the surface of the implant by a layer of fibrous tissue([Coathup et al., 2013a](#)).

Heck et al radiographically analysed that bone bridging occurring over the shoulder and conical coupling joint sections greatly improved the stability of the implants due to extra-cortical fixation. This further assures the long-term performance of the conical coupling used in the present modular prosthetic system([Heck et al., 1986a](#)). Similar findings were reported histologically by Okada et al. who suggested that ECB bridging

and ingrowth were found to be effective in achieving secure fixation of both titanium fibermesh-coated and cobalt-chromium-molybdenum bead-coated modular prostheses implanted in dogs followed-up for 12 weeks([Okada et al., 1988a](#)).

Turcotte et al evaluated radiographs for signs of aseptic loosening and osteolysis. They identified the stem size/reamer diameter ratio leading to a somewhat stable three-point configuration of the implant with an additional thin cement mantle enhancing fixation([Turcotte et al., 2017](#)). Bergin et al and Skinner et al also supported this concept as they reported a lower incidence of aseptic loosening when a high bone-to-stem diameter ratio was present([Bergin et al., 2012](#), [Skinner et al., 2003](#)).

An additional problem associated with intramedullary cement fixation in skeletally immature patients is that the femur and the medullary cavity increase in girth as the patient grows. Fractures and cortical drifting can occur as the bone of these patients is constantly growing. My study did not include patients with fracture but in a study by Neel et al, three of 15 patients (20%) implanted with non invasive expandable endoprotheses had fracture([Neel et al., 2003](#)). Blunn and Wait in their study on remodelling of bone around Intramedullary stems in growing patients reported that the bone at the transaction site had resorbed, resulting in bone below the shoulder of the prosthesis becoming less dense because of stress protection([Blunn and Wait, 1991](#)).

Our study showed a survival rate of 90.6% at a follow-up of 46 months which is comparable to studies conducted by Futani et al([Futani et al., 2006](#)) and Schinhan et al([Schinhan et al., 2015](#)) who reported a cumulative ten-year survival rate of 82% and 83% respectively in children after limb-salvage surgery of the femur.

This study had a few limitations. It was a retrospective analysis whereby patient variation in height, weight, activity level, and dose of chemotherapy were not accounted for. Furthermore, the sample size included was small. Studies on massive bone tumour implants are scarce and challenging due to the relatively low number of patients treated using a distal femoral replacement. Further variations were minimized as all implants were of a similar design and manufactured by one manufacturer. All patients were treated at a single institution performing the same surgical techniques and providing consistent patient care.

From the results obtained in this chapter, I can conclude that a grooved HA-coated ingrowth collar located at the shoulder of cemented distal femoral massive prostheses resulted in increased osteointegration of extra-cortical bone leading to a reduction in the number of progressive RLL adjacent to the intramedullary cemented stem in skeletally immature patients. I can also conclude that the use of a HA-coated collar led to decreased cortical bone loss adjacent to the transection site. These results suggest that possibly as a result of load transfer from the shoulder to the cortical bone surrounding the IM stem, the HA collar may help reduce the risk of aseptic loosening.

More prospective studies are required with larger numbers of patients and longer follow-ups to determine if our preliminary observations relate to increase longevity and reduced revision rates for loosening in implants with a HA collar in skeletally immature patients.

Chapter 5

Discussion

Over time the treatment of bone sarcomas has evolved in terms of both medical and surgical management. Limb salvage surgeries have changed patients' quality of life enabling them to recover function quickly, boosting their self-confidence and increasing their chance of leading a normal life.

Both uncemented and cemented fixation of prosthesis to bone have been tested and used over the years. The ultimate aim of these prostheses is to obtain osteointegration with the surrounding bone and ensure there is no hindrance to optimum function of the limb. The most common reason for failure of massive prostheses is still aseptic loosening. Numerous authors have studied the reasons for aseptic loosening (ASL) and ways of enhancing implant fixation to bone. Formation of extra-cortical bridging and osteointegration of implant to bone using hydroxyapatite collars, leading to decreased aseptic loosening is one of the most recent innovations aimed at improving fixation of these implants. This has been the focus of my research and in this thesis I present evidence that HA collars can enhance osteointegration of extra-cortical bone for distal femoral replacements, improving fixation and survivorship of these implants. Our institution has over the years conducted and published numerous studies on DFRs and their fixation methods to bone. It was thus feasible to quantify these long term results, leading me to write my thesis on this subject.

I performed three studies to evaluate the degree of osteointegration of DFRs and assessed its relationship with aseptic loosening. The first study was the evaluation of cemented HA collared prosthesis in 61 adults over nine years. In the second study, I investigated uncemented, custom-made, hydroxyapatite-coated collared distal femoral endoprotheses in 69 patients over 12 years with an average follow-up period of 124.2 months. In the third study, Osteointegration of Extendable Distal Femoral

Replacements with a Hydroxyapatite Coated collar in skeletally immature group was investigated in 24 patients with an average follow-up period of 77.2 months. Finally the third study, in skeletally immature patients, investigated whether the use of hydroxyapatite collars in adolescent patients enabled the prostheses to remain in place into adulthood.

The aim of the thesis was to 1) To evaluate the long-term survival of cemented and uncemented distal femoral bone tumour endoprostheses in adults and skeletally immature patients and 2) To investigate the relationship between the degree of osteointegration onto the hydroxyapatite (HA) coated collar located at the bone-implant junction and aseptic loosening (ASL) of these endoprostheses.

Numerous authors have successfully used HA collars both *in vivo* and *in vitro* ([Capello et al., 2006](#), [Hayashi et al., 1991](#), [Soballe, 1993](#), [Bloebaum et al., 1991](#), [Gupta et al., 2006b](#)). Gupta et al used an HA coated knee-sparing distal femoral endoprosthesis in young patients with malignant bone tumours of the distal femur in whom it was possible to resect the tumour and to preserve the distal femoral condyles. They reported that there was excellent osteointegration at the prosthesis bone interface with formation of new bone around the hydroxyapatite collar and that the prosthesis allowed preservation of the knee, achieving good functional result ([Gupta et al., 2006b](#)). Similar results have been published by Capello et al ([Capello et al., 2006](#)) and Soballe et al ([Soballe, 1993](#)).

Extra-cortical bone bridging and ingrowth achieved due to HA coatings have been shown, by finite element analysis, to reduce the stresses on the stem and the cement mantle of a tumour endoprosthesis([Chao and Sim, 1990a](#)). It has been suggested that this transmission of forces to the cortical bone-implant junction and the resultant reduction of forces at the stem-cement interface can provide substantial improvements in long-term implant fixation to bone([Chao and Sim, 1992](#)).

A number of animal and clinical studies have demonstrated ECB bridging occurring at the shoulder of massive bone tumour implants([Chao and Sim, 1990a](#), [Heck et al., 1986a](#), [Heck et al., 1986b](#), [Kuo et al., 1983b](#), [Okada et al., 1988a](#), [Ward et al., 1993a](#)). However, bone ingrowth with direct ECB-implant contact (osteointegration of the newly formed bone) in bone tumour implants retrieved from humans has only been identified in the study reported in this thesis([Coathup et al., 2013a](#)).

Our observation of cemented DFRs as reported in chapter 2 of the thesis was carried out to evaluate osteointegration of implant to bone and we concluded that when bone is osseointegrated onto the shaft of the prosthesis, survival at ten years increases by more than 20%. The results also showed that the probability of these implants surviving without revision for any reason for a mean of 8.5 years was 88.5% and the risk of aseptic loosening was 6% at five years and 11% at ten years. The study also demonstrated radiographic evidence of osteointegration of the collar in 70% of patients over a two to eighteen-year follow-up period and histological analysis of four implants

confirmed osseous ingrowth within the grooved collar with direct bone-implant contact. In these patients the success was 98% at 18 years, however, in patients where osseointegration did not occur, the failure rate was 25%. Histological analysis showed that when a grooved hydroxyapatite-coated structure was used, direct bone contact with the surface of the implant was seen, whereas in cases where no collar was present, the extra-cortical bone that formed at the shoulder did not osteointegrate but was instead separated from the surface of the implant by a layer of fibrous tissue, confirming osseointegration with direct contact between the extra-cortical bone and the shoulder of massive bone tumour endoprostheses in patients([Coathup et al., 2013a](#)).

Chao et al([Chao et al., 2004b](#)) and Shin et al([Shin et al., 2000](#)) in their studies have also shown that the use of the extra-cortical bone-bridging and ingrowth fixation technique is associated with improved implant fixation and reduced loosening.

However, Tanzer et al, 2003 reported that, although radiographic investigation suggested ingrowth at the collar of porous-coated implants in patients, histological analysis revealed no osteointegration and that only fibrous tissue was present within the porous coating([Tanzer et al., 2003](#)).

In chapter 3 of this thesis I reviewed uncemented, custom-made, distal femoral endoprosthetic replacements performed in 69 patients between 1994 and 2006. The

results suggested that custom-made uncemented distal femur replacements had a higher rate of aseptic loosening compared to published results when used with cemented fixation. Thus study also suggested that loosening of uncemented replacements occurs early indicating that initial fixation of the implant is crucial([Batta et al., 2014](#)).

Bradish et al ([Bradish et al., 1987](#)) and Roberts et al ([Roberts et al., 1991](#)) also reported low rates of revisions due to aseptic loosening (0% and 6% respectively) in their 16 year follow-up studies of cemented endoprotheses. For the HA coated cementless version the short-term results of 47 reconstructions reported only one case of aseptic loosening after a mean follow-up of 15 years (10 to 35) ([Jeys et al., 2008](#)).

Turcote et al in their study on radiographic assessment of distal femoral endoprotheses concluded that cementing distal femur prosthesis with a tight canal fit and with a thin cement mantle appears to be a viable option at short and medium term([Turcotte et al., 2017](#)). This concept is also supported by Bergin et al([Bergin et al., 2012](#)) and Skinner et al([Skinner et al., 2003](#)), who demonstrate lower incidence of aseptic loosening when a high bone-to-stem diameter ratio was present in their studies.

Adequate primary stability and minimal micromotion (< 150 µm) are critical to the osteointegration of uncemented implants ([Unwin et al., 1993](#)). Bony ingrowth results

in a stable and durable implant, with greater longevity and decreased risk of aseptic loosening. Without initial stability, excessive micromotion results in the formation of fibrous tissue, making the implant inherently unstable and vulnerable to future loosening ([Scharschmidt et al., 2011](#)).

Comparison of the results of cemented and cementless fixation of a DFR are confounded because of differences in implant design, the use of chemotherapy and local radio-therapy, the amount of bone and soft-tissue resected and fixation concepts([Kinkel et al., 2010a](#)). Proponents of uncemented DFR like Kinkel et al ([Kinkel et al., 2010b](#)) have reported an aseptic loosening rate of 25% in cemented *versus* 9% in uncemented using the Modular Universal Tumour And Revision System[®] (MUTARS) (Implant cast, Buxtehude, Germany) DFR at a mean follow-up of 46 months (3 to 128). In contrast, Bickels et al ([Bickels et al., 2002](#)) favoured cemented prostheses and reported survival rates of 88% for 110 cemented DFRs inclusive of custom, modular and expandable implants at a median follow-up of 7.8 years (two to 16.5).

Postoperative radiographs to monitor the reactions around implants are usually taken at intervals from the day of implantation of the prosthesis and continuing as long as the surgeon feels it necessary to do so from a clinical point of view. The purpose of the radiographic examination is not only done to diagnose lack of osteointegration, but

is also used to assess the status of the bone and to monitor for bone absorption or implant subsidence indicating loosening([Pala et al., 2013b](#)).

Osteointegration scoring systems developed on radiograph examinations have also been used by numerous authors to assess the level of osteointegration between bone and implant in fields of dentistry([Nasr and Meffert, 1993](#)), wrist joint surgeries([Möller et al., 2004](#)), hip arthroplasty([Engh et al., 1990a](#), [Moore et al., 2006](#), [Roche et al., 2016](#)) and knee surgeries([Coathup et al., 2013a](#)).

In 2013 I introduced objective scoring to quantify the degree of extra cortical bone formation to assess formation of extra-cortical bone bridging around HA collar of cemented distal femoral prosthesis. The score was assessed radiographically by measuring the thickness of new bone formed. Extra-cortical bone that was separated from the implant by a clear radiolucent line was considered not in-grown, and was assigned a score of 0. A score of 1 represented extra-cortical bone (>5mm thick and >1mm long) in contact with the implant surface in any one of the four (anteroposterior and mediolateral) zones. The maximal score was 4, which represented extra-cortical bone growth in all four zones. I was successfully able to measure that at the five-year follow-up interval, only two out of the fifteen patients scored 0 and thirteen of the collars had osteointegrated([Coathup et al., 2013a](#)).

The final experimental study of my thesis was a radiographic assessment of the osteointegration of extendable distal femoral replacements with a Hydroxyapatite Coated collar in 24 skeletally immature patients at an average follow up period of 77.2 months. Radiographs of patients were measured for osteointegration scores whereby the scoring system was adapted from our previous study([Coathup et al., 2013a](#)) and Radiolucent Line Scoring (RLL) which was adapted from a study conducted by Coathup et al([Coathup et al., 2015](#)) at our institution. Results showed a reduced RLL score and extra-cortical bone loss when there was increased osteointegration of the ECB leading to a reduction in the number of RLL adjacent to the intramedullary cemented stem. In this study the use of a HA-coated collar led to decreased cortical bone loss adjacent to the transection site.

Previously, Osteointegration was assessed by radiographically measuring the length and width of resorption zones around the titanium fixtures by Moller et al on the wrist joint([Möller et al., 2004](#)) . Based on these measurements the osteointegration of each fixture was assigned a score from 0 to 3; where 0 indicated minimal or no change, 1 indicated slight bone resorption under the joint connection, extending along less than half of the implant length, 2 indicated moderate bone resorption with a narrow resorption zone extending more than half of the implant length or a wide irregular resorption zone extending at least half of the implant length and 3 indicated obvious implant loosening, either with a wide irregular resorption zone extending around the

implant with or without implant subsidence or any implant subsidence of more than 1 mm on comparable radiographs with or without a narrow resorption zone around it ([Möller et al., 2004](#)). Their results confirmed that radiographs were an effective method of measuring osteointegration between bone and implant and they also help in detecting implant instability and loosening.

Radiolucent line scoring has been reported by a few authors as a radiographic outcome measure of implant to bone fixation. The absence of progressive lines around the porous surface portion of the implant and the presence of new bone bridging the gap between the endosteal surface and the porous portion of the implant in a radiograph indicates osteointegration, while the progressive implant migration is a major sign of implant instability. In most cases, the presence of one of these signs is suggestive of failed osteointegration and thus allows the prediction of fixation and stability of the implant ([Engh et al., 1990b](#)).

We have so far not used Radiostereometric Analysis (RSA) in the evaluation of the stability of endoprosthesis. Since the HA collar is much bigger in diameter than the femoral medullary canal, it cannot, therefore, practically subside into the canal. But in future we may evaluate loosening of the endoprostheses by using RSA.

We reported in a study done in our institution by Coathup et al ([Coathup et al., 2015](#)) that a grooved HA-coated ingrowth collar located at the shoulder of cemented distal

femoral massive prostheses results in increased osteointegration of extra-cortical bone leading to a reduction in the number of progressive radiolucent lines adjacent to the intramedullary cemented stem. We also showed that the use of a HA collar led to decreased cortical bone loss adjacent to the transaction site. We did this by examining twenty-two patients that were pair-matched to one of two groups; either implants with a HA-coated ingrowth collar (HA Collar Group) or implants without an ingrowth collar (Non-collar Group) and analysed the radiographs obtained throughout the follow up period, quantifying the osteointegration at the shaft of the implant. Radiolucent line progression around the cemented stem was semi-quantitatively assessed and cortical bone loss at the bone-shoulder implant junction was measured during the follow up period. Results showed that during the mean 7-year follow-up period, nine of the 11 HA collars were osteointegrated, whereas only one patient in the Non-collar Group showed contact of the bone with the implant surface and a radiolucent line between the extra-cortical bone and the shaft of the implant in the Non-collar group was clearly evident in all cases except one. The radiolucent line score increased with time in the non-collar group indicating progression toward loosening of the stem, while none of the implants in the HA Collar group had progressive radiolucent lines develop. Since an increase in the progression of radiolucent lines during the follow-up period may suggest the implant is gradually becoming aseptically loose, a grooved HA-coated ingrowth collar located at the shoulder of cemented distal femoral massive prostheses

can result in increased osteointegration of extra-cortical bone leading to a reduction in the number of progressive radiolucent lines adjacent to the intramedullary cemented stem([Coathup et al., 2015](#)). Similar studies were conducted by Ward et al and Turcotte et al who evaluated aseptic loosening and signs of osteolysis([Ward et al., 1997](#)) ([Turcotte et al., 2017](#)).

After completion of all the studies, we concluded that a grooved HA-coated ingrowth collar located at the shoulder of cemented distal femoral massive prostheses in both adult and skeletally immature patients resulted in increased osteointegration of extra-cortical bone and that the use of a HA-coated collar led to decreased cortical bone loss adjacent to the transection site. These results suggest that possibly as a result of load transfer from the shoulder to the cortical bone surrounding the IM stem, the HA collar may help reduce the risk of aseptic loosening.

HA collar is in the simplest form an example of tissue engineering scaffold which is defined as a material that has been engineered to cause desirable cellular interactions to contribute to the formation of new functional tissues for medical purposes. In all the three chapters we have investigated the role of grooved HA collars but we cannot be certain, whether it is the grooved collars or the HA that enhances osteointegration. Studies have shown that 90⁰ angled shapes promote bone deposition independent of the coating applied. There are some studies that looked at the macro topography and

shown that bone cells respond solely to shape irrespective of implant chemistry. Pore shape and size alone can induce bone formation in non bony sites.

5.1 Current Concepts in DFR

Three-dimensional (3D) scaffolds are a key requirement of scaffold-based bone tissue engineering because scaffolds can mimic the structure and function of the extracellular matrix and support cell adhesion, proliferation, differentiation, and tissue regeneration([Xia et al., 2013](#)).

Recent research strongly suggests that the choice of scaffold material and its internal porous architecture significantly influences the type of tissue that regenerates, tissue structure, and function. In addition to possessing the appropriate material composition and internal pore architecture for regenerating a specific target tissue, scaffolds must also have mechanical properties appropriate to support the newly formed tissue. In the case of bone, failure to provide adequate mechanical load-bearing function will cause a loss of function as the scaffold defines the ultimate shape of the new bone([Eshraghi and Das, 2010](#)).

Rapid prototyping (RP) has attracted a great deal of attention because it allows the user to precisely control and to construct complex geometrical scaffolds with intricate internal and external architectures. Selective laser sintering (SLS) is one type of RP technology where complex structures are formed from metallic alloy powders ([Ryan](#)

[et al., 2006](#)). As a follow on from my project, the use of a porous collar made using SLS and titanium alloy collar has been investigated in an animal model and been shown to be effective in terms of bone ingrowth and extra cortical osteointegration ([Mumith et al., 2017](#)). In fact this has been further developed into a human implant (Fig 5.1 A, B, C) which at the time of writing is about to be tested in a human clinical trial.



Fig 5.1 A- Proximal femoral implant B- Implant porous shoulder C- Porous Collar

Another of the studies on HA collars has investigated the concept of spraying autologous bone marrow-derived mesenchymal stromal cells (MSCs) within a fibrin glue carrier onto the HA collar in an ovine bone tumour model. Results showed significantly increased extra-cortical bone growth adjacent to the implant with increased bone-implant contact when compared with the fibrin only group. However due to the risk of MSCs from cancer patients being neoplastic then allogeneic MSCs must be sourced ([Kalia et al., 2006](#)).

In a recent study we investigated the hypothesis that allogeneic MSCs and osteoprogenitor cells (OPCs) will augment bone growth equally when compared with autologous BMSCs. The results were not significant and we concluded that spraying bone marrow-derived autologous stromal cells or OPCs onto the HA-coated ingrowth collars could be used in patients; however, further work is needed to determine the role of allogeneic cells in bone augmentation in vivo in order to eliminate the risks associated with autogenic transplantation in cancer patients([Coathup et al., 2013c](#)).

At the moment use of culture expanded stem cells would be regarded as an advanced therapy medicinal product (ATPM) and more severe regulatory classification would apply. However in none neoplastic patients requiring a massive segmental replacements, in revision for example, it may be possible to enhance bone formation using autologous stem cells from bone marrow aspirate obtained at the time of surgery .

5.2 Non invasive techniques of assessing implant stability

Recently, two non-invasive techniques, bone scintigraphy and resonance frequency analysis (RFA), have been used in clinical and animal studies to assess the status of implants in dentistry. These non-destructive methods have many advantages including no invasion to the subject allowing for multiple within-subject comparisons, no need to sacrifice animals, and no influence on the following histological analysis.

However, insufficient data is available on their roles in osteointegration evaluation([Zhou et al., 2008](#)).

RFA is an extensively used method in clinical researches to monitor implant stability([Aparicio et al., 2006](#)). The application of RFA is based on the perspective that increasing bone anchorage of an implant would alter RFA value because of changes in the stiffness of bone–implant interface([Meredith et al., 1997](#)). RFA uses a piezoelectric transducer, which emits a sinusoidal signal within a specific frequency meant to make the implant vibrate. The device measures implant resistance to vibration and transforms into an ISQ value (implant stability quotient - ranges from 1 to 100, with higher values indicating greater stability)([Meredith, 1998](#), [Herrero-Climent et al., 2013](#)).

This implant stability measuring technique is being extensively used in dentistry, however, according to the authors knowledge, no attempt has been done to replicate its usage for orthopaedic implants. We would however very likely start using RFA in our bone tumour patients to assess the stability and strength of osteointegration of endoprostheses. It would give valuable additional information apart from the radiographic score of osteointegration.

5.3 Scope for future studies

Distal femoral replacements after tumour resection are widely being used with their modifications and enhancements being developed, studied, experimented and utilised so that patients can have a better quality of life.

However, more studies are required to be conducted on the ideal fixation method of the implant to bone, the most effective coating on the implant, mode of depositing the coating on the implant, measures to check for implant stability and use of allogenic cells to augment bone growth.

A group of patients which I have not investigated but where the use of a HA collar may be advantages is for revision procedures. Segmental replacements are used following failure of more standard hip and knee replacements as well as revision of bone tumour implants. Revision implants are not generally as successful as prostheses used in primary cases. The use of a HA collar in these situations may be beneficial.

Development of the ideal endoprosthesis and means of implantation will be a breakthrough in orthopaedic surgery and increased chances of survival of both young and old patients.

Chapter 6

Appendix

NHS R&D Response to Enquiry

To: Dr Melanie Coathup

From: Iva Hauptmannova

Date: 20.09.12

Project Title: Histological sub-study

Dear Dr Coathup,

In relation to your enquiry dealing with samples collected in early 1990s and subsequently used as part of your review, I can confirm the following based on the information provided:

- The samples and implants were obtained prior to the current legislation coming into effect, and as such would have been incorporated into our samples audit, which was conducted locally prior to the legislation.
- Any such samples obtained prior to 2004 would have been primarily obtained for diagnostic purposes, and would not have been subject to the same procedures as we would expect today. All such samples have been incorporated under our existing Biobank approval (ref. 09/H0304/78), and you it would be within the legal framework for you to utilise these.

As such I can confirm that the samples have been used within the legal framework within the project, which you described.

Yours sincerely,

[REDACTED]
Iva Hauptmannova
R&D Manager

NHS R&D Management Confirmation of Notification of Service Evaluation

To: Vineet Batta (cc Prof. Gordon Blunn, clinical lead Prof. T. Briggs)
From: Iva Hauptmannova (R&D Manager)
Date: 22nd of December 2010

Project Title: Evaluation of Long term clinical, radiological and histopathological results of HA coated distal femur SMILES implants (SE10.017)


The project evaluation form you have submitted has been reviewed and based on the NRES "Defining Research" leaflet it was concluded that your project fits into the category of service evaluation and as such does not require approval from Research Ethics Committee (REC) or R&D Office.

You do not require permission from the R&D Office to proceed with this project, but you should take into consideration implication of your project on service delivery and discuss with your units general manager any implication the project may have.

As this project requires access to patient notes you should take this letter to the medical records department confirming that you have authorised access to patient notes as part of the clinical care team.

Please Note: Service Evaluation projects do not require the same level of governance as research of an interventional nature. For the latter, applicable clinical research legislation needs to be considered as part of research set up and conduct. However, any service evaluation projects and teams involved in such must be aware of and follow any relevant guidance and framework to ensure patient safety and confidentiality.

Yours sincerely,



Handwritten signature

Presentations at Conferences

1. Sahirad C, Batta V, Sebag A, Coathup M, Pollack R, Aston W, Briggs TWR, Blunn GW. Enhanced Fixation of Distal Femoral Replacements with Hydroxyapatite-Coated Collars in Skeletally Immature Patients. British Orthopaedic Association, Birmingham, UK Sept 25-28th, 2018
2. Batta V, Coathup MJ, Pollock R, Aston W, Cannon SR, Skinner J, Briggs TWR, Unwin PS, Blunn GW. Long-term survival of cemented distal femoral endoprostheses with a hydroxyapatite coated collar. British Orthopaedic Research Society, Oxford, Sept 4-5, 2013.
3. Batta V, Coathup MJ, Pollock R, Aston W, Cannon S, Skinner J, Briggs TWR, Blunn GW. Uncemented, custom made hydroxyapatite coated collared distal femoral endoprostheses: Up to eighteen years follow up. International Society for Limb Salvage, Bolgna, Italy, Sept 11-13, 2013.
4. Batta V, Coathup MJ, Pollock R, Aston W, Cannon SR, Skinner J, Briggs TWR, Unwin PS, Blunn GW. Long-term survival of cemented distal femoral endoprostheses with a hydroxyapatite coated collar. International Society for Limb Salvage, Bologna, Italy, Sept 11-13, 2013.
5. Coathup MJ, Batta V, Aston W, Pollock R, Cannon SR, Skinner J, Briggs TWR, Blunn GW. Long-term survival of cemented distal femoral endoprostheses with a HA-coated collar. A histological study and a radiographic follow-up. International Society for Limb Salvage, Bologna, Italy, Sept 11-13, 2013.

Chapter 7

Bibliography

- ABDULKARIM, A., ELLANTI, P., MOTTERLINI, N., FAHEY, T. & O'BYRNE, J. M. 2013. Cemented versus uncemented fixation in total hip replacement: a systematic review and meta-analysis of randomized controlled trials. *Orthopedic reviews*, 5.
- ABUDU, A., GRIMER, R., TILLMAN, R. & CARTER, S. 2006. The use of prostheses in skeletally immature patients. *Orthopedic Clinics of North America*, 37, 75-84.
- AGARWAL, M. 2007. Low cost limb reconstruction for musculoskeletal tumours. *Current Opinion in Orthopaedics*, 18, 561-571.
- AGARWAL, M. G. & NAYAK, P. 2012. *Limb Salvage for Osteosarcoma: Current Status with a Review of Literature*, INTECH Open Access Publisher.
- AHLMANN, E., MENENDEZ, L., KERMANI, C. & GOTHA, H. 2006a. Survivorship and clinical outcome of modular endoprosthetic reconstruction for neoplastic disease of the lower limb. *Bone & Joint Journal*, 88, 790-795.
- AHLMANN, E. R., MENENDEZ, L. R., KERMANI, C. & GOTHA, H. 2006b. Survivorship and clinical outcome of modular endoprosthetic reconstruction for neoplastic disease of the lower limb. *Journal of bone and joint surgery*, 88B, 790-5.
- ALBREKTSSON, T. & JOHANSSON, C. 2001. Osteoinduction, osteoconduction and osseointegration. *European Spine Journal*, 10, S96-S101.
- APARICIO, C., LANG, N. P. & RANGERT, B. 2006. Validity and clinical significance of biomechanical testing of implant/bone interface. *Clinical oral implants research*, 17, 2-7.
- BARBAS, A., BONNET, A.-S., LIPINSKI, P., PESCI, R. & DUBOIS, G. 2012. Development and mechanical characterization of porous titanium bone

- substitutes. *Journal of the mechanical behavior of biomedical materials*, 9, 34-44.
- BARJAKTAROVIĆ, R., POPOVIĆ, Z. & RADOIČIĆ, D. 2011. Megaendoprosthesis in the treatment of bone tumors in the knee and hip region. *Vojnosanitetski pregled*, 68, 62-67.
- BARUT, N., ANRACT, P., BABINET, A. & BIAU, D. 2015. Peri-prosthetic fractures around tumor endoprostheses: a retrospective analysis of eighteen cases. *Int Orthop*, 39, 1851-6.
- BATTA, V., COATHUP, M., PARRATT, M., POLLOCK, R., ASTON, W., CANNON, S., SKINNER, J., BRIGGS, T. & BLUNN, G. 2014. Uncemented, custom-made, hydroxyapatite-coated collared distal femoral endoprostheses. *Bone Joint J*, 96, 263-269.
- BEEBE, K., SONG, K. J., ROSS, E., TUY, B., PATTERSON, F. & BENEVENIA, J. 2009. Functional Outcomes After Limb-Salvage Surgery and Endoprosthetic Reconstruction With an Expandable Prosthesis: A Report of 4 Cases. *Archives of Physical Medicine and Rehabilitation*, 90, 1039-1047.
- BERGIN, P. F., NOVEAU, J. B., JELINEK, J. S. & HENSHAW, R. M. 2012. Aseptic Loosening Rates in Distal Femoral Endoprostheses: Does Stem Size Matter? *Clinical Orthopaedics and Related Research®*, 470, 743-750.
- BICKELS, J., WITTIG, J. C., KOLLENDER, Y., HENSHAW, R., KELLAR-GRANEY, K. L., MELLER, I. & MALAWAR, M. M. 2002. Distal femoral resection with endoprosthetic reconstruction: a long term follow-up study. *Clinical Orthopaedics and Related Research*, 400, 225-35.
- BLEYER, W., HAAS, J., FEIGL, P., GREENLEE, T., SCHALLER, R., MORGAN, A., PENDERGRASS, T., JOHNSON, F., BERNSTEIN, I. & CHARD, R. 1982.

- Improved three-year disease-free survival in osteogenic sarcoma. *Bone & Joint Journal*, 64, 233-238.
- BLOEBAUM, R. D., MERRELL, M., GUSTKE, K. & SIMMONS, M. 1991. Retrieval analysis of a hydroxyapatite-coated hip prosthesis. *Clinical Orthopaedics and related research*, 97-102.
- BLUNN, G. W., BRIGGS, T. W., CANNON, S. R., WALKER, P. S., UNWIN, P. S., CULLIGAN, S. & COBB, J. P. 2000. Cementless fixation for primary segmental bone tumor endoprostheses. *Clin Orthop Relat Res*, 223-30.
- BLUNN, G. W. & WAIT, M. E. 1991. Remodelling of bone around intramedullary stems in growing patients. *Journal of Orthopaedic Research*, 9, 809-19.
- BOBYN, J., STACKPOOL, G., HACKING, S., TANZER, M. & KRYGIER, J. 1999. Characteristics of bone ingrowth and interface mechanics of a new porous tantalum biomaterial. *Bone & Joint Journal*, 81, 907-914.
- BOSSHARDT, D. D., CHAPPUIS, V. & BUSER, D. 2017. Osseointegration of titanium, titanium alloy and zirconia dental implants: current knowledge and open questions. *Periodontology 2000*, 73, 22-40.
- BRA-NEMARK, P.-I., ZARB, G. A., ALBREKTSSON, T. & ROSEN, H. M. 1986. Tissue-Integrated Prostheses. Osseointegration in Clinical Dentistry. LWW.
- BRADISH, C. F., KEMP, H. B., SCALES, J. T. & WILSON, J. N. 1987. Distal femoral replacement by cus-tom-made prostheses: clinical follow-up and survivorship analysis. *Journal of Bone and Joint Surgery*, 69, 276-84.
- BRÅNEMARK, P. 1977. Osseointegrated implants in the treatment of the edentulous jaw. *Scand J Plast Reconstr Surg*, 11.
- BUS, M. P. A., DIJKSTRA, P. D. S., VAN DE SANDE, M. A. J., TAMINIAU, A. H. M., SCHREUDER, H. W. B., JUTTE, P. C., VAN DER GEEST, I. C. M., SCHAAP,

- G. R. & BRAMER, J. A. M. 2014. Intercalary Allograft Reconstructions Following Resection of Primary Bone Tumors. *A Nationwide Multicenter Study*, 96, e26.
- CALVERT, G., CUMMINGS, J., BOWLES, A., JONES, K., WURTZ, L. D. & RANDALL, R. L. 2014. A Dual-center Review of Compressive Osseointegration for Fixation of Massive Endoprosthetics: 2- to 9-year Followup. *Clinical Orthopaedics and Related Research*®, 472, 822-829.
- CAPELLO, W. N., D'ANTONIO, J. A., JAFFE, W. L., GEESINK, R. G., MANLEY, M. T. & FEINBERG, J. R. 2006. Hydroxyapatite-coated femoral components: 15-year minimum followup. *Clin Orthop Relat Res*, 453.
- CARLSSON, Å., BJÖRKMAN, A., BESJAKOV, J. & ÖNSTEN, I. 2005. Cemented tibial component fixation performs better than cementless fixation: a randomized radiostereometric study comparing porous-coated, hydroxyapatite-coated and cemented tibial components over 5 years. *Acta orthopaedica*, 76, 362-369.
- CHAO, E. & SIM, F. 1990a. Composite fixation of segmental bone/joint defect replacement (SDR) prostheses. Biological and biomechanical justifications. *La Chirurgia degli organi di movimento*, 75, 171.
- CHAO, E. Y., FUCHS, B., ROWLAND, C. M., ILSTRUP, D. M., PRITCHARD, D. J. & SIM, F. H. 2004a. Long-term results of segmental prosthesis fixation by extracortical bone-bridging and ingrowth. *J Bone Joint Surg Am*, 86-A, 948-55.
- CHAO, E. Y., FUCHS, B., ROWLAND, C. M., ILSTRUP, D. M., PRITCHARD, D. J. & SIM, F. H. 2004b. Long-term results of segmental prosthesis fixation by extracortical bone-bridging and ingrowth. *J Bone Joint Surg Am*, 86, 948-955.

- CHAO, E. Y. & SIM, F. H. 1990b. Composite fixation of segmental bone/joint defect replacement (SDR) prostheses. Biological and biomechanical justifications. *La Chirurgia degli organi di movimento*, 75, 171-3.
- CHAO, E. Y. & SIM, F. H. 1992. Composite fixation of salvage prostheses for the hip and knee. *Clinical orthopaedics and related research*, 276, 91-101.
- CLERIES, L., FERNÁNDEZ-PRADAS, J. & MORENZA, J. 2000. Bone growth on and resorption of calcium phosphate coatings obtained by pulsed laser deposition. *Journal of Biomedical Materials Research Part A*, 49, 43-52.
- COATHUP, M. J., BATTÀ, V., POLLOCK, R. C., ASTON, W. J., CANNON, S. R., SKINNER, J. A., BRIGGS, T. W., UNWIN, P. S. & BLUNN, G. W. 2013a. Long-Term Survival of Cemented Distal Femoral Endoprostheses with a Hydroxyapatite-Coated Collar. *J Bone Joint Surg Am*, 95, 1569-1575.
- COATHUP, M. J., BATTÀ, V., POLLOCK, R. C., ASTON, W. J., CANNON, S. R., SKINNER, J. A., BRIGGS, T. W., UNWIN, P. S. & BLUNN, G. W. 2013b. Long-term survival of cemented distal femoral endoprostheses with a hydroxyapatite-coated collar: A histological study and a radiographic follow-up. *Journal of bone and joint surgery*, 95, 1569-75.
- COATHUP, M. J., COBB, J. P., WALKER, P. S. & BLUNN, G. W. 2000. Plate fixation of prostheses after segmental resection for bone tumours. *J Orthop Res*, 18, 865-72.
- COATHUP, M. J., KALIA, P., KONAN, S., MIRZA, K. & BLUNN, G. W. 2013c. A comparison of allogeneic and autologous mesenchymal stromal cells and osteoprogenitor cells in augmenting bone formation around massive bone tumor prostheses. *Journal of Biomedical Materials Research Part A*, 101A, 2210-2218.

- COATHUP, M. J., SANGHRAJKA, A., ASTON, W. J., GIKAS, P. D., POLLOCK, R. C., CANNON, S. R., SKINNER, J. A., BRIGGS, T. W. & BLUNN, G. W. 2015. Hydroxyapatite-coated collars reduce radiolucent line progression in cemented distal femoral bone tumor implants. *Clin Orthop Relat Res*, 473, 1505-14.
- COBB, J., ASHWOOD, N., ROBBINS, G., WITT, J., UNWIN, P. & BLUNN, G. 2005. Triplate fixation. *Bone & Joint Journal*, 87, 534-539.
- COLE, B. J., BOSTROM, M. P., PRITCHARD, T. L., SUMNER, D. R., TOMIN, E., LANE, J. M. & WEILAND, A. J. 1997. Use of bone morphogenetic protein 2 on ectopic porous coated implants in the rat. *Clinical orthopaedics and related research*, 219-228.
- CRISTOFOLINI, L., BINI, S. & TONI, A. 1998. In vitro testing of a novel limb salvage prosthesis for the distal femur. *Clinical Biomechanics (Bristol, Avon)*, 13, 608-15.
- D'ANTONIO, J. A., CAPELLO, W., CROTHERS, O., JAFFE, W. & MANLEY, M. 1992. Early clinical experience with hydroxyapatite-coated femoral implants. *JBJS*, 74, 995-1008.
- DARD, M., SEWING, A., MEYER, J., VERRIER, S., ROESSLER, S. & SCHARNWEBER, D. 2000. Tools for tissue engineering of mineralized oral structures. *Clinical oral investigations*, 4, 126-129.
- DAUGAARD, H., ELMENGAARD, B., BECHTOLD, J. E., JENSEN, T. & SOBALLE, K. 2010. The effect on bone growth enhancement of implant coatings with hydroxyapatite and collagen deposited electrochemically and by plasma spray. *J Biomed Mater Res A*, 92, 913-21.

- DAVIS, A., BELL, R., BADLEY, E., YOSHIDA, K. & WILLIAMS, J. 1999. Evaluating functional outcome in patients with lower extremity sarcoma. *Clinical orthopaedics and related research*, 358, 83-100.
- DE GIGLIO, E., SABBATINI, L., COLUCCI, S. & ZAMBONIN, G. 2000. Synthesis, analytical characterization, and osteoblast adhesion properties on RGD-grafted polypyrrole coatings on titanium substrates. *Journal of Biomaterials Science, Polymer Edition*, 11, 1073-1083.
- DECILVEO, A. P., SZCZECH, B. W., TOPFER, J. & WITTIG, J. C. 2017. Reconstruction Using Expandable Endoprotheses for Skeletally Immature Patients With Sarcoma. *Orthopedics*, 40, e157-e163.
- DEGASNE, I., BASLE, M., DEMAIS, V., HURE, G., LESOURD, M., GROLLEAU, B., MERCIER, L. & CHAPPARD, D. 1999. Effects of roughness, fibronectin and vitronectin on attachment, spreading, and proliferation of human osteoblast-like cells (Saos-2) on titanium surfaces. *Calcified tissue international*, 64, 499-507.
- DOMINKUS, M., KREPLER, P., SCHWAMEIS, E., WINDHAGER, R. & KOTZ, R. 2001. Growth prediction in extendable tumor prostheses in children. *Clinical orthopaedics and related research*, 390, 212-220.
- ENGH, C. A., MASSIN, P. & SUTHERS, K. E. 1990a. Roentgenographic assessment of the biologic fixation of porous-surfaced femoral components. *Clin Orthop Relat Res*, 257.
- ENGH, C. A., MASSIN, P. & SUTHERS, K. E. 1990b. Roentgenographic assessment of the biologic fixation of porous-surfaced femoral components. *Clinical orthopaedics and related research*, 257, 107-128.
- ESHRAIGHI, S. & DAS, S. 2010. Mechanical and microstructural properties of polycaprolactone scaffolds with one-dimensional, two-dimensional, and three-

- dimensional orthogonally oriented porous architectures produced by selective laser sintering. *Acta Biomater*, 6, 2467-76.
- FARFALLI, G. L., BOLAND, P. J., MORRIS, C. D., ATHANASIAN, E. A. & HEALEY, J. H. 2009. Early equivalence of uncemented press-fit and Compress femoral fixation. *Clin Orthop Relat Res*, 467, 2792-9.
- FLINT, M. N., GRIFFIN, A. M., BELL, R. S., FERGUSON, P. C. & WUNDER, J. S. 2006. Aseptic loosening is uncommon with uncemented proximal tibia tumor prostheses. *Clinical Orthopaedics and Related Research*, 450, 52-9.
- FROMME, P., BLUNN, G. W., ASTON, W. J., ABDOOLA, T., KORIS, J. & COATHUP, M. J. 2017. The effect of bone growth onto massive prostheses collars in protecting the implant from fracture. *Medical Engineering & Physics*, 41, 19-25.
- FROSCH, K.-H. & STÜRMER, K. M. 2006. Metallic biomaterials in skeletal repair. *European Journal of Trauma*, 32, 149-159.
- FUKUROKU, J., INOUE, N., RAFIEE, B., SIM, F. H., FRASSICA, F. J. & CHAO, E. Y. 2007. Extracortical bone-bridging fixation with use of cortical allograft and recombinant human osteogenic protein-1. *J Bone Joint Surg Am*, 89, 1486-1496.
- FUTANI, H., MINAMIZAKI, T., NISHIMOTO, Y., ABE, S., YABE, H. & UEDA, T. 2006. Long-term follow-up after limb salvage in skeletally immature children with a primary malignant tumor of the distal end of the femur. *The Journal of bone and joint surgery. American volume*, 88, 595-603.
- GIKAS, P. D., KELLER, S., BOYLE, R. & STALLEY, P. D. (ii) Principles of the surgical management of bone tumours. *Orthopaedics and Trauma*, 29, 160-162.

- GKAVARDINA, A. & TSAGOZIS, P. 2014. The use of megaprotheses for reconstruction of large skeletal defects in the extremities: a critical review. *Open Orthop J*, 8, 384-9.
- GOODMAN, S. B., YAO, Z., KEENEY, M. & YANG, F. 2013. The Future of Biologic Coatings for Orthopaedic Implants. *Biomaterials*, 34, 3174-3183.
- GOSHEGER, G., GEBERT, C., AHRENS, H., STREITBUERGER, A., WINKELMANN, W. & HARDES, J. 2006. Endoprosthetic reconstruction in 250 patients with sarcoma. *Clinical Orthopaedics and Related Research*, 164-171.
- GOULDING, K. A., GASTON, C. L. & GRIMER, R. J. 2014. Outcomes and Options for Prosthetic Reconstruction After Tumour Resection About the Knee. *Current Surgery Reports*, 2, 42.
- GRIFFIN, A. M., PARSONS, J. A., DAVIS, A. M., BELL, R. S. & WUNDER, J. S. 2005. Uncemented tumor endoprotheses at the knee - Root causes of failure. *Clinical Orthopaedics and Related Research*, 71-79.
- GRIMER, R. J. 2005. Surgical options for children with osteosarcoma. *The Lancet Oncology*, 6, 85-92.
- GROUNDLAND, J. S. & BINITIE, O. 2016. Reconstruction After Tumor Resection in the Growing Child. *Orthop Clin North Am*, 47, 265-81.
- GUO, W., JI, T., YANG, R., TANG, X. & YANG, Y. 2008. Endoprosthetic replacement for primary tumours around the knee - Experience from Peking University. *Journal of Bone and Joint Surgery-British Volume*, 90B, 1084-1089.
- GUPTA, A., MESWANIA, J., POLLOCK, R., CANNON, S., BRIGGS, T., TAYLOR, S. & BLUNN, G. 2006a. Non-invasive distal femoral expandable endoprosthesis for limb-salvage surgery in paediatric tumours. *Bone & Joint Journal*, 88, 649-654.

- GUPTA, A., POLLOCK, R., CANNON, S. R., BRIGGS, T. W., SKINNER, J. & BLUNN, G. 2006b. A knee-sparing distal femoral endoprosthesis using hydroxyapatite-coated extracortical plates. Preliminary results. *J Bone Joint Surg Br*, 88, 1367-72.
- HAN, G., WANG, Y., BI, W., JIA, J., WANG, W., XU, M., ZHENG, X., MEI, L. & YANG, M. 2015. Reconstruction using massive allografts after resection of extremity osteosarcomas the study design: A retrospective cohort study. *Int J Surg*, 21, 108-11.
- HANNA, S., SEWELL, M., ASTON, W., POLLOCK, R., SKINNER, J., CANNON, S. & BRIGGS, T. 2010. Femoral diaphyseal endoprosthetic reconstruction after segmental resection of primary bone tumours. *Bone & Joint Journal*, 92, 867-874.
- HANZLIK, J. A., DAY, J. S., RIMNAC, C. M. & KURTZ, S. M. 2015. Is There A Difference in Bone Ingrowth in Modular Versus Monoblock Porous Tantalum Tibial Trays? *J Arthroplasty*, 30, 1073-8.
- HARDES, J., GEBERT, C., SCHWAPPACH, A., AHRENS, H., STREITBURGER, A., WINKELMANN, W. & GOSHEGER, G. 2006. Characteristics and outcome of infections associated with tumor endoprostheses. *Archives of orthopaedic and trauma surgery*, 126, 289-296.
- HAYASHI, K., UENOYAMA, K., MATSUGUCHI, N. & SUGIOKA, Y. 1991. Quantitative analysis of in vivo tissue responses to titanium-oxide-and hydroxyapatite-coated titanium alloy. *Journal of Biomedical Materials Research Part A*, 25, 515-523.
- HECK, D., CHAO, E., SIM, F., PRITCHARD, D. & SHIVES, T. 1986a. Titanium Fibermetal Segmental Replacement Prostheses: A Radiographic Analysis and

Review of Current Status. *Clinical orthopaedics and related research*, 204, 266-285.

HECK, D., NAKAJIMA, I., KELLY, P. & CHAO, E. 1986b. The effect of load alteration on the biological and biomechanical performance of a titanium fiber-metal segmental prosthesis. *JBJS*, 68, 118-126.

HECK, D. A., CHAO, E. Y., SIM, F. H., PRITCHARD, D. J. & SHIVES, T. C. 1986c. Titanium fibermetal segmental replacement prostheses. A radiographic analysis and review of current status. *Clinical Orthopaedics and Related Research*, 266-85.

HECK, D. A., NAKAJIMA, I., KELLY, P. J. & CHAO, E. Y. 1986d. The effect of load alteration on the biological and biomechanical performance of a titanium fiber-metal segmental prosthesis. *Journal of bone and joint surgery*, 68A, 118-26.

HEISEL, C., KINKEL, S., BERND, L. & EWERBECK, V. 2006a. Megaprotheses for the treatment of malignant bone tumours of the lower limbs. *International orthopaedics*, 30, 452-7.

HEISEL, C., KINKEL, S., BERND, L. & EWERBECK, V. 2006b. Megaprotheses for the treatment of malignantbone tumours of the lower limbs. *International Orthopaedics*, 30, 452-457.

HENDERSON, E. R., GROUNDLAND, J. S., PALA, E., DENNIS, J. A., WOOTEN, R., CHEONG, D., WINDHAGER, R., KOTZ, R. I., MERCURI, M. & FUNOVICS, P. T. 2011a. Failure mode classification for tumor endoprotheses: retrospective review of five institutions and a literature review. *The Journal of Bone & Joint Surgery*, 93, 418-429.

HENDERSON, E. R., GROUNDLAND, J. S., PALA, E., DENNIS, J. A., WOOTEN, R., CHEONG, D., WINDHAGER, R., KOTZ, R. I., MERCURI, M., FUNOVICS, P.

- T., HORNICEK, F. J., TEMPLE, H. T., RUGGIERI, P. & LETSON, G. D. 2011b. Failure Mode Classification for Tumor Endoprostheses: Retrospective Review of Five Institutions and a Literature Review. *Journal of Bone and Joint Surgery-American Volume*, 93A, 418-429.
- HERRERO-CLIMENT, M., SANTOS-GARCÍA, R., JARAMILLO-SANTOS, R., ROMERO-RUIZ, M. M., FERNÁNDEZ-PALACIN, A., LÁZARO-CALVO, P., BULLÓN, P. & RÍOS-SANTOS, J. V. 2013. Assessment of Osstell ISQ's reliability for implant stability measurement: A cross-sectional clinical study. *Medicina Oral, Patología Oral y Cirugía Bucal*, 18, e877-e882.
- HWANG, J. S., MEHTA, A. D., YOON, R. S. & BEEBE, K. S. 2014. From amputation to limb salvage reconstruction: evolution and role of the endoprosthesis in musculoskeletal oncology. *J Orthop Traumatol*, 15, 81-6.
- ILYAS, I., KURAR, A., MOREAU, P. G. & YOUNGE, D. A. 2001. Modular megaprosthesis for distal femoral tumors. *International Orthopaedics*, 25, 375-77.
- JAYESH, R. S. & DHINAKARSAMY, V. 2015. Osseointegration. *J Pharm Bioallied Sci*, 7, S226-9.
- JEYS, L., GRIMER, R., CARTER, S. & TILLMAN, R. 2005. Periprosthetic infection in patients treated for an orthopaedic oncological condition. *J Bone Joint Surg Am*, 87, 842-849.
- JEYS, L. M., KULKARNI, A., GRIMER, R. J., CARTER, S. R., TILLMAN, R. M. & ABUDU, A. 2008. Endoprosthetic reconstruction for the treatment of musculoskeletal tumors of the appendicular skeleton and pelvis. *Journal of Bone and Joint Surgery-American Volume*, 90A, 1265-71.

- JONES, A. C., ARNS, C. H., HUTMACHER, D. W., MILTHORPE, B. K., SHEPPARD, A. P. & KNACKSTEDT, M. A. 2009. The correlation of pore morphology, interconnectivity and physical properties of 3D ceramic scaffolds with bone ingrowth. *Biomaterials*, 30, 1440-1451.
- KALIA, P., BLUNN, G. W., MILLER, J., BHALLA, A., WISEMAN, M. & COATHUP, M. J. 2006. Do autologous mesenchymal stem cells augment bone growth and contact to massive bone tumor implants? *Tissue engineering*, 12, 1617-1626.
- KASTE, S. C., NEEL, M. D., MEYER, W. H., PRATT, C. B. & RAO, B. N. 1999. Extracortical bridging callus after limb salvage surgery about the knee. *Clin Orthop Relat Res*, 180-5.
- KAWAI, A., LIN, P. P., BOLAND, P. J., ATHANASIAN, E. A. & HEALEY, J. H. 1999. Relationship between magnitude of resection, complication, and prosthetic survival after prosthetic knee reconstructions for distal femoral tumors. *Journal of Surgical Oncology*, 70, 109-115.
- KIENAPFEL, H., SPREY, C., WILKE, A. & GRISS, P. 1999. Implant fixation by bone ingrowth. *J Arthroplasty*, 14, 355-68.
- KINKEL, S., LEHNER, B., KLEINHANS, J., JAKUBOWITZ, E., EWERBECK, V. & HEISEL, C. 2010a. Medium to long-term results after reconstruction of bone defects at the knee with tumor endoprostheses. *Journal of surgical oncology*, 101, 166-169.
- KINKEL, S., LEHNER, B., KLEINHANS, J. A., JAKUBOWITZ, E., EWERBECK, V. & HEISEL, C. 2010b. Medium to Long-Term Results After Reconstruction of Bone Defects at the Knee With Tumor Endoprostheses. *Journal of Surgical Oncology*, 101, 166-169.

- KOTZ, R. & SALZER, M. 1982. Rotation-plasty for childhood osteosarcoma of the distal part of the femur. *JBJS*, 64, 959-969.
- KROON, P. & FREEMAN, M. 1992. Hydroxyapatite coating of hip prostheses. Effect on migration into the femur. *Bone & Joint Journal*, 74, 518-522.
- KUO, K. N., GITELIS, S., SIM, F. H., PRITCHARD, D., CHAO, E., ROSTOKER, W., GALANTE, J. O. & MCDONALD, P. 1983a. Segmental replacement of long bones using titanium fiber metal composite following tumour resection. *Clinical Orthopaedics and Related Research*, 176.
- KUO, K. N., GITELIS, S., SIM, F. H., PRITCHARD, D., CHAO, E., ROSTOKER, W., GALANTE, J. O. & MCDONALD, P. 1983b. Segmental replacement of long bones using titanium fiber metal composite following tumor resection. *Clinical orthopaedics and related research*, 176, 108-114.
- LEUCHT, P., KIM, J. B., WAZEN, R., CURREY, J. A., NANJI, A., BRUNSKI, J. B. & HELMS, J. A. 2007. Effect of mechanical stimuli on skeletal regeneration around implants. *Bone*, 40, 919-30.
- LEVIN, A. S., ARKADER, A. & MORRIS, C. D. 2017. Reconstruction Following Tumor Resections in Skeletally Immature Patients. *Journal of the American Academy of Orthopaedic Surgeons*, 25, 204-213.
- LEWALLEN, E. A., RIESTER, S. M., BONIN, C. A., KREMERS, H. M., DUDAKOVIC, A., KAKAR, S., COHEN, R. C., WESTENDORF, J. J., LEWALLEN, D. G. & VAN WIJNEN, A. J. 2015. Biological strategies for improved osseointegration and osteoinduction of porous metal orthopedic implants. *Tissue Eng Part B Rev*, 21, 218-30.
- LI, Y., YANG, W., LI, X., ZHANG, X., WANG, C., MENG, X., PEI, Y., FAN, X., LAN, P. & WANG, C. 2015. Improving osteointegration and osteogenesis of three-

- dimensional porous Ti6Al4V scaffolds by polydopamine-assisted biomimetic hydroxyapatite coating. *ACS applied materials & interfaces*, 7, 5715-5724.
- LIND, M., OVERGAARD, S., SONG, Y., GOODMAN, S. B., BÜNGER, C. & SØBALLE, K. 2000. Osteogenic protein 1 device stimulates bone healing to hydroxyapatite-coated and titanium implants. *The Journal of arthroplasty*, 15, 339-346.
- MARCOVE, R. 1977. En bloc resection for osteogenic sarcoma. *Canadian journal of surgery. Journal canadien de chirurgie*, 20, 521-528.
- MATSUMINE, A., UEDA, T., SUGITA, T., YAZAWA, Y., ISU, K., KAWAI, A., ABE, S., YAKUSHIJI, T., HIRAGA, H. & SUDO, A. 2011. Clinical outcomes of the KYOCERA Physio Hinge Total Knee System Type III after the resection of a bone and soft tissue tumor of the distal part of the femur. *Journal of surgical oncology*, 103, 257-263.
- MEDING, J. B., KEATING, E. M., RITTER, M. A., FARIS, P. M. & E., B. M. 2004. Minimum ten-year follow-up of a straight-stemmed, plasma-sprayed, titanium-alloy, uncemented femoral component in primary total hip arthroplasty. *Journal of bone and joint surgery*, 86A, 92-7.
- MENDONÇA, S. M. H. D., CASSONE, A. E. & BRANDALISE, S. R. 2008. Functional assessment of patients with bone sarcomas submitted to surgical treatment using total or partial prosthesis in replacement of the distal femoral end. *Acta Ortopédica Brasileira*, 16, 13-18.
- MENEGHINI, R. M., FORD, K. S., MCCOLLOUGH, C. H., HANSSSEN, A. D. & LEWALLEN, D. G. 2010. Bone remodeling around porous metal cementless acetabular components. *The Journal of arthroplasty*, 25, 741-747.

- MEREDITH, N. 1998. Assessment of implant stability as a prognostic determinant. *International Journal of Prosthodontics*, 11.
- MEREDITH, N., SHAGALDI, F., ALLEYNE, D., SENNERBY, L. & CAWLEY, P. 1997. The application of resonance frequency measurements to study the stability of titanium implants during healing in the rabbit tibia. *Clinical oral implants research*, 8, 234-243.
- MITTERMAYER, F., KREPLER, P., DOMINKUS, M., SCHWAMEIS, E., SLUGA, M., HEINZL, H. & KOTZ, R. 2001. Long-term followup of uncemented tumor endoprostheses for the lower extremity. *Clinical Orthopaedics and Related Research*, 167-77.
- MÖLLER, K., GEIJER, M., SOLLERMAN, C. & LUNDBORG, G. 2004. Radiographic evaluation of osseointegration and loosening of titanium implants in the MCP and PIP joints. *The Journal of hand surgery*, 29, 32-38.
- MOORE, M. S., MCAULEY, J. P., YOUNG, A. M. & ENGH, C. A. S. 2006. Radiographic Signs of Osseointegration in Porous-coated Acetabular Components. *Clinical Orthopaedics and Related Research*, 444, 176-183.
- MORII, T., MORIOKA, H., UEDA, T., ARAKI, N., HASHIMOTO, N., KAWAI, A., MOCHIZUKI, K. & ICHIMURA, S. 2013. Deep infection in tumor endoprosthesis around the knee: a multi-institutional study by the Japanese musculoskeletal oncology group. *BMC Musculoskeletal Disorders*, 14, 51-51.
- MORSCHER, E. W., WIDMER, K. H., BEREITER, H., ELKE, R. & SCHENK, R. 2002. [Cementless socket fixation based on the "press-fit" concept in total hip joint arthroplasty]. *Acta Chir Orthop Traumatol Cech*, 69, 8-15.
- MUMITH, A., COATHUP, M., CHIMUTENGWENDE-GORDON, M., ASTON, W., BRIGGS, T. & BLUNN, G. 2017. Augmenting the osseointegration of

- endoprotheses using laser-sintered porous collars: an in vivo study. *Bone Joint J*, 99, 276-282.
- MYERS, G. J., ABUDU, A. T., CARTER, S. R., TILLMAN, R. M. & GRIMER, R. J. 2007a. Endoprosthetic replacement of the distal femur for bone tumours: long-term results. *J Bone Joint Surg Br*, 89, 521-6.
- MYERS, G. J. C., ABUDU, A. T., CARTER, S. R., TILLMAN, R. M. & GRIMER, R. J. 2007b. The long-term results of endoprosthetic replacement of the proximal tibia for bone tumours. *Journal of Bone and Joint Surgery-British Volume*, 89B, 1632-1637.
- NASR, H. F. & MEFFERT, R. M. 1993. A proposed radiographic index for assessment of the current status of osseointegration. *International Journal of Oral & Maxillofacial Implants*, 8.
- NEEL, M. D., WILKINS, R. M., RAO, B. N. & KELLY, C. M. 2003. Early multicenter experience with a noninvasive expandable prosthesis. *Clinical Orthopaedics and Related Research*, 415, 72-81.
- NIU, X. H., HAO, L., ZHANG, Q. & DING, Y. 2007. [Massive allograft replacement in management of bone tumors]. *Zhonghua Wai Ke Za Zhi*, 45, 677-80.
- NYSTROM, L. M. & MORCUENDE, J. A. 2010. Expanding endoprosthesis for pediatric musculoskeletal malignancy: current concepts and results. *Iowa Orthop J*, 30, 141-9.
- O'DONNELL, P. W., GRIFFIN, A. M., EWARD, W. C., STERNHEIM, A., WUNDER, J. S. & FERGUSON, P. C. 2014. Early follow-up of a custom non-fluted diaphyseal press-fit tumour prosthesis. *Int Orthop*, 38, 123-7.

- OKADA, Y., SUKA, T., SIM, F., GORSKI, J. & CHAO, E. 1988a. Comparison of replacement prostheses for segmental defects of bone. Different porous coatings for extracortical fixation. *JBJS*, 70, 160-172.
- OKADA, Y., SUKA, T., SIM, F. H., GORSKI, J. P. & CHAO, E. Y. 1988b. Comparison of replacement prostheses for segmental defects of bone. Different porous coatings for extracortical fixation. *J Bone Joint Surg Am*, 70, 160-72.
- OTTAVIANI, G., ROBERT, R. S., HUH, W. W. & JAFFE, N. 2009. Functional, psychosocial and professional outcomes in long-term survivors of lower-extremity osteosarcomas: amputation versus limb salvage. *Cancer Treat Res*, 152, 421-36.
- PALA, E., MAVROGENIS, A., ANGELINI, A., HENDERSON, E., LETSON, G. D. & RUGGIERI, P. 2013a. Cemented versus cementless endoprostheses for lower limb salvage surgery. *J BUON*, 18, 496-503.
- PALA, E., MAVROGENIS, A. F., ANGELINI, A., HENDERSON, E. R., DOUGLAS LETSON, G. & RUGGIERI, P. 2013b. Cemented versus cementless endoprostheses for lower limb salvage surgery. *J buon*, 18, 496-503.
- PALA, E., TROVARELLI, G., CALABRO, T., ANGELINI, A., ABATI, C. N. & RUGGIERI, P. 2015. Survival of modern knee tumor megaprotheses: failures, functional results, and a comparative statistical analysis. *Clin Orthop Relat Res*, 473, 891-9.
- PALUMBO, B. T., HENDERSON, E. R., GROUNDLAND, J. S., CHEONG, D., PALA, E., LETSON, G. D. & RUGGIERI, P. 2011. Advances in segmental endoprosthetic reconstruction for extremity tumors: a review of contemporary designs and techniques. *Cancer Control*, 18, 160-170.

- PARRY, M. & GRIMER, R. 2015. Limb Salvage in Paediatric Bone Tumours. *Journal of Bone and Soft Tissue Tumors Sep-Dec*, 1, 10-16.
- PICARDO, N., BLUNN, G., SHEKKERIS, A., MESWANIA, J., ASTON, W., POLLOCK, R., SKINNER, J., CANNON, S. & BRIGGS, T. 2012. The medium-term results of the Stanmore non-invasive extendible endoprosthesis in the treatment of paediatric bone tumours. *J Bone Joint Surg Br*, 94, 425-430.
- PICCIOLI, A., ROSSI, B., SACCHETTI, F., SPINELLI, M. & DI MARTINO, A. 2015. Fractures in bone tumour prosthesis. *International Orthopaedics*, 39, 1981-1987.
- PILLIAR, R. M. 2005. Cementless implant fixation—toward improved reliability. *Orthopedic Clinics of North America*, 36, 113-119.
- PURI, A. 2014. Limb salvage in musculoskeletal oncology: Recent advances. *Indian J Plast Surg*, 47, 175-84.
- PURI, A. 2015. Limb salvage: When, where, and how? *Indian J Orthop*, 49, 46-55.
- RAHBEK, O., OVERGAARD, S., LIND, M., BENDIX, K., BÜNGER, C. & SØBALLE, K. 2001. Sealing effect of hydroxyapatite coating on peri-implant migration of particles. *Bone & Joint Journal*, 83, 441-447.
- RAPHEL, J., HOLODNIY, M., GOODMAN, S. B. & HEILSHORN, S. C. 2016. Multifunctional Coatings to Simultaneously Promote Osseointegration and Prevent Infection of Orthopaedic Implants. *Biomaterials*, 84, 301-314.
- ROBERTS, P., CHAN, D., GRIMER, R. J., SNEATH, R. S. & SCALES, J. T. 1991. Prosthetic replacement of the distal femur for primary bone-tumors. *Journal of Bone and Joint Surgery*, 73, 762-69.
- ROCHE, O., GIRARD, J., CANOVAS, F., MIGAUD, H., BONNOMET, F., GOLDSCHILD, M. & LE BÉGUEC, P. 2016. Assessment of fixation in

- cementless femoral revision of total hip arthroplasty: comparison of the Engh score versus radiolucent line measurement. *International Orthopaedics*, 40, 907-912.
- RÖHLECKE, C., WITT, M., KASPER, M., SCHULZE, E., WOLF, C., HOFER, A. & FUNK, R. H. 2001. Synergistic effect of titanium alloy and collagen type I on cell adhesion, proliferation and differentiation of osteoblast-like cells. *Cells Tissues Organs*, 168, 178-187.
- ROSEN, G., CAPARROS, B., NIRENBERG, A., MARCOVE, R. C., HUVOS, A. G., KOSLOFF, C., LANE, J. & MURPHY, M. L. 1981. Ewing's sarcoma: Ten-year experience with adjuvant chemotherapy. *Cancer*, 47, 2204-2213.
- RÖßLER, S., SEWING, A., STÖLZEL, M., BORN, R., SCHARNWEBER, D., DARD, M. & WORCH, H. 2003. Electrochemically assisted deposition of thin calcium phosphate coatings at near-physiological pH and temperature. *Journal of Biomedical Materials Research Part A*, 64, 655-663.
- RUBIO, D., SERRANO, M. & WANG, E. 2013. Tumour endoprosthetic reconstruction for primary aggressive and malignant bone tumours of the distal femur. *Malays Orthop J*, 7, 1-5.
- RYAN, G., PANDIT, A. & APATSIDIS, D. P. 2006. Fabrication methods of porous metals for use in orthopaedic applications. *Biomaterials*, 27, 2651-2670.
- SARAN, N., ZHANG, R. & TURCOTTE, R. E. 2011. Osteogenic protein-1 delivered by hydroxyapatite-coated implants improves bone ingrowth in extracortical bone bridging. *Clin Orthop Relat Res*, 469, 1470-8.
- SCEMAMA, C., DAVID, B., BENSIDHOUM, M. & HAMADOUCHE, M. 2014. Osseointegration of polyethylene implants coated with titanium and

- biomimetically or electrochemically deposited hydroxyapatite in a rabbit model. *Int Orthop*, 38, 1739-44.
- SCHARSCHMIDT, T., COHEN, A., THOMAS, N., CHING, R. & CONRAD, E. 2011. Torsional stability of uncemented femoral stems in oncologic reconstructions. *Orthopedics*, 34, 96.
- SCHINHAN, M., TIEFENBOECK, T., FUNOVICS, P., SEVELDA, F., KOTZ, R. & WINDHAGER, R. 2015. Extendible Prostheses for Children After Resection of Primary Malignant Bone Tumor: Twenty-seven Years of Experience. *J Bone Joint Surg Am*, 97, 1585-91.
- SCHROEDER, A., POHLER, O. & SUTTER, F. 1976. Tissue reaction to an implant of a titanium hollow cylinder with a titanium surface spray layer. *Schweizerische Monatsschrift fur Zahnheilkunde= Revue mensuelle suisse d'odontostomatologie*, 86, 713-727.
- SCHWARTZ, A. J., KABO, J. M., EILBER, F. C., EILBER, F. R. & ECKARDT, J. J. 2010a. Cemented Distal Femoral Endoprotheses for Musculoskeletal Tumor Improved Survival of Modular versus Custom Implants. *Clinical Orthopaedics and Related Research*, 468, 2198-2210.
- SCHWARTZ, A. J., KABO, J. M., EILBER, F. C., EILBER, F. R. & ECKARDT, J. J. 2010b. Cemented distal femoral endoprotheses for musculoskeletal tumor: improved survival of modular versus custom implants. *Clin Orthop Relat Res*, 468, 2198-210.
- SHAHID, M., ALBERGO, N., PURVIS, T., HERON, K., GASTON, L., CARTER, S., GRIMER, R. & JEYS, L. 2017. Management of sarcomas possibly involving the knee joint when to perform extra-articular resection of the knee joint and is it safe? *European Journal of Surgical Oncology (EJSO)*, 43, 175-180.

- SHIN, D. S., CHOONG, P. F., CHAO, E. Y. & SIM, F. H. 2000. Large tumor endoprostheses and extracortical bone-bridging: 28 patients followed 10-20 years. *Acta Orthop Scand*, 71, 305-11.
- SIM, F. H., FRASSICA, F. J. & CHAO, E. Y. 1995. Orthopaedic management using new devices and prostheses. *Clinical orthopaedics and related research*, 160-72.
- SIM, I. W., TSE, L. F., EK, E. T., POWELL, G. J. & CHOONG, P. F. 2007. Salvaging the limb salvage: management of complications following endoprosthetic reconstruction for tumours around the knee. *European Journal of Surgical Oncology*, 33, 796-802.
- SIMON, M. A., ASCHLIMAN, M. A., THOMAS, N. & MANKIN, H. J. 1986. Limb-salvage treatment versus amputation for osteosarcoma of the distal end of the femur. *The Journal of bone and joint surgery. American volume*, 68, 1331-7.
- SKINNER, J., TODO, S., TAYLOR, M., WANG, J., PINSKEROVA, V. & SCOTT, G. 2003. Should the cement mantle around the femoral component be thick or thin? *Bone & Joint Journal*, 85, 45-51.
- SOBALLE, K. 1993. Hydroxyapatite ceramic coating for bone implant fixation. Mechanical and histological studies in dogs. *Acta Orthop Scand Suppl*, 255, 1-58.
- SPIEGELBERG, B., SEWELL, M., ASTON, W., BLUNN, G., POLLOCK, R., CANNON, S. & BRIGGS, T. 2009. The early results of joint-sparing proximal tibial replacement for primary bone tumours, using extracortical plate fixation. *Bone & Joint Journal*, 91, 1373-1377.
- STAALS, E. L., COLANGELI, M., ALI, N., CASANOVA, J. M., DONATI, D. M. & MANFRINI, M. 2015. Are Complications Associated With the Repiphysis®

- Expandable Distal Femoral Prosthesis Acceptable for Its Continued Use?
Clinical Orthopaedics and Related Research®, 473, 3003-3013.
- STEVENSON, J., WIGLEY, C., BURTON, H., GHEZELAYAGH, S., MORRIS, G., EVANS, S., PARRY, M. & JEYS, L. 2017. Minimising aseptic loosening in extreme bone resections: custom-made tumour endoprostheses with short medullary stems and extra-cortical plates. *Bone Joint J*, 99, 1689-1695.
- STOKKE, J., SUNG, L., GUPTA, A., LINDBERG, A. & ROSENBERG, A. R. 2015. Systematic review and meta-analysis of objective and subjective quality of life among pediatric, adolescent, and young adult bone tumor survivors. *Pediatr Blood Cancer*, 62, 1616-29.
- SUGIYAMA, H., WHITESIDE, L. A. & ENGH, C. A. 1992. Torsional fixation of the femoral component in total hip arthroplasty: the effect of surgical press-fit technique. *Clinical Orthopaedics and Related Research*, 275.
- SUN, L., BERNDT, C. C., GROSS, K. A. & KUCUK, A. 2001. Material fundamentals and clinical performance of plasma-sprayed hydroxyapatite coatings: a review. *Journal of biomedical materials research*, 58, 570-592.
- TANG, F., ZHOU, Y., MIN, L., ZHANG, W., SHI, R., LUO, Y., DUAN, H. & TU, C. 2016. limb-salvage treatment of en-block resected distal femoral tumors with endoprosthesis of all-polyethylene tibial component: a 9-year follow-up study. *OncoTargets and therapy*, 9, 5361.
- TANZER, M., KARABASZ, D., KRYGIER, J. J., COHEN, R. & BOBYN, J. D. 2005. Bone augmentation around and within porous implants by local bisphosphonate elution. *Clinical Orthopaedics and Related Research*, 441, 30-9.

- TANZER, M., TURCOTTE, R., HARVEY, E. & BOBYN, J. D. 2003. Extracortical bone bridging in tumor endoprostheses. Radiographic and histologic analysis. *J Bone Joint Surg Am*, 2365-70.
- TAYLOR, S., PERRY, J., MESWANIA, J., DONALDSON, N., WALKER, P. & CANNON, S. 1997a. Telemetry of forces from proximal femoral replacements and relevance to fixation. *Journal of biomechanics*, 30, 225-234.
- TAYLOR, S. J. G., PERRY, J. S., MESWANIA, J. M., DONALDSON, N., WALKER, P. S. & CANNON, S. R. 1997b. Telemetry of forces from proximal femoral replacements and relevance to fixation. *Journal of Biomechanics*, 30, 225-34.
- TORBERT, J. T., FOX, E. J., HOSALKAR, H. S. & OGILVIE, C. M. 2005. Lackman RD. Endoprosthetic reconstructions: results of long-term followup of 139 patients. *Clinical Orthopaedics and Related Research*, 438.
- TORSTRICK, F. B., EVANS, N. T., STEVENS, H. Y., GALL, K. & GULDBERG, R. E. 2016. Do Surface Porosity and Pore Size Influence Mechanical Properties and Cellular Response to PEEK? *Clin Orthop Relat Res*.
- TOY, P. C., WHITE, J. R., SCARBOROUGH, M. T., ENNEKING, W. F. & GIBBS, C. P. 2010. Distal femoral osteoarticular allografts: long-term survival, but frequent complications. *Clin Orthop Relat Res*, 468, 2914-23.
- TURCOTTE, R., STAVROPOULOS, N., TORESON, J. & ALSULTAN, M. 2017. Radiographic assessment of distal femur cemented stems in tumor endoprostheses. *European Journal of Orthopaedic Surgery & Traumatology*, 1-7.
- TYLER, W. K., HEALEY, J. H., MORRIS, C. D., BOLAND, P. J. & O'DONNELL, R. J. 2009. Compress periprosthetic fractures: interface stability and ease of revision. *Clin Orthop Relat Res*, 467, 2800-6.

- UNWIN, P., CANNON, S., GRIMER, R., KEMP, H., SNEATH, R. & WALKER, P. 1996a. Aseptic loosening in cemented custom-made prosthetic replacements for bone tumours of the lower limb. *J Bone Joint Surg Br*, 78, 5-13.
- UNWIN, P. S., CANNON, S. R., GRIMER, R. J., KEMP, H. B. S., SNEATH, R. S. & WALKER, P. S. 1996b. Aseptic loosening in cemented custom-made prosthetic replacements for bone tumours of the lower limb. *Journal of bone and joint surgery*, 78B, 5- 13.
- UNWIN, P. S., COBB, J. P. & WALKER, P. S. 1993. Distal femoral arthroplasty using custom-made prostheses: the first 218 cases. *Journal of Arthroplasty*, 8, 259-68.
- VASCONCELLOS, L. M., LEITE, D. O., OLIVEIRA, F. N., CARVALHO, Y. R. & CAIRO, C. A. 2010. Evaluation of bone ingrowth into porous titanium implant: histomorphometric analysis in rabbits. *Braz Oral Res*, 24, 399-405.
- VENABLE, C. & STUCK, W. G. 1948. RESULTS OF RECENT STUDIES AND EXPERIMENTS CONCERNING METALS USED IN THE INTERNAL FIXATION OF FRACTURES. *JBJ*, 30, 247-250.
- VENABLE, C. S. & STUCK, W. G. 1941. THREE YEARS' EXPERIENCE WITH VITALLIUM IN BONE SURGERY. *Annals of surgery*, 114, 309.
- VENABLE, C. S. & STUCK, W. G. 1943. Clinical uses of vitallium. *Annals of surgery*, 117, 772.
- VENABLE, C. S., STUCK, W. G. & BEACH, A. 1937. The effects on bone of the presence of metals; based upon electrolysis: an experimental study. *Annals of surgery*, 105, 917.

- VON DER MARK, K. & PARK, J. 2013. Engineering biocompatible implant surfaces. Part II: cellular recognition of biomaterial surfaces: lessons from cell–matrix interactions. *Prog Mater Sci*, 58, 327-381.
- WANG, H., ELIAZ, N., XIANG, Z., HSU, H.-P., SPECTOR, M. & HOBBS, L. W. 2006. Early bone apposition in vivo on plasma-sprayed and electrochemically deposited hydroxyapatite coatings on titanium alloy. *Biomaterials*, 27, 4192-4203.
- WARD, W. G., JOHNSTON, K. S., DOREY, F. J. & ECKARDT, J. J. 1993a. Extramedullary porous coating to prevent diaphyseal osteolysis and radiolucent lines around proximal tibial replacements. A preliminary report. *JBJS*, 75, 976-987.
- WARD, W. G., JOHNSTON, K. S., DOREY, F. J. & ECKARDT, J. J. 1993b. Extramedullary porous coating to prevent diaphyseal osteolysis and radiolucent lines around proximal tibial replacements. A preliminary report. *J Bone Joint Surg Am*, 75, 976-87.
- WARD, W. G., JOHNSTON, K. S., DOREY, F. J. & ECKARDT, J. J. 1997. Loosening of massive proximal femoral cemented endoprostheses: radiographic evidence of loosening mechanism. *The Journal of arthroplasty*, 12, 741-750.
- WAUTHLE, R. 2014. *Industrialization of Selective Laser Melting for the Production of Porous Titanium and Tantalum implants*. UMC Utrecht.
- WAUTHLE, R., VAN DER STOK, J., YAVARI, S. A., VAN HUMBEECK, J., KRUTH, J.-P., ZADPOOR, A. A., WEINANS, H., MULIER, M. & SCHROOTEN, J. 2015. Additively manufactured porous tantalum implants. *Acta biomaterialia*, 14, 217-225.

- WILLERT, H. G. & BUCHHORN, G. H. 1999. Osseointegration of cemented and noncemented implants in artificial hip replacement: long-term findings in man. *J Long Term Eff Med Implants*, 9, 113-30.
- WILLIE, B. M., YANG, X., KELLY, N. H., MERKOW, J., GAGNE, S., WARE, R., WRIGHT, T. M. & BOSTROM, M. P. 2010. Osseointegration into a novel titanium foam implant in the distal femur of a rabbit. *J Biomed Mater Res B Appl Biomater*, 92, 479-88.
- WINDHAGER, R., SCHREINER, M., STAATS, K. & APPRICH, S. 2016. Megaprotheses in the treatment of periprosthetic fractures of the knee joint: indication, technique, results and review of literature. *International Orthopaedics*, 40, 935-943.
- WIRGANOWICZ, P. Z., ECKARDT, J. J., DOREY, F. J., EILBER, F. R. & KABO, J. M. 1999. Etiology and results of tumor endoprosthesis revision surgery in 64 patients. *Clinical Orthopaedics and Related Research*, 358, 64-74.
- WUNDER, J. S., LEITCH, K., GRIFFIN, A. M., DAVIS, A. M. & S., B. R. 2001. Comparison of two methods of reconstruction for primary malignant tumors at the knee: a sequential cohort study. *Journal of Surgical Oncology*, 77, 89-99.
- XIA, Y., ZHOU, P., CHENG, X., XIE, Y., LIANG, C., LI, C. & XU, S. 2013. Selective laser sintering fabrication of nano-hydroxyapatite/poly-epsilon-caprolactone scaffolds for bone tissue engineering applications. *Int J Nanomedicine*, 8, 4197-213.
- XU, S., YU, X., XU, M. & FU, Z. 2013. Inactivated autograft-prosthesis composite has a role for grade III giant cell tumor of bone around the knee. *BMC Musculoskeletal Disord*, 14, 319.

- YANG, G. L., HE, F. M., HU, J. A., WANG, X. X. & ZHAO, S. F. 2009. Effects of biomimetically and electrochemically deposited nano-hydroxyapatite coatings on osseointegration of porous titanium implants. *Oral Surg Oral Med Oral Pathol Oral Radiol Endod*, 107, 782-9.
- YANG, J., ZHU, B., FU, K. & YANG, Q. 2015. The long-term outcomes following the use of inactivated autograft in the treatment of primary malignant musculoskeletal tumor. *J Orthop Surg Res*, 10, 177.
- YIN, B., MA, P., CHEN, J., WANG, H., WU, G., LI, B., LI, Q., HUANG, Z., QIU, G. & WU, Z. 2016. Hybrid Macro-Porous Titanium Ornamented by Degradable 3D Gel/nHA Micro-Scaffolds for Bone Tissue Regeneration. *International journal of molecular sciences*, 17, 575.
- YOSHIDA, Y., OSAKA, S. & TOKUHASHI, Y. 2010. Analysis of limb function after various reconstruction methods according to tumor location following resection of pediatric malignant bone tumors. *World Journal of Surgical Oncology*, 8, 39.
- YU, X. C., XU, S. F., XU, M., LIU, X. P., SONG, R. X. & FU, Z. H. 2014. Alcohol-inactivated autograft replantation with joint preservation in the management of osteosarcoma of the distal femur: a preliminary study. *Oncol Res Treat*, 37, 554-60.
- ZHANG, R., AN, Y., TOTH, C. A., DRAUGHN, R. A., DIMAANO, N. M. & HAWKINS, M. V. 2004. Osteogenic protein-1 enhances osseointegration of titanium implants coated with peri-apatite in rabbit femoral defect. *Journal of Biomedical Materials Research Part B: Applied Biomaterials*, 71, 408-413.
- ZHOU, Y., JIANG, T., QIAN, M., ZHANG, X., WANG, J., SHI, B., XIA, H., CHENG, X. & WANG, Y. 2008. Roles of bone scintigraphy and resonance frequency

analysis in evaluating osseointegration of endosseous implant. *Biomaterials*, 29, 461-474.

ZWOLAK, P., KÜHNEL, S. P. & FUCHS, B. 2011. Extraarticular knee resection for sarcomas with preservation of the extensor mechanism: surgical technique and review of cases. *Clinical Orthopaedics and Related Research®*, 469, 251-256.