

**DIAGNOSTIC UTILITY OF MRS VALUES IN  
HIPPOCAMPUS FORMATION OF MEDICALLY  
INTRACTABLE TEMPORAL LOBE EPILEPSY  
PATIENTS IN HUSM**

**BY**

**DR. GYATHRI DEVI A/P DHARMALINGAM**

**DISSERTATION SUBMITTED IN PARTIAL  
FULFILLMENT OF THE REQUIREMENTS FOR THE  
DEGREE OF MASTER OF MEDICINE  
(RADIOLOGY)**



**UNIVERSITI SAINS MALAYSIA**

**MAY 2017**

**DIAGNOSTIC UTILITY OF MRS VALUES IN  
HIPPOCAMPUS FORMATION OF MEDICALLY  
INTRACTABLE TEMPORAL LOBE EPILEPSY  
PATIENTS IN HUSM**

**By**

**DR. GYATHRI DEVI A/P DHARMALINGAM**

**DISSERTATION SUBMITTED IN PARTIAL FULFILLMENT OF THE  
REQUIREMENTS FOR THE DEGREE OF MASTER OF MEDICINE  
(RADIOLOGY)**

**UNIVERSITI SAINS MALAYSIA**

**MAY 2017**

**SUPERVISOR:**

**DR. WIN MAR @ SALMAH JALALUDDIN**

## ACKNOWLEDGEMENT

It is a pleasure to thank the many people who made this thesis possible. Firstly I would like to express my heartfelt gratitude and utmost thanks to my main and co-supervisors, Dr. Win Mar @ Salmah Jalaluddin and Prof. John Tharakan, for the guidance, insightful comments and patience given to me throughout the present study.

Further more, I would like to extend my gratitude to the following individuals for their continuous support in various ways up completion of this thesis:

1. Staff from Radiology Department and Neurosciences Department, HUSM, for the technical assistance and advice during the data collection.
2. Prof Madya Dr Mohd Shafie Abdullah, Prof Madya Dr Mohd Ezane Aziz, Dr Juhara Haron, Dr Norzila Abu Bakar, Dr Chandran, Dr Ahmad Tarmizi, Dr Wan Aireene, Dr Ahmad Hadif, Dr Khairil Amir, radiologists all of whom have directly or indirectly contributed their support to the success of this study.
3. Colleagues and all the staff in the Department of Radiology, HUSM

Last but not the least, I would like to thank Universiti Sains Malaysia for the Short-Term Research Grant Scheme No: 304/PPSP/61313116.

## TABLE OF CONTENTS

<b>ACKNOWLEDGEMENT</b> .....	<b>ii</b>
<b>TABLE OF CONTENTS</b> .....	<b>iii</b>
<b>LIST OF TABLES</b> .....	<b>iv</b>
<b>LIST OF FIGURES</b> .....	<b>v</b>
<b>LIST OF ABBREVIATIONS</b> .....	<b>vi</b>
<b>ABSTRAK</b> .....	<b>vii</b>
<b>ABSTRACT</b> .....	<b>ix</b>
<b>SECTION ONE INTRODUCTION</b> .....	<b>1</b>
<b>SECTION TWO STUDY PROTOCOL</b> .....	<b>5</b>
1.0 RESEARCH PROPOSAL .....	5
<b>SECTION THREE BODY CONTENT</b> .....	<b>26</b>
2.0 Main document.....	27
2.1 Abstract .....	27
2.2 Introduction .....	28
2.3 General Objective.....	29
2.4 Materials and methods .....	30
2.5 Results .....	32
2.6 Discussions.....	40
2.7 Conclusion.....	45
2.8 Acknowledgement.....	46
2.9 References .....	46
3.0 Selected journal format.....	49
<b>SECTION 4 REFERENCE MATERIAL</b> .....	<b>60</b>
4.0 REFERENCES .....	60
<b>SECTION 5 APPENDICES</b> .....	<b>63</b>
APPENDIX 1: DATA COLLECTION SHEET .....	63
APPENDIX 2: PATIENT INFORMATION AND CONSENT FORM.....	64

## LIST OF TABLES

Table 1	Overall demographic data of participant.....	35
Table 2	Demographic data of participant according to control and disease groups.....	37
Table 3	Comparison of mean MRS values of left and right sides hippocampal formation in control patients .....	37
Table 4	Comparison between MRS values ipsilateral to positive EEG findings in hippocampal formation of MTLE patients and that of control subjects.....	38
Table 5	Comparison between MRS values of ipsilateral and contralateral to positive EEG findings in hippocampal formation in MTLE patients .....	38
Table 6	Association between EEG findings and MRS values of hippocampus in MTLE patients .....	39
Table 7	Utility of hippocampal formation MRI and MRS findings in diagnosis of MTLE .....	39

## LIST OF FIGURES

- Figure 1      Region of interest (ROI) placement in the normal left temporal lobe. Coronal oblique TSE T2 (A) and coronal oblique FLAIR (B) were used for the single voxel placement. .... 36
- Figure 2      Region of interest (ROI) placement in the left temporal lobe of patient with atrophy. Coronal oblique TSE T2 (A) and coronal oblique FLAIR (B) were used for the single voxel placement. .... 36

## LIST OF ABBREVIATIONS

Cho	Choline
Cr	Creatin-phosphocreatin
NAA	N-acetyl aspartate
EEG	Electroencephalogram
HUSM	Hospital Universiti Sains Malaysia
HS	Hippocampal sclerosis
MRI	Magnetic resonance imaging
MRS	Magnetic resonance spectrometry
MTLE	Medically intractable temporal lobe epilepsy
MTS	Mesial temporal sclerosis

**UTILITY DIAGNOSTIK NILAI MRS DALAM FORMASI HIPPOCAMPUS PESAKIT  
EPILEPSI TEMPORAL LOBE LUAR KAWALAN PERUBATAN DALAM HUSM**

**ABSTRAK**

**Latar Belakang:** Analisis formasi hippocampal oleh pengimejan resonans magnetik (MRI) dan proton MR spektroskopi ( $^1\text{H}$ -MRS) adalah sangat berguna untuk lateralisasi tumpuan seizure dan diagnosis epilepsi lobus temporal luar kawalan perubatan (MTLE). Kajian ini bertujuan untuk menilai utiliti diagnostik keputusan MRS, MRI, dan kombinasi MRI-MRS daripada formasi hippocampal pesakit MTLE.

**Tatacara:** Sebanyak 14 pesakit MTLE dan 14 subjek kawalan telah menjalani pemeriksaan MRI dan MRS ke atas formasi hippocampal. Para pesakit disahkan mendapati MTLE secara klinikal dan menunjukkan unilateralisasi dalam pemeriksaan electroencephalogram (EEG). Pesakit dipastikan bebas daripada seizure untuk tempoh sekurang-kurangnya 24 jam sebelum analisis kajian untuk mengelakkan kemungkinan penjejasan ketepatan keputusan selepas ictal akut.

**Keputusan:** Terdapat penyusutan nilai dalam NAA/Cr dan kenaikan Cho/Cr yang ketara ( $p < 0.05$ ) dalam formasi hippocampal ipsilateral pesakit MTLE berbanding dengan nilai yang didapati daripada kontralateral dan kumpulan kawalan, masing-masing. Dalam penilaian utiliti diagnostik nilai MRS individu untuk pengesanan focus epilepsi dalam formasi hippocampal, hanya NAA/Cr dan NAA/Cho menunjukkan persetujuan sederhana dan berpatutan yang ketara dengan keputusan lateralisasi EEG, masing-masing. Analisis kombinasi nilai-nilai MRS atau MRI sahaja menunjukkan persetujuan yang berpatutan dan sederhana dengan keputusan lateralisasi EEG, masing-



masing. Analisis menggunakan kombinasi MRS+MRI menunjukkan persetujuan tinggi dengan dengan keputusan lateralisasi EEG. Perjanjian peratusan positif dan negatif dengan keputusan lateralisasi EEG adalah 79% dan 93%, masing-masing.

**Kesimpulan:** Analisis kombinasi MRS+MRI menambahbaik lateralization fokus epilepsi dan diagnosis MTLE.

**Kata-kata kunci:** Epilepsi lobus temporal luar kawalan perubatan (MTLE), pengimejan MR (MRI), spektrometri MR (MRS), analisis kombinasi MRI-MRS

# DIAGNOSTIC UTILITY OF MRS VALUES IN HIPPOCAMPUS FORMATION OF MEDICALLY INTRACTABLE TEMPORAL LOBE EPILEPSY PATIENTS IN HUSM

## ABSTRACT

**Background:** Hippocampal formation analysis by magnetic resonance imaging (MRI) and proton MR spectroscopy (1H-MRS) is useful for lateralization of seizure focus and diagnosis of medical intractable temporal lobe epilepsy (MTLE). The present study assessed the diagnostic utility of MRS, MRI, and combinatorial MRI-MRS findings from hippocampal formation of MTLE patients.

**Methods:** A total of 14 MTLE patients and 14 control subjects were underwent MRI and MRS examination on hippocampal formation. The patients were clinically diagnosed as MTLE patients and revealed unilateralization by electroencephalogram (EEG) examination. The patient was ensured seizure free for a minimum period of 24 hours before the analyses to avoid possible effect of acute post ictal changes.

**Results:** There were significant ( $p < 0.05$ ) decrement in NAA/Cr and increment in Cho/Cr in ipsilateral hippocampal formation of MTLE patients compared to that of contralateral findings and control group, separately. In the evaluation of diagnostic utility of individual MRS value for detection of epileptic focus in hippocampal formation, only NAA/Cr and NAA/Cho revealed significant moderate and fair agreements with the EEG lateralization findings, respectively. Analysis by combinatorial MRS values or MRI alone revealed fair and moderate agreement with EEG lateralization findings, respectively. Analysis using combinatorial MRS+MRI showed substantial agreement with with EEG lateralization findings. The positive and

negative percentage agreements with EEG lateralization findings were 79% and 93%, respectively.

**Conclusion:** Combinatorial MRS+MRI analysis improved the lateralization of epileptic focus and diagnosis of MTLE.

**Keywords:** Medical intractable temporal lobe epilepsy (MTLE), MR imaging (MRI), MR spectrometry (MRS), Combinatorial MRI-MRS analysis

**SECTION ONE**

**INTRODUCTION**

## SECTION ONE

### INTRODUCTION

Temporal lobe epilepsy is a chronic neurological condition characterized by recurrent, unprovoked epileptic seizures (epilepsy) which originate in the temporal lobe of the brain. The seizures involve sensory changes; for example, smelling an unusual odor that is not there, or disturbance of memory. The most common cause is mesial temporal sclerosis (MTS), arising in the hippocampus, the parahippocampal gyrus and the amygdala which are located in the inner (medial) aspect of the temporal lobe. Temporal lobe epilepsy (TLE) is the single most common form of partial seizure. Treatment is through medication or surgery and prognosis is variable.

The International League against Epilepsy proposed a definition of medically intractable or drug-resistance epilepsy as a failure of adequate trials of 2 tolerated and appropriately chosen and used AED schedules. However the seizure frequency and the time factor are varied. The most common cause of MTLE is hippocampal sclerosis (HS) which accounts for 50%-70% of the cases. The sclerosis foci can be unilateral or bilateral, but the latter is less common (Ende et al., 1997; Achten et al., 1998). HS can be spotted preoperatively on magnetic resonance imaging (MRI) in patients with MTLE (Cascino, 1995). However, 20-30% of patients with chronic TLE have negative MRI findings (Xu et al., 2015).

On the other hand, if EEG examination revealed inconvincing or insufficient data, invasive intracranial EEG recording could aid in identification of the epileptic focus. EEG used in helping the diagnosis of MTLE can be divided into interictal and

ictal state. The characteristic EEG findings during interictal state is anterior temporal sharp waves, spikes and followed by slow waves. This is present in up to 94% of the patients. During ictal state, the scalp EEG will show unilateral 5-7 Hz rhythmic discharges that appears within the first 30 seconds of the first objective or subjective clinical sign and symptoms of a seizure; in anterior-inferior temporal scalp EEG. This characteristic rhythm occurs in about 90% of patients with MTLE and has 95% specificity for lateralizing the seizure. There are promising reports that suggest that it may be possible to determine the in the functional and structural changes temporal lobe of the patients with refractory epilepsy consequent to the recent improvements in the imaging techniques.

<sup>1</sup>H magnetic resonance spectroscopy (MRS) has been introduced as a noninvasive sensitive technique which is useful especially in the preoperative evaluation of TLE patients with lateralization findings. MRS of the brain can detect and quantify various neuronal molecules including N-acetyl aspartate (NAA), creatin-phosphocreatin(Cr) and cholin (Cho). Decreased NAA signals indicate neuronal loss or dysfunction, while the increase of the signals taken from Cr and Cho indicate gliosis (Gadian et al., 1996; Connelly et al., 1998; Achten et al., 1998; Someya et al.,2000). The use of NAA/Cho+Cr signal ratio is considered to be a sensitive indicator of neuronal loss and astrocytosis (Connelly et al., 1998; Connelly et al., 1994; Hammen et al., 2006). Various studies of TLE patients have reported on the relationship between metabolism from MRS and function from neuropsychological analysis. However, there are a limited number of studies which has investigated the relationship between the patients who had hippocampal sclerosis (HS) and Magnetic Resonance Imaging negative TLE patients (MR-negative TLE) (Namer et al., 1999; Sawrie et al.,2000;

Martin). Study by Connelly, Van Paesschen [12] showed that there was five out of seven MTLE patients with negative MRI findings presented abnormally low NAA/(Cr+Cho) ratio. Another study by Woermann, McLean [13] analysed MRS measurements in normal subjects (n=15), patients with unilateral HS (n=15), and TLE patients with negative MRI findings (n=15). Twelve out of fifteen HS patients had abnormally low NAA concentration in sclerotic region; while in patients with negative MRI findings, only four subjects revealed abnormal NAA findings. Study by Xu, Ergene [4] revealed significant decrement in the NAA/Cr and NAA/(Cr+Cho) ratios of MTLE patients with negative MRI findings, compared to the that of control subjects.

To date, increasing interest among clinicians has been shown in surgical treatment of MTLE due to the improved outcome compared to conservative treatment. Findings from MRI and/or MRS examinations coupled with scalp EEG analysis are important in lateralization of epileptic focus, preoperatively. The present study aimed to examine the usefulness of diagnostic utility of both MRI and MRS findings in lateralization of epileptic focus in hippocampal formation and diagnosis of MTLE.

**SECTION TWO**

**STUDY PROTOCOL**



**SECTION TWO**  
**STUDY PROTOCOL**

**1.0 RESEARCH PROPOSAL**

**RESEARCH PROPOSAL**

**Title:**

MRS Values in Hippocampus Formation of Medically Intractable Temporal Lobe  
Epilepsy Patients in HUSM

**Name of student:** Dr. Gyathri Devi A/P Dharmalingam (MMC: 46190)

**Student ID:** MMed (Radiology), P-UM0018/13

**Supervisor:**

Dr. Win Mar @ Salmah Jalaluddin (MMC: 30920)

Senior Lecturer, Department of Radiology, HUSM

**Co-supervisor:**

Prof. John Tharakan

Senior Lecturer, Department of Neurosciences, HUSM

Pusat Pengajian Sains Perubatan

Kampus Kesihatan

Universiti Sains Malaysia

16150 Kubang Kerian,

Kelantan, Malaysia.

## **Summary of Research Proposal for Review of Human Ethical Committee**

### **1.1 TITLE:**

Diagnostic Utility of MRS Values in Hippocampus Formation of Medically Intractable Temporal Lobe Epilepsy Patients in HUSM

### **1.2 OBJECTIVES:**

#### **1.2.1 GENERAL OBJECTIVE**

- To determine MRS values in the Hippocampus Formation of medically intractable temporal lobe epilepsy (TLE) patients.

#### **1.2.2 SPECIFIC OBJECTIVE**

1. To compare the MRS mean values of the hippocampal formation in medically intractable TLE patients with normal individuals
2. To determine association between EEG findings with MRS values in medically intractable TLE patients

### **1.3 RESEARCH HYPOTHESIS**

1. There is no significant difference in MRS values of the hippocampal formation in medically intractable Temporal Lobe Epilepsy patients with normal individuals.

2. There is no significant difference between EEG findings with MRS values in medically intractable TLE patients.

#### **1.4 BACKGROUND**

Temporal lobe epilepsy is a chronic neurological condition characterized by recurrent, unprovoked epileptic seizures (epilepsy) which originate in the temporal lobe of the brain. The seizures involve sensory changes; for example, smelling an unusual odor that is not there, or disturbance of memory. The most common cause is mesial temporal sclerosis epilepsy (MTLE), arising in the hippocampus, the parahippocampal gyrus and the amygdala which are located in the inner (medial) aspect of the temporal lobe. Temporal lobe epilepsy (TLE) is the single most common form of partial seizure. Treatment is through medication or surgery and prognosis is variable.

The International League against Epilepsy proposed a definition of medically intractable or drug-resistance epilepsy as a failure of adequate trials of 2 tolerated and appropriately chosen and used AED schedules. However the seizure frequency and the time factor are varied. EEG used in helping the diagnosis of MTLE can be divided into interictal and ictal state.

The characteristic EEG findings during interictal state is anterior temporal sharp waves, spikes and followed by slow waves. This is present in up to 94% of the patients. During ictal state, the scalp EEG will shows unilateral 5-7 Hz rhythmic discharges that appears within the first 30 seconds of the first objective or subjective clinical sign and symptoms of a seizure; in anterior-inferior temporal scalp EEG. This characteristic rhythm occurs in about 90% of patients with MTLE and has 95% specificity for

lateralizing the seizure. There are promising reports that suggest that it may be possible to determine the in the functional and structural changes temporal lobe of the patients with refractory epilepsy consequent to the recent improvements in the imaging techniques.

<sup>1</sup>H magnetic resonance spectroscopy (MRS) has been introduced as a noninvasive sensitive technique which is useful especially in the preoperative evaluation of TLE patients with lateralization findings. MRS of the brain can detect and quantify various neuronal molecules including N-acetyl aspartate (NAA), creatin-phosphocreatin(Cr) and cholin (Cho). Decreased NAA signals indicate neuronal loss or dysfunction, while the increase of the signals taken from Cr and Cho indicate gliosis (Gadian et al., 1996; Connelly et al., 1998; Achten et al., 1998; Someya et al.,2000). The use of NAA/Cho+Cr signal ratio is considered to be a sensitive indicator of neuronal loss and astrocytosis (Connelly et al., 1998; Connelly et al., 1994; Hammen et al., 2006). Various studies of TLE patients have reported on the relationship between metabolism from MRS and function from neuropsychological analysis. However, there are a limited number of studies which has investigated the relationship between the patients who had hippocampal sclerosis (HS) and Magnetic Resonance Imaging negative TLE patients (MR-negative TLE) (Namer et al., 1999; Sawrie et al.,2000; Martin).

The purpose of this study is to assess the utility of hippocampal MRS measurements in patients with known MTLE with comparison to the normal individuals.

## **1.5 METHODOLOGY**

**Study design:** Prospective comparative study from 1 September 2014 till 31<sup>st</sup>  
Dec 2015 (1 year)

**Source population:** Patients from neurology clinic from Hospital University Sains  
Malaysia (USM)

### **1.5.1 Inclusion criteria for patients:**

- 18 years and above
- clinically diagnosed as MTLE
- Interictal epileptiform activity from either or both temporal lobe on routine scalp EEG
- Seizure free for a minimum period of 24 hours before the MR imaging to avoid possible effect of acute post ictal changes.

### **1.5.2 Exclusion criteria for patients:**

- Presence of focal abnormalities like neoplastic or vascular pathology on MRI
- Presence of any disease affecting the cognitive function

### **1.5.3 Inclusion criteria for normal controls:**

- 18 years and above
- No history of epilepsy
- No neurological deficit

### **1.5.4 Exclusion criteria for normal controls:**

- Presence of focal abnormalities like neoplastic or vascular pathology on

- Abnormal hippocampal formation-either reduced in size or increased in signal intensity on T2 and FLAIR.

## **1.6 OPERATIONAL DEFINITION:**

### **1.6.1 Anatomy of the Hippocampus on MRI**

The hippocampus is best imaged in the coronal plane, angled perpendicular to the long axis of the hippocampal body. Three parts of the hippocampus (head, body and tail) can be identified by local landmarks:

#### **Hippocampal head:**

- basilar artery to interpeduncular cistern
- posterior most extent is the first slice where the uncus is clearly seen

#### **Hippocampal body:**

- interpeduncular cistern to superior colliculus.

#### **Hippocampal tail:**

- from superior colliculus
- from the point at which the fornix can be seen in full profile

### **1.6.2 Clinical diagnosis**

Patients are classified as medically intractable Temporal lobe epilepsy (MTLE) based on clinical history, seizure description, results on intensive EEG monitoring and failure to control symptoms with more than 2 anti-epileptic drugs (AED) medication by neurophysician.

### **1.6.3 Definition of intractable epilepsy**

Drug-resistant epilepsy as a failure of adequate trials of 2 tolerated and appropriately chosen and used anti-epileptic drug (AED) schedules. However, the seizure frequency and time factor are varied. Intractable epilepsy definition is proposed by International League against Epilepsy and this is currently used clinical and research setting (Definition of intractable epilepsy –Sinha S Pub Med 2011).

### **1.6.4 Temporal lobe Epilepsy**

Temporal lobe epilepsy was defined by the International League against Epilepsy (ILAE) a condition characterized by recurrent, unprovoked seizures originating from the medial or lateral temporal lobe. The seizures associated with this condition consist of simple partial seizures without loss of awareness and complex partial seizures (i.e. with loss of awareness). Common features are memory impairment and aura.

### **1.6.5 EEG diagnosis**

Electrophysiological examination was performed in the electrophysiological laboratories in Hospital Universiti Sains Malaysia, Neuroscience department. 25 lead EEG device with ECG At least 2 separate EEG recordings were obtained from all patients and EEG records were evaluated and interpreted by an experienced neurologist.

### **1.6.6 Mesial temporal sclerosis (MTS)**

This refers to hippocampal sclerosis, which is the most commonly association with medically intractable temporal lobe epilepsy (MTLE). MRI done in coronal high resolution T2WI/FLAIR will show hippocampal atrophy, increased T2 signal and loss

of internal architecture (interdigitations of hippocampus). Severe and long standing, additional associated findings include atrophy of ipsilateral fornix and mamillary body.

### 1.7 RESEARCH TOOL:

#### High resolution MR imaging

MR imaging was performed by using Philips 3 Tesla (Acheiva Mr scanner, Best The Netherlands) with permitted automated shimming, water suppression and data processing technique. A standard head coil will be used (SENSE-HEAD-32).

#### MR SEQUENCES:

- a) Sagittal T1W\_SE
- b) Coronal Oblique\_T1 IR
- c) Coronal Oblique\_TSE\_T2
- d) Coronal Oblique\_FLAIR
- e) Coronal\_T1W-3D\_FFE
- f) MRS
- g) DTI
- h) ADC

#### MR Sequence detail parameter

##### a) Sagittal T1W\_SE

<i>Coil</i>	<i>SENSE-HEAD-32</i>
<i>Field of View (FOV)</i>	
<ul style="list-style-type: none"> <li>• <i>AP (mm)</i></li> <li>• <i>RL (mm)</i></li> <li>• <i>FH (mm)</i></li> </ul>	<p>232</p> <p>131</p> <p>250</p>
<i>Voxel size</i>	
<ul style="list-style-type: none"> <li>• <i>-AP (mm)</i></li> <li>• <i>-RL (mm)</i></li> </ul>	<p>0.9</p> <p>1.12</p>
<i>Slice thickness (mm)</i>	5
<i>Slice gap (mm)</i>	5
<i>Reconstruction Voxel Size (mm)</i>	0.449
<i>TR/TE (ms)</i>	500/10
<i>ACQ matrix M x P (mm)</i>	280x206
<i>Reconstruction voxel MPS (mm)</i>	0.45/0.45/5.0
<i>Reconstruction matrix</i>	560
<i>Total scan duration</i>	3:30.2



**b) Axial T2W (3mm)**

<i>Coil</i>	<i>SENSE-HEAD-32</i>
<i>Field of View (FOV)</i>	
• <i>AP (mm)</i>	230
• <i>RL (mm)</i>	184
• <i>FH (mm)</i>	150
<i>Voxel size</i>	
• <i>-AP (mm)</i>	0.575
• <i>-RL (mm)</i>	0.72
<i>Slice thickness (mm)</i>	3
<i>Slice gap (mm)</i>	3
<i>Reconstruction Voxel Size (mm)</i>	0.449
<i>TR/TE (ms)</i>	4000/99
<i>ACQ matrix M x P (mm)</i>	400x240
<i>Reconstruction voxel MPS (mm)</i>	0.449
<i>Reconstruction matrix</i>	512
<i>Total scan duration</i>	3:28.0

**c) Axial T1W (3mm)**

<i>Coil</i>	<i>SENSE-HEAD-32</i>
<i>Field of View (FOV)</i>	
• <i>AP (mm)</i>	230
• <i>RL (mm)</i>	183
• <i>FH (mm)</i>	154
<i>Voxel size</i>	
• <i>AP (mm)</i>	0.9
• <i>RL (mm)</i>	1.12
<i>Slice thickness (mm)</i>	3
<i>Slice gap (mm)</i>	3
<i>Reconstruction Voxel Size (mm)</i>	0.449
<i>TR/TE (ms)</i>	600/10
<i>ACQ matrix M x P (mm)</i>	256X163
<i>Reconstruction voxel MPS (mm)</i>	0.449
<i>Reconstruction matrix</i>	512
<i>Total scan duration</i>	4:58.8

**d) Coronal Oblique\_T1 IR**

<i>Coil</i>	<i>SENSE-HEAD-32</i>
<i>Field of View (FOV)</i>	
• <i>-AP (mm)</i>	<i>200</i>
• <i>-RL (mm)</i>	<i>209</i>
• <i>-FH (mm)</i>	<i>79</i>
<i>Voxel size</i>	
• <i>-AP (mm)</i>	<i>0.55</i>
• <i>-RL (mm)</i>	<i>0.69</i>
<i>Slice thickness (mm)</i>	<i>3</i>
<i>Slice gap (mm)</i>	<i>3</i>
<i>Reconstruction Voxel Size (mm)</i>	<i>0.537</i>
<i>TR/TE (ms)</i>	<i>2000/800</i>
<i>ACQ matrix M x P (mm)</i>	<i>364x303</i>
<i>Reconstruction voxel MPS (mm)</i>	<i>0.537</i>
<i>Reconstruction matrix</i>	<i>400</i>
<i>Total scan duration</i>	<i>02:18.0</i>

**e) Coronal Oblique\_TSE\_T2**

<i>Coil</i>	<i>SENSE-HEAD-32</i>
<i>Field of View (FOV)</i>	
• <i>AP (mm)</i>	<i>79</i>
• <i>RL (mm)</i>	<i>159</i>
• <i>FH (mm)</i>	<i>200</i>
<i>Voxel size</i>	
• <i>AP (mm)</i>	<i>0.6</i>
• <i>RL (mm)</i>	<i>0.6</i>
<i>Slice thickness (mm)</i>	<i>3</i>
<i>Slice gap (mm)</i>	<i>3</i>
<i>Reconstruction Voxel Size (mm)</i>	<i>0.359</i>
<i>TR/TE (ms)</i>	<i>1987/100</i>
<i>ACQ matrix M x P (mm)</i>	<i>332x264</i>
<i>Reconstruction voxel MPS (mm)</i>	<i>0.359</i>
<i>Reconstruction matrix</i>	<i>560</i>
<i>Total scan duration</i>	<i>01:4:3</i>

**f) Coronal Oblique \_FLAIR**

<i>Coil</i>	<i>SENSE-HEAD-32</i>
<i>Field of View (FOV)</i>	
<ul style="list-style-type: none"> <li>• <i>AP (mm)</i></li> <li>• <i>RL (mm)</i></li> <li>• <i>FH (mm)</i></li> </ul>	<p>79</p> <p>183</p> <p>230</p>
<i>Voxel size</i>	
<ul style="list-style-type: none"> <li>• <i>AP (mm)</i></li> <li>• <i>RL (mm)</i></li> </ul>	<p>0.65</p> <p>0.87</p>
<i>Slice thickness (mm)</i>	3
<i>Slice gap (mm)</i>	3
<i>Reconstruction Voxel Size (mm)</i>	0.449
<i>TR/TE (ms)</i>	11000/125
<i>ACQ matrix M x P (mm)</i>	352x186
<i>Reconstruction voxel MPS (mm)</i>	0.449
<i>Reconstruction matrix</i>	512
<i>Total scan duration</i>	05:08:0

**g) Coronal\_T1W\_3D\_FFE**

<i>Coil</i>	<i>SENSE-HEAD-32</i>
<i>Field of View (FOV)</i>	
<ul style="list-style-type: none"> <li>• <i>-AP (mm)</i></li> <li>• <i>-RL (mm)</i></li> <li>• <i>-FH (mm)</i></li> </ul>	<p>125</p> <p>200</p> <p>240</p>
<i>Voxel size</i>	
<ul style="list-style-type: none"> <li>• <i>-AP (mm)</i></li> <li>• <i>-RL (mm)</i></li> </ul>	<p>0.5</p> <p>1</p>
<i>Reconstruction Voxel Size (mm)</i>	0.375
<i>TR/TE (ms)</i>	25/2.3
<i>ACQ matrix M x P (mm)</i>	240 x200
<i>Reconstruction voxel MPS (mm)</i>	0.375
<i>Reconstruction matrix</i>	640
<i>Total scan duration</i>	03:52:3

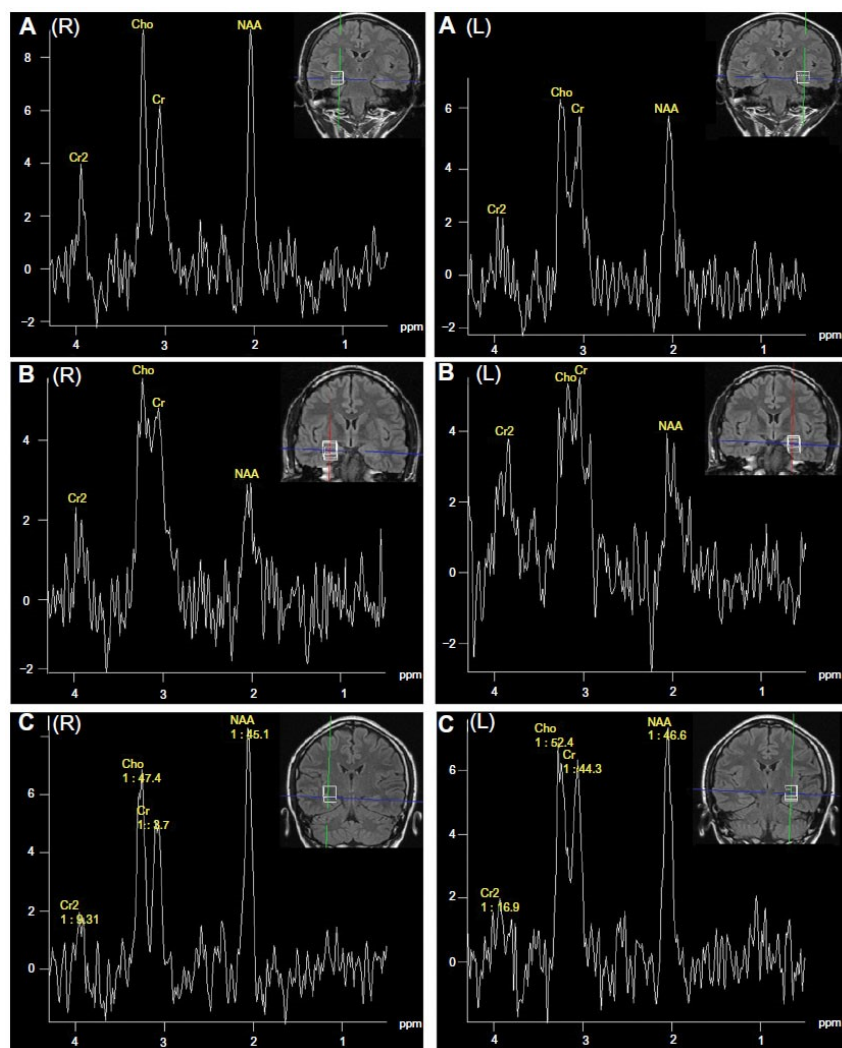
## h) MRS value measurement

Single voxel proton spectroscopy was undertaken by using Philips 3 Tesla Acheiva MR scanner, Best The Netherlands. Examinations were performed with

$^1\text{H}$ -MRS and specific metabolite changes of :

- a) NAA/Cr
- b) NAA/Cho
- c) Naa/Cho+Cr

The voxel of interest focus on the head of hippocampus. Three orthogonal plane sagittal, transerve and coronal T2w image can be used localizer to place the voxel.



## **1.8 WORKSTATION:**

All image processing will be performed using Philips MR Workspace 2.6.3.5 software.

Post-processing MRS data is acquired.

### **Image acquisition of the subjects:**

- Subject will be screened against the inclusion/exclusion criteria. Subjects who agreed to participate will be asked to sign written informed consent forms.
- All subjects will undergo MR imaging at MRI room in the Radiology department, HUSM using Philips 3 Tesla Achieva MR scanner, Best, The Netherlands. All subjects will undergo the same imaging protocol consisting of whole brain Sagittal T1- weighted, Axial T1 and T2-weighted, coronal oblique T1IR, coronal oblique T2, coronal oblique FLAIR, coronal\_T1W\_3D\_FFE and MRS.
- A standard head coil will be used SENSE-HEAD-32

### **Image analysis: MRS**

- All MRS image processing will be performed using Philips MR Workspace 2.6.3.5 software.
- Values will be obtained at the region of interest (right and left hippocampal formation).
- Images will be reviewed and analyzed by the researcher (validation will be performed with radiologist)

### **Sample Size Determination**

- (1) For objective no. 1, sample sizes were calculated with two means formula by using the Power and Sample Size Program.

#### 1.1. MRS

For MRS (NAA/Cho+Cr) value, the difference of the mean between the normal and patients was 0.245 and of the standard deviation ( $\sigma$ ) was 0.06. Total sample size obtained was 4 (normal 1 and abnormal 3) (2).

- (2) For objective no. 2, single mean formula was used.

For MRS value (NAA/Cho+Cr), single mean formula was used. The mean for ipsilateral side was 0.60 and standard deviation was 0.09. The mean for contralateral side was 0.78 and standard deviation was 0.13. Total sample size obtained was 4 (4).

The minimum sample size needed was 4.

### **Statistical analysis**

Independent t test for objective (1). McNemar's test or Kappa statistic for objective (2).

**Data Collection Sheet:**

<b>Serial no</b>	<b>RN</b>	<b>Age</b>	<b>M/F</b>			
<b>Clinical Diagnosis</b>						
<b>EEG</b>						
<b>Conventional features</b>	<b>Right side</b>	<b>Left side</b>				
<b>FLAIR -SIGNALS</b>						
<b>T2-SIGNALS</b>						
<b>MAMMARY BODIES</b>						
<b>FORNIX</b>						
<b>MRS VALUES</b>	<b>H</b>	<b>B</b>	<b>T</b>	<b>H</b>	<b>B</b>	<b>T</b>
<b>NAA/CHO</b>						
<b>NAA/Cr</b>						
<b>NAA/Cho+Cr</b>						

**H-Head of hippocampus**

**B-Body of hippocampus**

**C-Tail of hippocampus**

## Expected Result

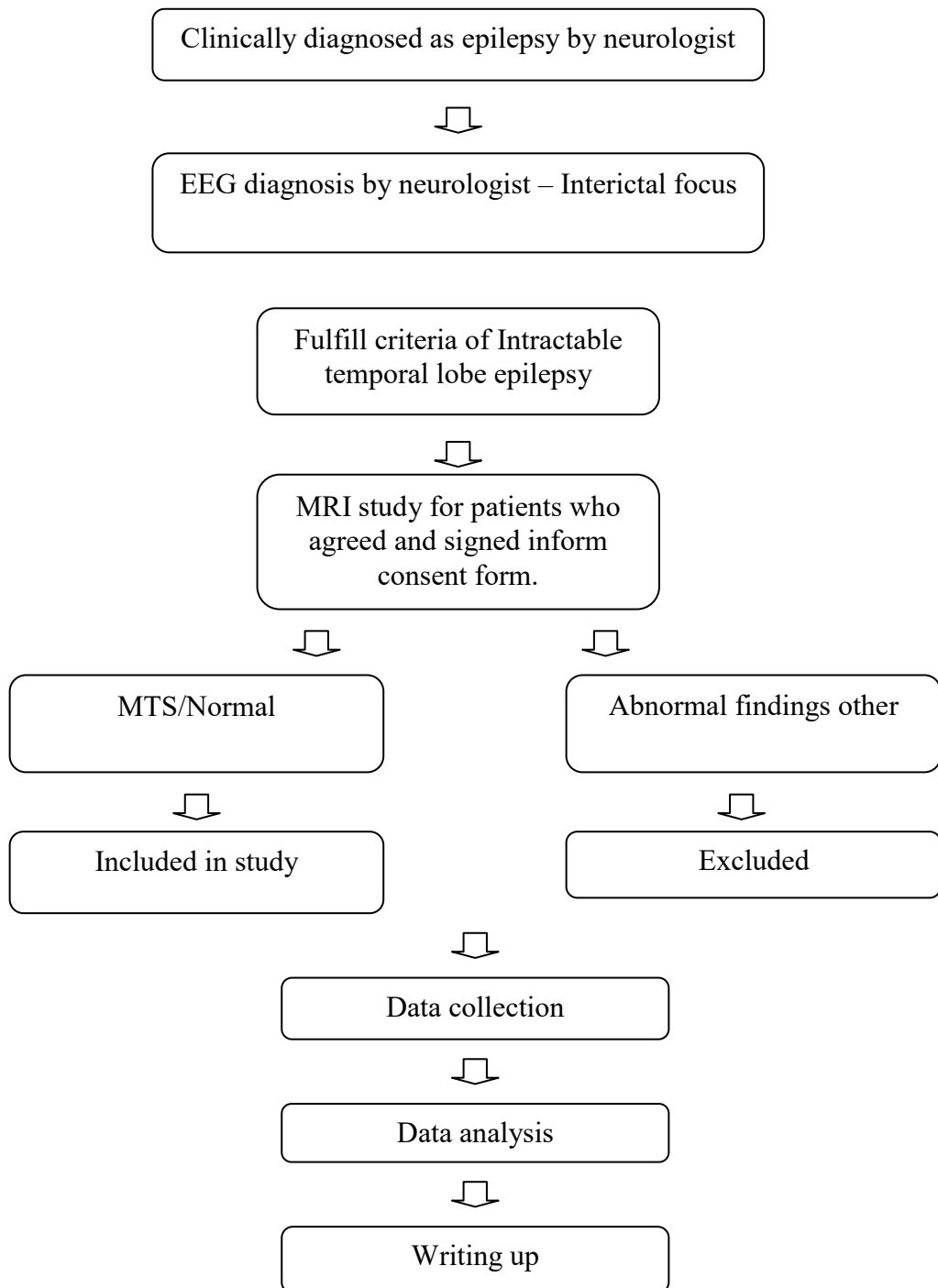
### Metabolite Concentrations and Metabolite Peak Ratios in Patient and Control Subjects

<i>Subjects</i>	<i>Metabolic Peak Ratio</i>		
	<i>NAA(Choline+Creatine)</i>	<i>NAA/Choline</i>	<i>NAA/Creatine</i>
Control subjects			
<b>All patients</b> Ipsilateral hemisphere Contralateral hemisphere			
<b>Patients with MRI positive</b> Ipsilateral hemisphere Contralateral hemisphere			
<b>Patients with MRI negative</b> Ipsilateral hemisphere Contralateral hemisphere			

		<i>MR Spectroscopic Imaging</i>			
		<i>Left vs RT Hemisphere</i>		<i>Patient vs Control Subject</i>	
<i>Patient No/Age/Sex/ Duration of Illness</i>	<i>EEG</i>	<i>NAA(Choline+Creatine)</i>	<i>tNAA</i>	<i>NAA(Choline+Creatine)</i>	<i>tNAA</i>
<b>Patients with hippocampus atrophy (MRI positive)</b>					
<b>Patients without hippocampal atrophy (MRI negative)</b>					
<i>Note -</i>					



## FLOW CHART



## MRI EXAMINATION FLOW CHART

Whole brain Sagittal, Axial, Coronal T1



Temporal lobe series – Coronal Oblique T1 IR,  
T2 TSE, FLAIR



Features of mesial temporal sclerosis or normal  
study.



### MR SPECTROSCOPY

Diffusion tensor imaging sequence

Fractional anisotropy (FA), Tracer D and  
apparent diffusion coefficient values calculation  
at MRI workstation



Calculation of MRS values at MRI workstation.

Whole brain Sagittal, Axial, Coronal T1

### **1.9 EXPECTED OUTCOME:**

**Name of Journal** : AJNR Radiology

**Number of Graduate Student** : 2 M. Sc.

**Miscellaneous** : -

### **1.10 PUBLICATION RELATED TO THIS PROJECT**

1. Win Mar @ Salmah Jalaluddin, Norhasiza MAT JUSOH, Izzat Abdulla Ali BASAHAI, Mohd Shafie ABDULLAH, Ahmad Helmy ABDUL KARIM , Anis Kausar GAZALI. Normalised MRI Volumetry of the Hippocampus among Normal Malay Children and Adolescents. MJMS, vol 20, issue 1 January - March 2013
2. Muhammad Fadli Embong, Ruwaida Yaacob, Mod Shafie Abdullah, Ahmad Helmy Abdul Karim, Anis Kausar Ghazali, Win Mar @ Salmah Jalaluddin. MR volumetry of Hippocampus in Normal Adult Malay of age 50 years old and above. MJMS July 2013 Vol 20, Issue 4
3. Anusha Achuthan, Mandava Rajeswari, and Win Mar @ Salmah Jalaluddin. Hippocampus Localization Guided by Coherent Point Drift Registration Using Assembled Point Set. Hybrid Artificial Intelligent Systems Lecture Notes in Computer Science, 2013, Vol 8073 pp 92-102. DOI 10.1007/978-3-642-40846-5\_10
4. Win Mar Salmah, J. A. Noorfizura, A. Mohd Shafie, Helmy AK, A.R. Salmi, L. Naing. Hippocampal MR Volumetric Studies in Paediatric Patients With Epilepsy and Normal Controls. NRJ (The Neuroradiology Journal) Digital Vol 1, issue 13, 597-604, July 15, 2011

### **1.11 EQUIPMENT & MATERIALS AVAILABLE IN THE UNIVERSITY THAT IS USED FOR THIS**

#### **RESEARCH**

MRI- Philip 3.0 Tesla Achieva MR Scanner, Best, The Netherland

## 1.12 REFERENCE

- Achten E., Santens P., Boon P., De Coo D., Van De Kerckhove T., De Reuck J. et al.: Single-voxel proton MR spectroscopy and positron emission tomography for lateralization of refractory temporal lobe epilepsy. *AJNR Am. J. Neuroradiol.* 1998; 19:1–8.
- Babb T., Brown W.J.: Pathological findings in epilepsy. In: J.Engel Jr. (ed.), *Surgical Treatment of the Epilepsies*. Raven Press, New York 1987, 511–540.
- Baxendale S.A., Van Paesschen W., Thompson P.J., Duncan J.S., Harkness W.F., Shorvon S.D.: Hippocampal cell loss and gliosis: relationship to preoperative and postoperative memory function. *Neuropsychiatry Neuropsychol. Behav. Neurol.*, 1998, 11: 12–21.
- Bronen R.A., Cheung G., Charles J.T., Kim J.H., Spencer D.D., Spencer S.S. et al.: Imaging findings in hippocampal sclerosis: correlation with pathology. *AJNR Am. J. Neuroradiol.*, 1991, 12: 933–940.
- Bruton C.J.: *The Neuropathology of Temporal Lobe Epilepsy*. Oxford University Press, Oxford 1988, 1–158.
- Chelune G.J.: Hippocampal adequacy versus functional reserve: predicting memory functions following temporal lobectomy. *Arch. Clin. Neuropsychol.*, 1995, 10: 413–432.
- Cendes F., Andermann F., Dubeau F., Matthews P.M., Arnold D.L.: Normalization of neuronal metabolic dysfunction after surgery for temporal lobe epilepsy. Evidence from proton MR spectroscopic imaging. *Neurology*, 1997, 49: 1525–1533.
- Cendes F., Caramanos Z., Andermann F., Dubeau F., Arnold D.L.: Proton magnetic resonance spectroscopic imaging and magnetic resonance imaging volumetry in the lateralization of temporal lobe epilepsy: a series of 100 patients. *Ann. Neurol.*, 1997, 42: 737–746.