

Spring 5-17-2019

The Change of Alveolar Bone Thickness on Mandibular Central Incisors of Skeletal Class II Patients After Orthodontic Treatment Using Cone-Beam Computed Tomography.

Kensuke Matsumoto

University of Pennsylvania, mkensuke@upenn.edu

Scott Sherrill-Mix

University of Pennsylvania, sherrillmix@gmail.com

Normand Boucher

University of Pennsylvania, boucherortho@gmail.com

Nipul Tanna

University of Pennsylvania, nipul77@upenn.edu

Follow this and additional works at: https://repository.upenn.edu/dental_theses

Part of the [Orthodontics and Orthodontology Commons](#), and the [Periodontics and Periodontology Commons](#)

Recommended Citation

Matsumoto, Kensuke; Sherrill-Mix, Scott; Boucher, Normand; and Tanna, Nipul, "The Change of Alveolar Bone Thickness on Mandibular Central Incisors of Skeletal Class II Patients After Orthodontic Treatment Using Cone-Beam Computed Tomography." (2019). *Dental Theses*. 38.

https://repository.upenn.edu/dental_theses/38

This paper is posted at Scholarly Commons. https://repository.upenn.edu/dental_theses/38

For more information, please contact repository@pobox.upenn.edu.

The Change of Alveolar Bone Thickness on Mandibular Central Incisors of Skeletal Class II Patients After Orthodontic Treatment Using Cone-Beam Computed Tomography.

Abstract

Objective: To test the null hypothesis that orthodontic tooth movement does not create dehiscences and the sagittal width dimension of alveolar bone is maintained. **Materials and Methods:** In 60 skeletal class II patients, CBCT images at pre- (T1) and post-orthodontic treatment (T2) were obtained and the presence of dehiscences was recorded. Based on the presence of dehiscences at T1 and T2, the patients were divided into four groups. The alveolar bone thickness at the level of 2 (CEJ2), 5 (CEJ5), 10 (CEJ10), and 15 (CEJ15) mm from the cemento-enamel junction (CEJ) was measured on CBCT images in cross section along the long axis on the central incisors. CBCT-synthesized lateral cephalometric images were analyzed. Statistical analysis and the Pearson correlation analyses were utilized at a p . **Results:** CBCT imaging showed that 27.1% of the mandibular central incisors had dehiscences at T1. With pre-existing dehiscence, the incidence of dehiscence increased to 50% at T2. Patients that developed dehiscences after orthodontic treatment showed the highest percentage of alveolar bone loss (-23.7% at CEJ2, -19.9% at CEJ5 at T2). In the group where patients developed dehiscences after orthodontic treatment, there was statistically significant mean increase of L1-NB (3.1mm) and IMPA (9.8°) (p). **Conclusions:** When camouflaging skeletal Class II patients, the limits of mandibular anterior incisor forward movement might be less than previously thought. In order to prevent the development of inadvertent dehiscences during the orthodontic treatment, careful diagnosis with CBCT images is recommended. Furthermore, when excessive protrusion and/or proclination is planned, additional treatment modalities such as orthognathic surgery, tooth extraction, and partial corticotomy with bone grafting should be considered.

Degree Type

Thesis

Degree Name

MSOB (Master of Science in Oral Biology)

Primary Advisor

Normand Boucher, DDS

Keywords

Skeletal Class II, CBCT

Subject Categories

Dentistry | Orthodontics and Orthodontology | Periodontics and Periodontology



The change of alveolar bone thickness on mandibular central incisors of skeletal Class II patients after orthodontic treatment using cone-beam computed tomography.

Kensuke Matsumoto, DMD (mkensuke@upenn.edu)

A dissertation in Periodontics and Orthodontics
Presented to the faculty of Penn Dental Medicine in fulfillment of the requirements for the
Degree of Master of Science in Oral Biology
in 2019

Master's Thesis Committee:

Normand Boucher, DDS (Advisor)

Clinical associate professor of orthodontics
Department of Orthodontics

Nipul K. Tanna, DMD, MS

Clinical assistant professor of orthodontics
Director of Postdoctoral Periodontics/Orthodontics program
Department of Orthodontics

Jonathan Korostoff, DMD, PhD

Professor of periodontics
Director, Master of Science in Oral Biology program
Department of Periodontics

Francis K. Mante, BDS, MS, PhD, DMD, MA (Hon)

Associate professor
Director of biomaterials
Division of Restorative Dentistry

Statistician:

Scott Sherrill-Mix, PhD

Department of Microbiology

ACKNOWLEDGMENT

I would like to express my sincere appreciation to my adviser and mentor, Dr. Boucher. You gave me the opportunity to work with you and throughout my residency along with contributing research. Your leadership and passion in our specialty inspired me.

Thank you, Dr. Sherrill-Mix, not only for your statistic inputs but also your professional attitude and guidance, without your support this project would not have been completed.

I would like to thank Dr. Tanna for your endless support and mentorship for six years. Your professionalism provided a role model that continually motivated me.

Thank you Dr. Korostoff for sharing your great insights and deep thoughts.

Thank you Dr. Mante for your time, effort, and encouragement.

I also would like to thank Dr. Chung and Dr. Hangorsky for your continuous support and encouragement.

Lastly, I would like to thank my family and friends for your unconditional love, support, and understanding throughout my life.

This research is dedicated to the memories of Dr. Vanarsdall and Dr. Teles.

The change of alveolar bone thickness on mandibular central incisors of skeletal Class II patients after orthodontic treatment using cone-beam computed tomography.

Abstract:

Objective: To test the null hypothesis that orthodontic tooth movement does not create dehiscences and the sagittal width dimension of alveolar bone is maintained.

Materials and Methods: In 60 skeletal class II patients, CBCT images at pre- (T1) and post-orthodontic treatment (T2) were obtained and the presence of dehiscences was recorded. Based on the presence of dehiscences at T1 and T2, the patients were divided into four groups. The alveolar bone thickness at the level of 2 (CEJ2), 5 (CEJ5), 10 (CEJ10), and 15 (CEJ15) mm from the cemento-enamel junction (CEJ) was measured on CBCT images in cross section along the long axis on the central incisors. CBCT-synthesized lateral cephalometric images were analyzed. Statistical analysis and the Pearson correlation analyses were utilized at a $p < .05$ significance level.

Results: CBCT imaging showed that 27.1% of the mandibular central incisors had dehiscences at T1. With pre-existing dehiscence, the incidence of dehiscence increased to 50% at T2. Patients that developed dehiscences after orthodontic treatment showed the highest percentage of alveolar bone loss (-23.7% at CEJ2, -19.9% at CEJ5 at T2). In the group where patients developed dehiscences after orthodontic treatment, there was statistically significant mean increase of L1-NB (3.1mm) and IMPA (9.8°) ($p < .001$). Based upon logistic regression analyses, for each 1mm change in L1-NB at CEJ2, the width of the alveolar process decreases by 0.25mm. Similarly, for each 1° degree change in IMPA at CEJ2, the width decreases by 0.07mm.

Conclusions: When camouflaging skeletal Class II patients, the limits of mandibular anterior incisor forward movement might be less than previously thought. In order to prevent the development of inadvertent dehiscences during the orthodontic treatment, careful diagnosis with CBCT images is recommended. Furthermore, when excessive protrusion and/or proclination is planned, additional treatment modalities such as

orthognathic surgery, tooth extraction, and partial corticotomy with bone grafting should be considered.

Introduction:

Proffit and Ackerman¹ addressed to the challenge of our understanding of the limitation of tooth movement with a widely accepted diagram of the “envelope of discrepancy” (**Fig.1**). They estimated that with conventional orthodontic treatment the limits of extrusion, retraction, intrusion, and protraction of mandibular incisors are: 2 mm, 3 mm, 4 mm, and 5 mm, respectively. These parameters were anecdotally determined by the anatomical boundaries of the alveolar bone width. According to Wennström et al.,² following extensive bodily movement of incisors in a labial direction through the alveolar bone, most teeth clinically demonstrated some apical displacement of the gingival margin. Karring et al.³ concluded that dehiscences can be produced in the alveolar bone by tipping teeth in facial direction and such tooth movements are not necessarily accompanied by loss of connective tissue attachment. Advocates of the “compensatory bone formation” theory of tooth movement claim that when teeth are moved labially and pass the original cortical plate the alveolar bone thickness is maintained or increased due to bone apposition around the roots. Steiner et al.⁴ and Wingard and Bowers⁵ reported conflicting results. In monkey studies the former reported dehiscences whereas the latter reported no dehiscences with forward movements of the roots.

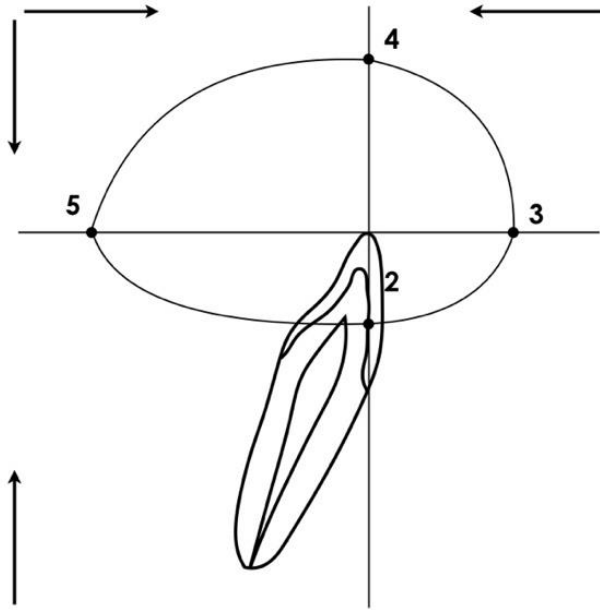


Fig.1 The envelope of discrepancy for mandibular arch.

Recently, cone beam computed tomography (CBCT) imaging has enhanced our ability to evaluate the morphology of the craniofacial and dentoalveolar complex. It allows the quantitative assessment of the dimensions of alveolar bone which could not be evaluated in two-dimensional images due to the superimposition of anatomical structures. According to Fuhrmann et al.,⁶ there is a general overestimation of the symphyseal labiolingual bone width on two-dimensional lateral cephalograms when compared with physical measurements of the actual specimens. Over 80% of defects identifiable in CBCT images were not readily visible on the two-dimensional lateral cephalograms.

Dehiscence and fenestration during orthodontic treatment may occur due to several reasons including but not limited to the direction of tooth movement, the magnitude of orthodontic force, the amount of tooth movement, the dimensions of alveolar bone, and anatomic integrity of periodontal tissues.^{7,8} To minimize these problems, the alveolar bone morphology must be evaluated before orthodontic

treatment as part of diagnosis. CBCT imaging has been shown to be an excellent modality in assessing bone topography and anatomy.⁶ Taking the presence of pre-existing dehiscences and fenestrations⁹⁻¹² into consideration in a comprehensive treatment plan reduces the risk of future attachment loss, especially when teeth are moved in a labiolingual/buccolingual direction.¹³⁻¹⁶ It has also been shown that the presence of a dehiscence or fenestration in the alveolar bone is not pathognomonic for gingival recession, but is a potential risk for exacerbating gingival recession.^{11,17,18} The risk for development of recessions in conjunction with orthodontic tooth movement is present only if the tooth has been moved out of the alveolar bone housing; that is, when an alveolar bone dehiscence has been created.⁷ Conversely, gingival recession is simply a clinical manifestation of an underlying alveolar bone deficiency. Should gingival recessions be a part of the limitation of tooth movement? Is it preferable to evaluate alveolar bone deficiency to determine the limits of tooth movement?

The purpose of this study is to evaluate the presence of dehiscences and the change of alveolar bone thickness on mandibular central incisors in skeletal Class II patients between pre- and post-orthodontic treatment in CBCT images.

Null hypothesis:

Orthodontic tooth movement does not create dehiscences and the sagittal width dimension of alveolar bone is maintained.

Material and methods:

Patients

A total of 60 patients (23 males and 37 females, Caucasian or Asian), with a diagnosis as a skeletal Class II malocclusion from a private practice (West Chester, PA) were enrolled in this study. All cases were treated by the same orthodontist (N.B.) and finished between June 1st of 2015 to May 31st of 2017. The study was performed with the approval of the institutional review board of University of Pennsylvania (Protocol Number 827961). The inclusion criteria were the followings: 1) CBCT data available between ages 8 and 20, 2) skeletal Class II (ANB>3°) as determined from CBCT synthesized cephalograms at pre-orthodontic treatment: T1, 3) Angle Class II (Full-step or End-to-end) molar relationship at least on one side at T1, 4) Angle Class I molar relationships at the end of orthodontic treatment: T2, 5) non-extraction cases, 6) minimum rotation and crowding on mandibular central incisors, 7) healthy, and 8) no history of orthodontic treatment. Exclusion criteria were severe dental crowding, endodontically treated teeth, restored teeth, teeth with attachment loss, keratinized tissue width less than 2 mm, and systemically compromised patients. Based upon the presence of dehiscences in CBCT images, patients were divided into four groups. There were dehiscences at both pre- and post-orthodontic treatments (Group 1). No dehiscences were found at the pre-orthodontics and dehiscences developed at the post-orthodontics (Group 2). No dehiscences were found at both pre- and post-orthodontic treatments (Group 3). Lastly, dehiscences were found at the pre-orthodontics and no dehiscences were found at the post-orthodontics (Group 4).

CBCT Evaluation

For each patient, two sets CBCT scans were taken at T1 and T2. T2 was taken 3 months after the tooth movement of central incisors was completed. Patients were scanned in the natural head position with maximum intercuspation using an iCAT scanner (Imaging Science International, Hatfield, PA). Images were obtained at a scan time of 9.6 seconds, 5 mA, 120 KVp, and 0.3-mm voxel size. The digital files (Digital Imaging and Communications in Medicine) of each CBCT scan were exported into Dolphin Imaging software version 11.9.7.20 (Patterson Dental Supply, St. Paul, MN) and 3D images were reconstructed for analysis. Cross-sectional slices through the two mandibular central incisors in the 60 patients were generated to show labial and lingual surfaces of the total 120 central incisors. The slices were generated at the putative midline of long axis labiolingually on each tooth and reconstructed with 2.0-mm slice thickness.

Measurements

The following measurements on the 60 sets of CBCT synthesized lateral cephalogram were analyzed at T1 and T2: 1) SNA ($^{\circ}$), 2) SNB ($^{\circ}$), 3) ANB ($^{\circ}$), 4) MP-SN ($^{\circ}$), 5) FMA ($^{\circ}$), 6) L1-NB (mm), and 7) IMPA ($^{\circ}$). One operator traced and measured the entire sample of cephalometric analyses.

The alveolar bone thickness (ABT) at the level of 2 (CEJ2), 5 (CEJ5), 10 (CEJ10), and 15 (CEJ15) mm from the cemento-enamel junction (CEJ) was measured on CBCT images in cross section along the long axis on the central incisors. (**Fig.2**).

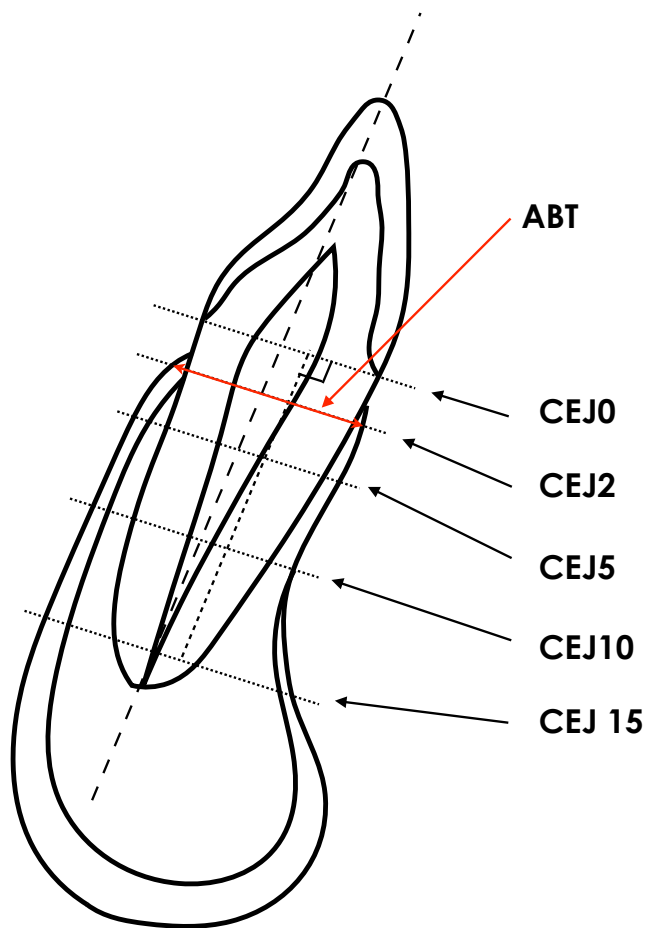


Fig.2 Illustrations of reference points, lines and measurement variables used for mandibular central incisors. CEJ0; cross section line on the CEJ, CEJ2; cross section 2mm below CEJ, CEJ5; cross section 5mm below the CEJ, CEJ10; cross section 10mm below the CEJ, and CEJ15; cross section 15mm below the CEJ

A dehiscence was identified when there was no cortical bone on the labial surface in at least three sagittal views and the alveolar bone height (ABH) was more than 2 mm from the cemento enamel junction.¹⁹ A CEJ-to-AC measurement ≤ 2 mm was normal on the basis of previous studies that found the distance from the CEJ to AC to range from 0 to 2 mm in persons with no history or signs of periodontal disease.^{8,19,21} All measurements were determined on both central incisors and the mean of the two was used for further analysis.

Two examiners were calibrated for the measurements of alveolar bone on the CBCT images and synthesized cephalograms, using the same computer and screen (resolution of 1920 x1080 pixels) under the same lighting conditions. To evaluate the reliability of the linear measurements, 10 patients were randomly selected from the total sample. Intraoperator reliability was determined twice at an interval of two weeks. Interoperator reliability was determined between two operators. Variation was minimal in repeated measurements within the same operator with a mean absolute difference of 0.24 (95% CI: 0.18 - 0.29) and Pearson correlation: $r=0.93$ (95% CI: 0.82 - 0.97) for the alveolar bone width. Between operators, a mean absolute difference was 0.29 (95% CI: 0.15 - 0.43) and Pearson correlation (r) was 0.92 (95% CI: 0.68 - 0.98).

Statistics

Paired t -tests were used to evaluate differences between pre- and post-treatment measurements of ABT, and cephalometric analysis. Two sample t -tests were used at a $p=.05$ significance level. Additionally, logistic regression analyses were applied in order to assess associations between tooth movements and the risk of alveolar bone loss in the sagittal direction.

Results:

Eleven patients (four males and seven females) were removed from the subjects due to the lack of adequate quality of the CBCT images for the evaluation. The mean ages of patients were 11.23 (SD=1.59) years at pre-orthodontic treatment (T1) and 14.48 (SD=1.20) years at post-orthodontic treatment (T2) in **Table I**. There were no significant differences between male and female groups ($p > .05$).

Table I. Age of subjects

Age (years)	Male (N=19)		Female (N=29)		Total (N=48)		<i>p-value</i>	Significance
	Mean	SD	Mean	SD	Mean	SD		
T1	11.5	1.90	11.0	1.35	11.2	1.59	0.335	N.S.
T2	14.8	1.54	14.2	0.87	14.5	1.20	0.134	N.S.
T2-T1	3.3	0.95	3.2	1.29	3.25	1.16	0.738	N.S.

The results of the lateral cephalometric measurements were listed in **Table II** and showed that no skeletal or dental variations were found between males and females ($p > .05$) except for MP-SN ($^{\circ}$) change ($p < .05$).

Table II. Cephalometric analysis

Measurement	Male (N=19)		Female (N=29)		Total (N=48)		p-value	Significance	
	Mean	SD	Mean	SD	Mean	SD			
SNA (°)	T1	81.9	3.61	81.0	2.91	81.34	3.20	0.3988	N.S.
	T2	81.9	3.21	80.7	3.01	81.2	3.12	0.2061	N.S.
	T2-T1	0.02	1.68	-0.32	1.38	-0.19	1.50	0.4611	N.S.
SNB (°)	T1	77.0	2.92	76.5	2.47	76.7	2.64	0.5291	N.S.
	T2	78.2	2.53	76.9	2.88	77.4	2.80	0.0907	N.S.
	T2-T1	1.25	1.38	0.40	1.51	0.74	1.50	0.0515	N.S.
ANB (°)	T1	4.9	1.62	4.6	1.25	4.7	1.40	0.4129	N.S.
	T2	3.6	1.89	3.8	1.51	3.7	1.65	0.7489	N.S.
	T2-T1	-1.29	1.07	-0.77	1.09	-0.98	1.10	0.1039	N.S.
MP-SN (°)	T1	32.0	4.73	32.2	5.00	32.1	4.84	0.8637	N.S.
	T2	30.4	5.36	32.2	6.28	31.5	5.94	0.2913	N.S.
	T2-T1	-1.64	1.53	-0.08	3.09	-0.70	2.68	0.0255	*
FMA (°)	T1	24.2	4.92	24.0	4.37	24.1	4.55	0.8494	N.S.
	T2	22.7	5.53	23.8	5.40	23.4	5.42	0.5116	N.S.
	T2-T1	-1.49	1.39	-0.20	3.08	-0.71	2.61	0.0549	N.S.
L1-NB (mm)	T1	3.73	2.15	3.62	1.39	3.7	1.71	0.8436	N.S.
	T2	4.81	2.77	4.81	2.00	4.8	2.30	0.9961	N.S.
	T2-T1	1.08	1.96	1.19	1.59	1.14	1.72	0.8429	N.S.
IMPA (°)	T1	90.9	5.49	91.2	5.91	91.1	5.69	0.8722	N.S.
	T2	96.4	5.10	95.5	6.84	95.9	6.17	0.6060	N.S.
	T2-T1	5.53	5.34	4.38	4.39	4.83	4.77	0.4412	N.S.

* P=.05

There were not statistically significant differences between males and females regarding the ABT at each level of the CEJ at T1 and T2. The mean value of ABT in mandibular central incisors at CEJ 2 was 6.01 (SD=0.58) mm at T1 resulted in 5.42 (SD=0.70) mm at T2. The mean change of ABT at the CEJ2 was -0.59 (SD=0.55) mm and -0.82 (SD=0.57) mm at the CEJ5 in all groups, respectively. While the ABT decreased more in males at CEJ5 and 15 compared with females (**Table III**), both *p*-values were greater than 0.03 and thus would not survive correction for multiple comparisons.

Table III. The change of alveolar bone thickness at each level of the tooth

Alveolar bone thickness		Male (N=19)		Female (N=29)		Total (N=48)		<i>p</i> -value	Significance
		Mean	SD	Mean	SD	Mean	SD		
CEJ 2 (mm)	T1	6.07	0.71	5.97	0.48	6.01	0.58	0.6049	N.S.
	T2	5.41	0.64	5.43	0.74	5.42	0.70	0.9125	N.S.
	T2-T1	-0.66	0.60	-0.54	0.52	-0.59	0.55	0.4803	N.S.
CEJ 5 (mm)	T1	6.79	0.70	6.67	0.78	6.72	0.75	0.5847	N.S.
	T2	5.81	0.76	5.99	0.89	5.92	0.84	0.4575	N.S.
	T2-T1	-1.02	0.55	-0.68	0.55	-0.82	0.57	0.0399	*
CEJ 10 (mm)	T1	8.74	1.33	8.87	1.95	8.81	1.71	0.7867	N.S.
	T2	7.43	1.75	8.11	2.48	7.84	2.22	0.2776	N.S.
	T2-T1	-1.30	0.88	-0.76	0.99	-0.98	0.98	0.0542	N.S.
CEJ 15 (mm)	T1	11.63	1.86	12.95	2.22	11.45	2.07	0.6180	N.S.
	T2	10.26	1.94	12.90	3.16	10.68	2.74	0.3523	N.S.
	T2-T1	-1.37	1.63	-0.05	1.35	-0.77	1.53	0.0349	*

* *P*=.05

The prevalence of dehiscence was shown in **Table IV**. 31.6% of teeth in males, and 24.1% of teeth in females had dehiscences at T1. The prevalence of dehiscences increased to 57.9% in males and 44.8% in females at T2. Consequently, for the entire sample the presence of dehiscences increased from 22.9% to 50.0% as a result of treatment.

Table IV. The prevalence of dehiscences in central incisors

Dehiscence	Male (n=38)				Female (n=58)				Total (n=96)			
	T1		T2		T1		T2		T1		T2	
	(n)	(%)	(n)	(%)	(n)	(%)	(n)	(%)	(n)	(%)	(n)	(%)
Present	12	31.6	22	57.9	14	24.1	26	44.8	26	27.1	48	50.0
Absent	26	68.4	16	42.1	44	75.9	32	55.2	70	72.9	48	50.0

The patients were divided into four groups based upon the presence of dehiscences between T1 and T2, and each group was compared with the others (**Table V**). No patients classified into Group 4 were identified; therefore, no Group 4 results were included in **Table V**.

Comparing Groups 2 and 3, statistically significant alveolar bone reduction occurred at CEJ2 (-1.47 vs -0.30 mm, $p < .001$) and at CEJ5 (-1.34 vs -0.70 mm, $p < .05$) after the orthodontic treatment. Group 2 exhibited the highest percentage of alveolar bone loss (-23.7% at CEJ2, -19.9% at CEJ5 at the end of the treatment). By contrast, there were not significant differences at CEJ10 and 15 between the groups.

Table V. Cephalometric and CBCT characteristics

Group	Group 1: N=13		Group 2: N=11		Group 3: N=24		G1 vs G2		G2 vs G3		G1 vs G3		
	Mean	SD	Mean	SD	Mean	SD	p-value	significance	p-value	significance	p-value	Significance	
Age (year)	Start	11.6	0.87	10.9	2.70	11.2	1.20	0.42177	N.S.	0.76716	N.S.	0.20183	N.S.
	Finish	14.5	0.97	14.7	1.90	14.4	0.92	0.68109	N.S.	0.57036	N.S.	0.79412	N.S.
CEJ 2 (mm)	T1	5.8	0.60	6.2	0.61	6.1	0.52	0.07600	N.S.	0.46129	N.S.	0.13832	N.S.
	T2	5.4	0.65	4.7	0.58	5.8	0.54	0.01835	*	0.00012	***	0.09125	N.S.
	T2-T1	-0.4	0.21	-1.5	0.33	-0.3	0.23	0.00000	****	0.00000	****	0.37174	N.S.
		(-6.5%)	3.75	(-23.7%)	4.91	(-5.0%)	3.65	0.00000	****	0.00000	****	0.24932	N.S.
CEJ 5 (mm)	T1	6.6	0.65	6.7	0.78	6.8	0.80	0.75255	N.S.	0.70790	N.S.	0.40784	N.S.
	T2	6.0	0.67	5.4	0.78	6.1	0.85	0.03880	*	0.01396	*	0.62931	N.S.
	T2-T1	-0.6	0.37	-1.3	0.66	-0.7	0.48	0.00422	**	0.01112	*	0.42397	N.S.
		(-8.8%)	5.58	(-19.9%)	9.19	(-10.2%)	6.69	0.00306	**	0.00678	**	0.51319	N.S.
CEJ 10 (mm)	T1	8.8	1.06	8.4	1.30	9.1	2.13	0.42569	N.S.	0.24948	N.S.	0.58541	N.S.
	T2	7.9	1.93	7.0	1.75	8.2	2.52	0.23073	N.S.	0.12723	N.S.	0.75473	N.S.
	T2-T1	-0.8	1.24	-1.4	1.03	-0.9	0.78	0.26624	N.S.	0.19447	N.S.	0.88740	N.S.
		(-10.2%)	13.87	(-16.6%)	12.64	(-10.8%)	9.53	0.24614	N.S.	0.19263	N.S.	0.88818	N.S.
CEJ 15 (mm)	T1	10.9	1.31	11.2	1.75	11.9	2.48	0.65449	N.S.	0.36432	N.S.	0.13033	N.S.
	T2	10.8	2.34	10.0	2.62	11.0	3.03	0.43736	N.S.	0.32825	N.S.	0.83086	N.S.
	T2-T1	-0.1	1.45	-1.2	1.76	-0.9	1.41	0.11483	N.S.	0.59195	N.S.	0.13219	N.S.
		(-1.8%)	12.62	(-11.5%)	14.77	(-8.3%)	11.15	0.10229	N.S.	0.53105	N.S.	0.13420	N.S.
SNA (°)	T1	82.3	3.14	80.8	1.97	81.1	3.64	0.15520	N.S.	0.75940	N.S.	0.27917	N.S.
	T2	82.1	3.44	80.8	2.67	80.8	3.14	0.31396	N.S.	0.95290	N.S.	0.25308	N.S.
	T2-T1	-0.2	1.66	0.1	1.94	-0.3	1.21	0.71933	N.S.	0.58445	N.S.	0.87415	N.S.
		77.2	2.47	75.8	1.77	76.8	3.03	0.11976	N.S.	0.24420	N.S.	0.63963	N.S.
SNB (°)	T1	77.7	2.44	76.3	2.34	77.7	3.13	0.17760	N.S.	0.15327	N.S.	0.96816	N.S.
	T2	77.7	2.44	76.3	2.34	77.7	3.13	0.17760	N.S.	0.15327	N.S.	0.96816	N.S.
	T2-T1	0.5	1.51	0.5	1.78	1.0	1.40	0.94894	N.S.	0.48872	N.S.	0.35848	N.S.
		5.1	1.26	5.1	1.77	4.3	1.22	0.91918	N.S.	0.22006	N.S.	0.06759	N.S.
ANB (°)	T1	5.1	1.26	5.1	1.77	4.3	1.22	0.91918	N.S.	0.22006	N.S.	0.06759	N.S.
	T2	4.4	1.66	4.5	1.94	3.0	1.23	0.94890	N.S.	0.04147	*	0.01644	*
	T2-T1	-0.7	1.00	-0.6	0.84	-1.3	1.21	0.76428	N.S.	0.06872	N.S.	0.14428	N.S.
		31.5	3.66	33.8	3.69	31.8	5.78	0.14190	N.S.	0.22370	N.S.	0.85746	N.S.
MP-SN (°)	T1	30.3	4.33	34.3	4.46	30.8	6.97	0.03544	*	0.07801	N.S.	0.79895	N.S.
	T2	30.3	4.33	34.3	4.46	30.8	6.97	0.03544	*	0.07801	N.S.	0.79895	N.S.
	T2-T1	-1.2	1.89	0.5	3.08	-1.0	2.78	0.12239	N.S.	0.17329	N.S.	0.80088	N.S.
		23.6	4.02	25.6	4.35	23.6	4.91	0.25672	N.S.	0.24130	N.S.	0.98901	N.S.
FMA (°)	T1	22.3	5.18	26.3	4.84	22.6	5.51	0.05996	N.S.	0.05625	N.S.	0.84993	N.S.
	T2	22.3	5.18	26.3	4.84	22.6	5.51	0.05996	N.S.	0.05625	N.S.	0.84993	N.S.
	T2-T1	-1.3	2.20	0.6	2.84	-1.0	2.60	0.08119	N.S.	0.12777	N.S.	0.68778	N.S.
		3.8	1.96	3.8	1.45	3.5	1.74	0.97787	N.S.	0.69138	N.S.	0.70794	N.S.
L1-NB (mm)	T1	4.6	2.27	6.9	1.82	3.9	1.96	0.01336	*	0.00028	***	0.35508	N.S.
	T2	4.6	2.27	6.9	1.82	3.9	1.96	0.01336	*	0.00028	***	0.35508	N.S.
	T2-T1	0.9	1.62	3.1	1.46	0.4	1.13	0.00160	**	0.00005	****	0.37530	N.S.
		91.1	4.07	89.5	6.34	91.8	6.20	0.47877	N.S.	0.33087	N.S.	0.69083	N.S.
IMPA (°)	T1	94.9	4.39	99.2	5.59	94.9	6.87	0.04893	*	0.06234	N.S.	0.96258	N.S.
	T2	94.9	4.39	99.2	5.59	94.9	6.87	0.04893	*	0.06234	N.S.	0.96258	N.S.
	T2-T1	3.7	4.36	9.8	2.83	3.2	4.20	0.00054	***	0.00001	****	0.69342	N.S.

* P=0.05; ** P=0.01; *** P=0.001; **** P<0.0001

There were four parameters (L1-NB, IMPA, ANB and MP-SN) on the cephalometrics that differed significantly between the subgroups (**Table V**). In Group 2, the changes of L1-NB (mm) significantly increased 3.1 mm compared with Group 1 (0.9 mm) and Group 3 (0.4 mm), respectively ($p<.01$). There was a statistically significant increase of IMPA (9.78°) in Group 2, and IMPA was less than 4° in Groups 1 and 3 ($p<.001$). The other two parameters that had significantly differences were the higher reduction of ANB ($^\circ$) in Group 3 than Groups 1 and 2 at T2, and the higher increase of MP-SN ($^\circ$) in Group 2 compared with Group 1.

Based on the data, there is a significant association between CEJ2 and L1-NB/IMPA. A simple linear relationship between these two variables would predict that for each 1mm change in L1-NB CEJ2 decreases by 0.25mm (95% CI: 0.17-0.34, **Fig.3**) or for each 1° degree change in IMPA CEJ2 decreases by 0.07mm (95% CI: 0.04 – 0.11mm, **Fig.4**).

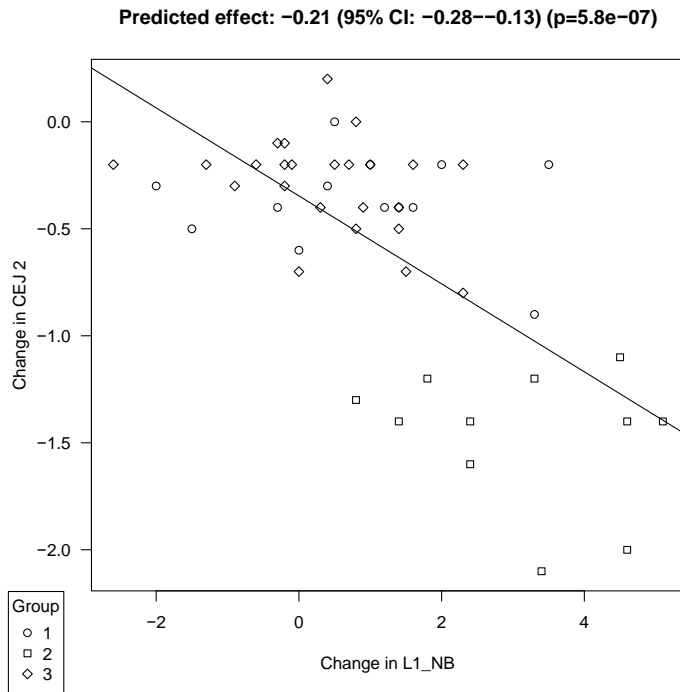


Fig.3 A linear regression analysis between the alveolar bone thickness change in CEJ2 and L1-NB change.

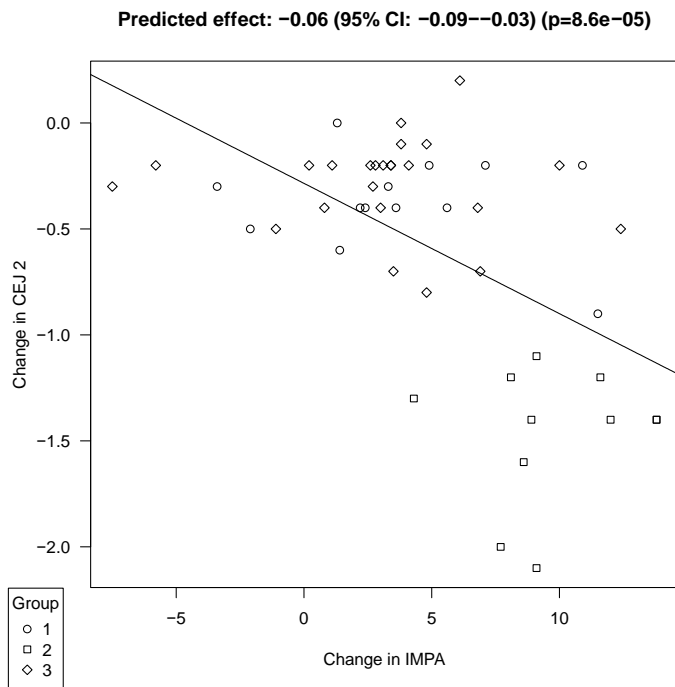


Fig.4 A linear regression analysis between the alveolar bone thickness change in

CEJ2 and IMPA change.

Discussion:

The etiology of dehiscence and fenestration during orthodontic treatment is multifactorial and includes the direction of tooth movement, the magnitude of orthodontic forces, the amount of tooth movement, the dimensions of alveolar bone, and anatomic integrity of periodontal tissues.^{7,8} Anatomically, the alveolar bone becomes thinner from the posterior to the anterior region in the mandible.²⁵ Therefore, in the area of the mandibular symphysis, the direction and amount of tooth movement can easily violate the biologic limits of the alveolar process. Due to overlapping anatomic structures viewed in two dimensional lateral cephalograms, a qualitative assessment of the mandibular symphysis is not possible. On the other hand, the advent of CBCT imaging provides an excellent diagnostic modality to critically evaluate this area. Menezes et al²⁶ found excellent interexaminer and intraexaminer reproducibility of buccal and lingual bone plate thickness measurements in CBCT images on dried human mandibles and demonstrated good precision for voxel dimensions of 0.2, 0.3, and 0.4 mm. However, Leung et al.²⁷ reported that direct assessment of dry skulls with CBCT lacks the image of the periodontal apparatus; thus, it may result in system errors. To resolve this discrepancy, Timock et al.²⁸ compared CBCT and direct measurements on cadavers for buccal bone thickness. Mean absolute errors between CBCT and direct measurements of buccal bone thickness were small (0.13 mm) and showed no statistically significant differences or bias to underestimate or overestimate. Interoperator and intraoperator reliabilities had great agreement for CBCT measurements of buccal bone thickness 0.90. In a human clinical study,²⁹ both the sensitivity and specificity of CBCT for dehiscences was over 0.7 (voxel size of 0.125 mm), and the author concluded that the CBCT method might overestimate the actual measurements. In our study, an

0.3-mm voxel size was selected due to the balance of the amount of radiation exposure and clinical relevance. The measurements of ABT at each level from the CEJ (CEJ2-15) may be accurate. Yet, the sensitivity might not be as high as the specificity.

The results showed that 31.6% of males, 24.1% of females, and 27.1% of the mandibular central incisors in total had dehiscence at T1. The presence of dehiscence increased to 57.9% in males and 44.8% in females at T2. Consequently, the presence of dehiscence increased more than 20% of the incisors during the orthodontic treatment and reached to 50% of the incisors in the patients that had skeletal Class II malocclusion after the orthodontic treatment. Evangelista et al.⁹ compared the presence of dehiscences in the central incisors in patients with Class I and Class II Division 1 malocclusions and different facial types, and found that the incidence of dehiscences was 24.33%. Yagci et al.¹⁰ evaluated the presence of dehiscences in mandibular central incisors among patients with skeletal Class I, II, and III malocclusions with CBCT and showed the incidence, 27.92%, 27.11%, and 25.88%, respectively. Enhos et al.³⁰ reported the presence of dehiscences among patients with different vertical growth patterns and it was 27.08% in the total of all three groups. These results coincided with our results.

As Table II showed, all patients were diagnosed as skeletal Class II, and the mean ANB were 4.7° (SD=1.40) at T1 and 3.7° (SD=1.65) at T2. The mean SNA and SNB at T2 were 81.2° (SD=3.12) and 77.4° (SD=2.80), respectively. SNA was almost maintained and SNB increased approximately 1° at T2. MP-SN and FMA were reduced. The mandibular plane was flattened during the time of treatment. L1-NB increased more than 1 mm in total. The mean IMPA was 91.1° (SD=5.69) at T1 and increased to 95.9° (SD=6.17) at T2 (+4.87° change). None of the data had significant differences between males and females except for the change of MP-SN (-1.64° in males and -0.08° in females). Yoon and Chung.³¹ reported a longitudinal

study of craniofacial growth of untreated Class I and Class II girls from ages 9 to 18 years. They showed that the changes of SNA ($0.84 \pm 1.19^\circ$), SNB ($0.96 \pm 1.15^\circ$), and ANB ($-0.20 \pm 0.48^\circ$). Our study showed SNA ($-0.19 \pm 1.50^\circ$), SNB ($0.74 \pm 1.50^\circ$) and ANB ($-0.98 \pm 1.10^\circ$). This might be due to the differences of gender, in the observation time, and the range in the age of 8-13 at T1 to the age of 13-20 at T2. In an implant study, Bjork and Skieller³² demonstrated rotation of the mandible and remodeling of the MP. They found that 90.5% of the subjects showed forward rotation due to the fact that vertical growth at the condyle was greater than the sum of the vertical growth components at the facial sutures and the molar areas. Patients from ages 9 to 18 in skeletal Class II patients showed a mandibular forward rotation (decreased MP-SN).³³ MP-SN ($-0.81 \pm 2.65^\circ$) and FMA ($-0.71 \pm 2.65^\circ$) were reduced in the current study, and mandibular plane was flattened during the time of treatment, which coincided with their study.

The mean ABT at CEJ2 and CEJ5 were 5.42 (SD=0.70) mm and 5.92 (SD=0.84) mm at T1, respectively. The ABT was changed -0.59 (SD=0.55) mm and -0.82 (SD=0.57) mm at T2. Approximately 10% of ABT in the total was lost during the treatment. There was no significant difference between male and female groups except for the CEJ5 ($p=.0399$). In our patients, the ABT did not remain the same; rather, it decreased. None of the patients had an increase of ABT after the tooth movement.

Comparing Group 2 with 3 after tooth movement, statistically significant alveolar bone reduction occurred at CEJ2 (-1.47 vs -0.30 , $p<.001$) and at CEJ5 (-1.34 vs -0.70 mm, $p<.05$) after the orthodontic treatment. Group 2 exhibited the highest percentage of alveolar bone loss (-23.7% at CEJ2, -19.9% at CEJ5 at the end of the treatment). By contrast, there were not significant differences at CEJ10 and 15 between the groups. The amount of alveolar bone loss was more prominent at the marginal regions than it was at the apical region. This may be because the

treatment modality was mostly protrusion and proclination in order to achieve anterior coupling. The orthodontic forces applied to the central incisors were concentrated to the labial crestal bone thus creating greater accumulation of pressure at the marginal region. These findings agreed with the results of animal studies.²⁻⁴

Wennström et al.² showed histologic evidence of alveolar crestal bone loss when the tooth moved labially, but attachment loss did not necessarily occur. Similarly, Karring et al.³ found reduced alveolar bone height, with connective tissue fibers having a course parallel to the roots in the teeth tipped in facial direction. In addition, none of the histologic studies^{2-4,34} indicate that the cortical plate was reestablished. These studies agreed with the previous Reitan's studies^{35,36} where dehiscences formed when teeth were tipped facially due to a lack of compensatory bone formation on the facial. The concept of compensatory bone formation was proposed by Gottlieb and Orban.³⁷ According to this concept the bone around dehiscences would have remodeled if light force had been applied or the teeth had been retained in the facially-moved position for a longer time period. However, studies^{2,3,34} which developed dehiscences with 50 gm light force for a period of 3-5 months showed no compensatory bone formation after 1-, 5- and 8-month retention period. In a study that contradicts Steiner et al.,⁴ Wingard and Bowers,⁵ reported that dehiscences failed to develop with forces up to 170 gm over 36 to 95 days followed by 4 months of retention. These results indicate that the discrepancy regarding compensatory bone formation may not be related to the difference of retention periods or the magnitude of force application, but rather the difference of the amount of tooth movement. Therefore, it can be concluded that compensatory bone formation does not occur around newly developed dehiscences after the tooth movement, even though the force application is terminated, and the teeth are retained in their facially-displaced position. In our study, we waited an

average of 3 months²⁰ after loading the teeth before we took the T2 scans.

The most striking finding in the present study is the relationship between tooth movement and the change. A simple linear relationship between CEJ2 and L1-NB or IMPA would predict that for each 1mm change in L1-NB CEJ2 decreases by 0.25 mm (95% CI: 0.17-0.34 mm, **Figs.3**) or for each 1° degree change in IMPA CEJ2 decreases by 0.07 mm (95% CI: 0.04 – 0.11 mm, **Figs.4**). In addition, excessive protrusion (L1-NB>3 mm) and proclination (IMPA>9°) of lower incisors caused dehiscences, while patients with tooth movement controlled within L1-NB<1 mm and IMPA<4° had less possibility to develop dehiscences (**Table.V**). In a study¹⁷ which focused on developing recessions rather than dehiscences based on IMPA, the results showed significantly more recessions during orthodontic treatment and at 3-year postoperative period in the patients with excessive proclination (more than 10° of IMPA) than in the patients with minimal change (less than 2° of IMPA) in incisor inclination.

Conclusions:

When camouflaging skeletal Class II patients, the limits of mandibular anterior incisor forward movement might be smaller than previously anecdotally considered (**Fig.1**) when considering the adverse effect on the alveolar bone. Pre-existing dehiscences in the mandibular central incisors were evident in the patients that had skeletal Class II malocclusion. In order to prevent the development of inadvertent dehiscences during the orthodontic treatment, careful diagnosis with CBCT images is essential. Furthermore, when excessive protrusion and/or proclination is planned, additional treatment modalities such as orthognathic surgery, tooth extraction and partial corticotomy with bone grafting should be taken into consideration to avoid periodontal complications during and/or after orthodontic treatment.

1. The null hypothesis was rejected. Dehiscences increased, from 27.1% of the mandibular central incisors to 50.0% after orthodontic treatment in the patients that had skeletal Class II malocclusion. Furthermore, the alveolar bone thickness and height reduced at the end of the orthodontic treatment.
2. Patients who developed dehiscences lost 23.7% of alveolar bone thickness at CEJ2 and 19.9% at CEJ5, on average, over the course of treatment.
3. In the group of patients that developed dehiscences during the orthodontic

treatment, the changes of L1-NB (mm) and IMPA (°) significantly increased 3.1 mm and 9.8° compared with the group of patients that did not develop dehiscences (0.4 mm, $p < .01$ and 3.2°, $p < .001$).

4. A simple linear relationship between CEJ2 and L1-NB or IMPA would predict that for each 1 mm change in L1-NB CEJ2 decreases by 0.25 mm (95% CI: 0.17-0.34 mm) or for each 1° degree change in IMPA CEJ2 decreases by 0.07 mm (95% CI: 0.04 - 0.11 mm).

Reference:

1. Proffit WR. and Ackerman JL. (1982) Diagnosis and Treatment Planning. In: Graber, T.M. and Swain, B.F., Eds., Current Orthodontic Concepts and Techniques, Chapter 1, Mosby, St. Louis, 3-100.
2. Wennström JL, Lindhe J, Sinclair F, Thilander B. Some periodontal tissue reactions to orthodontic tooth movement in monkeys. J Clin Periodontol. 1987;14:121–129.
3. Karring T, Nyman S, Thilander B, Magnusson I. Bone regeneration in orthodontically produced alveolar bone dehiscences. J Periodontal Res. 1982;17:309-315.
4. Steiner GG, Pearson JK, Ainamo J. Changes of the marginal periodontium as a result of labial tooth movement in monkeys. J Periodontol. 1981;52:314-320.
5. Wingard CE, Bowers GM. The effects of facial bone from facial tipping of incisors in monkeys. J Periodontol. 1976;47:450-454.
6. Fuhrmann R. Three-dimensional interpretation of labiolingual bone width of the lower incisors. J Orofac Orthop 1996;57:168–185.
7. Wennström JL. Mucogingival considerations in orthodontic treatment. Semin Orthod. 1996;2:46-54.
8. Wehrbein H, Bauer W, Diedrich P. Mandibular incisors, alveolar bone and symphysis after orthodontic treatment: a retrospective study. Am J Orthod Dentofacial Orthop. 1996;110:239–246.

9. Evangelista K, Vasconcelos KF, Bumann A, Hirsch E, Nitka M, Silva MAG. Dehiscence and fenestration in patients with Class I and Class II Division 1 malocclusion assessed with cone-beam computed tomography. *Am J Orthod Dentofacial Orthop.* 2010;138:133–133.
10. Yagci A, Veli I, Uysal T, Ucar FI, Ozer T, Enhos S. Dehiscence and fenestration in skeletal Class I, II, and III malocclusions assessed with cone-beam computed tomography. *Angle Orthod.* 2012;82:67–74.
11. Nahm KY, Kang JH, Moon SC, Choi YS, Kook YA, Kim SH, Huang J. Alveolar bone loss around incisors in Class I bidentoalveolar protrusion patients: a retrospective three-dimensional cone beam CT study. *Dentomaxillofac Radiol.* 2012;41:481-8.
12. Gracco A, Luca L, Bongiorno MC, Siciliani G. Computed tomography evaluation of mandibular incisor bony support in untreated patients. *Am J Orthod Dentofacial Orthop.* 2010;138:179–187.
13. Renkema AM, Fudalej PS, Renkema AA, Abbas F, Bronkhorst E, Katsaros C. Gingival labial recessions in orthodontically treated and untreated individuals: a case-control study. *J Clin Periodontol.* 2013;40:631–637.
14. Lund H. et al. Cone beam computed tomography evaluations of marginal alveolar bone before and after orthodontic treatment combined with premolar extractions. *Eur J Oral Sci.* 2012;120:201–211.
15. Renkema AM, Fudalej PS, Renkema A, Kiekens R, Katsaros C. Development of labial gingival recessions in orthodontically treated patients. *Am J Orthod Dentofacial Orthop.* 2013;143:206–212.
16. Richman C. Is gingival recession a consequence of an orthodontic tooth size and/or tooth position discrepancy? “A paradigm shift.” *Compend Contin Educ Dent.* 2011;32:e73–e79.
17. Artun J, Krogstad O. Periodontal status of mandibular incisors following excessive proclination. A study in adults with surgically treated mandibular prognathism. *Am J Orthod Dentofacial Orthop.* 1987;91:225–232.
18. Joss-Vassalli I, Grebenstein C, Topouzelis N, Sculean A, Katsaros C. Orthodontic therapy and gingival recession: a systematic review. *Orthod Craniofac Res.* 2010;13:127-141.

19. Persson RE, Hollender LG, Laurell L, Persson GR. Horizontal alveolar bone loss and vertical bone defects in an adult patient population. *J Periodontol.* 1998;69:348–356.
20. Sarikaya S, Haydar B, Ciğer S, Ariyürek M. Changes in alveolar bone thickness due to retraction of anterior teeth. *Am J Orthod Dentofacial Orthop.* 2002;122:15-26.
21. Lupi JE, Handelman CS, Sadowsky C. Prevalence and severity of apical root resorption and alveolar bone loss in orthodontically treated adults. *Am J Orthod Dentofacial Orthop.* 1996;109:28–37.
22. Stoner JE. An investigation into the accuracy of measurements made on radiographs of the alveolar crests of dried mandibles. *J Periodont* 1972;43:699-701.
23. Kallestal C, Matsson L. Criteria for assessment of interproximal bone loss on bitewing radiographs in adolescents. *J Clin Periodont* 1989;16:300-4.
24. Fuhrmann R. Three-dimensional evaluation of periodontal remodeling during orthodontic treatment. *Semin Orthod.* 2002;8:23–28.
25. Swasty D, Lee JS, Huang JC, Maki K, Gansky SA, Hatcher D, Miller AJ. Anthropometric analysis of the human mandibular cortical bone as assessed by cone-beam computed tomography. *J Oral Maxillofac Surg.* 2009;67:491–500.
26. Menezes CCD, Janson G, Massaro CDS, Cambiaghi L, Garib DG. Reproducibility of bone plate thickness measurements with cone-beam computed tomography using different image acquisition protocols. *Dent Press J Orthod.* 2010; 15:143–149.
27. Leung CC, Palomo L, Griffith R, Hans MG. Accuracy and reliability of cone-beam computed tomography for measuring alveolar bone height and detecting bony dehiscences and fenestrations. *Am J Orthod Dentofacial Orthop.* 2010;137:S109–S119.
28. Timock AM, Cook V, McDonald T, Leo MC, Crowe J, Benninger BL, Covell DA Jr. Accuracy and reliability of buccal bone height and thickness measurements from cone-beam computed tomography imaging. *Am J Orthod Dentofacial Orthop.* 2011;140:734-744.

29. Sun L, Zhang L, Shen G, Wang B, Fang B. Accuracy of cone-beam computed tomography in detecting alveolar bone dehiscences and fenestrations. *Am J Orthod Dentofacial Orthop.* 2015;147:313-323.
30. Enhos S, Uysal T, Yagci A, Veli İ, Ucar FI, Ozer T. Dehiscence and fenestration in patients with different vertical growth patterns assessed with cone-beam computed tomography. *Angle Orthod.* 2012;82:868-874.
31. Yoon SS and Chung CH. Comparison of craniofacial growth of untreated Class I and Class II girls from ages 9 to 18 years: A longitudinal study. *Am J Orthod Dentofacial Orthop.* 2015;147:190-6.
32. Bjork A, Skieller V. Facial development and tooth eruption: an implant study at the age of puberty. *Am J Orthod* 1972;62:339-83.
33. Chung CH and Wong WW. Craniofacial growth in untreated skeletal Class II subjects: a longitudinal study. *Am J Orthod Dentofacial Orthop.* 2002;122:619-26.
34. Batenhorst KF, Bowers GM, Williams JE. Tissue changes resulting from facial tipping and extrusion of incisors in monkeys. *J Periodontol.* 1974;45:660-668.
35. Reitan K. Some factors determining the evaluation of forces in orthodontics. *Am J Orthod* 43: 32, 1957.
36. Reitan K. Continuous bodily movement and its histological significance. *Acta Odontol Scand* 6: 115, 1947.
37. Gottlieb B. and Orban B. Die Veränderungen der Gewebe bei übermässiger Beanspruchung der Zähne. Leipzig, Georg Thieme, 1931.