



2017

# Medial Temporal Lobe Does Not Tell The Whole Story: Episodic Memory In 'atypical' Variants Of Alzheimer's Disease

Khaing T. Win

*University of Pennsylvania*, [kwin.2011@gmail.com](mailto:kwin.2011@gmail.com)

Follow this and additional works at: <https://repository.upenn.edu/edissertations>

 Part of the [Neuroscience and Neurobiology Commons](#)

---

## Recommended Citation

Win, Khaing T., "Medial Temporal Lobe Does Not Tell The Whole Story: Episodic Memory In 'atypical' Variants Of Alzheimer's Disease" (2017). *Publicly Accessible Penn Dissertations*. 2767.  
<https://repository.upenn.edu/edissertations/2767>

This paper is posted at ScholarlyCommons. <https://repository.upenn.edu/edissertations/2767>  
For more information, please contact [repository@pobox.upenn.edu](mailto:repository@pobox.upenn.edu).

---

# Medial Temporal Lobe Does Not Tell The Whole Story: Episodic Memory In 'atypical' Variants Of Alzheimer's Disease

## **Abstract**

Alzheimer's disease is the most common form of dementia, which is globally epidemic and well-known by the general public. Episodic memory, a conscious recollection of a particular event in spatial and temporal context, is the most prominent deficit in the early stage of clinical amnesic AD, and reflected by the shrinkage of structures in medial temporal lobe (MTL), including the hippocampus. According to Braak staging, tangles begin in the transentorhinal cortex of the MTL, which then spreads to hippocampal subfields, and later to neocortical areas. Cases that are less recognized by the general public are patients with the atypical variants of AD. Interestingly, many of the atypical cases of AD appear to share the same histopathological features with clinical amnesic AD. According to the diagnostic criteria for these atypical variants of AD, episodic memory should be relatively preserved. However, inconsistent reports on the episodic memory performance and the hippocampal involvement in these atypical cases pose challenges for accurately diagnosing these patients. The two kinds of atypical variants of AD that I focused here are logopenic variant of Primary Progressive Aphasia (lvPPA) and posterior cortical atrophy (PCA). The overarching theme of my thesis is to examine 1) whether the atypical cases of AD have episodic memory difficulty, and if so, 2) what brain areas are responsible for this difficulty. Chapter 2 and 3 of the current thesis show that 1) episodic memory difficulty is observed in lvPPA and PCA cases and 2) this impairment is modulated by deficit in other cognitive domains and associated with disease in non-MTL brain regions. This would be consistent with the 'hippocampal-sparing' hypothesis that not all AD histopathology begins in the MTL, and these hippocampal-sparing conditions suggest that additional mechanisms must be considered in the genesis of spreading pathology in AD.

## **Degree Type**

Dissertation

## **Degree Name**

Doctor of Philosophy (PhD)

## **Graduate Group**

Neuroscience

## **First Advisor**

Murray Grossman

## **Second Advisor**

Joe Kable

## **Keywords**

Atypical variant of Alzheimer's disease, episodic memory (verbal/visual), hippocampus/medial temporal lobe, lexical retrieval, logopenic variant of Primary Progressive Aphasia, posterior cortical atrophy

---

**Subject Categories**

Neuroscience and Neurobiology

PRACTICAL ADVICE:

MEDIAL TEMPORAL LOBE DOES NOT TELL THE WHOLE STORY: EPISODIC  
MEMORY IN 'ATYPICAL' VARIANTS OF ALZHEIMER'S DISEASE

Khaing Thnizar Win

A DISSERTATION

In

Neuroscience

Presented to the Faculties of the University of Pennsylvania

In

Partial Fulfillment of the Requirements for the  
Degree of Doctor of Philosophy

2017

Supervisor of Dissertation

---

Murray Grossman, MD, EdD  
Professor of Neurology

Graduate Group Chairperson

---

Joshua I. Gold, PhD  
Professor of Neuroscience

Dissertation Committee

Joe Kable, PhD, Baird Term Associate Professor of Psychology  
David Wolk, MD, Associate Professor of Neurology  
Corey McMillan, PhD, Assistant Professor of Neurology  
David Libon, PhD, Professor of Geriatrics and Gerontology, and Psychology

© Khaing T. Win

---

All rights reserved

2017

## **DECLARATION**

This dissertation is the result of my own work, with the collaboration with Dr. Paul Yushkevich on the high resolution of T2 MRI imaging to maximize the visualization of subregions within the Medial Temporal Lobe described in Chapters 2 and 3, and the collaboration with Dr. Corey McMillan and Dr. David Wolk on interpretation of data and study concept described in Chapters 2 and 3. This dissertation has not been submitted, in whole or in part, for any other degree, or qualification.

## **ACKNOWLEDGEMENTS**

First, I would like to thank the Penn Biomedical Graduate Studies and Neuroscience Graduate Group (NGG) for supporting me financially, and providing such a unique and collaborative scientific environment, which enabled me to pursue my personal research interests. It has been a privilege to be a part of the NGG. First of all, I would not be a part of NGG if it was not for Kelly Jordan-Scuitto, who immediately recognized my passion for science and doing research at the Annual Biomedical Research Conference for Minority Conference in 2010, and who encouraged me to apply for the Neuroscience Graduate Program at UPenn. Her faithful confidence has given me boundless energy needed to submit my research proposal for National Science Foundation Research, which was successfully funded for the next three years, for which I am very grateful. Special thanks go to Josh Gold, the NGG Chair, whose ambition, dedication, and support have allowed the NGG to become what it is today and to promote such a vibrant fun research community. In addition, I am very grateful to have gone through my journey of graduate research experience alongside Josh, who has been with me through the good times and the bad, and whose kindness, honesty and wicked sense of humor have helped me to find my way through many unimaginable crisis. Next, I would like to extend my special gratitude to NGG administrators, particularly Jane Hoshi, Christine Clay, and Tom Hindman, for always being there for me, giving me valuable advices on many

administrative-related processes, and making sure that everything in my graduate career has gone smoothly.

Second, I would like to thank Murray Grossman, whose supervision of my PhD projects was invaluable in helping me to create this thesis. The countless discussions about memory, neurodegeneration, neuropsychology, and cognitive neuroscience have greatly shaped my research I conducted during my PhD and have certainly influenced my view of the field. His wisdom and insight into my projects have challenged me intellectually to become a better scientist. I also would like to thank my Thesis Committee members for providing their precious time to share their expertise with me and give me valuable feedback on my research for improvement.

Novel findings for the involvement of Medial Temporal Lobe subfields would not be possible if it was not for the collaboration with Paul Yushkevich, John Pluta, and Long Xie. I would also like to take this opportunity to thank John Pluta, Long Xie, and Charles Jester for their support and their unwavering commitment to teach me various imaging methods used through my graduate research career.

My sincere gratitude goes to two of the best and most courteous scientists I have come across throughout my career: Nicola Spotorno and Jeff Philips. Their generous support and kindness to lend me a hand whenever I needed help with imaging techniques, or whenever I needed a lending ear for my problems, or



whenever I needed a shoulder to cry on have made my graduate career much more positive, more manageable, and worthwhile. I am very fortunate to have wonderful officemates and friends, such as Nicola and Jeff, at Penn. I would also like to take this opportunity to thank my other officemates, Naomi Nevler, Sherry Ash, and Mingyeong Choi, for being supportive during the good times and the bad, especially when both my grandmother and grandfather passed away. My grandfather was one of the reasons why I was very passionate and motivated to carry out my Ph.D. thesis in the field of Alzheimer's Disease. It was very difficult for me to overcome the sadness personally and to continue to work on my research since my grandfather was diagnosed with Alzheimer's disease and he lived through the end of the most severe stage of Alzheimer's disease. Thank you, Sherry and Naomi, for being there for me during my difficult times and encouraging me to keep pressing on personally, mentally, and intellectually.

I would like to thank my NGG friends. Special thanks go to Herminio Guajardo, Elaine Liu, Will Olson, Anna Stern, Yin Li, Laura Bryant, and Shivon Robinson (and her boyfriend Andrew) for being such great friends that I could count on. They have not only given me feedbacks on my research but also provided me with endless support and advices on how to better tackle problems in my lab, and my personal life.

Outside of the academic field, I am very grateful to have gone through my life alongside my supportive and loving parents. The invaluable debt I owe to

them is for their sacrifice they have made to bring my sister and I to the United States, the land of BIG DREAMS; always having confidence in me; and encouraging me to pursue my dream, a perfect combination, which has got me to where I am today. I would also like to thank my sweet sister, Ei Ei, who is my best friend, and whom I can count on regardless of the circumstances and the sacrifice she has made to help me to be successful.

My deepest gratitude goes to Justin Thomas and Lorre Atlan, who provided me with priceless motivational and practical support in writing this PhD and finishing up my Ph.D. I am immensely grateful for them being there for me throughout this process.

Finally, and most importantly, I owe a huge debt of gratitude to my caring boyfriend, Dan Hong, for his unwavering support and encouragement throughout the course of my Ph.D. I also would like to acknowledge Iri Hong, our rescued adorable English bulldog, for bringing me happiness and always cheering me on. I simply can't imagine how I would successfully complete my Ph.D. without these two.

## **Abstract**

Alzheimer's disease is the most common form of dementia, which is globally epidemic and well-known by the general public. Episodic memory, a conscious recollection of a particular event in spatial and temporal context, is the most prominent deficit in the early stage of clinical amnesic AD, and reflected by the shrinkage of structures in medial temporal lobe (MTL), including the hippocampus. According to Braak staging, tangles begin in the transentorhinal cortex of the MTL, which then spreads to hippocampal subfields, and later to neocortical areas. Cases that are less recognized by the general public are patients with the atypical variants of AD. Interestingly, many of the atypical cases of AD appear to share the same histopathological features with clinical amnesic AD. According to the diagnostic criteria for these atypical variants of AD, episodic memory should be relatively preserved. However, inconsistent reports on the episodic memory performance and the hippocampal involvement in these atypical cases pose challenges for accurately diagnosing these patients. The two kinds of atypical variants of AD that I focused here are **logopenic variant of Primary Progressive Aphasia (lvPPA)** and **posterior cortical atrophy (PCA)**. The overarching theme of my thesis is to examine 1) whether the atypical cases of AD have episodic memory difficulty, and if so, 2) what brain areas are responsible for this difficulty. Chapter 2 and 3 of the current thesis show that 1) episodic memory difficulty is observed in lvPPA and PCA cases and 2) this

impairment is modulated by deficit in other cognitive domains and associated with disease in non-MTL brain regions. This would be consistent with the 'hippocampal-sparing' hypothesis that not all AD histopathology begins in the MTL, and these hippocampal-sparing conditions suggest that additional mechanisms must be considered in the genesis of spreading pathology in AD.

**Keywords:** atypical variant of Alzheimer's disease, episodic memory (verbal/visual), Alzheimer's disease, logopenic variant of Primary Progressive Aphasia, lexical retrieval, posterior cortical atrophy, hippocampus/medial temporal lobe

## **Table of Contents**

Declaration.....	iii
Acknowledgements .....	iv
Abstract .....	v
Chapter I: INTRODUCTION	
A) Memory in AD .....	1
B) Medial temporal lobe and memory .....	3
C) Pathological hallmark of AD .....	5
D) Other cognitive impairments and their anatomy in AD .....	6
E) Clinical trials for AD (any progress?).....	8
F) Variants of AD .....	10
G) Logopenic variant of primary progressive aphasia .....	12
H) Posterior cortical atrophy.....	16
I) Research focus: rationale for this research .....	21
Chapter II: Project 1 - Examine the neuroanatomical basis of verbal episodic memory in logopenic variant of primary progressive aphasia (published manuscript; Win et al. 2017)	
A) Introduction .....	28
B) Method .....	31
C) Results.....	38

D) Discussion.....	42
E) Tables/Figures .....	49
Chapter III: Project 2 - Examine the neuroanatomical basis of visual episodic memory in posterior cortical atrophy	
A) Introduction .....	52
B) Method .....	56
C) Results .....	63
D) Discussion .....	67
E) Tables/Figures .....	72
Chapter IV: DISCUSSION/FUTURE DIRECTIONS	
A) Summary of my research and potential shortcomings.....	78
B) Future direction .....	85
Abbreviations Index .....	92
References.....	93

## **CHAPTER I. INTRODUCTION**

Alzheimer's disease (AD) is the most common cause of dementia, which is defined as a cognitive deficit in at least two domains that is also interfering with independence in everyday activities in elderly individuals (McKhann et al. 2011). By 2040, it is estimated to affect 81 million people worldwide (Gold and Budson 2008; 2017). Episodic memory, which allows individuals to recall personal experiences, is often the most prominent deficit in clinical AD, which later then progresses to affect multiple cognitive domains (McKhann et al. 2011).

### **Section I.A. Memory in AD**

The most salient feature and earliest symptom of AD often is the inability to form new memories and retain them (Gold and Budson 2008; Arshavsky 2010). During the early course of the disease, such impairment may result in forgetfulness of crucial events, including misplacing items, missing doctor appointments, paying bills late, and forgetting to take medications (Gold and Budson 2008). Memory loss is observed in both verbal and visual modalities (Collie and Maruff 2000).

Verbal episodic memory may be assessed with story recall, word list learning or verbal paired associate tasks (Collie and Maruff 2000). Most often in the clinical setting, it is usually assessed with delayed free recall of a list of words. Here, participants are given a list of words to remember, and they are

asked to recall the words after a filled delay period. In a recognition memory test, participants study a list of words, and after a filled period these are later presented in a randomly ordered list where some were previously studied ('old' items) and some were novel ('new' items). Participants are then asked to identify whether each item on the list is 'old' or 'new'. (Gold and Budson 2008) Delayed free recall test is a more difficult process than recognition memory test since it requires a lexical retrieval process (Indefrey 2011). AD patients performed poorly on both tasks compared to age-matched individuals (Helkala et al. 1988; Gold and Budson 2008; Bonner-Jackson et al. 2015).

Visual episodic memory may be assessed in the same way. Examples (Collie and Maruff 2000) include Warrington's recognition memory for faces (Warrington 1984), visual retention test (Benton 1945), and Rey Figure Recall Test (Osterrieth 1944). In clinic, it is often assessed with Rey Figure Recall Test, where participants are asked to copy a figure composed of geometric shapes, and the individual is asked to draw it from memory after a filled delayed period. AD patients have difficulty drawing this figure from memory after a delayed period (Kasai et al. 2006; Bonner-Jackson et al. 2015).



## **Section I.B. Medial temporal lobe and memory**

From lesion studies, including patient H.M., and work in neuroimaging, we have learned that one canonical structure responsible for memory is the medial temporal lobe (MTL) (Cohen and Eichenbaum 1995; Clark and Squire 2010; Wixted and Squire 2011a; 2011b; Eichenbaum 2013). MTL encompasses several histologically distinct regions (Andersen 2007; Duvernoy et al. 2013); it consists of hippocampus [(consisting of the cornu ammonis subfields, CA1, CA2, CA3), dentate gyrus (CA4/DG), and subiculum] and extra-hippocampal structures [entorhinal cortex, (ERC) and perirhinal cortex]. Each substructure has different computational processing roles contributing to the memory system. Memory retrieval occurs upon experiencing environment or internal cue that share specific features with a stored memory. These cues are processed in various respective neocortical areas, which then send signals to ERC and to DG and then to CA3. CA3 is essential for creating the so-called hippocampal index, which distinctly records an item or event associated with a particular episode and facilitates subsequent retrieval (Nakazawa et al. 2002; Shastri 2002; Teyler and Rudy 2007). As a result, the neural patterns of activity associated with the original event recorded in CA1, subiculum and other neocortical areas are reinstated (Shastri 2002; Teyler and Rudy 2007). This reinstatement allows the individual to experience the recall of the sensory information (ie.sound, sight smell, taste) that were associated with the original event (Gold and Budson 2008). Many groups

have reported the alteration in hippocampal shape and surface structure as well as atrophy in the medial temporal lobe subregions in AD patients compared to age-matched healthy controls (Wang et al. 2006; Barnes et al. 2007; Scher et al. 2007). ERC (Di Paola et al. 2007), DG (Ohm 2007), CA3 (Adachi et al. 2003) are all altered in AD patients.

Hippocampal atrophy has been the best established biomarker to stage the progression of AD pathology in the brain across the entire disease spectrum (Jack et al. 2011; Dickerson et al. 2017) among the core biomarkers of AD (Dubois et al. 2007; 2010; Albert et al. 2011; McKhann et al. 2011; Sperling et al. 2011). Burton and colleagues also (2008) reported that MTL/hippocampal atrophy is highly accurate diagnostic marker for autopsy confirmed AD. Their ROC analysis for MTL/hippocampal atrophy showed 91% sensitivity and 94% specificity for AD diagnosis compared to dementia with Lewy bodies and vascular cognitive impairment (Burton et al. 2008). Patients with typical AD display atrophy and hypometabolism of the bilateral hippocampus, medial temporal lobe, posterior cingulate, precuneus and temporoparietal cortex on structural MRI and  $^{18}\text{F}$ -fluorodeoxyglucose (FDG)-positron emission tomography (PET) brain imaging (Busatto et al. 2003; Warren et al. 2012).

Alzheimer's disease is associated with the accumulation of misfolded amyloid and tau in the brains of these patients (see below). Other

pathophysiological biomarkers, including PET of brain amyloid, are also utilized in corroborating AD diagnosis (McKhann et al. 2011; Blennow et al. 2015). Excess amyloid deposition on Pittsburgh compound B (PiB) and other PET amyloid radioligands is also seen in AD patients (Pievani et al. 2011; Warren et al. 2012). Cerebrospinal fluid (CSF) measurements of tau and amyloid- $\beta$  (A $\beta$ ) are also used for diagnosis. Studies have reported an increased level of raised total tau and reduced level of A $\beta$  on CSF profile (Shaw et al. 2009).

### **Section I.C. Pathological hallmark of AD**

Two major pathological hallmarks of AD are plaques, which are composed of amyloid- $\beta$  peptide (A $\beta$ ), and neurofibrillary tangles (NFT), which are composed of hyperphosphorylated tau protein (P-tau) (Trojanowski and Lee 1999; Blennow et al. 2006; 2015). A $\beta$  pathology precedes before tau pathology; the accumulation of A $\beta$  leads to accumulation and spread of tau pathology (Braak and Braak 1991; Schöll et al. 2016), which in turn results in structural, cognitive and function changes in the diseased brain (Bourgeat et al. 2010; Chételat et al. 2010; Landau et al. 2012; Insel et al. 2016). Braak staging predicts the pattern of MTL atrophy. According to Braak staging, tangles begin in the transentorhinal cortex of the MTL, which then spreads to hippocampal subfields, and later to neocortical areas (Braak and Braak 1991). The pathology underlying AD precedes even before the appearance of clinical symptoms.

### **Section I.D. Other cognitive impairments and the associated anatomy in AD**

In addition to memory, deficits in other cognitive domains are seen in clinical amnesic AD as well. Deficits in attention, working memory and other aspects of executive function are often detected on neuropsychological tests, and are associated with atrophy in frontal areas (Baudic et al. 2006). Language (Pekkala et al. 2013) and visuospatial abilities (Kasai et al. 2006) are also impaired in clinical amnesic AD patients.

In the language domain, lexical retrieval deficits in discourse serve as an early indicator of AD (Pekkala et al. 2013). Lexical retrieval is a multi-step process where the corresponding concept of a target word in semantic memory is identified and the name that best labels this concept is then selected and expressed phonologically or in writing. One way to assess lexical retrieval is a picture-naming test, where participants have to name the pictures that are shown. Compared to age-matched healthy participants, AD patients perform worse on a confrontation naming task 2–3 years before the diagnosis (Chen et al. 2001; Mickes et al. 2007). This performance steadily declines in AD patients as the disease progresses (Locascio et al. 1995; Salmon et al. 1999). Left middle and inferior temporal gyri were associated with naming performance in AD patients (Grossman et al. 2004; Graves et al. 2007; Peters et al. 2009b).

Visuospatial ability is another domain that is impaired in AD patients. In

Rey Figure Test, the visuospatial dysfunction is apparent when AD patients are copying the Rey Figure; there are some spatial misplacement of geometric components of the figure (Kasai et al. 2006). The visuospatial deficit can compromise daily activities, such as reading, visuospatial orientation, and motion detection, in AD patients reviewed in (Cronin-Golomb and Hof 2004). The performance on the visual tasks declines gradually with the progression of the disease (Mendez et al. 1990) and are associated with atrophy in the visual association cortex (Mendez et al. 1990), Brodmann area 5 of the superior parietal lobe (Katz and Rimmer 1989), the parietooccipital junction and the premotor areas (Thiyagesh et al. 2009).

## **Section I.E. Clinical trials for AD (any progress?)**

Since the discovery of Alzheimer's disease in 1906, scientists and clinicians from multiple disciplines have worked arduously and collaboratively to better understand the pathogenesis of AD by studying molecular, structural, functional alterations in the diseased animal models as well as in the patients who are clinically diagnosed with AD (Hardy 2006). To determine appropriate treatments for AD, cognitive measures have been used traditionally as clinical trial endpoints, which are measures of disease outcomes in clinical studies (Lawrence et al. 2017). Despite these remarkable efforts for development of therapeutic agents, many clinical trials have failed repetitively and there still exists the gap between the basic science discovery and clinical application (Beach 2017). This has raised many concerns regarding the present propositions of disease-modifying agents. There is now converging evidence that the pathogenesis of AD gets under way many years before the onset of dementia (reviewed in (Sperling et al. 2011)). In 2011, three consensus panels joined to better define AD in terms of three clinically-defined stages: (1) presymptomatic or preclinical, (2) mild cognitive impairment (MCI), the transition zone between the cognitive decline in aging and the cognitive burden of AD, and (3) dementia (Albert et al. 2011; McKhann et al. 2011; Sperling et al. 2011).

In addition to this clinically defined "AD dementia", which is a well-known

common form of dementia by the public, there are other forms of clinical syndromes, whose predominant underlying pathology is AD pathology but display distinct clinical phenotypical presentations as well as distinct pattern of brain atrophy affected (Lam et al. 2013; Dickerson et al. 2017). These cases will be referred to as the 'atypical' variants of AD, whose age onset is much younger (<65 years old) than clinical AD (Dickerson et al. 2017). Because memory seems to be relatively spared in these atypical variants of AD compared to the clinical AD cases, these atypical cases are misdiagnosed more than half of the times (Murray et al. 2011) and are not considered as AD, and hence these cases are not eligible for clinical trials for AD. The disadvantage of clinical studies is that the diagnoses for the atypical cases are made using clinical criteria and pathologic confirmation may not always be available. These variants further demonstrate how complex and heterogeneous AD is and poses additional challenges for effective treatments targeting the right population. My dissertation focuses on studying these atypical variants of AD. My two projects examined whether memory was affected in these cases, as seen in the clinical amnesic AD, since reports on memory in the atypical cases are variable. Next, if these patients appear to have some degree of memory difficulty, my thesis also examined which cognitive and anatomical factors contribute the appearance of memory difficulty in atypical cases.

## **Section I.F. Variants of AD**

As mentioned above, there are different variant subtypes that are associated with AD pathology. Interestingly, many of these variant cases share biological features with clinical amnesic AD; the identical plaque and tangle pathology found in clinical amnesic AD, which I will refer to as typical AD, are also found in these variant clinical subtypes (Dickerson et al. 2017). Neuropathologic studies have demonstrated that it is not A $\beta$  plaques that drive this heterogeneity within AD syndrome, but rather the distribution of NFTs burden and associated neuronal degeneration that forecast the particular clinical syndrome (Hof et al. 1989; Dickerson et al. 2017). Murray and colleagues (2011) recently developed a system to classify the heterogeneity of neuropathology in AD (Murray et al. 2011). Based on the relative density of NFTs in the hippocampus and other neocortical areas, AD can be divided into three subtypes: typical AD, hippocampal-sparing AD, and limbic-predominant AD (Murray et al. 2011; Janocko et al. 2012). NFTs are disproportionately distributed in cortical areas with relative sparing of the hippocampus in hippocampal-sparing AD, while NFTs distribution follow the pattern of Braak staging scheme in typical AD, where hippocampus is mostly affected. There are more NFTs in hippocampus, with sparse NFTs in association cortices and little or no NFTs in primary sensory-motor cortices in limbic-predominant AD. Age seems to be one major factor that influences the topography of neurodegeneration in AD



(Dickerson et al. 2017), with younger patients more likely to show neurodegeneration more prominently in temporoparietal areas but have less prominent NFTs in the MTL (hippocampal-sparing cases) while older patients showing more prominent neurodegeneration in the hippocampus and other MTL structures than in neocortical areas particularly early in the course of disease (“limbic predominant”).

Typical AD or clinical amnesic AD patients are the cases where memory is a predominant factor. On the other hand, hippocampal-sparing AD present with different cognitive and anatomic profiles compared to **the typical presentation** seen in clinical AD, and hence sometimes are referred to as ‘atypical’ cases of AD. My dissertation focuses on examining ***hippocampal-sparing variant cases of AD***. According to the diagnostic criteria for these hippocampal-sparing variant of AD cases, memory is relatively spared compared to their prominent deficits in other cognitive domains (Warren et al. 2012). Individuals with hippocampal-sparing AD may have prominent deficits in language domains, while other may have prominent deficits in visuo-perceptual domains (Lam et al. 2013; Dickerson et al. 2017). The two variants of hippocampal-sparing AD that will be the focus of my dissertation are **logopenic variant of primary progressive aphasia (lvPPA) and posterior cortical atrophy (PCA)**.

### **Section I.G. Logopenic variant of primary progressive aphasia (lvPPA)**

The language variant of primary progressive aphasia (PPA) often associated with AD pathology is the logopenic variant of primary progressive aphasia (lvPPA). This is characterized by core features of impaired lexical retrieval, and difficulty repeating sentences or phrases (Gorno-Tempini et al. 2011; Leyton and Hodges 2013; Mesulam et al. 2013). There has been a growing interest in lvPPA given that 1) a third of PPA patients have AD as the underlying pathology, and 2) lvPPA is an interesting population to examine the clinical-anatomical heterogeneity of AD because of its distinct clinical profile and distribution of brain atrophy.

Consensus diagnostic criteria (Gorno-Tempini et al. 2011) require that in addition to the core language deficit in confrontation naming and repetition, lvPPA patients must have any of three of the following features: phonological errors in spontaneous speech and naming, spared semantic knowledge, spared motor speech, and absence of frank agrammatism. LvPPA patients exhibit remarkable word-finding difficulties that disrupt the flow of spontaneous conversation (Wilson et al. 2010); some authors have described their speech as interrupted with sounds such as “mmm,” “uhh,” and “ohh,” as if they are searching for the correct target word, or interrupted with repetition of the utterance such as “my daughter is, my mother daughter is, picking me up.” The naming deficit in lvPPA sometimes is as severe as in the semantic variant of

PPA, but naming errors are usually phonological rather than semantic coordinate and superordinate errors seen in semantic variant patients. LvPPA patients typically have relatively spared semantic knowledge (Leyton et al. 2011; Mesulam et al. 2012); lvPPA patients know the properties of the word they are meaning to describe (“it’s the Australian one... it hops around” (Leyton and Hodges 2013), and performance on naming tasks is improved with phonological cues (Rohrer et al. 2010; Leyton et al. 2011; Savage et al. 2013).

According to the consensus diagnostic criteria, supporting neuroimaging of lvPPA patients should display either prominent atrophy in left posterior perisylvian/parietal areas on MRI or prominent hypoperfusion or hypometabolism in left posterior perisylvian /parietal areas on SPECT or PET (Gorno-Tempini et al. 2011). Multiple neuroimaging studies have shown involvement of left temporo-parietal junction area, including posterior temporal, supramarginal, and angular gyri (Gorno-Tempini et al. 2004; Henry and Gorno-Tempini 2010; Mesulam et al. 2012; Mesulam and Weintraub 2014; Mesulam et al. 2014b). The damage to these areas corresponds to core deficits observed in lvPPA patients. The confrontation naming deficit in lvPPA is associated with atrophy in middle temporal gyrus and other inferior-posterior parietal areas while the repetition deficit is correlated with posterior third of the superior temporal gyrus (Leyton and Hodges 2013). The naming deficit in typical AD patients is also associated with the inferior-posterior parietal areas (Harasty et al. 1999). This may suggest

that the naming deficit in lvPPA and typical AD patients depends on impaired lexical retrieval (Hodges et al. 1992; Hodges 1995; Croot et al. 2000).

The repetition deficit is another cardinal characteristic of lvPPA clinical phenotype. LvPPA patients have reduced verbal short-term memory but this deficit is secondary to an impairment of the phonological loop, caused by damage to the posterior left superior temporal gyrus (Archeson et al., 2011; Baldo et al., 2012). Many studies have shown reduced performance in digit span and tasks that requires a high demand on short-term memory resources correlating to atrophy in posterior left superior temporal gyrus (Amici et al. 2007; Leff et al. 2009; Archeson et al. 2011; Richardson et al. 2011; Baldo et al. 2012). While typical AD patients have reduced verbal short-term memory, the mechanism underlying this deficit also may be due to an executive control deficit caused by atrophy in frontal regions (Peters et al. 2009a; Huntley and Howard 2010).

Episodic memory should be relatively spared according to the diagnostic criteria for lvPPA. However, evaluations of verbal episodic memory have been inconsistent in lvPPA (Josephs et al. 2013; Rohrer et al. 2013; Flanagan et al. 2014; Piguet et al. 2015; Ramanan et al. 2016). This is frequently assessed with verbal delayed free recall. However, recall may be confounded by the lexical retrieval deficit in lvPPA. While visual memory has been reported to be spared in

lvPPA (Weintraub et al. 2013), this would not explain the verbal episodic memory deficit that has been reported in lvPPA. Hence, the question of interest is whether verbal episodic memory is affected, measured by verbal delayed free recall performance, and if so, which factors might explain this appearance of deficit. How would lvPPA patients perform on the verbal recognition memory test, which does not require the process of lexical retrieval? One study has reported that lvPPA patients have comparable performance on verbal recognition memory compared to healthy controls (Ramanan et al. 2016). Review of the lvPPA literature is not very clear on this issue of verbal episodic memory performance in lvPPA. No other study has examined in detail the relationship between lexical retrieval and verbal episodic memory, assessed via verbal delayed free recall. This gap in knowledge can lead to more inconsistent reports on verbal episodic memory performance in lvPPA literature. It is, therefore, the hope of my research to fill this gap (more details in RATIONALE SECTION on page 23).

The clinical boundary between lvPPA and typical AD presentations can sometimes be blurry due to the language deficits that can be observed in typical AD (Leyton and Hodges 2013). There are some overlapping cognitive characteristics between lvPPA and AD. Language impairment, including lexical retrieval deficit, is observed in both lvPPA (Gorno-Tempini et al. 2004; Henry and Gorno-Tempini 2010; Gorno-Tempini et al. 2011; Mesulam 2013; Mesulam et al. 2014a) and typical AD (Grossman et al. 2004; Pekkala et al. 2013). While

repetition difficulty is a necessary feature of lvPPA (Gorno-Tempini et al. 2011), AD patients also can exhibit repetition difficulty (2014). In some cases, lvPPA patients are impaired on verbal episodic memory (Flanagan et al. 2014; Ramanan et al. 2016). Our clinical cohort of lvPPA also showed some degree of impairment on verbal delayed recall task (Win et al. 2017). At a first glance, the two cohorts thus can present with similar clinical characteristics and can be confusing in terms of diagnosis.

A majority of cases of lvPPA are associated with AD pathology. However, the distribution of pathological changes and genetic risk factors are different between lvPPA patients and typical AD patients. Compared to typical AD, lvPPA patients have a higher proportion of NFT pathologic burden in the left perisylvian language cortices than typical AD patients (Gefen et al. 2012). Consistent with the distinct clinical phenotypes of typical AD and lvPPA, different genetic risk factors may play a role in lvPPA compared to typical AD. Apolipoprotein  $\epsilon 4$  (APOE4) polymorphism, which is linked to typical AD, is less common in lvPPA (Wolk et al. 2010; Rogalski et al. 2011b).

### **Section I.H. Posterior cortical atrophy (PCA)**

Posterior cortical atrophy (PCA) is a neurodegenerative condition, characterized by prominent visual perceptual-spatial deficits. This syndrome was

first described in 1988 when Benson et al. [1] reported five patients with prominent visual complaints and who all exhibited both Balint's syndrome (oculomotor apraxia, simultanagnosia, optic ataxia) and Gerstmann's syndrome (agraphia, acalculia, finger anomia, right-left disorientation). Early diagnosis of PCA is a major challenge and often delayed owing to its misleading presentation with visual complaints, which lead patients to consult an ophthalmologist at first (Tang-Wai 2004). Based on neuropsychological examination, PCA patients display alexia, Balint's syndrome, Gerstmann's syndrome, prosopagnosia, or environmental agnosia (Borruat 2013). The complaints associated with the visuospatial deficit include blurred vision, lack of sharpness, difficulty walking on uneven ground, difficulty evaluating distances when driving, inaccurately grasping objects under visual guidance (Crutch et al. 2012; Vighetto 2013; Crutch et al. 2013b). Additional complaints associated with visuoperceptual deficits include difficulty recognizing faces, landmarks, or objects (Crutch et al. 2012; Vighetto 2013; Crutch et al. 2013b).

The visuospatial dysfunction results from damage to the occipitoparietal pathway, also known as the dorsal ('where') pathway of visual information (Biotti et al., 2012). In contrast, visuoperceptual dysfunction results from damage to the occipitotemporal pathway or ventral ('what') pathway, which mediates recognition of forms and colors that account in part for the various forms of visual agnosia (Borruat 2013). Lehmann and colleagues (2011) examined basic visual

processing in 21 PCA patients, which was assessed with six tests: form detection, form coherence, form discrimination, color discrimination, motion coherence, and point localization; and higher-order visual functions. Performance was correlated with cortical thickness. All PCA patients were impaired in at least one basic visual function test, and 81% of these patients were impaired on at least 3/6 tests. These patients were categorized based on dorsal stream and ventral stream dysfunction: patients with visuospatial difficulties had thinner occipitoparietal areas while patients with visuoperceptual difficulties had thinner occipitotemporal areas.

While a small number of PCA cases is associated with dementia with Lewy Bodies, corticobasal degeneration (CBD), or rarely, Creutzfeldt–Jakob disease (Renner et al., 2004; Tang-Wai et al., 2004), majority of cases of PCA are associated with AD pathology. Just like in lvPPA patients, PCA patients have a different distribution of pathological changes and genetic risk factors compared to typical AD. Compared to typical AD, PCA patients have fewer plaques and NFTs in the prefrontal cortex and hippocampus, while greater burden of plaques and NFTs in the occipitoparietal areas and occipitotemporal junction is observed (Hof et al., 1997; Tang-Wai et al., 2004). Genetically, ApoE 4 allele does not seem to be a risk factor for PCA, while it is strongly associated with typical AD (Schott et al., 2006; Snowden et al., 2007; Van der Flier et al., 2006).



There are many proposed diagnostic criteria for PCA outlined by several centers over the past decade (Mendez et al. 2002; Tang-Wai 2004), but consensus criteria were just recently developed this year by a number of clinicians and researchers from multiple international centers in an effort to establish a consensus opinion regarding the PCA syndrome (Crutch et al. 2017). According to these international consensus diagnostic criteria (Crutch et al. 2017), PCA patients must present with at least three of the following features: space perception deficit, simultanagnosia, object perception deficit, constructional dyspraxia, environmental agnosia, oculomotor apraxia, dressing apraxia, optic ataxia, alexia, left/right disorientation, acalculia, limb apraxia (not limb-kinetic), apperceptive prosopagnosia, agraphia, homonymous visual field defect, or finger agnosia. In addition, PCA patients must have relative sparing of memory, speech and nonvisual language, executive functions, behavior and personality. Neuroimaging must display prominent occipitoparietal or occipitotemporal atrophy on MRI or hypometabolism/hypoperfusion on FDG-PET/ SPECT.

Reports on examination of memory in PCA are not very systematic. Neuropsychological studies of PCA patients reported sparing of memory in PCA (Renner et al. 2004; Charles and Hillis 2005; Migliaccio et al. 2009b; Crutch et al. 2012; Borruat 2013; Crutch et al. 2013a; Ossenkuppele et al. 2015) but these studies use verbal recall task to measure 'memory'. As mentioned earlier,

episodic memory can be examined in two modalities, verbal and visual. The careful examination of visual episodic memory is crucially important given the diagnostic criteria requirement of relative sparing of 'memory.' However, all these neuropsychological studies (Renner et al. 2004; Charles and Hillis 2005; Migliaccio et al. 2009b; Crutch et al. 2012; Borruat 2013; Crutch et al. 2013a; Ossenkoppele et al. 2015) reported the deficit of visuospatial skills in PCA but failed to report the visual component of episodic memory. Visual episodic memory in PCA may be impaired especially due to the inability to encode the visual materials that the patients are asked to remember. Indeed, a case study report of a PCA patient has displayed the poor performance of Rey Recall test (Kennedy et al. 2012). But no study has examined the visuospatial and visuoperceptual factors contributing to visual episodic memory performance in PCA, and there still remains a gap in knowledge in the field. My research addressed this concern and aimed to fill this gap (more details in Section I.I).

## **Section I.I. Research focus: rationale for this research**

AD pathology in these atypical variant cases may be “hippocampal-sparing” (Murray et al. 2011; Janocko et al. 2012; Lam et al. 2013; Wolk 2013) and thus may not begin in the MTL as in clinical amnesic cases of AD (Braak and Braak 1991). Indeed, the diagnostic criteria for these atypical variant cases required relatively preserved episodic memory. However, there have been inconsistent reports on episodic memory sparing and the involvement of MTL structures, including the hippocampus, in lvPPA and PCA. The overarching theme of my thesis is to examine 1) whether these atypical cases of AD have episodic memory difficulty (verbal modality in lvPPA and visual modality in PCA), and if so, 2) what brain areas are responsible for this difficulty. I hypothesize that episodic memory difficulty in atypical AD cases is mild, and is often associated with non-memory components of performance, such as difficulty retrieving a list of words during verbal free recall or difficulty encoding visuospatial materials that must be recalled. Moreover, I hypothesize that this pattern of performance on memory tasks is associated with disease in other, non-MTL brain regions. This would be consistent with the hypothesis that not all AD histopathology begins in the MTL, and these hippocampal-sparing conditions suggest that additional mechanisms must be considered in the genesis of spreading pathology in AD.

Prominent verbal and nonverbal memory loss and visuospatial impairment are exclusionary criteria for PPA (Gorno-Tempini et al. 2011). However,

evaluations of verbal episodic memory have been inconsistent in lvPPA (Rohrer et al. 2013; Flanagan et al. 2014). This is frequently assessed with delayed verbal free recall, where participants name a list of recalled words after a delay period. However, poor verbal recall may be confounded by the lexical retrieval deficit in lvPPA. Thus, their failure to retrieve the phonological word form of a target word can easily be misinterpreted as an inability to recall this target word on the memory paradigm. One group has assessed both verbal and non-verbal episodic memory in PPA patients, and shown verbal retrieval failures compared to relatively successful visual memory (Weintraub et al. 2013). However, this group studied a mixture of PPA variants (including agrammatic, logopenic, and semantic). Moreover, this study did not clarify whether delayed verbal free recall deficits in lvPPA specifically are due to the true episodic memory difficulties, mediated by MTL/hippocampus or limited lexical retrieval.

Reports of hippocampal atrophy in lvPPA also have been inconsistent (Gorno-Tempini et al. 2011; Josephs et al. 2013; Mesulam 2013), despite a statistical association of lvPPA with Alzheimer's disease (AD) pathology (Grossman, 2010; Gianinni et al, 2017). Likewise, the distribution of pathology in lvPPA has been unclear (Hu et al. 2010). Some have reported no observable difference in neurofibrillary tangle (NFT) density in hippocampus between lvPPA and clinical AD (Josephs et al. 2013), while others have reported minimal NFT pathology in the hippocampus of lvPPA (Gefen et al. 2012). These

inconsistent reports on lvPPA cases may be due in part to the clinical heterogeneity of lvPPA. Recent findings (Sajjadi et al. 2014; Mesulam et al. 2014a; Leyton et al. 2015) showed that not all lvPPA cases are uniform: some displayed only lexical retrieval deficit with predominant atrophy in posterior-inferior temporal-parietal areas, while others displayed additional repetition deficit with prominent atrophy in left superior temporal gyrus. The third subgroup of lvPPA displayed mild deficits in single word comprehension with atrophy extending to the medial aspect of temporal cortex (Leyton et al. 2015). These reports still did not address the question of the appearance of verbal episodic memory performance and the status of the involvement of hippocampus. No group has evaluated the role of lexical retrieval in verbal episodic memory in lvPPA, nor evaluated the anatomical basis for apparent verbal episodic memory difficulty in lvPPA. Here, my research examined more closely the role of a lexical retrieval deficit in verbal episodic memory performance of lvPPA, and gray matter (GM) atrophy associated with these deficits in left lateral and medial temporal lobe (MTL) including hippocampus.

Studies of neurodegenerative patients and fMRI studies of healthy adults have associated lexical retrieval with left middle temporal gyrus (Grossman et al. 2004; DeLeon et al. 2007; Baldo et al. 2013). Since both lvPPA (Gorno-Tempini et al. 2011; Leyton et al. 2015) and clinical AD patients (Grossman et al. 2004; Pekkala et al. 2013) have lexical retrieval difficulty, we predicted that left

middle temporal gyrus would be associated with lexical retrieval in both lvPPA and clinical AD. We also hypothesized that, if a lexical retrieval deficit interferes with delayed free recall in lvPPA, left middle temporal gyrus atrophy would be associated with delayed free recall performance. By comparison, we predicted that delayed verbal free recall performance in clinical typical AD would be associated with hippocampal atrophy. Because the hippocampus is comprised of different subfields, it is possible that subfields within the hippocampus in lvPPA are differentially affected. Thus, there may be selective atrophy of a hippocampal subfield in lvPPA that is too small to see because of the limited spatial resolution of traditional MRI, and this may interfere with verbal episodic memory in lvPPA. Traditional T1 imaging cannot detect subtle changes in hippocampal subfields (Yushkevich et al. 2014). To overcome this issue, we used high in-plane resolution T2 imaging to assess hippocampal subfields. This fine-grained analysis allowed us to examine whether delayed free recall in lvPPA and clinical AD could be due in part to selective atrophy of hippocampal subfields.

As in lvPPA, criteria for PCA requires relatively spared memory. It is difficult to assess the visual episodic memory in PCA given their visuo-perceptual and visuo-spatial difficulty. PCA patients do perform poorly on visual episodic memory tasks, such as recall of the Rey Complex Figure (Crutch et al. 2012). However, reports of visual episodic memory difficulty in PCA are highly variable (Renner et al. 2004; Kas et al. 2011; Ossenkoppele et al. 2015). Unlike

clinical typical AD cases, PCA patients have minimal atrophy in the hippocampus(Lam et al. 2013). One study has reported the deformation of hippocampal shape in PCA (Manning et al. 2015). It is unclear, whether hippocampus is involved in visual episodic memory performance.

The disease in PCA at the early stage may begin in parietal areas, including precuneus. Precuneus is another structure that is widely implicated in episodic memory retrieval (reviewed in (Cavanna and Trimble 2006)). Many studies have reported the activation of precuneus during the episodic memory retrieval of highly imageable pairs of associates (Fletcher et al. 1995), old/new effect or remember/know judgment in a recognition memory paradigm (Addis et al. 2007; Dörfel et al. 2009), as well a retrieval of past episodes and imagining the future (Schacter and Addis 2007). Indeed, the role of precuneus in episodic memory is not surprising given that precuneus is anatomically and functionally connected to the medial temporal lobe, including the hippocampus (Takahashi et al. 2008).

Given the underlying AD pathology, it is unclear whether the visual episodic memory deficit seen in PCA patients is affected directly by their precuneus disease or hippocampal atrophy. Here, we examined both visual perceptual and visual episodic memory function in PCA and related these performances to precuneus atrophy. Because most PCA cases are associated

with AD pathology, I could not rule out selective atrophy of a hippocampal subfield in PCA that is too small to see because of the limited spatial resolution of traditional MRI, and this may interfere with episodic memory in PCA. Thus, I was interested to examine whether MTL subfield atrophy in PCA patients could explain a visual episodic memory deficit. I used fine-grained high resolution imaging that allowed us to quantify the subfields within the MTL. We also included typical amnesic AD patients as lesion control for a comparative study. We hypothesized that PCA patients, unlike typical AD, have visual episodic memory difficulty, and this may be due in part to their precuneus disease, and not due to MTL/hippocampal atrophy.

To summarize, the overarching hypotheses for episodic memory performance in atypical variants of AD (lvPPA and PCA) cases are: 1) Episodic memory in atypical AD may due in part to deficits in other cognitive domains; and 2) Episodic memory in atypical AD may be associated with disease in other, non-MTL brain regions. To test these hypotheses, standard neuropsychological tests that tapped into respective cognitive deficits were employed. Next, we utilized T1 brain imaging to define the gray matter areas that were atrophied in patients compared to demographically matched (age, gender, education) elderly participants. The atrophy of gray matter areas was then related to the performance on neuropsychological tests in lvPPA and PCA. Region of interest of analyses were also employed to examine whether whole hippocampus



was affected. We took a step further to examine whether hippocampal subregions were differentially involved in atypical AD. As mentioned above, the MTL and hippocampus is a complex structure that is comprised of multiple subregions. While hippocampal atrophy may not be detected when performing whole brain analyses and region of interest analyses, it is possible that hippocampal subregions are differentially affected. Traditional T1 brain imaging may not be ideal for detecting differential involvement of MTL and hippocampal subregions. Collaborating with Paul Yushkevich, we were able to utilize a high-resolution T2 imaging sequence that optimized the visualization of hippocampal subregions and allowed me to examine quantitatively whether hippocampal subregions and extrahippocampal structures are differentially affected in these atypical AD cases.

## **CHAPTER II. Project 1: Examine the neuroanatomical basis of verbal episodic memory in lvPPA**

### **Section II.A. INTRODUCTION**

Logopenic variant primary progressive aphasia (lvPPA) is a neurodegenerative condition that is a form of primary progressive aphasia (PPA) characterized by core deficits in repetition and lexical retrieval, a process of linking the semantic representations of objects, actions, thoughts and the like to their corresponding phonological word forms (Gorno-Tempini et al. 2011; Leyton and Hodges 2013; Mesulam et al. 2013). According to the published diagnostic criteria (Gorno-Tempini et al. 2011), verbal episodic memory should be spared. However, evaluations of verbal episodic memory have been inconsistent in lvPPA (Rohrer et al. 2013; Flanagan et al. 2014). This is frequently assessed with delayed free recall, where participants name a list of recalled words after a delay period. However, recall may be confounded by the lexical retrieval deficit in lvPPA. Thus, their failure to retrieve the respective phonological word form of the target word can easily be confused with their inability to recall this target word on the memory paradigm. One group has assessed both verbal and non-verbal episodic memory in PPA patients, and shown verbal retrieval failures compared to relatively successful visual memory (Weintraub et al. 2013). However, this group studied a mixture of PPA variants (including agrammatic, logopenic, and semantic). Moreover, this study did not clarify whether delayed verbal free recall

deficits in lvPPA specifically are due to hippocampal-mediated episodic memory difficulties or limited lexical retrieval.

Reports of hippocampal atrophy in lvPPA also have been inconsistent (Gorno-Tempini et al. 2011; Josephs et al. 2013; Mesulam 2013), despite a statistical association of lvPPA with Alzheimer's disease (AD) pathology (Grossman 2010). Likewise, the distribution of pathology in lvPPA has been unclear (Hu et al. 2010). Some have reported no observable difference in neurofibrillary tangle (NFT) density in hippocampus between lvPPA and clinical AD (Josephs et al. 2013), while others have reported minimal NFT pathology in the hippocampus of lvPPA (Gefen et al. 2012). These inconsistent reports on lvPPA cases may be due in part to the clinical heterogeneity of lvPPA. Recent findings (Sajjadi et al. 2014; Mesulam et al. 2014a; Leyton et al. 2015) showed that not all lvPPA cases are uniform: some displayed only lexical retrieval deficit with predominant atrophy in posterior-inferior temporal-parietal areas, while others displayed additional repetition deficit with prominent atrophy in left superior temporal gyrus. The third subgroup of lvPPA displayed mild deficits in single word comprehension with atrophy extending to the medial aspect of temporal cortex (Leyton et al. 2015).

No group has evaluated the role of lexical retrieval in verbal episodic memory in lvPPA, nor evaluated the anatomical basis for episodic memory difficulty in lvPPA. Here, we examined more closely the role of a lexical retrieval

deficit in verbal episodic memory performance of lvPPA, and gray matter (GM) atrophy associated with these deficits in left lateral and medial temporal lobe (MTL) including hippocampus. Studies of neurodegenerative patients and fMRI studies of healthy adults have associated lexical retrieval with left middle temporal gyrus (Grossman et al. 2004; DeLeon et al. 2007; Baldo et al. 2013). Since both lvPPA (Gorno-Tempini et al. 2011; Leyton et al. 2015) and clinical AD patients (Grossman et al. 2004; Pekkala et al. 2013) have lexical retrieval difficulty, we predicted that left middle temporal gyrus would be associated with lexical retrieval in both lvPPA and clinical AD. We also hypothesized that, if a lexical retrieval deficit interferes with delayed free recall in lvPPA, left middle temporal gyrus atrophy would be associated with delayed free recall performance. By comparison, we predicted that delayed free recall performance in clinical AD would be associated with hippocampal atrophy. Because the hippocampus is comprised of different subfields, it is possible that subfields within the hippocampus in lvPPA are differentially affected. Traditional T1 imaging cannot detect subtle changes in hippocampal subfields (Yushkevich et al. 2014). To overcome this issue, we used high in-plane resolution T2 imaging to assess hippocampal subfields. This fine-grained analysis allowed us to examine whether delayed free recall in lvPPA and clinical AD could be due in part to selective atrophy of hippocampal subfields.

## **Section II.B. METHODS**

### **Participants**

We studied 38 right-handed native English-speakers with lvPPA (n=12) or clinical AD (n=26), and 16 healthy controls [Mini-Mental State Examination (MMSE; (Folstein et al. 1975a) > 27] with comparable gender [ $X^2=0.08$ ;  $p>0.05$ ], age [ $F(2,51)=1.24$ ;  $p>0.05$ ], and education [ $F(2,51)=0.49$ ;  $p>0.05$ ] recruited from the Frontotemporal Degeneration Center at the University of Pennsylvania. lvPPA and AD patients were matched in MMSE [ $U=94.5$ ,  $Z=-1.95$ ,  $p>0.05$ ] and disease duration [ $U=153.50$ ,  $Z=-0.08$ ,  $p>0.05$ ]. Because we were interested in whether lexical retrieval modulates verbal episodic memory, Boston Naming Test (BNT; (Williams et al. 1989) performance in lvPPA and AD was matched [ $U=111.00$ ,  $Z=-1.43$ ,  $p>0.05$ ]. Diagnoses were established using published criteria for lvPPA (Gorno-Tempini et al. 2011) and clinical AD (McKhann et al. 2011) by board-certified neurologists (DJI, MG) based on a mental status examination. Clinically, lvPPA patients displayed word-finding and repetition problems while clinical AD patients displayed episodic memory difficulties. Exclusionary criteria included vascular disease, structural brain abnormalities such as hydrocephalus, medical diseases interfering with cognition, and primary psychiatric disorders. Nine of twelve lvPPA patients had cerebrospinal fluid (CSF) data: 8 with CSF ABeta42<192 pg/ml [mean (S.D.) = 127.38 (27.43)] that is consistent with likely AD pathology and 1 without this criterion (ABeta42>192

pg/ml: 357 pg/ml). Fourteen of 26 clinical AD patients had available CSF data with ABeta42<192 pg/ml [mean (S.D.) = 124.14 (20.67)].

## **Behavioral methods**

Neuropsychological testing included a 30-item BNT ((Williams et al. 1989) to assess lexical retrieval; the delayed free recall component of the Philadelphia Verbal Learning Test (PVL; (Libon et al. 2011a), a 9-word list-learning task (drawn from 3 semantic categories {tools, fruits, furniture} with 5 learning trials, immediate recall and delayed recall probes, and recognition with equal numbers of foil types (semantic, interference, unrelated) to assess verbal episodic memory; and forward digit span (FDS; (Wechsler 1997) to assess repetition. To minimize the lexical retrieval component of verbal episodic memory, we also assessed the recognition component of PVL (Libon et al. 2011a) using d-prime, the difference between the z-transforms of hit rate and false alarm rate, to account for the false positive alarm rate. Shapiro-Wilk test showed that demographic variables were normally distributed ( $p > 0.05$ ) but neuropsychological variables were not ( $p < 0.05$ ). Hence, neuropsychological variables were assessed using non-parametric tests including  $X^2$ , Mann-Whitney U, and Kruskal-Wallis.

**Standard protocol approvals, registrations, and patient consents.** All subjects completed a written informed consent procedure in accordance with the Declaration of Helsinki and approved by the institutional review board (IRB) of the University of Pennsylvania. The study was approved by the University of Pennsylvania's IRB.

## Imaging

We included subsets of lvPPA (n=10; 8 with AD-CSF and 1 without) and AD (n=26; 14 with AD-CSF and 1 without) patients who had available high-resolution T1 MRI scans, and an independent group of 17 healthy matched controls (gender:  $X^2=1.27, p>0.05$ ; age:  $X^2=0.38, p>0.05$ ; education:  $X^2=1.00, p>0.05$ ). These participants underwent a structural T1-weighted, 3-dimensional, spoiled gradient-echo sequence, which was obtained on a Siemens 3.0T Trio scanner with an 8-channel head coil with sequence parameters of TR = 1620 ms, TE = 3 ms, flip angle = 15°, matrix = 192 × 256, slice thickness = 1 mm, and in-plane resolution = 1 × 1 mm. The images were normalized to a standard space and segmented using the Advanced Normalization Tools (ANTs) (<http://www.picsl.upenn.edu/ANTS/>) PipeDream interface (<http://sourceforge.net/projects/neuropipedream/>) (Tustison et al., 2014). Reasons for exclusion included health and safety (e.g., metallic implants, shrapnel, claustrophobia), intercurrent illness, scheduling and transportation difficulty. Imaging was acquired within 6 months ( $\mu=2.6$  months,  $\sigma=2.6$ ) of behavioral data. We used Advanced Normalization Tools (ANTs), a state-of-the-art pipeline, for all image processing, as described elsewhere (McMillan and Wolk 2016).

**T1 Whole-Brain Imaging Analysis.** Non-parametric permutation-based imaging analyses were performed with threshold-free cluster enhancement (TFCE)



(Smith and Nichols 2009) using the randomise tool in FSL (<http://fsl.fmrib.ox.ac.uk/fsl/fslwiki>). GM density was compared in lvPPA relative to controls. A t-test analysis was run with 10,000 permutations that is equivalent to a contrast corrected for multiple comparisons. The analyses were restricted to voxels containing GM using an explicit mask generated from the average GM probability map of all groups. We report clusters that survived a threshold of  $p < 0.005$  (uncorrected with TFCE), and contained a minimum of 50 adjacent voxels.

To relate behavioral performance to significant GM atrophy, we used the randomise tool of FSL to compute regression analyses between lvPPA patients' performance on a target task and GM density in regions of the brain showing GM atrophy relative to controls. Permutations were run exhaustively up to a maximum of 10,000 for each analysis. We reported clusters surviving a height threshold of  $p < 0.05$  uncorrected with TFCE and a minimum of 10 adjacent voxels. We used a very liberal statistical threshold purposefully to see if there is any possibility of a regression between episodic memory functioning and GM density in MTL of lvPPA.

**Peak Voxel Region of Interest (ROI).** Because we were interested to assess whether the region of left middle temporal gyrus identified in lvPPA was also implicated in AD performance, we extracted the statistically-significant peak voxel from the left middle temporal gyrus cluster identified in lvPPA (see below) and

used this peak voxel as our label for left middle temporal gyrus in AD. GM density at this peak voxel in left middle temporal gyrus was calculated in AD patients and controls, and Spearman correlation assessed an association between GM density of left middle temporal gyrus and BNT and delayed free recall in AD.

**T2 Medial Temporal Lobe Imaging.** To determine whether lvPPA patients had subtle hippocampal atrophy that could have impacted their verbal episodic memory, we examined the subset of patients who had high-resolution T2-weighted scan with the 8-channel coil (7 lvPPA {6 with AD-CSF, 1 without}, 19 AD (11 with AD-CSF, 1 without), and 17 demographically-matched controls. The parameters of the T2 are the following: TR/TE: 5310/68 ms, echo train length 15, 18.3 ms echo spacing, 150 flip angle, 0% phase oversampling, 0.4 3 0.4 mm<sup>2</sup> in plane resolution, 2 mm slice thickness, 30 interleaved slices with 0.6 mm gap, acquisition time 7:12 min. Images of each subject were labeled using the Automatic Segmentation of Hippocampus Subfields (ASHS) software (Yushkevich et al. 2014). This method utilizes a training and a segmentation pipeline that combines a multi-atlas label fusion (Wang et al. 2013) and a learning-based error correction module to produce a fully automated segmentation of Cornu Ammonis (CA), dentate gyrus (DG), and subiculum subfields along the entire length of the hippocampal formation, as well as segmentation of extrahippocampal structures, entorhinal (ERC) and perirhinal

cortices (BA35 and BA36). Briefly, candidate segmentations of a subject's T2-MRI were obtained using high-dimensional mapping to multiple manually labeled atlas images, and then fused into a consensus segmentation, taking into account the similarity between a subject's image and atlas images. Patterns of systematic segmentation errors are learned *a priori* using training data, and are corrected in a further post-processing step, to generate the final segmentation. Reliability of automated labeling for these subfields is generally high, as reported (Yushkevich et al. 2014), but CA2/3 were excluded since their segmentation was not reliable. Volumetric measures of the hippocampal subfields and thickness of extrahippocampal subfields were extracted for quantitative comparisons across cohorts. Thickness was used for extrahippocampal subfields since these subfields were not segmented throughout the entire anterior-posterior axis of MTL and we needed to normalize the volume by the number of segmented slices. Spearman correlation analyses were performed to relate MTL subfield atrophy to BNT as well as delayed free recall.

## **Section II.C. RESULTS**

### **Behavioral Analysis**

Compared to controls, worse MMSE was observed in lvPPA [U=18.00, Z=-3.83, p<0.001] and AD [U=2.00, Z=-5.42, p<0.001]. However, lvPPA and AD patients were matched in MMSE (Folstein et al. 1975b) [U=94.5, Z=-1.95, p>0.05] and disease duration [U=153.50, Z=-0.08, p>0.05]. Consistent with their clinical phenotype, lvPPA patients were more impaired on BNT [U=47.00, Z=-2.31, p<0.05] and FDS [U=21.50, Z=-3.54, p<0.001] than controls. FDS also was worse in lvPPA than AD (U=73.00, Z=-2.66, p<0.05). Though recognition memory was intact in lvPPA relative to controls [U=66.50, Z=-1.49, p>0.05], these patients exhibited worse delayed free recall relative to controls [U=39.00, Z=-2.69, p<0.01]. A correlation analysis revealed that BNT was associated with delayed free recall in lvPPA (rs=0.721, p=0.019) but BNT was not associated with recognition memory (rs=0.302, p=0.34). Intact verbal recognition memory suggested relatively preserved verbal episodic memory in lvPPA, and a common cognitive mechanism underlying impairments in lexical retrieval and delayed free recall in lvPPA.

Relative to controls, AD performed worse on BNT [U=52.50, Z=-4.05, p<0.001], delayed free recall [U=22.00, Z=-4.91, p<0.001] and recognition memory [U=78.50, Z=-3.39, p<0.005] but had intact FDS [U=133.00, Z=-1.68, p>0.05]. Relative to lvPPA, AD had worse delayed free recall [U=70.50, Z=-2.76,

p<0.01] and recognition memory (U=89.5, Z=-2.10, p<0.05). Unlike lvPPA, there was no association between delayed free recall and BNT in AD (r=0.110, p=0.591).

## **Imaging Analysis**

**Whole-Brain Imaging.** We examined whether there was a shared neuroanatomic substrate for BNT and delayed free recall in lvPPA. Compared to controls, lvPPA displayed GM atrophy only in left middle temporal gyrus (Fig.1), while the hippocampus was spared. Regression was used to relate behavioral performance to GM atrophy in lvPPA; decreased performance on both BNT (Fig.1, Panel A) and delayed free recall (Fig.1, Panel B) was related to left middle temporal gyrus atrophy.

**Region of Interest Analysis.** GM density at the peak voxel of left middle temporal gyrus cluster associated with BNT and delayed free recall in the whole-brain regression analysis described above was extracted for every participant of the cohort. GM density of this peak voxel was reduced in lvPPA compared to controls [ $U=61.00$ ,  $Z=-2.01$ ,  $p<0.05$ ] and in AD compared to controls [ $U=114.00$ ,  $Z=-2.52$ ,  $p<0.05$ ]. Reduced GM density at this left middle temporal gyrus voxel in AD was associated with decreased performance on BNT ( $r=0.537$ ,  $p=0.006$ ) but not with delayed free recall ( $p>0.05$ ).

**MTL subfield Imaging.** We examined whether hippocampal (CA1, DG, and subiculum) and extra-hippocampal subfields (ERC, BA35, and BA36) were differentially affected in lvPPA (Fig. 2, Panel A). Consistent with whole-brain regression results, there was no significant difference in hippocampal and extrahippocampal subfields between lvPPA and controls. However, AD patients

had differential MTL subfield atrophy compared to controls. This included bilateral CA1 and DG (Fig. 2. Panel B; left CA1 [ $p < 0.001$ ], right CA1 [ $p < 0.001$ ], left DG [ $p < 0.005$ ], right DG [ $p < 0.005$ ]). AD also showed atrophy in extra-hippocampal subfields (Fig2, Panel B), including left ERC [ $p < 0.05$ ] and right BA35 [ $p < 0.01$ ]).

Spearman correlation was used to assess an association between MTL subfields and behavioral performance. Neither BNT nor delayed free recall was associated with MTL subfields in lvPPA. In AD, both left CA1 [ $r_s = 0.543, p = 0.016$ ] and right CA1 [ $r_s = 0.473, p = 0.022$ ] were associated with delayed free recall, but not BNT ( $p > 0.05$ ).

## **Section II.D. DISCUSSION**

The status of verbal episodic memory performance in lvPPA is unclear. In this study, we aimed to elucidate whether the core language deficit in lexical retrieval in lvPPA interferes with their verbal episodic memory functioning and whether hippocampus disease also contributes to episodic memory difficulty, given the statistical likelihood of underlying AD pathology (Josephs et al. 2008; Grossman 2010; Mesulam et al. 2012). We found impaired lexical retrieval in lvPPA, and this correlated with their delayed verbal free recall performance. This was mediated by a common neural substrate in left middle temporal gyrus, but did not appear to be associated with MTL. Although CSF analyses indicated that likely AD pathology was present in a majority of lvPPA cases, detailed examination of hippocampal subfields failed to reveal any atrophy in lvPPA relative to controls. By comparison, clinical AD patients had atrophy in MTL subfields, which was associated with verbal episodic memory difficulty, while BNT was associated with left middle temporal gyrus. These findings are consistent with other reports of quantitative pathologic evidence of a hippocampal-sparing aphasic variant with AD pathology, which has disproportionate amount of NFT in cortical areas with relative sparing of the hippocampus (Janocko et al. 2012). The hippocampal-sparing variant of AD with primarily progressive aphasia due to prominent neocortical AD pathology accumulation is different from typical amnesic AD, where the NFT distribution



follows the Braak staging pattern (Braak and Braak 1991), of significant NFT burden in medial temporal lobe structures, including the hippocampus, relative to NFT distribution in the cortex. These different clinical and pathological variants of AD call to question the hypothesis that pathology originates in the MTL of all patients with AD pathology.

According to the 2011 criteria for PPA (Gorno-Tempini et al. 2011), patients are diagnosed with lvPPA if they exhibit impaired lexical retrieval and repetition as their primary deficit, with relatively preserved episodic memory. Given that lvPPA is a form of aphasia, most studies have focused on the language domain and have not evaluated the role of memory performance in the difficulties associated with diagnosing lvPPA. Evaluating verbal episodic memory performance in lvPPA may pose a challenge. Indeed, reports of verbal episodic memory performance in lvPPA have been inconsistent, with some reporting impaired memory (Flanagan et al. 2014; Piguet et al. 2015; Ramanan et al. 2016) and one study observing equally impaired verbal episodic memory and recognition memory in AD and lvPPA patients who also had visual memory difficulty (Ramanan et al. 2016), while others found no deficit (Weintraub et al. 2013; Mesulam et al. 2014b).

Verbal episodic memory is typically tested using delayed free recall, which requires lexical retrieval and production, and therefore verbal episodic memory can be confounded by the lexical retrieval deficit observed in lvPPA. However,

previous work has not indicated whether verbal episodic memory difficulty is associated with impaired lexical retrieval. We found verbal episodic memory difficulty in lvPPA and that this deficit was correlated with their impaired lexical retrieval, raising the possibility that lexical retrieval difficulty may underlie in part the verbal episodic memory deficit that is reported at times in lvPPA. We also found that our lvPPA cohort had preserved verbal recognition memory, and we hypothesize that this was because this form of verbal episodic memory testing does not require lexical retrieval and production. While it is possible that successful recognition memory performance was due in part to the fact that this is an easier task than delayed free recall, it is noteworthy that the clinical AD patients matched the lvPPA patients in MMSE, yet lvPPA patients were significantly less impaired in their recognition memory than AD. Another group reported similar findings, where PPA patients were impaired on verbal recall, but their performance on verbal recognition memory was near ceiling compared to controls (Weintraub et al. 2013). Additional work is needed to evaluate episodic memory performance in lvPPA.

Our findings associated lexical retrieval difficulty in lvPPA with atrophy of left middle temporal gyrus. This area has been widely implicated in lexical retrieval in lvPPA (Henry and Gorno-Tempini 2010; Leyton and Hodges 2013; Mesulam et al. 2013; 2014a) as well as AD (Harasty et al. 1999; Grossman et al. 2004; Apostolova et al. 2008) and stroke (DeLeon et al. 2007; Indefrey 2011).

Moreover, delayed free recall performance in lvPPA was related to the same area of left middle temporal gyrus, underlining the contribution of impaired lexical retrieval to the verbal episodic memory deficits of lvPPA. Moreover, there was no hippocampal atrophy in lvPPA that could have explained any memory difficulty. Our study also found that lexical retrieval difficulty in AD is associated with the same cluster of left middle temporal gyrus that was atrophied in lvPPA. Unlike lvPPA, delayed free recall performance in AD was not related to left middle temporal gyrus.

Despite the presence of likely AD pathology in most of our lvPPA cohort, detailed analysis reveal no observable changes in hippocampal and extrahippocampal subfields compared to controls, while AD patients showed hippocampal subfield atrophy that was associated with their verbal episodic memory deficit. Involvement of the hippocampus in the neuroimaging and pathological literature in lvPPA has been inconsistent. One report described greater NFT burden in language-related areas and throughout the left hemisphere than entorhinal cortices in lvPPA, and that NFT deposition is greater in the left peri-Sylvian language cortices than typical AD patients (Gefen et al. 2012). Others reported no observable difference in NFT density in the hippocampus in lvPPA compared to AD, consistent with their imaging result, although NFT density ratio in temporoparietal areas relative to hippocampus is higher in lvPPA (Josephs et al. 2013). MMSE of lvPPA reported in this paper

was in the moderately impaired range ( $14.3\pm 7.7$ ), reflecting patients with considerably more cognitive impairment than our cohort, and this may explain in part the discrepancy with findings of the present study where patients had milder cognitive impairment (MMSE:  $25.67\pm 3.2$ ). Other sources of discrepancy in the literature may be due in part to the relatively small sample sizes of lvPPA, different severity and disease duration of patient groups, and pathological observations typically obtained many years after the clinical phenotype has been ascertained. Nevertheless, paralleling our findings, a functional connectivity study demonstrated that the language network encompassing left posterior temporal areas is more affected in lvPPA than in AD, while the ventral default mode network associated with episodic memory was affected in AD more than lvPPA (Whitwell et al. 2015). Longitudinal imaging studies of lvPPA patients have suggested that the atrophy initially involving the left temporoparietal region subsequently spreads to include other left hemisphere regions (Rohrer et al. 2010; Rogalski et al. 2011a), although the presence of likely AD pathology was assessed only in a small number of cases. Hippocampal-sparing variant of AD cases has been identified as one of the three AD subtypes [amnesic AD (75% out of 889 cases), hippocampal sparing (11%), and limbic predominant (14%)] in autopsy series of patients with AD pathology (Murray et al. 2011). Our findings, together with these suggestive studies, raise the possibility of a variant of AD where pathology does not originate in the MTL, and suggest that the lvPPA

phenotype may be a marker of this variant. Findings such as these warrant more detailed examination of hypotheses concerned with spreading pathology in neurodegenerative diseases such as AD.

Some limitations must be considered when interpreting our data. First, atrophy in our lvPPA cohort was limited to left middle temporal gyrus. Other neuroimaging studies have shown a greater extent of atrophy encompassing left temporal-parietal junction (Gorno-Tempini et al. 2004; Migliaccio et al. 2009a). When using a more liberal threshold ( $p < 0.01$ , uncorrected), we also observed a similar atrophy pattern in left temporal and parietal areas area consistent with other neuroimaging studies. However, we did not observe left MTL atrophy even at this more liberal threshold in our lvPPA cohort. Second, while our cohorts were carefully matched, our sample size was relatively small. Larger cohorts of lvPPA patients are needed to assess these brain-behavior relationships more reliably. Although our patients had a typical phenotype of lvPPA that is statistically associated with AD pathology, two of our cases did not have CSF available that could have provided biomarker evidence of AD. Additional longitudinal studies would be helpful in resolving discrepancies concerning disease severity across studies. Lastly, our lvPPA cohort was relatively young, as was our matched AD group. Caution thus must be exercised in generalizing our findings to late-onset patients with lvPPA and AD.

With these caveats in mind, we conclude that lexical retrieval difficulty in

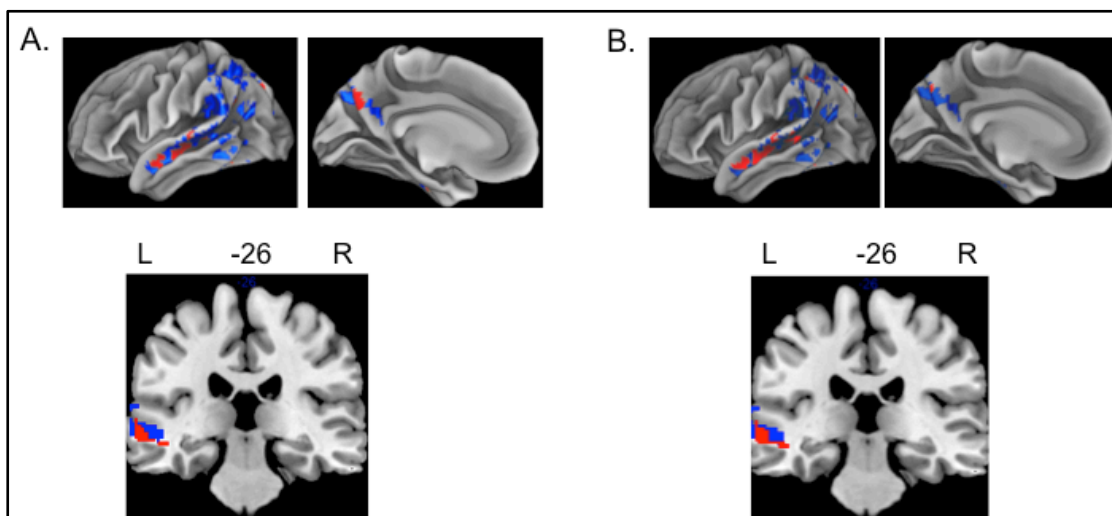
lvPPA interferes with verbal episodic memory functioning, and left middle temporal gyrus disease may be contributing to this common cognitive mechanism. No hippocampal atrophy was evident despite the presence of likely AD pathology in lvPPA. Verbal delayed free recall thus can be confounded by lexical retrieval difficulty in lvPPA, and this confound may be circumvented in part with recognition memory testing. Although both our AD and lvPPA cohorts were cognitively comparable, the cognitive and anatomical profile of lvPPA is distinct from AD, where the apparent memory deficit was mediated by hippocampal disease and was not modulated by lexical retrieval difficulty or left middle temporal gyrus atrophy. These distinctions suggest that lvPPA may be a marker for an atypical, hippocampal-sparing variant of AD pathology that may not originate in the MTL.

**Section II.E. Tables/Figures**

**Table 1. Mean (standard deviation) demographic & clinical features of the cohorts**

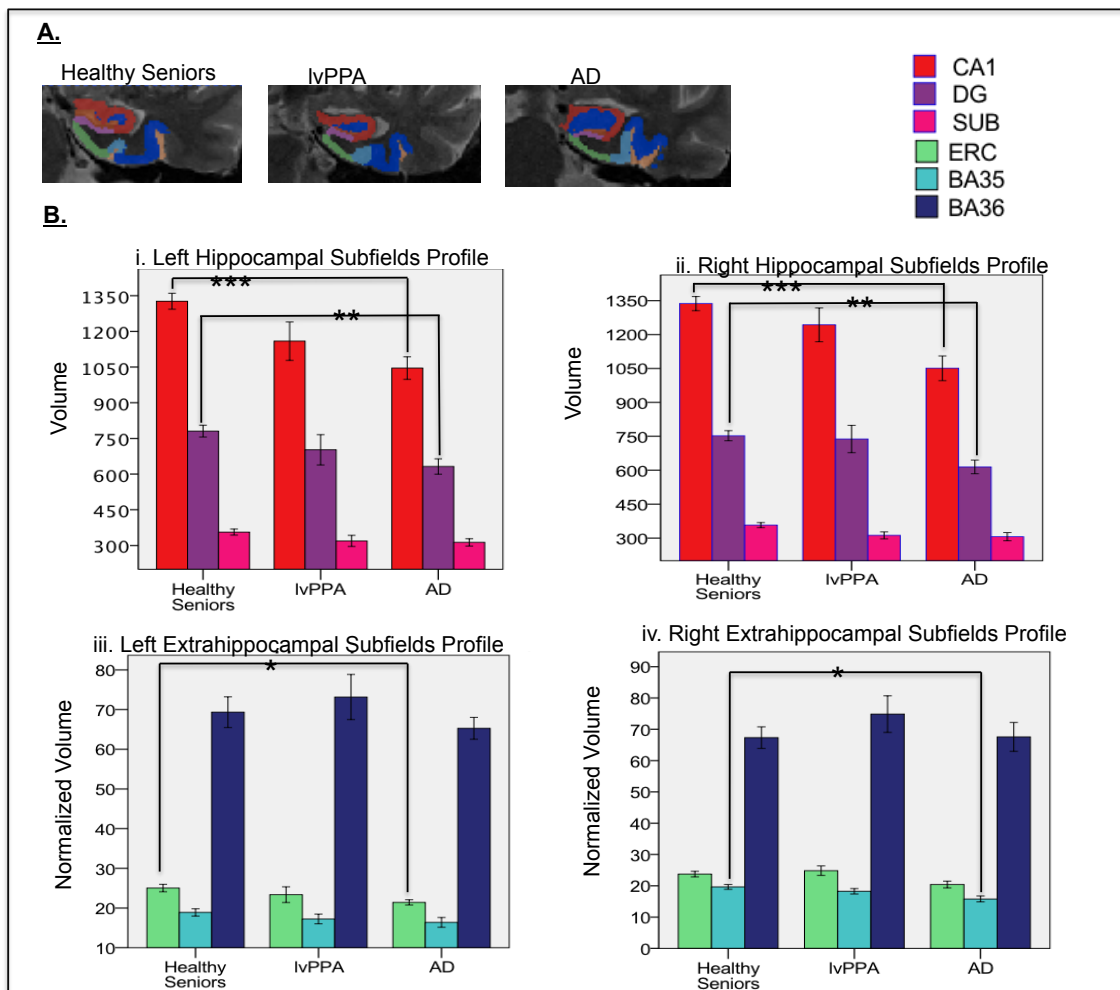
<b>Measure</b>	<b>lvPPA (n=12)</b>	<b>AD (n=26)</b>	<b>Healthy Seniors (n=16)</b>
<b><u>Demographic features of the cohorts</u></b>			
Gender (Male/Female)	5/7	14/12	7/9
Age, years	63.10 (8.80)	64.73 (7.78)	69.00 (9.13)
Education, years	16.08 (4.12)	15.19 (2.68)	15.94 (2.49)
Disease Duration, years	3.75 (2.38)	3.73 (2.00)	N/A
<b><u>Neuropsychological performance</u></b>			
Mini Mental State Exam (max=30)	25.67 (3.20)	23.69 (2.19)	29.63 (0.72)
Forward digit span (# digits)	4.67 (1.07)	5.88 (1.45)	6.68 (1.20)
Boston Naming Test (max=30)	23.75 (6.77)	22.85 (5.11)	28.19 (1.97)
Recognition Memory (d- prime)	2.77 (0.57)	1.88 (1.04)	3.04 (0.24)
Delayed free recall (max=9)	4.58 (3.15)	1.73 (2.51)	7.69 (1.30)

**Figure 1. Whole Brain Atrophy and Regression in IvPPA.** Pattern of atrophy of gray matter (GM), shown in blue (surface rendering and coronal slice), in IvPPA compared to controls. Atrophy was found only in the left hemisphere; these areas include middle temporal and parietal areas, significant at  $p < 0.005$  (uncorrected with threshold-free cluster enhancement). A) Decreased performance on BNT related to GM atrophy is shown in red. B) Decreased performance on delayed free recall related to GM is shown in red. Left middle temporal gyrus regression for both BNT and delayed free recall was shown in the coronal slice.





**Figure 2.** A: A representative segmentation of left MTL subfields in one of the participants in each group (healthy senior, IvPPA, AD) shown in a coronal view. B: Profile of volume of left and right hippocampal and extrahippocampal subfields across cohorts. \*\*p<0.01, \*\*\*p<0.001. Cornu Ammonis (CA), dentate gyrus (DG), subiculum (SUB), entorhinal (ERC) and perirhinal cortices (BA35 and BA36).



## **CHAPTER III. Project 2: Examine the neuroanatomical basis of visual episodic memory in PCA**

### **Section III.A. INTRODUCTION**

Posterior cortical atrophy (PCA) is a neurodegenerative disorder characterized by a progressive decline in visuospatial and visuoperceptual processing (Crutch et al. 2017). Consistent with the clinical phenotype, the predominant site of atrophy in PCA involves areas of the cerebrum that are important for visual perceptual-spatial processing, including occipital and posterior temporal and parietal cortices as well as precuneus. According to the most recent international consensus criteria, episodic memory is relatively spared (Crutch et al. 2017). This is an important consideration since clinical-pathological studies of PCA have shown that the overwhelming majority of reported cases have microscopic abnormalities most consistent with histopathology features of Alzheimer's disease. Most studies examining the neuropsychological characteristics of PCA corroborated this criterion of relatively spared episodic memory compared to their predominant deficit in the visuoperceptual and visuospatial domain (Renner et al. 2004; Charles and Hillis 2005; Migliaccio et al. 2009b; Kas et al. 2011; Crutch et al. 2012; Borruat 2013; Crutch et al. 2013a; Ossenkoppele et al. 2015), suggesting that PCA is a non-amnestic variant of AD. These studies have reported on verbal recall performance in PCA patients, which is relatively preserved, but visual episodic memory performance such as recall of

a complex visual geometric figure like the Rey Figure has not been reported frequently or examined carefully in PCA patients due to their difficulty in visual domain. Indeed, PCA patients appear to perform poorly on visual episodic memory tasks (Kennedy et al. 2012). Although this case study examined visuo-perceptual and visuo-spatial functioning in PCA, Kennedy and colleagues (2012) did not take into account of visuo-perceptual and visuo-spatial difficulty while assessing the visual memory. It is, therefore, unclear whether visual episodic memory deficits in PCA are due to impairment in episodic memory or to their impairment in visuo-perceptual and visuo-spatial processing.

Although most PCA cases have AD as their underlying pathology, PCA differs from typical AD cases with amnesic memory difficulty because PCA patients are said to have minimal atrophy in the hippocampus (Lehmann et al. 2011; Crutch et al. 2012; Ossenkoppele et al. 2015). The hippocampus and the medial temporal lobe (MTL) are the structures most commonly associated with episodic memory difficulty and hypothesized to be the site of pathological onset of AD (Braak and Braak 1991). Most MRI assessments of the hippocampus and MTL use whole-brain imaging, but this may miss atrophy in a hippocampal subfield that may be interfering with memory functioning. Precuneus is another structure that is widely implicated in episodic memory, in addition to its role in visuo-spatial and visuo-perceptual processing (reviewed Cavanna and Trimble, 2006; (Trimble and Cavanna 2008)). Kas and colleagues (2011) reported that

perfusion of precuneus is correlated with behavioral phenotype of PCA syndrome, including apraxia, acalculia, ocular apraxia, optic apraxia and Balint's syndrome (Kas et al. 2011). Precuneus contributes to oculomotor guidance and spatial control of motor activity (Cavanna and Trimble 2006). In addition to this role, studies have reported the activation of precuneus in healthy subjects during recognition memory (Addis et al. 2007; Dörfel et al. 2009) and retrieval of past episodes (Schacter and Addis 2007). In typical AD patients, precuneus is one of the earliest regions of hypoperfusion (Asllani et al. 2007; Langbaum et al. 2010; Miners et al. 2016) . Indeed, its role in episodic memory may not be surprising given that precuneus is anatomically and functionally connected to the MTL including the hippocampus (Takahashi et al. 2008). From this perspective, it is unclear whether precuneus is contributing to visual perceptual-spatial difficulties, memory deficits, or both in PCA.

In the present study, we examined both visual perceptual-spatial and visual episodic memory function in PCA, and examined whether performance is related to precuneus and hippocampal atrophy, including hippocampal subfields. We hypothesized that PCA patients have visual perceptual-spatial deficits as well as visual episodic memory difficulty that are associated in part with precuneus disease, and unlike typical AD, their memory difficulty is less associated with hippocampal atrophy. To examine the involvement of precuneus and hippocampus in visual perceptual-spatial and visual episodic memory functioning

in PCA, we also performed region of interest analyses and general linear model analyses to assess whether precuneus and hippocampus were related to visual episodic memory performance. Because the MTL is a complex structure consisting of multiple subregions, we also used high resolution T2 imaging to quantitatively examine whether hippocampal and extrahippocampal subfields were affected.

## **Section III.B. METHODS**

### **Participants**

We studied 42 right-handed native English-speakers with PCA (n=13), typical AD (n=17), and 12 healthy seniors (MMSE > 27) recruited from the Penn Frontotemporal Degeneration Center of the Department of Neurology at the University of Pennsylvania. Both our PCA and AD cohorts were seen by board-certified neurologists (DI, MG): diagnosis for our PCA cohort was established by criteria suggested by Crutch et al (2017) and were consistent with previous descriptions of PCA (Tang-Wai, 2004; McMonagle et al., 2006; Crutch 2012); diagnosis for our AD cohort is consistent with criteria for mild amnesic AD (McKhann et al., 2011). Clinically, PCA patients displayed visuo-perceptual and visuospatial problems, including core features of Balint's syndrome such as difficulty locating objects in space, difficulty with body-part relationships, and difficulty with dressing and performing other spatially-mediated tasks, while AD patients displayed episodic memory difficulties. A consensus evaluation was used to confirm clinical diagnosis, based on a semi-structured neurologic history, a complete neurologic examination, and a detailed mental status assessment. CSF examination in PCA (n=9 have available CSF data) and AD (n=17) was consistent with underlying AD pathology in both groups as 100% of PCA patients and 100% of AD patients had CSF level of beta-amyloid1-42 <192 pg/ml. As summarized in Table 1, groups were matched for gender [ $X^2(2)=0.522$ ;  $p>0.05$ ],

age [ $F(2,39)=2.18$ ;  $p > 0.05$ ], and education [ $F(2,39)=0.38$ ;  $p > 0.05$ ]. Disease duration between patient groups was matched [ $U=101.00$ ,  $Z=-0.41$ ,  $p > 0.05$ ]. Exclusionary criteria included evidence of vascular disease or structural brain abnormalities such as hydrocephalus, but MRI was not used for diagnostic purposes. Patients were also excluded on the basis of medical diseases interfering with cognition and primary psychiatric disorders.

### **Behavioral methods**

Participants had neuropsychological testing that included mini-mental state examination (MMSE; Folstein et al., 1975) to assess the disease severity; modified Rey Complex Figure (Lezak et al. 2012) from Philadelphia Brief Assessment of Cognition ((Libon et al. 2011b); total score=12 instead of 36 using a specific scoring algorithm) recall one minute after their copy to assess visual episodic memory. To account for visuoperceptual difficulty on visual episodic memory performance, we calculated the percentage of modified Rey Recall performance in each individual based on the elements presented in the individual's modified Rey Copy performance (recall score divided by copy score; referred to as percentage of copied recall in Table 1). To assess verbal episodic memory, we used verbal learning and memory from Philadelphia Brief Assessment of Cognition (Libon et al. 2011b), which is a six-word list administered over three trials. Verbal delayed free recall for this list was assessed

after a 1–2-minute filled delay. Between-group differences in neuropsychological variables were assessed using  $\chi^2$  tests, t-tests, analysis of variance (ANOVA), Mann-Whitney U-Test and Tukey test, as appropriate.

**Standard protocol approvals, registrations, and patient consents.** All subjects completed a written informed consent procedure in accordance with the Declaration of Helsinki and approved by the institutional review board of the University of Pennsylvania.

### **Imaging methods.**

For imaging analyses, all 13 PCA and 17 AD patients had high-resolution T1 MRI scans, and imaging in controls was obtained from an independent group of 16 healthy seniors with comparable gender [ $\chi^2(2)=0.51$ ;  $p=.98$ ], age [ $F(2,42)=1.82$ ;  $p=0.174$ ], and education [ $F(2,42)=0.15$ ;  $p=0.87$ ]. These participants underwent a structural T1-weighted, 3-dimensional, spoiled gradient-echo sequence, which was obtained on a Siemens 3.0T Trio scanner with an 8-channel head coil with sequence parameters of TR = 1620 ms, TE = 3 ms, flip angle = 15°, matrix = 192 x 256, slice thickness = 1 mm, and in-plane resolution = 1 x1 mm. The images were normalized to a standard space and segmented using the Advanced Normalization Tools (ANTs) (<http://www.picsl.upenn.edu/ANTS/>) PipeDream interface (<http://sourceforge.net/projects/neuropipedream/>) (Tustison et al. 2014).



Imaging was acquired within 6 months ( $\mu=2.6$  months,  $\sigma=2.6$ ) of behavioral data.

**T1 Whole Brain Imaging Analysis.** Non-parametric permutation-based imaging analyses were performed using the randomise tool in FSL (<http://fsl.fmrib.ox.ac.uk/fsl/fslwiki>) with TFCE (Smith and Nichols 2009). Gray matter (GM) density was compared in PCA and AD relative to healthy seniors. A t-test analysis was run with 10,000 permutations that is equivalent to a contrast corrected for multiple comparisons. The analyses were restricted to voxels containing GM using an explicit mask generated from the average GM probability map of all groups. We report clusters that survived a threshold of  $p<0.005$  (FWE corrected), and contained a minimum of 50 adjacent voxels.

To relate behavioral performance to regions of significant GM disease, we used the randomise tool of FSL with TFCE to compute regression analyses between patients' performance on a target task and GM density in regions of the brain showing GM atrophy relative to healthy seniors. Permutations were run exhaustively up to a maximum of 10,000 for each analysis. We reported clusters surviving a height threshold of  $p<0.05$  (uncorrected) and a minimum of 10 adjacent voxels.

**Region of Interest Analysis.** Thirty normal aging brains from the OASIS dataset (Marcus et al. 2007) underwent labeling using MindBoggle protocol (Arno Klein 2012). After applying ANTs joint label fusion, which is a weighted voting based label fusion technique (Wang et al. 2013), on the 30 labeled brains, an

anatomically defined template space label set containing 98 cortical and 15 subcortical GM regions of interest (ROIs) were generated. The label set was then warped from the template space to each individual's native space in our PCA cohort and masked by the individual's GM image to create the individual's native label set. GM volumes of each ROI in the individual's native label set were then calculated. Because we were interested in the involvement of precuneus and hippocampus in visual memory, bilateral precuneus and hippocampus (4 ROIs, Fig 2) were extracted from the label set. We then performed a regression analysis with PCA patients' behavioral scores of interest and GM volume in these ROI regions, while covarying for their intracranial volume. A significant positive regression would suggest that the involvement of the each ROI is predicted by the respective behavioral performance.

**T2 Medial Temporal Lobe Thickness Analysis.** We sought to determine whether PCA patients had differential MTL and hippocampal subfield atrophy that could have impacted their visual episodic memory. Therefore we examined MTL subfields using high-resolution T2-MRI images {TR/TE: 5310/68 ms, echo train length 15, 18.3 ms echo spacing, 15° flip angle, 0% phase oversampling, 0.4 x 0.4 mm<sup>2</sup> in plane resolution, 2 mm slice thickness, 30 interleaved slices with 0.6 mm gap, acquisition time 7:12 min} that were labeled using the Automatic Segmentation of Hippocampus Subfields (ASHS) software package (Yushkevich et al. 2014). We examined the subset of patients who had high-resolution

T2 MRI scans of the medial temporal lobe (7 PCA, 12 AD, and 16 healthy seniors who were demographically matched to the entire cohort and to each other) obtained in the same scan session. Briefly, this method utilizes a training pipeline and a segmentation pipeline that combines a multi-atlas label fusion (Wang et al. 2013) and a learning-based error correction module to produce a fully automated segmentation of Cornu Ammonis (CA), dentate gyrus (DG), and subiculum subfields along the entire length of the hippocampal formation, as well as segmentation of extrahippocampal structures, including entorhinal (ERC) and perirhinal (BA35 and BA36) and parahippocampal cortices (PHC). Candidate segmentations of a subject's T2-MRI were obtained using high-dimensional mapping to multiple manually labeled atlas images, and then fused into a consensus segmentation, taking into account the similarity between a subject's image and atlas images. Patterns of systematic segmentation errors are learned *a priori* using training data, and are corrected in a further post-processing step, to generate the final segmentation. Reliability of automated labeling for these subfields is high, as reported (Yushkevich et al. 2014). CA2/3 were not included in our analyses since their segmentation was not reliable. Thickness measures of subfields were extracted by establishing point-wise correspondence between automatic segmentation for quantitative comparisons across cohorts (FWE corrected). Thickness was used for extra-hippocampal subfields since these subfields were not segmented throughout the entire anterior-posterior axis of

MTL and we needed to normalize the volume by the number of slices contributing to the analysis. Pearson correlation analyses were performed to relate MTL subfield atrophy to Rey recall performance.

### **Section III.C. RESULTS**

**Behavioral Analysis.** Table 1 summarizes the behavior profile and results of participants in our study. Compared to controls, worse MMSE was observed in PCA [U=13.50, Z=-3.57,  $p<0.001$ ] and AD [U=0.00, Z=-4.55,  $p<0.001$ ] compared to controls. AD patients were more impaired on MMSE [U=60.00, Z=-2.12,  $p<0.05$ ] compared to PCA patients, although we found no correlation between MMSE and other cognitive measures. Consistent with their clinical phenotype, PCA patients were more impaired on modified Rey Copy [U=30.00, Z=-3.16,  $p=0.002$ ] and modified Rey Recall [U=2.00, Z=-4.19,  $p<0.001$ ] than controls. AD patients were also more impaired on modified Rey Copy [U=18.00, Z=-4.00,  $p<0.001$ ] and modified Rey Recall [U=4.50, Z=-4.40,  $p<0.001$ ] than controls. Between PCA and AD patients, there was no significant difference in modified Rey Copy [U=95.50, Z=-0.64,  $p>0.05$ ] or modified Rey Recall [U=101.50, Z=-0.40,  $p>0.05$ ] performance. To reduce the potential confound presented by the challenge of evaluating visual episodic memory performance in an individual who has difficulty perceiving the stimulus, we also examined visual recall as a percent of each participant's visual copy performance. Compared to controls, lower percentage of copied recall was observed in PCA [U=14.00, Z=-3.53,  $p<0.001$ ] and AD [U=4.50, Z=-4.41,  $p<0.001$ ]. There was no significant difference in percentage of copied recall [U=99.50, Z=-0.49,  $p>0.05$ ] between PCA and AD patients. AD patients may be

at a disadvantage for performing modified Rey Recall since they may not be able to use verbally-mediated recall strategy to recall the geometric shapes due to their verbal episodic memory difficulty.

**T1 Imaging Analysis.** Whole brain imaging showed that PCA, relative to healthy seniors, has significant atrophy in occipitotemporal and parietal cortices (OTPC), including bilateral precuneus and inferior parietal gyri (Fig. 1A); AD had a widespread atrophy relative to healthy seniors in OTPC, including bilateral precuneus, inferior parietal gyri, middle temporal gyri, as well as MTL regions including bilateral hippocampi (Fig. 1B).

Regression analyses in PCA showed that Rey recall in PCA is related to bilateral precuneus and angular gyrus (Fig 1C). In AD, Rey recall was related to bilateral hippocampus, right middle temporal gyrus, and right precuneus (Fig 1D). To account for patients' visuoperceptual difficulty in their performance on visual episodic memory, we also performed a regression analysis on copied recall (percent of Rey Recall) performance in PCA and AD. This regression analysis showed that Rey Recall performance, after taking account of visuoperceptual difficulty, in PCA was associated with areas in OTPC, including right precuneus (Fig 1E) while Rey Recall performance, after taking account of visuoperceptual difficulty, in AD was associated with hippocampus and right MTG (Fig 1F). This result showed that precuneus and other parietal areas significantly modulate visual episodic memory performance in PCA even after taking into account for

their visuo-perceptual difficulty.

**Region of Interest Analysis.** Since both hippocampus and precuneus have been implicated in memory retrieval, we used hippocampus and precuneus regions of interest (Fig 2) to further examine the plausible contributions of each of these regions in visual episodic memory performance, assessed by Rey Recall, in PCA. We then used general linear model (GLM) to demonstrate whether the involvement of precuneus and hippocampus was predicted by Rey Recall performance. Rey Recall predicted the right precuneus (Table 2), but not the left precuneus. Rey Recall was not associated with the hippocampus bilaterally (Table 2).

**Medial Temporal Lobe Subfield Imaging Analysis.** We examined whether hippocampal (CA1, DG, and subiculum) and extra-hippocampal subfields (ERC, BA35, and BA36) were differentially affected in PCA. MTL subfields were comparable between PCA and controls ( $p > 0.05$ ). However, AD patients, compared to the controls, had thinner left subiculum ( $p < 0.001$ ), left DG ( $p < 0.001$ ), left BA35 ( $p < 0.001$ ), left PHC ( $p < 0.01$ ), right DG ( $p < 0.001$ ), right ERC ( $p < 0.01$ ), right PHC ( $p < 0.001$ ). Compared to PCA, AD patients had thinner left PHC ( $p < 0.01$ ) and left BA35 ( $p < 0.01$ ). Regional thickness of significant MTL subfields across the cohorts is illustrated in Fig 3. We related thinning of MTL subfields in AD patients to their performance on Rey recall and found that left subiculum ( $r = 0.8$ ,  $p = 0.002$ ) and right DG ( $r = 0.7$ ,  $p = 0.009$ ) were associated with

visual episodic memory. There was no association between visual episodic memory and MTL subfields in PCA patients.



### **Section III.D. DISCUSSION**

The presence and anatomic basis for visual episodic memory difficulty in PCA is unclear. In this study, we aimed to elucidate whether the visuoperceptual deficit in PCA interferes with their visual episodic memory functioning and whether MTL and hippocampal disease also contributes to this appearance on visual episodic memory difficulty, given the statistical likelihood of underlying AD pathology (Ossenkoppele et al. 2015). We found a visuoperceptual deficit, evident by Rey Copy, as well as visual episodic memory difficulty, assessed by Rey Recall, in PCA.

According to the most recent 2017 international consensus criteria for PCA (Crutch et al. 2017), patients are diagnosed with PCA if they exhibit impaired visuoperceptual and visuospatial deficit as their primary deficit, with relatively preserved episodic memory. Given that PCA patients have impairment in the visuoperceptual domain, most studies have not evaluated visual memory performance, resulting in difficulties diagnosing PCA. This is because of the potential confound presented by the challenge of evaluating visual episodic memory performance in an individual who has difficulty perceiving the stimulus that must be recalled. PCA patients in fact performed poorly on the Rey Copy task compared to healthy seniors. In the present study, we addressed this challenge by examining visual recall as a percent of each patient's visual copy performance. Using this measure, we found poor visual memory recall

performance in PCA. These findings lead us to conclude that patients with PCA have visual episodic memory difficulty.

It is noteworthy that, consistent with other reports, we found that verbal recall was relatively spared in PCA patients ( $p > 0.05$ ). One way to circumvent the potential confounds associated with assessments of visual memory in PCA has been the assessment of verbal episodic memory. However, this does not address the issue of the basis for visual episodic memory difficulty found in PCA. We addressed this issue in the present study by relating memory performance to the anatomic distribution of atrophy in PCA. We found that performance on visual memory measures was related to brain regions in the parietal areas, including bilateral precuneus. Even after taking into account of their visuoperceptual difficulty, we still found that precuneus was associated with Rey Recall performance. The ROI analysis of precuneus also revealed converging findings, where Rey Recall performance predicted the involvement of right precuneus but not the hippocampus. Along with our study, several functional imaging studies have shown the activation of precuneus in episodic memory retrieval tasks (Rugg et al. 2002; Cabeza and Nyberg 2006). Earlier studies have demonstrated that precuneus is involved in retrieval that depends on mental imagery (Shallice et al. 1994; Fletcher et al. 1995) as well as retrieval independent of imagery (Krause et al. 1999; Schmidt 2002).

Importantly, neither visuoperceptual nor visual episodic memory performance appeared to be associated with MTL or hippocampus in PCA. Although CSF analyses indicated that likely AD pathology was present in a majority of PCA cases, detailed examination of MTL subfields failed to reveal any atrophy in PCA relative to controls. PCA findings thus are consistent with other reports of quantitative pathologic evidence of a hippocampal-sparing variant with AD pathology, which has disproportionate amount of NFT in occipitotemporal and parietal areas with relative sparing of the hippocampus (Janocko et al. 2012). As Murray and colleagues have reported, hippocampal-sparing variant of AD cases has been identified as one of the three AD subtypes [amnesic AD (75% out of 889 cases), hippocampal sparing (11%), and limbic predominant (14%)] in autopsy series of patients with AD pathology (Murray et al. 2011). The hippocampal-sparing variant of AD with visuoperceptual impairment due to prominent neocortical AD pathology accumulation is different from typical amnesic AD, where the NFT distribution follows the Braak staging pattern (Braak and Braak 1991), of significant NFT burden in MTL structures, including the hippocampus, relative to NFT distribution in the cortex. Our findings, together with these suggestive studies, raise the possibility of a variant of AD where pathology does not originate in the MTL, and suggest that the PCA phenotype may be a marker of this variant. Findings such as these warrant more detailed examination of hypotheses concerned with spreading pathology in

neurodegenerative diseases such as AD.

Some limitations must be considered when interpreting our data. First, atrophy in our PCA cohort using the whole brain T1 imaging analyses was defined using a conservative threshold (FWE corrected  $p < 0.005$ ) and hippocampus was not one of the areas that was affected at this threshold. When using a much more liberal threshold ( $p < 0.01$ , FWE corrected), we were able to observe some hippocampal atrophy. However, ROI analysis of the hippocampus as well as the fine-grained T2 imaging analysis of MTL subfields did not show evidence of hippocampal atrophy or evidence of hippocampal involvement in the visual episodic memory deficit observed in our PCA cohort. Second, while our cohorts were carefully matched demographically as well as the patient groups were matched for the disease duration, our sample size was relatively small. Larger cohorts of PCA patients are needed to assess these brain-behavior relationships more reliably. Although our patients had a typical phenotype of PCA that is statistically associated with AD pathology, four of our cases did not have CSF that was consistent with biomarker evidence of AD pathology, opening the possibility that another pathologic condition may be underlying the typical PCA syndrome we observed in our cohort. Additional longitudinal studies would be helpful in determining whether some of these PCA patients evolve over time to a clinical presentation that is more typical of amnesic AD. Lastly, although our PCA cohort was age-matched to our AD group, MMSE was worse in our AD

cohort than PCA. Caution thus must be exercised in generalizing our findings to late-onset patients with PCA and AD.

With these caveats in mind, we conclude that PCA patients appear to have visual episodic memory difficulty. Visual perceptual-spatial difficulty is a prominent clinical feature of PCA, and despite attempts to control for these perceptual-spatial deficits, the visual memory deficit in PCA remained statistically robust. Both visual perceptual-spatial and visual memory deficits were related to atrophy in occipitoparietal areas, including bilateral precuneus. However, no hippocampal atrophy was evident in PCA despite the presence of likely AD pathology. These findings suggest that PCA may be a marker for an atypical, hippocampal-sparing variant of AD, and implicate precuneus in visual episodic memory functioning. The clinical-anatomical profile of PCA is distinct from AD, where the visual memory deficit was related to MTL and hippocampal atrophy seen in these patients.

**Section III.E. Tables/Figures**

**Table 1. Mean (standard deviation) demographic & clinical features of the cohorts**

cohort	ELD (N=12, F=6)	PCA (N=13, F=8)	Clinical amnesic AD (N=17, F=12)
	Mean	Mean	Mean
Age at Test, yrs	60.9 (4.0)	57.7 (5.9)	56.8 (4.5)
Education, yrs	16.6 (2.6)	15.6 (2.9)	16.1 (2.5)
Disease Duration, yrs	N/A	3.0 (1.5)	3.1 (1.9)
CSF (ABeta42<192 pg/ml)	N/A	9 cases	All 17 cases
MMSE (max =30)	29.4 (0.7)	23.8 (2.3) ***	20.4 (3.9) *** #
JOLO (max=6)	5.8 (0.6)	2.8 (2.5) ***	2.9 (2.1) ***
Rey Copy (max=12)	12.0(0.0)	5.8 (5.6) ***	5.8 (4.0)***
Rey Recall (max =12)	10.8 (1.1)	2.8 (3.5) ***	2.2 (3.2) ***
Percent (%) of Recall (Recall/Copy)	90 (10)	30 (39.3) ***	22 (27.9)***
Verbal Recall (max=6)	4.0 (1.0)	2.6 (1.8)	1.2 (1.2) *

\*\*\*p<0.001 Compared to elderly controls (ELD)

# p < 0.05 Compared to PCA

**Figure 1. Whole Brain Atrophy and Regression in PCA.** Pattern of atrophy of gray matter (GM), shown in blue (coronal slice), in patients compared to controls, significant at  $p < 0.005$  (FWE corrected with threshold-free cluster enhancement). A) PCA<ELD, atrophy was found in occipitotemporal and parietal areas, including the precuneus, but there was no hippocampal atrophy. B) AD<ELD, atrophy was found in occipitotemporal and parietal areas, including the hippocampus and precuneus. Decreased performance on Rey Recall related to GM atrophy is shown in pink for PCA (C) and AD (D). Decreased performance on copied recall (percent of Rey Recall; recall corrected for copy performance) related to GM atrophy is shown in pink for PCA (E) and AD (F). uncorrected  $p < 0.05$ ,  $k \geq 10$

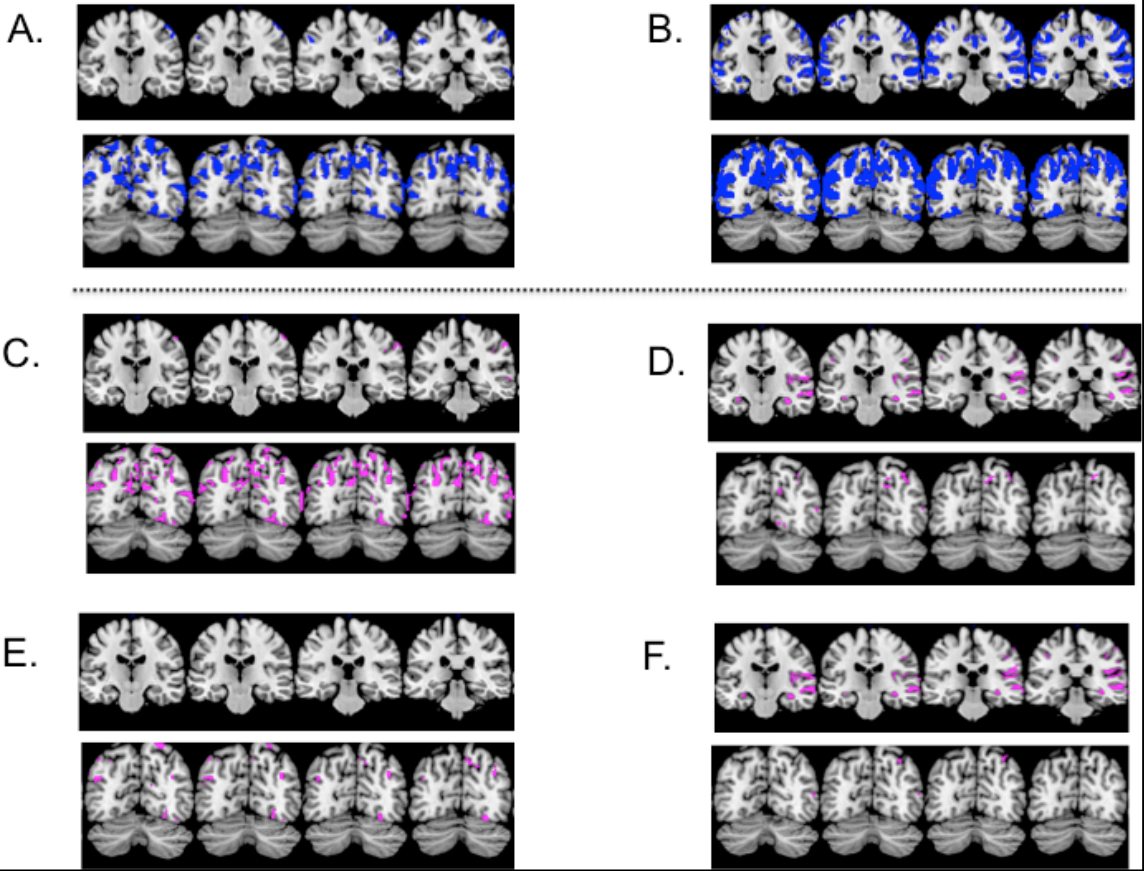




Figure 2. Mind-boogle label of precuneus and hippocampus

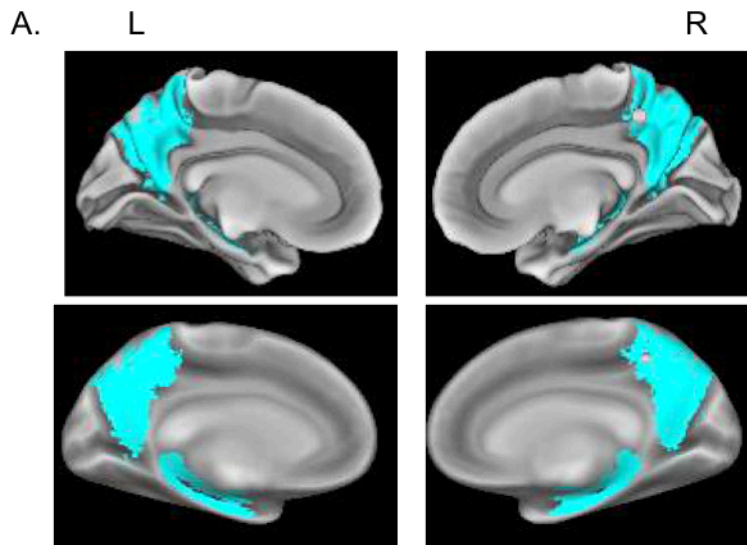
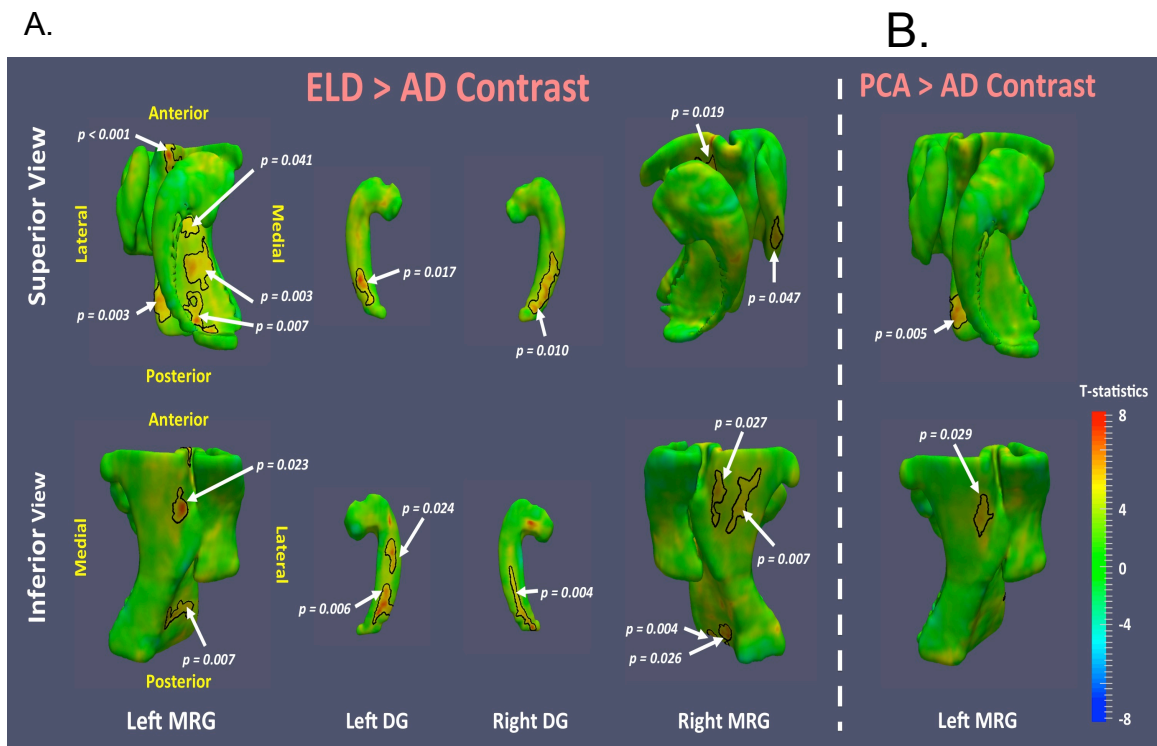


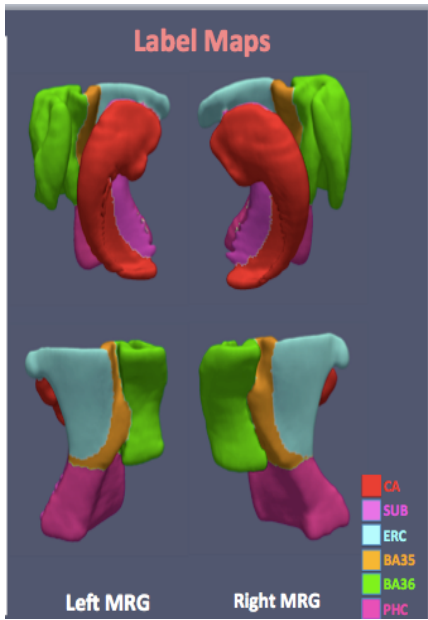
Table 2. General Linear Model predicting the involvement of precuneus and hippocampus. ICV: intracranial volume

Anatomic ROI	Hemisphere	Rey Recall + ICV	
		R <sup>2</sup>	p value
Precuneus	R	0.6342	0.0065
	L	-	-
Hippocampus	R	-	-
	L	-	-

Figure 3. Regional Thickness Analysis of MTL Subfields in patients.

MRG: merged surface rendering for all the MTL subfields except dentate gyrus (DG).





## CHAPTER IV. DISCUSSION/FUTURE DIRECTIONS

### Section IV.A. Summaries of my research and potential shortcomings

Episodic memory is the most prominent deficit in the early stage of clinical amnesic AD. This deficit is reflected by shrinkage of the MTL structures, including the hippocampus. According to Braak staging, tangles, a key pathological markers of AD, begin in the transentorhinal cortex of the MTL, which then spreads to hippocampal subfields, and later to neocortical areas (Braak and Braak 1991). Interestingly, many of the atypical variants of AD appear to share the same histopathological features with clinical amnesic AD, but clinical diagnostic criteria require episodic memory to be relatively preserved early in the disease course of these atypical cases. The two kinds of atypical variants of AD that I focused on here and included in my thesis projects are **logopenic variant of Primary Progressive Aphasia (lvPPA)**, also known as the language variant of AD and **posterior cortical atrophy (PCA)**, also known as the visual variant of AD. Despite AD pathology, the cognitive and anatomical profile of atypical variants of AD cases, particularly lvPPA and PCA, are distinct from the presentation of clinical amnesic AD. The reports on episodic memory performance and MTL involvement in lvPPA and PCA are inconsistent. My dissertation examined whether (1) the atypical cases of AD have episodic memory difficulty, and if so, 2) what brain areas are responsible for this difficulty. The central hypothesis is that impaired performance on measures of episodic

memory difficulty in atypical AD cases is due in part to non-memory components of the task, such as lexical retrieval and visual perception, and that this pattern of performance is associated in part with disease in other, non-MTL brain regions. This would be consistent with the hypothesis that not all AD histopathology begins in the MTL, and these hippocampal-sparing conditions suggest that additional mechanisms must be considered in the genesis of spreading pathology in AD.

The summary of my findings for each of these atypical syndromes, lvPPA and PCA, are as follows. LvPPA patients exhibited some degree of impairment of a measure of verbal episodic memory. I found this deficit observed in lvPPA was due in part to their limited lexical retrieval. This was associated with atrophy of left MTG, and not related to MTL/hippocampal atrophy, as in the typical AD cases (Win et al. 2017). Likewise, performance on a measure of visual episodic memory performance in PCA was impaired and this appeared to be due in part to difficulty perceiving in geometric design that had to be remembered. This deficit was not related to MTL/hippocampal atrophy, unlike the typical AD cases. Rather, their visual episodic memory difficulty appears to be mediated in part by disease in parietal regions including the precuneus. The effect of precuneus was significantly predicted by the visual episodic memory performance in PCA.

Braak staging (Braak and Braak 1991) suggests that AD pathology in typical AD cases begins in MTL/hippocampus. However, this does not appear to

be true for all forms of AD histopathology. AD pathology in atypical cases of AD, such as lvPPA and PCA, may not begin in the hippocampus/MTL. Other studies, along with my research, corroborated this theory. Here, I report that atypical cases with AD pathology have minimal MTL/hippocampal disease, and their difficulty on measures of episodic memory appears to be due in part to other, non-MTL brain regions. MTL/hippocampus consists of multiple subregions and a specific subregion may be differentially affected that can interfere with memory performance but cannot be detected with a regular T1 brain imaging. My research employed a fine-grained T2 imaging sequence, that maximizes the visualization of the hippocampal and extrahippocampal subregions to qualitatively and quantitatively examined the differential involvement of these subregions. Even with this high resolution imaging, there is no significant changes in subregions of the MTL/hippocampus in lvPPA or PCA. This result is consistent with the notion of hippocampal-sparing variant of AD (Murray et al. 2011). Clinical evaluations of the atypical variants of AD may show relative sparing of memory but the neuropsychological evaluation of verbal episodic memory in lvPPA and visual episodic memory in PCA exhibited some degree of impairment. This research may provide important clues about how AD spreads, and highlights the eligibility of atypical variants of AD for clinical trials despite the absence of significant episodic memory difficulty.

Poor performance on the delayed free recall task in lvPPA is a

confounding factor and can be confused with true verbal episodic memory difficulty mediated by MTL/hippocampal atrophy. As shown above, the inability to produce the words on the free recall task after a delayed period in lvPPA patients is due in part to their deficit in phonological retrieval of words. Some studies evaluating memory in lvPPA patients claimed that verbal memory was equally as impaired as patients with typical AD (Flanagan et al. 2014; Ramanan et al. 2016). In fact, these studies did not examine carefully the potential role of a lexical retrieval impairment that can influence on verbal episodic memory. My research demonstrated that there may be a common cognitive mechanism shared by lexical retrieval and verbal episodic memory, and suggested that the neural component underlying the common component is left MTG. My research also exposed the weakness of the delayed free recall task for lvPPA patients to assess memory. A better measure to show a relative sparing of memory, which is one of the criteria, is to use verbal recognition memory, which is less confounded by the lexical retrieval deficit. Future studies should carefully implement verbal memory measures that do not require lexical retrieval to better cater to a neurodegenerative population with impaired lexical retrieval when assessing verbal episodic memory.

Similarly, poor performance on a measure of visual episodic memory was observed in patients with PCA. Examination of visual episodic memory in PCA was challenging due to their visuo-perceptual and visuo-spatial problems. One

traditional way to assess visual episodic memory is using Rey Figure Recall test. Studies characterizing neuropsychological profile of PCA patients did not report the performance on measures of visual episodic memory recall. Here, we examined carefully the performance of Rey Recall in PCA patients and its neural correlate. By accounting for their visuoperceptual difficulty, my research demonstrated that precuneus, along with other parietal areas, mediates the visual episodic memory performance as well as visual perceptual difficulty.

There are some limitations of my research. Detailed limitations associated with each of my studies have been addressed in respective section. Here, I will briefly discuss additional limitations. One of the shortcomings of my research is the use of the retrospective data on neuropsychological measures. This limited the nature of the specific neuropsychological measures that were available and resulted in some potential confounds that clouded interpretation of the results. Not all the patients who are diagnosed as lvPPA or PCA patients have neuropsychological measures available, further contributing to the small sample size. Larger cohorts of lvPPA or PCA patients are needed to assess these brain-behavior relationships reported in my studies more reliably. CSF was available in many of the patients that were examined, and while the results were consistent with likely AD pathology, it might have been better to examine autopsy brains in these cases to determine more directly the locus of pathology. Moreover, there was no CSF available in a few cases of the patient cohort. So I cannot rule out



that another pathologic condition may be underlying the typical lvPPA or PCA cases observed in the cohort of my research.

Indeed, although lvPPA and PCA are atypical cases of AD, and majority of these cases are associated with AD pathology, the biology underlying the pathology of lvPPA and PCA patients may differ. Some cases of lvPPA patients have been reported to be associated with FTL-D-U pathology, which is negative for tau immunoreactivity but positive for ubiquitin immunoreactivity (Mesulam et al. 2008). Schott and colleagues (2016) reported that the genetic risk factors associated with PCA are in or near APOE, CR1 (chromosome 1), ABCA7 (ATP-binding cassette, sub-family A, member 7), BIN1 (bridging integrator 1). In addition, exploratory genome-wide association studies in these PCA patients (Schott et al. 2016) identified three novel loci: rs76854344 near *CNTNAP5* (*Contactin-associated protein-like 5*); rs72907046 near *FAM46A* (*Family with sequence similarity 46*); and rs2525776 near *SEMA3C* (*Class III Semaphorin 3C*). These studies suggest the different genetic profile between the atypical variant of AD cases; additional molecular factor may be driving the distribution of NFT in lvPPA and PCA.

It would have been valuable to have longitudinal data to observe whether pathology in these atypical cases spread to the MTL as the disease progresses. Because my findings on lvPPA and PCA patients were single cross-sectional snapshot, the pattern of atrophy captured in lvPPA and PCA patients were more

focal and could be anywhere in the disease spectrum of typical AD. As the disease progresses, it is plausible for lvPPA and PCA patients to convert to typical AD. In addition, there was no known functional imaging data to provide further converging evidence on the performance of verbal episodic memory in lvPPA and visual episodic memory in PCA. Lastly, our cohorts of lvPPA and PCA was relatively young, as was our matched AD group. Caution thus must be exercised in generalizing our findings to late-onset patients with these syndromes.

## **Section IV.B. Future Directions**

The diagnostic criteria for lvPPA (Gorno-Tempini et al. 2011) and PCA (Crutch et al. 2017) require relatively spared episodic memory. As shown here, lvPPA patients perform poorly on the verbal delayed free recall task while their recognition memory is comparable to healthy seniors (Win et al. 2017). Recognition memory appear to be a better assessment of memory for lvPPA patients and there may be some advantages to incorporating verbal recognition memory as part of the criteria when diagnosing lvPPA patients rather than broadly requiring the sparing of episodic memory. Their lexical retrieval deficit has a significant effect on performing the delayed free recall task. Future studies should develop episodic memory measure that does not rely heavily on lexical retrieval when assessing neurodegenerative population. Similarly, my research showed that PCA patients do perform poorly on the Rey Figure Recall test while they perform comparable to the healthy seniors on the verbal recall measure. Hence, current diagnostic criteria for PCA patients should further elaborate on which domain (verbal or visual) of episodic memory should be spared since visual episodic memory is indeed affected in PCA cases due in part to disease in parietal brain regions that also contribute to visual-perceptual functioning.

The longitudinal studies to track the disease progression in these atypical variant of AD are scarce. Rohrer and colleagues (2013) reported the longitudinal study of lvPPA patients revealed more involvement of posterior regions, including

atrophy in posterior cingulate/precuneus bilaterally, as well as involvement of anterior temporal and MTL regions. Moreover, lvPPA patients displayed a trend for a greater left/right hemisphere ratio over time compared to healthy controls; the rate of atrophy of the left hemisphere in lvPPA patients was greater than that of the right hemisphere. Consistent with the longitudinal anatomical changes in left temporo-parietal junction, lvPPA patients performed worse over time on sentence level processing associated with single word comprehension, repetition, and verbal recall (Rohrer et al. 2013). By criteria (Gorno-Tempini et al. 2011), lvPPA patients display relatively intact recognition memory. Longitudinally, the cognitive and neuroanatomical profile in lvPPA patients may not be confined to areas related to initial symptomatology. Future studies should investigate the performance of verbal recognition memory and visual episodic memory in lvPPA patients as the disease progresses and observe whether the involvement of MTL regions has an impact on verbal recognition memory and visual episodic memory.

One serial imaging study observed alteration in the pattern of atrophy in PCA and AD over time (Lehmann et al. 2012). This study showed that compared to healthy controls, both the PCA and typical AD patients had significant atrophy changes in temporal and parietal regions more globally as the disease progresses. Here, I reported that visual episodic memory in PCA patients was affected and it was a true memory difficulty contributed by precuneus. Even after

taking into an account of visuoperceptual difficulty, measured by copied recall (percent of recall based on the individual performance on copy), the precuneus effect still remained. On the other hand, the MTL regions and precuneus mediated visual episodic memory difficulty in typical AD patients. After taking into an account of visuoperceptual difficulty in typical AD patients, measured by copied recall (percent of recall based on the individual performance on copy), the MTL effect still remained. Future longitudinal studies should investigate whether PCA cases progress from an initially focal presentation to a more global pattern of atrophy, including MTL regions, and converge to the clinical presentations of AD over time. These studies also should examine whether MTL regions, if affected over time in PCA patients, contribute in part to visual episodic memory difficulty, in addition to the involvement of precuneus.

My research, along with previous reports (Murray et al. 2011; Janocko et al. 2012), hope to illuminate that AD is a very complex and heterogeneous disease. This concept of heterogeneity of AD has been increasingly recognized over the past decade but it was originally discussed in 1969 (McDONALD 1969). McDonald (1969) reported two distinct subgroups among dementia patients he was seeing in his clinic; the first group of patients had prominent memory disorder and the second group of patients exhibited prominent difficulties with praxis, visual construction, and cortical sensation, and he called these patients 'parietal group'. However, most people at the time believed that different stages

of the disease progression conferred clinical variation (Ritchie and Touchon 1992). Hence, McDonald's findings of AD heterogeneity as well as AD subtype variability were not recognized (Ritchie and Touchon 1992) until PET imaging. Early PET studies demonstrated the distinct patterns of brain hypometabolism among AD subjects (Foster et al. 1983; Haxby et al. 1985); although these patients had memory impairments, participants with left hemispheric hypometabolism had greater language deficit while participants with right parietal hypometabolism had visuospatial impairment (Chase et al. 1984; Duara et al. 1986). Fisher and colleagues (1997) also reported different subtypes of AD based on different neuropsychological profiles using the CERAD (Consortium to Establish a Registry for Alzheimer's Disease) database: individuals with anomia displayed prominent left hypometabolism while impairment of constructional praxis displayed prominent right hemispheric hypometabolism (Fisher et al. 1996; 1997a; 1997b). The participants in his study had the same age of onset, suggesting the different profile seen in these subtypes were the true variants and were not due to different stages in the disease progression. Longitudinal follow-up studies further supported the distinct subtypes of AD by showing how these subtypes remained different over time (Grady et al. 1986; Fisher et al. 1997b). In the recent report on AD subtypes (Murray et al. 2011), hippocampal sparing variant AD cases account for 11% of the cases that was studied in Murray's cohort.

Since Alois Alzheimer discovered AD in 1906, much progress in understanding the disease has been made in clinical, molecular, and neuroimaging fields (Hardy 2006). Despite these arduous efforts, clinical trials for AD patients have failed; the Food and Drug association (FDA) approved drugs for managing AD was based on research that were done three decades ago (Beach 2017). The most recent FDA approved therapeutic agent is directed at blocking glutamatergic excitotoxicity (Memantine / Namenda) in 2003, while agents targeting the cholinergic supplementation, which was suggested back in 1970s, is still at large for current therapy. Clinical trials using the agents to reduce the amyloid aggregation (i.e. Tramiprosate, Tarenflurbil) have been targeting at the stages of mild to moderate AD dementia; these trials failed to support efficacy in AD dementia patients.

Once the significant neuronal insult has occurred, anti-A $\beta$  intervention appears unlikely to succeed; which was the case in triple-transgenic mouse models of AD (Oddo et al. 2004). Hypothetical models examining the pathological marker of A $\beta$  show the neuronal insult has already taken place downstream of A $\beta$  aggregation, which occur even prior to this prodromal stage (Jack et al. 2010; Rowe et al. 2010). Using the longitudinal A $\beta$  information available in 89 healthy seniors with up to 10 years of follow-up, Insel and colleagues (2017) combined the level and rate of change of A $\beta$  to estimate the time to A $\beta$ -positivity for each participant and to significant A $\beta$  pathology for

associations with brain structure, metabolism, and cognition using mixed-effects models (Insel et al. 2017a). They reported that accelerated rates of FDG-PET were observed to occur 20 years or more before the conventional threshold for A $\beta$ -positivity while subtle signs of cognitive dysfunction were observed 10 years or more before A $\beta$ -positivity (Insel et al. 2017b). Hence, even intervention made at a prodromal stage of AD in MCI patients during Phase II testing of therapeutic agents may be too late.

According to the Alzheimer's Association (2017), it is estimated that 5.5 million Americans are living with AD in 2017. Of these, 5.3 million are over 65 years of age and ~ 200,000 individuals have younger-onset Alzheimer's (under the age of 65). It is reported that deaths from AD have increased by 89% while heart disease have decreased by 14% since 2000. Not only it is costly and burdensome on the AD patients themselves for atypical variants of AD, it is also stressful for the caregivers due to the care responsibilities since AD patients. As the disease progresses, patients cannot left alone due to worsening impairment in multiple cognitive domains. Without a doubt, the caregivers of AD patients are at greater risk of health problems, such as clinical depression, and cardiovascular disease (reviewed in Ross and Carroll 2017). These challenges are exacerbated in cases of atypical variants of AD cases with minimal memory difficulty due to the additional delay in making an accurate diagnosis. It is, therefore, paramount to develop approaches for managing care for AD patients.



To add to this unfortunate epidemic problem, with more than half of hippocampal sparing AD patients being misdiagnosed. Dr. Melissa Murray suggested that over 600,000 Americans make up the hippocampal sparing AD variant (AAN talk, 2016). While there are myriads of strides for therapy for typical AD patients, even for those at the prodromal stage, the clinical trial for therapy for these atypical variants of AD are scarce. Patients with atypical variants of AD are not eligible for the traditional AD clinical trials even though the underlying pathology for majority of these cases is AD. It is my hope that this research further adds value to demonstrate that these atypical variants of AD (at least in lvPPA and PCA) exhibit the appearance of memory difficulty. Due to the heterogeneity within the AD spectrum, lvPPA and PCA patients will benefit more from the precision medicine. Hopefully, there will be more focused and specialized trials for these atypical variants of AD cases in the near future for therapeutic treatment.

## **ABBREVIATION INDEX**

ABCA7 = ATP-binding cassette, sub-family A, member 7

AD = Alzheimer's disease

APOE4 = Apolipoprotein ε4

BIN1 = bridging integrator 1

BNT = Boston Naming Test

CA = cornu ammonis

CR1 = chromosome 1

DG = dentate gyrus

ERC = entorhinal cortex

FDG = fluorodeoxyglucose

GM = Gray matter

JOLO = Judgment of Line Orientation test

LvPPA = logopenic variant of primary progressive aphasia

MMSE = Mini-Mental State Examination

MTL = medial temporal lobe

PCA = posterior cortical atrophy

PET = Positron emission tomography

ROI = region of interest

TFCE = threshold-free cluster enhancement

## REFERENCES

- Acheson DJ, Hamidi M, Binder JR, Postle BR. A Common Neural Substrate for Language Production and Verbal Working Memory. <http://dxdoiorg/101162/jocn201021519>. MIT Press 238 Main St., Suite 500, Cambridge, MA 02142-1046 USA journals-info@mit.edu; 2011 Mar 31;23(6):1358–67.
- Adachi M, Kawakatsu S, Hosoya T, Otani K, Honma T, Shibata A, et al. Morphology of the Inner Structure of the Hippocampal Formation in Alzheimer Disease. *American Journal of Neuroradiology*. *American Journal of Neuroradiology*; 2003 Sep 1;24(8):1575–81.
- Addis DR, Wong AT, Schacter DL. Remembering the past and imagining the future: common and distinct neural substrates during event construction and elaboration. *Neuropsychologia*. 2007 Apr 8;45(7):1363–77.
- Albert MS, DeKosky ST, Dickson D, Dubois B, Feldman HH, Fox NC, et al. The diagnosis of mild cognitive impairment due to Alzheimer's disease: Recommendations from the National Institute on Aging-Alzheimer's Association workgroups on diagnostic guidelines for Alzheimer's disease. *Alzheimer's & Dementia*. 2011 May;7(3):270–9.
- Amici S, Ogar J, Brambati SM, Miller BL, Neuhaus J, Dronkers NL, et al. Performance in Specific Language Tasks Correlates With Regional Volume Changes in Progressive Aphasia. *Cognitive and Behavioral Neurology*. 2007 Dec 1;20(4):203–11.
- Andersen P. *The Hippocampus Book*. Andersen P, Morris R, Amaral D, Bliss T, O'Keefe J, editors. Oxford University Press; 2007.
- Apostolova LG, Lu P, Rogers S, Dutton RA, Hayashi KM, Toga AW, et al. 3D mapping of language networks in clinical and pre-clinical Alzheimer's disease. *BRAIN AND LANGUAGE*. 2008 Jan;104(1):33–41.
- Arno Klein JT. 101 Labeled Brain Images and a Consistent Human Cortical Labeling Protocol. *Front Neurosci*. *Frontiers Media SA*; 2012;6:171.
- Arshavsky YI. Why Alzheimer's Disease Starts with a Memory Impairment: Neurophysiological Insight. *Journal of Alzheimer's Disease*. 2010 Apr 6;20(1):5–16.
- Asllani I, Habeck C, Scarmeas N, Borogovac A, Brown TR, Stern Y. Multivariate and Univariate Analysis of Continuous Arterial Spin Labeling Perfusion

- MRI in Alzheimer's Disease. *Journal of Cerebral Blood Flow & Metabolism*. SAGE PublicationsSage UK: London, England; 2007 Oct 24.
- Baldo JV, Arévalo A, Patterson JP, Dronkers NF. Grey and white matter correlates of picture naming: evidence from a voxel-based lesion analysis of the Boston Naming Test. *Cortex*. 2013 Mar;49(3):658–67.
- Baldo JV, Katseff S, Dronkers NF. Brain regions underlying repetition and auditory-verbal short-term memory deficits in aphasia: Evidence from voxel-based lesion symptom mapping. *Aphasiology*. 2nd ed. Taylor & Francis; 2012 Feb 22;26(3-4):338–54.
- Barnes J, Godbolt AK, Frost C, Boyes RG, Jones BF, Scahill RI, et al. Atrophy rates of the cingulate gyrus and hippocampus in AD and FTLD. *Neurobiol Aging*. Elsevier; 2007 Jan 1;28(1):20–8.
- Baudic S, BARBA G, THIBAUDET M, SMAGGHE A, REMY P, TRAYKOV L. Executive function deficits in early Alzheimer's disease and their relations with episodic memory. *Archives of Clinical Neuropsychology*. 2006 Jan;21(1):15–21.
- Beach TG. A Review of Biomarkers for Neurodegenerative Disease: Will They Swing Us Across the Valley? *Springer Healthcare*; 2017 Jul 3;;s5–13.
- Benton AL. A VISUAL RETENTION TEST FOR CLINICAL USE. *Arch NeurPsych*. American Medical Association; 1945 Sep 1;54(3):212–6.
- Blennow K, de Leon MJ, Zetterberg H. Alzheimer's disease. *Lancet*. 2006 Jul 29;368(9533):387–403.
- Blennow K, Dubois B, Fagan AM, Lewczuk P, de Leon MJ, Hampel H. Clinical utility of cerebrospinal fluid biomarkers in the diagnosis of early Alzheimer's disease. *Alzheimer's & Dementia*. 2015;11(1):58–69.
- Bonner-Jackson A, Mahmoud S, Miller J, Banks SJ. Verbal and non-verbal memory and hippocampal volumes in a memory clinic population. *Alzheimers Res Ther*. BioMed Central; 2015 Oct 15;7(1):61.
- Borruat F-X. Posterior cortical atrophy: review of the recent literature. *Curr Neurol Neurosci Rep*. Springer US; 2013 Dec;13(12):406–8.
- Bourgeat P, Chételat G, Villemagne VL, Fripp J, Raniga P, Pike K, et al.  $\beta$ -Amyloid burden in the temporal neocortex is related to hippocampal atrophy in elderly subjects without dementia. *Neurology*. Lippincott Williams &

- Wilkins; 2010 Jan 12;74(2):121–7.
- Braak H, Braak E. Neuropathological staging of Alzheimer-related changes. *Acta Neuropathol.* Springer-Verlag; 1991;82(4):239–59.
- Burton EJ, Barber R, Mukaetova-Ladinska EB, Robson J, Perry RH, Jaros E, et al. Medial temporal lobe atrophy on MRI differentiates Alzheimer's disease from dementia with Lewy bodies and vascular cognitive impairment: a prospective study with pathological verification of diagnosis. *Brain.* 2008 Nov 11;132(1):195–203.
- Busatto GF, Garrido GEJ, Almeida OP, Castro CC, Camargo CHP, Cid CG, et al. A voxel-based morphometry study of temporal lobe gray matter reductions in Alzheimer's disease. *Neurobiol Aging.* 2003 Mar;24(2):221–31.
- Cabeza R, Nyberg L. *Imaging Cognition II: An Empirical Review of 275 PET and fMRI Studies.* <http://dxdoiorg/101162/08989290051137585>. MIT Press 238 Main St., Suite 500, Cambridge, MA 02142-1046 USA journals-info@mit.edu; 2006 Mar 13;12(1):1–47.
- Cavanna AE, Trimble MR. The precuneus: a review of its functional anatomy and behavioural correlates. *Brain.* Oxford University Press; 2006 Mar;129(Pt 3):564–83.
- Charles RF, Hillis AE. Posterior cortical atrophy: Clinical presentation and cognitive deficits compared to Alzheimer's disease. *Behavioural Neurology.* 2005 Jul 20;:15–23.
- Chase TN, Fedio P, Foster NL, Brooks R, Di Chiro G, Mansi L. Wechsler Adult Intelligence Scale Performance: Cortical Localization by Fluorodeoxyglucose F18-Positron Emission Tomography. *Arch Neurol.* American Medical Association; 1984 Dec 1;41(12):1244–7.
- Chen P, Ratcliff G, Belle SH, Cauley JA, DeKosky ST, Ganguli M. Patterns of Cognitive Decline in Presymptomatic Alzheimer Disease: A Prospective Community Study. *Arch Gen Psychiatry.* American Medical Association; 2001 Sep 1;58(9):853–8.
- Chételat G, Villemagne VL, Bourgeat P, Pike KE, Jones G, Ames D, et al. Relationship between atrophy and  $\beta$ -amyloid deposition in Alzheimer disease. *Ann Neurol.* Wiley Subscription Services, Inc., A Wiley Company; 2010 Mar 1;67(3):317–24.
- Clark RE, Squire LR. An animal model of recognition memory and medial

- temporal lobe amnesia: History and current issues. *Neuropsychologia*. 2010 Jul;48(8):2234–44.
- Cohen NJ, Eichenbaum H. *Memory, Amnesia, and the Hippocampal System*. MIT Press; 1995.
- Collie A, Maruff P. The neuropsychology of preclinical Alzheimer's disease and mild cognitive impairment. *Neuroscience and Biobehavioral Reviews*. 2000 May;24(3):365–74.
- Cronin-Golomb A, Hof PR. *Vision in Alzheimer's Disease*. Karger Medical and Scientific Publishers; 2004.
- Croot K, Hodges JR, Xuereb J, Patterson K. Phonological and Articulatory Impairment in Alzheimer's Disease: A Case Series. *BRAIN AND LANGUAGE*. 2000 Nov;75(2):277–309.
- Crutch SJ, Lehmann M, Schott JM, Rabinovici GD, Rossor MN, Fox NC. Posterior cortical atrophy. *The Lancet Neurology*. 2012 Feb;11(2):170–8.
- Crutch SJ, Lehmann M, Warren JD, Rohrer JD. The language profile of posterior cortical atrophy. *Journal of Neurology, Neurosurgery & Psychiatry*. BMJ Publishing Group Ltd; 2013a Apr;84(4):460–6.
- Crutch SJ, Schott JM, Rabinovici GD, Boeve BF, Cappa SF, Dickerson BC, et al. Shining a light on posterior cortical atrophy. *Alzheimers Dement*. 2013b. pp. 463–5.
- Crutch SJ, Schott JM, Rabinovici GD, Murray M, Snowden JS, van der Flier WM, et al. Consensus classification of posterior cortical atrophy. *Alzheimer's & Dementia*. 2017 Mar.
- DeLeon J, Gottesman RF, Kleinman JT, Newhart M, Davis C, Heidler-Gary J, et al. Neural regions essential for distinct cognitive processes underlying picture naming. *Brain*. Oxford University Press; 2007 May;130(Pt 5):1408–22.
- Di Paola M, Macaluso E, Carlesimo GA, Tomaiuolo F, Worsley KJ, Fadda L, et al. Episodic memory impairment in patients with Alzheimer's disease is correlated with entorhinal cortex atrophy. *Journal of Neurology*. Steinkopff-Verlag; 2007;254(6):774–81.
- Dickerson BC, Brickhouse M, McGinnis S, Wolk DA. Alzheimer's disease: The influence of age on clinical heterogeneity through the human brain connectome. *Alzheimer's & Dementia: Diagnosis, Assessment &*

- Disease Monitoring. Elsevier; 2017 Jan 1;6:122–35.
- Dörfel D, Werner A, Schaefer M, Kummer Von R, Karl A. Distinct brain networks in recognition memory share a defined region in the precuneus. *European Journal of Neuroscience*. 2009 Nov 6;30(10):1947–59.
- Duara R, Grady C, Haxby J, Sundaram M, Cutler NR, Heston L, et al. Positron emission tomography in Alzheimer's disease. *Neurology*. Lippincott Williams & Wilkins; 1986 Jul 1;36(7):879–9.
- Dubois B, Feldman HH, Jacova C, Cummings JL, DeKosky ST, Barberger-Gateau P, et al. Revising the definition of Alzheimer's disease: a new lexicon. *The Lancet Neurology*. 2010 Nov;9(11):1118–27.
- Dubois B, Feldman HH, Jacova C, DeKosky ST, Barberger-Gateau P, Cummings J, et al. Research criteria for the diagnosis of Alzheimer's disease: revising the NINCDS–ADRDA criteria. *The Lancet Neurology*. 2007 Aug;6(8):734–46.
- Duvernoy HM, Cattin F, Risold P-Y. *The Human Hippocampus*. Berlin, Heidelberg: Springer Science & Business Media; 2013.
- Eichenbaum H. What H.M. Taught Us. *Journal of Cognitive Neuroscience*. 2013 Jan;25(1):14–21.
- Fisher NJ, Rourke BP, Bieliauskas L, Giordani B, Berent S, Foster NL. Neuropsychological Subgroups of Patients with Alzheimer's Disease. *J Clin Exp Neuropsychol*. Taylor & Francis Group; 1996;18(3):349–70.
- Fisher NJ, Rourke BP, Bieliauskas LA. Neuropsychological Subgroups of Patients with Alzheimer's Disease: An Examination of the First 10 Years of CERAD Data. *J Clin Exp Neuropsychol*. Taylor & Francis Group; 1997a;21(4):488–518.
- Fisher NJ, Rourke BP, Bieliauskas LA, Giordani B, Berent S, Foster NL. Unmasking the heterogeneity of alzheimer's disease: Case studies of individuals from distinct neuropsychological subgroups. *J Clin Exp Neuropsychol*. 5 ed. Taylor & Francis Group; 1997b;19(5):713–54.
- Flanagan EC, Tu S, Ahmed S, Hodges JR, Hornberger M. Memory and orientation in the logopenic and nonfluent subtypes of primary progressive aphasia. *J Alzheimers Dis*. 2014;40(1):33–6.
- Fletcher PC, Frith CD, Baker SC, Shallice T, Frackowiak RS, Dolan RJ. The mind's eye--precuneus activation in memory-related imagery.

- NeuroImage. 1995 Sep;2(3):195–200.
- Folstein MF, Folstein SE, McHugh PR. “Mini-mental state.” A practical method for grading the cognitive state of patients for the clinician. *J Psychiatr Res.* 1975a Nov;12(3):189–98.
- Folstein MF, Folstein SE, McHugh PR. Folstein: “Mini-mental state”: a practical method... - Google Scholar. *Journal of psychiatric research*; 1975b.
- Foster NL, Chase TN, Fedio P, Patronas NJ, Brooks RA, Di Chiro G. Alzheimer's disease: focal cortical changes shown by positron emission tomography. *Neurology.* Lippincott Williams & Wilkins; 1983 Aug;33(8):961–5.
- Gefen T, Gasho K, Rademaker A, Lalehzari M, Weintraub S, Rogalski E, et al. Clinically concordant variations of Alzheimer pathology in aphasic versus amnesic dementia. *Brain.* Oxford University Press; 2012 May;135(Pt 5):1554–65.
- Gold CA, Budson AE. Memory loss in Alzheimer's disease: implications for development of therapeutics. *Expert Reviews.* 2008 Dec 12;8(12):1879–91.
- Gorno-Tempini ML, Dronkers NF, Rankin KP, Ogar JM, Phengrasamy L, Rosen HJ, et al. Cognition and anatomy in three variants of primary progressive aphasia. *Ann Neurol.* Wiley Subscription Services, Inc., A Wiley Company; 2004 Mar;55(3):335–46.
- Gorno-Tempini ML, Hillis AE, Weintraub S, Kertesz A, Mendez M, Ogar JM, et al. Classification of primary progressive aphasia and its variants. *Neurology.* 2011 Mar 15;76(11):1006–14.
- Grady CL, Haxby JV, Schlageter NL, Berg G, Rapoport SI. Stability of metabolic and neuropsychological asymmetries in dementia of the Alzheimer type. *Neurology.* Lippincott Williams & Wilkins; 1986 Oct 1;36(10):1390–0.
- Graves WW, Grabowski TJ, Mehta S, Gordon JK. A Neural Signature of Phonological Access: Distinguishing the Effects of Word Frequency from Familiarity and Length in Overt Picture Naming. <http://dxdoiorg/101162/jocn2007194617>. MIT Press 238 Main St., Suite 500, Cambridge, MA 02142-1046USA journals-info@mit.edu; 2007 Mar 23;19(4):617–31.
- Grossman M. Primary progressive aphasia: clinicopathological correlations. *Nat Rev Neurol.* 2010 Feb;6(2):88–97.
- Grossman M, McMillan C, Moore P, Ding L, Glosser G, Work M, et al.



- What's in a name: voxel-based morphometric analyses of MRI and naming difficulty in Alzheimer's disease, frontotemporal dementia and corticobasal degeneration. *Brain*. Oxford University Press; 2004 Mar;127(Pt 3):628–49.
- Harasty JA, Halliday GM, Kril JJ, Code C. Specific temporoparietal gyral atrophy reflects the pattern of language dissolution in Alzheimer's disease. *Brain*. 1999 Apr;122 ( Pt 4):675–86.
- Hardy J. A Hundred Years of Alzheimer's Disease Research. *Neuron*. 2006 Oct;52(1):3–13.
- Haxby JV, Duara R, Grady CL, Cutler NR, Rapoport SI. Relations between Neuropsychological and Cerebral Metabolic Asymmetries in Early Alzheimer's Disease. *Journal of Cerebral Blood Flow & Metabolism*. 3rd ed. SAGE Publications Sage UK: London, England; 1985;5(2):193–200.
- Helkala EL, Laulumaa V, Soininen H, Riekkinen PJ. Recall and recognition memory in patients with Alzheimer's and Parkinson's diseases. *Ann Neurol*. Wiley Subscription Services, Inc., A Wiley Company; 1988 Aug;24(2):214–7.
- Henry ML, Gorno-Tempini ML. The logopenic variant of primary progressive aphasia. *Current Opinion in Neurology*. 2010 Dec;23(6):633–7.
- Hodges J. Is semantic memory consistently impaired early in the course of Alzheimer's disease? Neuroanatomical and diagnostic implications. *Neuropsychologia*. 1995 Apr;33(4):441–59.
- Hodges JR, Salmon DP, Butters N. Semantic memory impairment in Alzheimer's disease: Failure of access or degraded knowledge? *Neuropsychologia*. 1992 Apr;30(4):301–14.
- Hof PR, Bouras C, Constandinidis J, Morrison JH. Balit's syndrome in Alzheimer's disease: specific disruption of the occipito-parietal visual pathway. *Brain Research*. 1989 Jul;493(2):368–75.
- Hu WT, McMillan C, Libon D, Leight S, Forman M, Lee VMY, et al. Multimodal predictors for Alzheimer disease in nonfluent primary progressive aphasia. *Neurology*. Lippincott Williams & Wilkins; 2010 Aug 17;75(7):595–602.
- Huntley JD, Howard RJ. Working memory in early Alzheimer's disease: a neuropsychological review. *International Journal of Geriatric Psychiatry*. John Wiley & Sons, Ltd; 2010 Feb 1;25(2):121–32.
- Indefrey P. The spatial and temporal signatures of word production

- components: a critical update. *Front Psychol*. 2011;2:255.
- Insel PS, Mattsson N, Mackin RS, Schöll M, Nosheny RL, Tosun D, et al. Accelerating rates of cognitive decline and imaging markers associated with  $\beta$ -amyloid pathology. *Neurology*. 2016 May 16;86(20):1887–96.
- Insel PS, Ossenkoppele R, Gessert D, Jagust W, Landau S, Hansson O, et al. Time to Amyloid Positivity and Preclinical Changes in Brain Metabolism, Atrophy, and Cognition: Evidence for Emerging Amyloid Pathology in Alzheimer's Disease. *Front Neurosci*. 2017a May 17;11:121–9.
- Insel PS, Ossenkoppele R, Gessert D, Jagust W, Landau S, Hansson O, et al. Time to Amyloid Positivity and Preclinical Changes in Brain Metabolism, Atrophy, and Cognition: Evidence for Emerging Amyloid Pathology in Alzheimer's Disease. *Front Neurosci*. 2017b May 17;11:121–9.
- Jack CR Jr, Barkhof F, Bernstein MA, Cantillon M, Cole PE, DeCarli C, et al. Steps to standardization and validation of hippocampal volumetry as a biomarker in clinical trials and diagnostic criterion for Alzheimer's disease. *Alzheimer's & Dementia*. 2011 Jul;7(4):474–4.
- Jack CR Jr, Knopman DS, Jagust WJ, Shaw LM, Aisen PS, Weiner MW, et al. Hypothetical model of dynamic biomarkers of the Alzheimer's pathological cascade. *The Lancet Neurology*. 2010 Jan;9(1):119–28.
- Janocko NJ, Brodersen KA, Soto-Ortolaza AI, Ross OA, Liesinger AM, Duara R, et al. Neuropathologically defined subtypes of Alzheimer's disease differ significantly from neurofibrillary tangle-predominant dementia. *Acta Neuropathol*. 2012 Sep 12;124(5):681–92.
- Josephs KA, Dickson DW, Murray ME, Senjem ML, Parisi JE, Petersen RC, et al. Quantitative neurofibrillary tangle density and brain volumetric MRI analyses in Alzheimer's disease presenting as logopenic progressive aphasia. *BRAIN AND LANGUAGE*. 2013 Nov;127(2):127–34.
- Josephs KA, Whitwell JL, Duffy JR, Vanvoorst WA, Strand EA, Hu WT, et al. Progressive aphasia secondary to Alzheimer disease vs FTLD pathology. *Neurology*. 2008 Jan 1;70(1):25–34.
- Kas A, de Souza LC, Samri D, Bartolomeo P, Lacomblez L, Kalafat M, et al. Neural correlates of cognitive impairment in posterior cortical atrophy. *Brain*. Oxford University Press; 2011 May;134(Pt 5):1464–78.
- Kasai M, Meguro K, Hashimoto R, Ishizaki J, Yamadori A, Mori E. Non-

- verbal learning is impaired in very mild Alzheimer's disease (CDR 0.5): Normative data from the learning version of the Rey–Osterrieth Complex Figure Test. 2006 Mar 7;:139–46.
- Katz B, Rimmer S. Ophthalmologic manifestations of Alzheimer's disease. *Survey of Ophthalmology*. 1989 Jul;34(1):31–43.
- Kennedy J, Lehmann M, Sokolska MJ, Archer H, Warrington EK, Fox NC, et al. Visualizing the emergence of posterior cortical atrophy. *Neurocase*. 2012 Jun;18(3):248–57.
- Krause BJ, Schmidt D, Mottaghy FM, Taylor J, Halsband U, Herzog H, et al. Episodic retrieval activates the precuneus irrespective of the imagery content of word pair associates A PET study. *Brain*. Oxford University Press; 1999 Feb 1;122(2):255–63.
- Lam B, Masellis M, Freedman M, Stuss DT, Black SE. Clinical, imaging, and pathological heterogeneity of the Alzheimer's disease syndrome. *Alzheimers Res Ther*. BioMed Central; 2013;5(1):1.
- Landau SM, Mintun MA, Joshi AD, Koeppe RA, Petersen RC, Aisen PS, et al. Amyloid deposition, hypometabolism, and longitudinal cognitive decline. *Ann Neurol*. Wiley Subscription Services, Inc., A Wiley Company; 2012 Oct 1;72(4):578–86.
- Langbaum JBS, Chen K, Caselli RJ, Lee W, Reschke C, Bandy D, et al. Hypometabolism in Alzheimer-Affected Brain Regions in Cognitively Healthy Latino Individuals Carrying the Apolipoprotein E  $\epsilon$ 4 Allele. *Arch Neurol*. American Medical Association; 2010 Apr 12;67(4):462–8.
- Lawrence E, Vegvari C, Ower A, Hadjichrysanthou C, De Wolf F, Anderson RM. A Systematic Review of Longitudinal Studies Which Measure Alzheimer's Disease Biomarkers. Ikram MA, editor. *Journal of Alzheimer's Disease*. 2017 Jul 19;59(4):1359–79.
- Leff AP, Schofield TM, Crinion JT, Seghier ML, Grogan A, Green DW, et al. The left superior temporal gyrus is a shared substrate for auditory short-term memory and speech comprehension: evidence from 210 patients with stroke. *Brain*. Oxford University Press; 2009 Dec 1;132(12):3401–10.
- Lehmann M, Barnes J, Ridgway GR, Ryan NS, Warrington EK, Crutch SJ, et al. Global gray matter changes in posterior cortical atrophy: a serial imaging study. *Alzheimers Dement*. 2012 Nov;8(6):502–12.

- Lehmann M, Crutch SJ, Ridgway GR, Ridha BH, Barnes J, Warrington EK, et al. Cortical thickness and voxel-based morphometry in posterior cortical atrophy and typical Alzheimer's disease. *Neurobiol Aging*. 2011 Aug;32(8):1466–76.
- Leyton CE, Hodges JR. Towards a Clearer Definition of Logopenic Progressive Aphasia. *Curr Neurol Neurosci Rep*. 2013 Sep 13;13(11):396.
- Leyton CE, Hodges JR, McLean CA, Kril JJ, Piguet O, Ballard KJ. Is the logopenic-variant of primary progressive aphasia a unitary disorder? *Cortex*. Elsevier Ltd; 2015 Jun 1;67(C):122–33.
- Leyton CE, Villemagne VL, Savage S, Pike KE, Ballard KJ, Piguet O, et al. Subtypes of progressive aphasia: application of the International Consensus Criteria and validation using  $\beta$ -amyloid imaging. *Brain*. Oxford University Press; 2011 Oct;134(Pt 10):3030–43.
- Lezak MD, Howieson DB, Bigler ED, Tranel D. *Neuropsychological Assessment*. Oxford University Press; 2012.
- Libon DJ, Bondi MW, Price CC, Lamar M, Eppig J, Wambach DM, et al. Verbal serial list learning in mild cognitive impairment: a profile analysis of interference, forgetting, and errors. *J Int Neuropsychol Soc*. Cambridge University Press; 2011a Sep;17(5):905–14.
- Libon DJ, Rascovsky K, Gross RG, White MT, Xie SX, Dreyfuss M, et al. The Philadelphia Brief Assessment of Cognition (PBAC): A Validated Screening Measure for Dementia. *The Clinical Neuropsychologist*. 3rd ed. Psychology Press; 2011b Dec 16;25(8):1314–30.
- Locascio JJ, Growdon JH, Corkin S. Cognitive Test Performance in Detecting, Staging, and Tracking Alzheimer's Disease. *Arch Neurol*. American Medical Association; 1995 Nov 1;52(11):1087–99.
- Manning EN, Macdonald KE, Leung KK, Young J, Pepple T, Lehmann M, et al. Differential hippocampal shapes in posterior cortical atrophy patients: A comparison with control and typical AD subjects. *Hum Brain Mapp*. 2015 Dec;36(12):5123–36.
- Marcus DS, Wang TH, Parker J, Csernansky JG, Morris JC, Buckner RL. Open Access Series of Imaging Studies (OASIS): Cross-sectional MRI Data in Young, Middle Aged, Nondemented, and Demented Older Adults. <http://dxdoi.org/10.1162/jocn.2007.19914.98>. MIT Press 238 Main St., Suite 500, Cambridge, MA 02142-1046USA journals-info@mit.edu; 2007 Aug

22;19(9):1498–507.

McDONALD C. Clinical Heterogeneity in Senile Dementia. *The British Journal of Psychiatry*. The Royal College of Psychiatrists; 1969 Mar 1;115(520):267–71.

McKhann GM, Knopman DS, Chertkow H, Hyman BT, Jack CR, Kawas CH, et al. The diagnosis of dementia due to Alzheimer's disease: recommendations from the National Institute on Aging-Alzheimer's Association workgroups on diagnostic guidelines for Alzheimer's disease. *Alzheimers Dement*. 2011. pp. 263–9.

McMillan CT, Wolk DA. Presence of cerebral amyloid modulates phenotype and pattern of neurodegeneration in early Parkinson's disease. *Journal of Neurology, Neurosurgery & Psychiatry*. 2016 Jun 9;;jnnp–2015–312690–12.

Mendez MF, Ghajarian M, Perryman KM. Posterior Cortical Atrophy: Clinical Characteristics and Differences Compared to Alzheimer's Disease. *Dement Geriatr Cogn Disord*. Karger Publishers; 2002;14(1):33–40.

Mendez MF, Mendez MA, Martin R, Smyth KA, Whitehouse PJ. Complex visual disturbances in Alzheimer's disease. *Neurology*. Lippincott Williams & Wilkins; 1990 Mar 1;40(3 Part 1):439–9.

Mesulam M, Wicklund A, Johnson N, Rogalski E, Léger GC, Rademaker A, et al. Alzheimer and frontotemporal pathology in subsets of primary progressive aphasia. *Ann Neurol*. Wiley Subscription Services, Inc., A Wiley Company; 2008 Jun;63(6):709–19.

Mesulam M-M. Primary progressive aphasia and the language network. *Neurology*. 2013 Jul 30;81:456–62.

Mesulam M-M, Rogalski EJ, Wieneke C, Hurley RS, Geula C, Bigio EH, et al. Primary progressive aphasia and the evolving neurology of the language network. *Nat Rev Neurol*. 2014a Oct;10(10):554–69.

Mesulam M-M, Weintraub S. Is it time to revisit the classification guidelines for primary progressive aphasia? *Neurology*. Lippincott Williams & Wilkins; 2014 Apr 1;82(13):1108–9.

Mesulam M-M, Weintraub S, Rogalski EJ, Wieneke C, Geula C, Bigio EH. Asymmetry and heterogeneity of Alzheimer's and frontotemporal pathology in primary progressive aphasia. *Brain*. Oxford University Press; 2014b Apr;137(Pt 4):1176–92.

Mesulam M-M, Wieneke C, Hurley R, Rademaker A, Thompson CK,

- Weintraub S, et al. Words and objects at the tip of the left temporal lobe in primary progressive aphasia. *Brain*. Oxford University Press; 2013 Feb;136(Pt 2):601–18.
- Mesulam M-M, Wieneke C, Thompson C, Rogalski E, Weintraub S. Quantitative classification of primary progressive aphasia at early and mild impairment stages. *Brain*. Oxford University Press; 2012 May;135(Pt 5):1537–53.
- Mickes L, Wixted JT, Fennema-Notestine C, Galasko D, Bondi MW, Thal LJ, et al. Progressive impairment on neuropsychological tasks in a longitudinal study of preclinical Alzheimer's disease. *Neuropsychology*. 2007;21(6):696–705.
- Migliaccio R, Agosta F, Rascovsky K, Karydas A, Bonasera S, Rabinovici GD, et al. Clinical syndromes associated with posterior atrophy: early age at onset AD spectrum. *Neurology*. Lippincott Williams & Wilkins; 2009a Nov 10;73(19):1571–8.
- Migliaccio R, Agosta F, Rascovsky K, Karydas A, Bonasera S, Rabinovici GD, et al. Clinical syndromes associated with posterior atrophy. *Journal of Neurology*. 2009b Nov 2;73:1571–8.
- Miners JS, Palmer JC, Love S. Pathophysiology of Hypoperfusion of the Precuneus in Early Alzheimer's Disease. *Brain Pathology*. 2016 Jul 1;26(4):533–41.
- Murray ME, Graff-Radford NR, Ross OA, Petersen RC, Duara R, Dickson DW. Neuropathologically defined subtypes of Alzheimer's disease with distinct clinical characteristics: a retrospective study. *The Lancet Neurology*. 2011 Sep;10(9):785–96.
- Nakazawa K, Quirk MC, Chitwood RA, Watanabe M, Yeckel MF, Sun LD, et al. Requirement for Hippocampal CA3 NMDA Receptors in Associative Memory Recall. *Science*. American Association for the Advancement of Science; 2002 Jul 12;297(5579):211–8.
- Oddo S, Billings L, Kesslak JP, Cribbs DH, LaFerla FM. A $\beta$  Immunotherapy Leads to Clearance of Early, but Not Late, Hyperphosphorylated Tau Aggregates via the Proteasome. *Neuron*. Elsevier; 2004 Aug 5;43(3):321–32.
- Ohm TG. The dentate gyrus in Alzheimer's disease. *The Dentate Gyrus: A Comprehensive Guide to Structure, Function, and Clinical Implications*. Elsevier; 2007. pp. 723–40. (Progress in Brain Research; vol. 163).

- Ossenkoppele R, Cohn-Sheehy BI, La Joie R, Vogel JW, Möller C, Lehmann M, et al. Atrophy patterns in early clinical stages across distinct phenotypes of Alzheimer's disease. *Hum Brain Mapp*. 2015 Aug 11;:n/a–n/a.
- Osterrieth PA. APA PsycNET Login. *Archives de psychologie*. 1944.
- Pekkala S, Wiener D, Himali JJ, Beiser AS, Obler LK, Liu Y, et al. Lexical retrieval in discourse: An early indicator of Alzheimer's dementia. *Clinical Linguistics & Phonetics*. 2013 Jul 12;27(12):905–21.
- Peters F, Collette F, Degueldre C, Sterpenich V, Majerus S, Salmon E. The neural correlates of verbal short-term memory in Alzheimer's disease: an fMRI study. *Brain*. Oxford University Press; 2009a Jul 1;132(7):1833–46.
- Peters F, Majerus S, Collette F, Degueldre C, Fiore GD, Laureys S, et al. Neural substrates of phonological and lexicosemantic representations in Alzheimer's disease. *Hum Brain Mapp*. Wiley Subscription Services, Inc., A Wiley Company; 2009b Jan 1;30(1):185–99.
- Pievani M, de Haan W, Wu T, Seeley WW, Frisoni GB. Functional network disruption in the degenerative dementias. *The Lancet Neurology*. 2011 Sep;10(9):829–43.
- Piguet O, Leyton CE, Gleeson LD, Hoon C, Hodges JR. Memory and emotion processing performance contributes to the diagnosis of non-semantic primary progressive aphasia syndromes. *J Alzheimers Dis*. IOS Press; 2015;44(2):541–7.
- Ramanan S, Flanagan E, Leyton CE, Villemagne VL, Rowe CC, Hodges JR, et al. Non-Verbal Episodic Memory Deficits in Primary Progressive Aphasias are Highly Predictive of Underlying Amyloid Pathology. Naismith S, editor. *J Alzheimers Dis*. IOS Press; 2016 Feb 5;51(2):367–76.
- Renner JA, Burns JM, Hou CE, McKeel DW, Storandt M, Morris JC. Progressive posterior cortical dysfunction. *Journal of Neurology*. 2004 Sep 17;:1175–80.
- Richardson FM, Ramsden S, Ellis C, Burnett S, Megnin O, Catmur C, et al. Auditory Short-term Memory Capacity Correlates with Gray Matter Density in the Left Posterior STS in Cognitively Normal and Dyslexic Adults. [http://dxdoi.org/10.1162/jocn\\_a\\_00060](http://dxdoi.org/10.1162/jocn_a_00060). MIT Press 55 Hayward Street, Cambridge, MA 02142-1315 USA journals-info@mit.edu; 2011 Nov 2;23(12):3746–56.
- Ritchie K, Touchon J. Heterogeneity in senile dementia of the Alzheimer

- type: Individual differences, progressive deterioration or clinical sub-types?  
Journal of Clinical Epidemiology. Elsevier; 1992 Dec 1;45(12):1391–8.
- Rogalski E, Cobia D, Harrison TM, Wieneke C, Thompson CK, Weintraub S, et al. Anatomy of language impairments in primary progressive aphasia. J Neurosci. Society for Neuroscience; 2011a Mar 2;31(9):3344–50.
- Rogalski EJ, Rademaker A, Harrison TM, Helenowski I, Johnson N, Bigio E, et al. ApoE E4 is a susceptibility factor in amnesic but not aphasic dementias. Alzheimer disease and associated disorders. NIH Public Access; 2011b Apr;25(2):159–63.
- Rohrer JD, Caso F, Mahoney C, Henry M, Rosen HJ, Rabinovici G, et al. Patterns of longitudinal brain atrophy in the logopenic variant of primary progressive aphasia. BRAIN AND LANGUAGE. 2013 Feb 5;127(2):121–6.
- Rohrer JD, Ridgway GR, Crutch SJ, Hailstone J, Goll JC, Clarkson MJ, et al. Progressive logopenic/phonological aphasia: erosion of the language network. NeuroImage. 2010 Jan 1;49(1):984–93.
- Rowe CC, Ellis KA, Rimajova M, Bourgeat P, Pike KE, Jones G, et al. Amyloid imaging results from the Australian Imaging, Biomarkers and Lifestyle (AIBL) study of aging. Neurobiol Aging. 2010 Aug;31(8):1275–83.
- Rugg MD, Otten LJ, Henson RNA. The neural basis of episodic memory: evidence from functional neuroimaging. Philosophical Transactions of the Royal Society B: Biological Sciences. The Royal Society; 2002 Aug 29;357(1424):1097–110.
- Sajjadi SA, Patterson K, Nestor PJ. Logopenic, mixed, or Alzheimer-related aphasia? Journal of Neurology. 2014;82:1127–31.
- Salmon DP, Heindel WC, Lange KL. Differential decline in word generation from phonemic and semantic categories during the course of Alzheimer's disease: Implications for the integrity of semantic memory. J Int Neuropsychol Soc. Cambridge University Press; 1999 Nov 1;5(7):692–703.
- Savage S, Hsieh S, Leslie F, Foxe D, Piguet O, Hodges JR. Distinguishing Subtypes in Primary Progressive Aphasia: Application of the Sydney Language Battery. Dement Geriatr Cogn Disord. Karger Publishers; 2013;35(3-4):208–18.
- Schacter DL, Addis DR. The cognitive neuroscience of constructive memory: remembering the past and imagining the future. Philosophical



- Transactions of the Royal Society B: Biological Sciences. The Royal Society; 2007 May 29;362(1481):773–86.
- Scher AI, Xu Y, Korf ESC, White LR, Scheltens P, Toga AW, et al. Hippocampal shape analysis in Alzheimer's disease: A population-based study. *NeuroImage*. 2007 May;36(1):8–18.
- Schmidt D. Brain systems engaged in encoding and retrieval of word-pair associates independent of their imagery content or presentation modalities. *Neuropsychologia*. 2002;40(4):457–70.
- Schott JM, Crutch SJ, Carrasquillo MM, Uphill J, Shakespeare TJ, Ryan NS, et al. Genetic risk factors for the posterior cortical atrophy variant of Alzheimer's disease. *Alzheimers Dement*. Elsevier; 2016 Aug;12(8):862–71.
- Schöll M, Lockhart SN, Schonhaut DR, O'Neil JP, Janabi M, Ossenkoppele R, et al. PET Imaging of Tau Deposition in the Aging Human Brain. *Neuron*. 2016 Mar;89(5):971–82.
- Shallice T, Fletcher P, Frith CD, Grasby P, Frackowiak RSJ, Dolan RJ. Brain regions associated with acquisition and retrieval of verbal episodic memory. *Nature*. 1994 Apr 14;368(6472):633–5.
- Shastri L. Episodic memory and cortico–hippocampal interactions. *Trends in Cognitive Sciences*. 2002 Apr;6(4):162–8.
- Shaw LM, Vanderstichele H, Knapik Czajka M, Clark CM, Aisen PS, Petersen RC, et al. Cerebrospinal fluid biomarker signature in Alzheimer's disease neuroimaging initiative subjects. *Ann Neurol*. Wiley Subscription Services, Inc., A Wiley Company; 2009 Apr 1;65(4):403–13.
- Smith SM, Nichols TE. Threshold-free cluster enhancement: Addressing problems of smoothing, threshold dependence and localisation in cluster inference. *NeuroImage*. Elsevier Inc; 2009 Jan 1;44(1):83–98.
- Sperling RA, Aisen PS, Beckett LA, Bennett DA, Craft S, Fagan AM, et al. Toward defining the preclinical stages of Alzheimer's disease: Recommendations from the National Institute on Aging–Alzheimer's Association workgroups on diagnostic guidelines for Alzheimer's disease. *Alzheimer's & Dementia*. 2011 May;7(3):280–92.
- Takahashi E, Ohki K, Kim D-S. Dissociated pathways for successful memory retrieval from the human parietal cortex: anatomical and functional connectivity analyses. *Cereb Cortex*. Oxford University Press; 2008

Aug;18(8):1771–8.

Tang-Wai DF. Clinical, genetic, and neuropathologic characteristics of posterior cortical atrophy. 2004 Sep 17;:1–7.

Teyler TJ, Rudy JW. The hippocampal indexing theory and episodic memory: Updating the index. *Hippocampus*. Wiley Subscription Services, Inc., A Wiley Company; 2007 Dec 1;17(12):1158–69.

Thiyagesh SN, Farrow TFD, Parks RW, Accosta-Mesa H, Young C, Wilkinson ID, et al. The neural basis of visuospatial perception in Alzheimer's disease and healthy elderly comparison subjects: An fMRI study. *Psychiatry Research: Neuroimaging*. 2009 May;172(2):109–16.

Trimble MR, Cavanna AE. Chapter 3.7 The role of the precuneus in episodic memory. *Handbook of Episodic Memory*. Elsevier; 2008. pp. 363–77. (*Handbook of Behavioral Neuroscience*; vol. 18).

Trojanowski JQ, Lee VM. Transgenic models of tauopathies and synucleinopathies. *Brain Pathol*. 1999 Oct;9(4):733–9.

Tustison NJ, Cook PA, Klein A, Song G, Das SR, Duda JT, et al. Large-scale evaluation of ANTs and FreeSurfer cortical thickness measurements. *NeuroImage*. Academic Press; 2014 Oct 1;99:166–79.

Vighetto A. Towards an earlier diagnosis of Alzheimer's disease presenting with visuospatial disorders (posterior cortical atrophy). *Revue Neurologique*. 2013 Oct;169(10):687–94.

Wang H, Suh JW, Das SR, Pluta J, Craige C, Yushkevich PA. Multi-Atlas Segmentation with Joint Label Fusion. *IEEE Trans Pattern Anal Mach Intell*. IEEE; 2013;35(3):611–23.

Wang L, Miller JP, Gado MH, McKeel DW, Rothermich M, Miller MI, et al. Abnormalities of hippocampal surface structure in very mild dementia of the Alzheimer type. *NeuroImage*. 2006 Mar;30(1):52–60.

Warren JD, Fletcher PD, Golden HL. The paradox of syndromic diversity in Alzheimer disease. *Nat Rev Neurol*. Nature Publishing Group; 2012 Jul 17;8(8):451–64.

Wechsler D. *Wechsler memory scale—Third edition*. The Psychological Corporation: San Antonio; 1997.

Weintraub S, Rogalski E, Shaw E, Sawlani S, Rademaker A, Wieneke C, et 108

- al. Verbal and nonverbal memory in primary progressive aphasia: the Three Words-Three Shapes Test. *Behavioural Neurology*. Hindawi Publishing Corporation; 2013;26(1-2):67–76.
- Whitwell JL, Jones DT, Duffy JR, Strand EA, Machulda MM, Przybelski SA, et al. Working memory and language network dysfunctions in logopenic aphasia: a task-free fMRI comparison with Alzheimer's dementia. *Neurobiol Aging*. 2015 Mar;36(3):1245–52.
- Williams BW, Mack W, Henderson VW. Boston Naming Test in Alzheimer's disease. *Neuropsychologia*. 1989;27(8):1073–9.
- Wilson SM, Henry ML, Besbris M, Ogar JM, Dronkers NF, Jarrold W, et al. Connected speech production in three variants of primary progressive aphasia. *Brain*. Oxford University Press; 2010 Jul 1;133(7):2069–88.
- Win KT, Pluta J, Yushkevich P, Irwin DJ, McMillan CT, Rascovsky K, et al. Neural Correlates of Verbal Episodic Memory and Lexical Retrieval in Logopenic Variant Primary Progressive Aphasia. *Front Neurosci*. Frontiers; 2017 Jun 14;11:33.
- Wixted JT, Squire LR. The Cognitive Neuroscience of Human Memory Since H.M. *Annu Rev Neurosci*. 2011a Jul 21;34(1):259–88.
- Wixted JT, Squire LR. The medial temporal lobe and the attributes of memory. *Trends in Cognitive Sciences*. 2011b May;15(5):210–7.
- Wolk DA. Amyloid Imaging in Atypical Presentations of Alzheimer's Disease. *Curr Neurol Neurosci Rep*. 2013 Oct 18;13(12):412.
- Wolk DA, Dickerson BC, Initiative TADN, Weiner M, Aiello M, Aisen P, et al. Apolipoprotein E (APOE) genotype has dissociable effects on memory and attentional–executive network function in Alzheimer's disease. *Proceedings of the National Academy of Sciences*. National Acad Sciences; 2010 Jun 1;107(22):10256–61.
- Yushkevich PA, Pluta JB, Wang H, Xie L, Ding S-L, Gertje EC, et al. Automated volumetry and regional thickness analysis of hippocampal subfields and medial temporal cortical structures in mild cognitive impairment. *Hum Brain Mapp*. 2014 Sep 2;36(1):258–87.
- Verbal Repetition in Primary Progressive Aphasia and Alzheimer's Disease. 2014 Jun 18;:575–85.

2017 Alzheimer's disease facts and figures. *Alzheimers Dement.* Elsevier; 2017  
Apr 1;13(4):325–73.