



University of Pennsylvania
ScholarlyCommons

Departmental Papers (Dental)

Penn Dental Medicine

3-2006

Experimental Study on the Acellular Demal Matrix Graft for the Root Coverage in Dog

Min-Young Cho
Ewha Womans University

Seoung-Ho Lee
Ewha Womans University

Keum-Ah Han
Ewha Womans University

Jun-Young Lee
Ewha Womans University

Hyeran H. Jeon
University of Pennsylvania School of Dental Medicine, hjeon@upenn.edu

See next page for additional authors

Follow this and additional works at: https://repository.upenn.edu/dental_papers

 Part of the [Oral and Maxillofacial Surgery Commons](#), and the [Periodontics and Periodontology Commons](#)

Recommended Citation

Cho, M., Lee, S., Han, K., Lee, J., Jeon, H. H., Kang, N., & Kim, M. (2006). Experimental Study on the Acellular Demal Matrix Graft for the Root Coverage in Dog. *Journal of the Korean Academy of Periodontology*, 36 (1), 239-251. <http://dx.doi.org/10.5051/jkape.2006.36.1.239>

This item was published when Dr. Jeon was affiliated with Ewha Womans University, but she is now a faculty member of the University of Pennsylvania.

This paper is posted at ScholarlyCommons. https://repository.upenn.edu/dental_papers/44
For more information, please contact repository@pobox.upenn.edu.

Experimental Study on the Acellular Demal Matrix Graft for the Root Coverage in Dog

Abstract

Mucogingival surgery is a plastic surgical procedure designed to correct defects in the morphology, position, and dimensions of the gingiva surrounding the teeth. Many surgical techniques have been reported in mucogingival surgery. Since these procedures also include the soft tissue esthetic approach, the term "periodontal plastic surgery" has been proposed to be more appropriate.¹ Root coverage is a procedure that falls with this definition, and it has attracted more interest than others.

Disciplines

Dentistry | Oral and Maxillofacial Surgery | Periodontics and Periodontology

Comments

This item was published when Dr. Jeon was affiliated with Ewha Womans University, but she is now a faculty member of the University of Pennsylvania.

Author(s)

Min-Young Cho, Seoung-Ho Lee, Keum-Ah Han, Jun-Young Lee, Hyeran H. Jeon, Na-Ra Kang, and Myung-Rae Kim

Experimental Study on the Acellular Dermal Matrix Graft for the Root Coverage in Dog

Min-Young Cho¹, Seung-Ho Lee^{2,3}, Keum-Ah Han³, Jun-Young Lee³,
Hye-Ran Jeon^{1,3}, Na-Ra Kang¹, Myung-Rae Kim¹

Department of Implantology, Graduate School of Clinical Dentistry, Ewha Womans University¹, Department of Periodontology, Graduate School of Clinical Dentistry, Ewha Womans University², Department of Periodontology, School of Medicine, Ewha Womans University³

I. Introduction

Mucogingival surgery is a plastic surgical procedure designed to correct defects in the morphology, position, and dimensions of the gingiva surrounding the teeth. Many surgical techniques have been reported in mucogingival surgery. Since these procedures also include the soft tissue esthetic approach, the term "periodontal plastic surgery" has been proposed to be more appropriate.¹ Root coverage is a procedure that falls with this definition, and it has attracted more interest than others. Root coverage has been performed through many surgical techniques. The autogenous masticatory graft (free gingival autograft) was proposed by Miller² as the first predictable technique to obtain root coverage. However, the procedure didn't show ideal esthetic results and offered a low degree of predictability in

the correction of gingival recessions. Pedicle grafts have been reported to offer good results in terms of root coverage³. Pedicle grafts provide the most esthetic result when adequate amount of keratinized gingiva exists. However, adequate gingiva does not always exist in adjacent locations.⁴ The guided tissue regeneration and the bilaminar techniques (BTs) consisting of connective tissue grafts with a pedicle graft have also been proposed as a possible therapeutic alternative in the management of gingival recessions.⁵⁻⁸ Comparative studies have demonstrated that bilaminar techniques show a significantly greater degree of predictability when the aim of the clinical trials is to obtain complete root coverage.^{9,10} The rationale of bilaminar techniques is to enhance the degree of predictability of therapeutic result

* Corresponding author : Seung-Ho Lee, Department of Periodontology, School of Medicine / Graduate School of Clinical Dentistry, Ewha Womans University, 911-1 Mok-6-dong, Yangcheon-gu, Seoul, Korea.
Tel : +82-2-2650-5680, Fax : +82-2-2650-5764, E-mail : perio772@ewha.ac.kr

by increasing the blood supply to the grafted tissue in comparison to the free gingival flap. Currently, bilaminar techniques are considered to be the surgical procedures offering the most predictable results when the maximum percentage of root coverage(%RC) represents the main goal.¹⁴ Bilaminar techniques make use of an autogenous connective tissue graft from the palate to increase the gingival dimensions, and therefore require a second surgical procedure to harvest the tissue from the donor area. This causes discomfort to the patient because two surgical sites must be prepared: The palatal donor site and the recipient site. As a result, postsurgical pain and the risk of bleeding from the donor site can be increased. The use of a barrier membrane underneath a coronally sliding flap in a GTR procedure has been proposed in order to avoid the need for tissue drawing from the palate. However, it has been observed that although the degree of root coverage yielded by GTR is similar to bilaminar techniques, the GTR procedure produces a lower increase in gingival thickness.¹⁵ And, the ability of guided tissue regeneration to produce a stable long term result has been questioned.¹⁶

Recently, acellular dermal graft(ADM) has been used as a substitute for the palatal donor sites for the root coverage, the treatment of alveolar ridge deformities, and the increasing the width of keratinized tissue around teeth.¹⁹ In addition, an acellular dermal matrix has been reported to have a favorable clinical outcome in root coverage at gingival recession sites.²⁰⁻²³ Originally, ADM was introduced in plastic surgery for the treatment of full-thickness burn wounds.²⁴ It was subsequently in-

troduced to periodontal surgery in 1994, as an alternative to the autogenous free gingival graft to increase the amount of keratinized attached gingiva around natural teeth or implants.²⁵ A periodontal plastic surgery procedure using ADM offers the advantage of avoiding the need for a palatal donor site, while offering to the clinician a tissue with a thickness similar to an autogenous connective graft. This allograft is obtained from a human donor skin tissue. Its cell components have been removed while the remaining bioactive components and the extracellular matrix preserved. Then the material is subsequently freeze-dried. The ADM exhibits undamaged collagen and elastin matrices that function as a scaffold to allow ingrowth by host tissues.²⁶ Due to its non-vital structure, it depends on cells and blood vessels from the recipient site to achieve reorganization.²⁶ The healing and revascularization of an autograft are based on the anastomoses between blood vessels of the gingival corium and the pre-existing blood vessels in the graft.^{27,28} When the ADM is associated with a coronally positioned flap, the overlying flap provides an extrasource of blood supply. Finally, the favorable healing and the incorporation of the allograft are enhanced as well.²⁹

Previous studies compared the clinical results obtained with ADM(test group) and the subepithelial connective tissue graft(SCTG;control group) for the treatment of gingival recessions.^{20,21,30} None of them showed any significant differences in recession reduction between the procedures. However, there is no information regarding the histologic evaluation of the ADM

graft or connective tissue graft.

The aim of the present study was to evaluate the effectiveness and histological healing appearance of an acellular dermal matrix allograft for the root coverage and to compare it with connective tissue grafts, when used with a coronally positioned flap.

II. Materials and Methods

1. Materials

Three male mongrels were used for this study. The left and right maxillary canines were prepared in each animal. At the initiation of the study, a mild chronic gingivitis with moderate amounts of calculus was present in all animals. All canines were scaled and polished prior to surgery. The acellular dermal matrix graft (SureDerm™; Hans Biomed, Seoul, Korea) and the autogenous connective tissue graft was used as the graft material.

2. Experimental methods

Prior to surgery, each dog was selected with an intramuscular injection of 50mg/ml

Ketamine HCL (Ketarlar; Yuhan-Kimberly, Seoul, Korea) and 1.5mg/10kg Xylazine (Rompun; Bayer-Korea, Seoul, Korea). In addition, the surgical area was locally anesthetized with 2% lidocaine solution containing epinephrine.

Before creating artificial gingival defect, a notch was placed at the gingival margin level with fissure bur. It served reference point at the coverage surgery and observations.

1) Surgical procedures

Surgical preparation of the artificial defect was previously described in detail by Guiha et al.³⁰ Artificial gingival recessions were created surgically by removing all keratinized gingiva and raising a mucoperiosteal flap and removing buccal alveolar bone. Finally, the buccal alveolar bone around canine was removed at level of 12mm apical direction from CEJ. The flaps were coronally positioned and sutured back leaving the some part of root surface exposed. The gingival wounds were left untreated for 35 days. Clinical data were recorded three times: beginning of the experiment, before surgical coverage, 4 weeks after the surgery. All measurements were performed at the buccal surface of the canines and were made at the experimental sites by a Williams probe (Vivacare TPS probe; Ivoclar Vivadent, Schaan, Liechtenstein) accurate to the nearest 0.5mm.

- a. Recession height (RH) : the distance between the cemento-enamel junction (CEJ) and the most apical point of the gingival margin.
- b. Probing pocket depth (PPD)
- c. Clinical attachment levels (CALs) : the distance from the bottom of the pocket to the CEJ. (RH + PPD)
- d. Height of the keratinized tissue (HKT) : between the most apical portion of the gingival margin to the mucogingival junction.

All surgical procedures were done by one operator. The same surgical procedures were used for both groups, except that one group received the acellular dermal matrix graft (test group), while

the other group received connective tissue graft (control group). Following intramuscular injection for sedation and local anesthesia, root planning of the exposed root surfaces was performed in order to remove the contaminated root surfaces. The exposed root surfaces were gently planed with sharp curettes and root surfaces were conditioned with a solution of citric acid (pH=1.0) for about 2 minutes 30 seconds. The cotton pellets were soaked in the solution and burished on the surfaces as a chemical preparation. That was changed approximately every 30 seconds. The tooth surfaces were then thoroughly flushed with sterile saline. The coronally positioned flap used in both groups was based on a design described by Bernimoulin et al.³¹ A partial thickness flap was reflected by sharp dissection as close to the periosteum as possible, beyond the mucogingival junction, and was extended until the partial thickness flap could be passively positioned over the defects without tension. Following flap elevation, the exposed root surface gently planed with sharp curettes.

The surgical protocol used for the ADM group (Fig 1) was described in detail by Dodge et al.³². The exposed root surface of the test group was treated with acellular dermal matrix allograft that was aseptically rehydrated in sterile saline, according to the manufacturer's instructions. The graft was trimmed to the shape and size designed to cover the root surface and the surrounding bone. The acellular dermal matrix was then positioned basement membrane (white side) of the ADM adjacent to the pedicle and the connective tissue side (red side) adjacent to the tooth and periosteum.

In the case of treating with a connective tissue graft, a connective tissue graft was removed from the middle palatal area (Figure 2). The graft was taken as full thickness including epithelium, connective tissue. The epithelium was removed with No. 15 blade on the surgical table. Finally, the harvested CTG was trimmed to same dimensions of the ADM. The palatal donor site was sutured with silk.

The graft material was placed against the root surface and was sutured using a sling suture technique with a Vicryl (Ethicon: Somerville, NJ, USA) 4-0 suture material after placement of the graft material. The flap was coronally positioned and sutured using a sling suture technique with a silk. The vertical releasing incisions were closed with interrupted sutures. All dogs underwent the same postsurgical management, consisting of intramuscular injection of Antibiotic (Ubactam: Hanmi Pharm, Seoul, Korea) and the prescription of 0.12% Chlorhexidine gluconate (Hexamedin solution: Bu Kwang pharm, Seoul, Korea) rinse weekly for 4 weeks following the surgery. The sutures were removed after 7 days healing.

2) Histologic examination

At 28 days after surgery, the specimens were taken in block with a scalpel and fissure burs under deep sedation. Blocks including the canines and the surrounding tissues were fixed in 10% formalin and decalcified with a solution which contained 5% nitric acid. The specimens were processed and embedded in paraffin. They were serially sectioned longitudinally at 4 μ m using

LEICA RM 2145 (Leica Microsystems Nussloch GmbH, Heidelberg, Germany) and stained with hematoxylin and eosin (H&E).

Each stained specimen was evaluated under a light microscope at varying magnifications to determine orientation. After initial evaluation, each stained section was magnified and photographed using the KAPPA Image Base (KAPPA opto-electronics, Gottingen, Germany). Analysis of each section was carried out under the light microscope at varying magnifications to record information pertaining to the overall structure and composition of the tissues.

3) Statistical analyses

Descriptive statistics are expressed as means \pm standard deviations (SD), while all the hypothesis testings were by non-parametric methods:

The percentage of root coverage was calculated as :

$$\frac{\text{gingival recession baseline} - \text{gingival recession at 4 weeks}}{\text{gingival recession baseline}} \times 100$$

Quantitative data were recorded as mean \pm standard deviation. The Wilcoxon signed rank test was used to analyze whether clinical measurements differed before and after

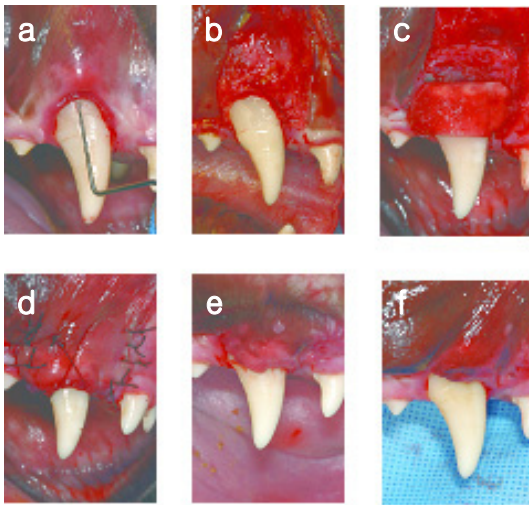


Figure 1. ADM group (Acellular dermal matrix graft).

- a)** Preoperative recession on a maxillary right canine with a narrow zone of keratinized tissue.
- b)** Reflection of partial thickness flap and recipient bed preparation.
- c)** Acellular dermal matrix graft sutured in place with a bioabsorbable suture.
- d)** Flap coronally sutured to completely cover the acellular dermal matrix graft.
- e)** Acellular dermal matrix graft at 2 weeks.
- f)** Acellular dermal matrix graft at 4 weeks.

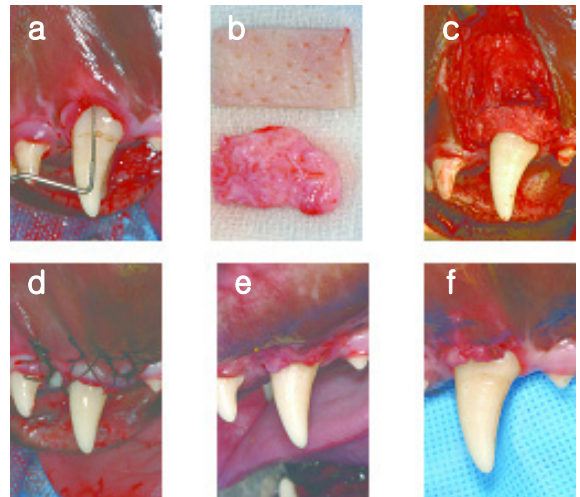


Figure 2. CT group (Connective tissue graft).

- a)** Preoperative recession on a maxillary left canine with a narrow zone of keratinized tissue.
- b)** Comparison of two graft material. (upper: acellular dermal matrix graft, lower: connective tissue graft)
- c)** Connective tissue graft sutured in place with a bioabsorbable suture material.
- d)** Coronally positioned flap sutured to completely cover the connective tissue graft.
- e)** Connective tissue graft at 2 weeks.
- f)** Connective tissue graft at 4 weeks.

treatment. The Mann–Whitney U test was used to determine if one surgical procedure produced better clinical result after 4 weeks. For all statistical analyses, a significance level of 5% was used.

III. Results

1. Clinical evaluation

Uneventful healing was observed through the experimental period in all dogs. Three dogs with six gingival recessions were treated with acellular dermal matrix graft (3 recessions) or connective tissue graft (3 recessions) associated with coronally positioned flap.

As comparison with the preoperative measurements, small amounts of keratinized tissue and moderate degree of reduction in recession height were observed at 4 weeks after graft surgery in all groups. But there were little change in pocket depth after healing. No significant differences were ob-

served between two groups in the clinical parameters evaluated.

The average initial recession height for the six sites was 6.78 ± 0.71 mm. After 4 weeks, the average residual recession height for all the sites was 2.50 ± 0.22 mm. (coverage percentage of root coverage = $58.50\% \pm 3.80\%$).

The results of the intragroup analysis are summarized in Table 1. Both treatments produced significant changes from baseline in all the parameters evaluated ($p < 0.05$) with the exception of PPD.

2. Histological evaluation

In all groups, the overlying epithelium of the gingiva and mucosa as well as the sulcular epithelium and junctional epithelium were similar. No gross inflammatory reaction was seen, and the inflammatory infiltrate was predominately located within the connective tissue adjacent to the sulcular epithelium in ADM-grafted sites. (Fig 3)

With in the gingiva, the collagen fibers of

Table 1. Gingival changes after ADM graft compared to CT graft.

Parameter	ADM (mm)	P-value	CT (mm)	P-value
HKT baseline	1.00 ± 0.57	$P < 0.05$	0.67 ± 0.33	$P < 0.05$
	3.00 ± 0.58		3.33 ± 0.67	
RH baseline	6.00 ± 0.00	$P < 0.05$	6.00 ± 0.00	$P < 0.05$
	2.67 ± 0.33		2.33 ± 0.33	
PPD baseline	2.00 ± 0.00	N.S	2.33 ± 0.33	N.S
	2.00 ± 0.00		2.00 ± 0.00	
CAL baseline	8.00 ± 0.00	$P < 0.05$	8.33 ± 0.33	$P < 0.05$
	4.67 ± 0.33		4.33 ± 0.33	

*Statistically significant at $p < 0.05$

#Wilcoxon signed rank test before and after treatment.

Table 2. Clinical difference between CT group and ADM group after 4 weeks.

Parameter	ADM (mm)	CT (mm)	p value
HKT increase	2.00±0.58	2.67±0.88	N.S
RH reduction	3.33±0.33	3.67±0.33	N.S
PPD decrease	0.00±0.00	0.33±0.33	N.S
CAL gain	3.33±0.33	4.00±0.00	N.S

*Statistically significant at $p < 0.05$

#Mann-Whitney U test between treatments

the host's overlying connective tissue and those of the underlying area corresponding to the grafted area were similarly dense and incorporated such that it was difficult to distinguish one from the other with standard H&E. The attachments to the root surfaces were similar. (Figure 3 and Figure 4)

Adjacent to the tooth and coronal to the osseous crest, beneath the graft, dense collagen was generally arranged parallel to the root surface in two groups. But, the collagen fiber density and quantity in CT-grafted

sites was considered mostly as 'sparse' while as 'dense' in the ADM-grafted site. As comparison with the autogenous connective tissue samples, a significantly increased bucco-lingual thickness of collagen fibers in the ADM grafted site was noted in the areas of previous graft placement. The osseous crest was present at the apical from the root notch in all groups. And alveolar bone remodeling appearance was observed in all sites. But, the remodeling process appeared to be more active in CT grafted sites




Figure 3. Acellular dermal matrix graft specimen.
a) root notch(←),connective tissue attachment(CT),collagen fiber(CF), osseous crest(O).(original magnification 12.5; H&E)
b) root(R), cementum(C). (original magnification 40; H&E)

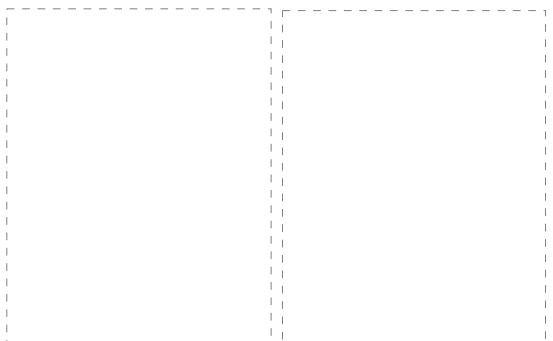


Figure 4. Connective tissue graft specimen.
a) root notch(→),connective tissue attachment(CT),collagen fiber(CF), osseous crest(O).(original magnification 12.5; H&E)
b) root (R), cementum(C).blood vessel(V) (original magnification 40)

In one specimen of CT grafted sites, blood vessels were observed between alveolar bone and periodontal ligament. The additional deposition or resorption of cementum was not observed in all specimens of each group.

IV. Discussion

The main goal of this study was to compare the effectiveness of two bilaminar techniques: the ADM graft and the autogenous CT graft. The results of present study showed that both periodontal plastic surgical procedures were able to significantly improve the clinical parameters evaluated from the preoperative baseline to the 4 weeks postoperative inspection. The only exception was seen for PPD, which did not show significant changes at the 4 weeks examination in either group. This result was expected, because the baseline PPD was compatible with a condition of gingival health in these experimental animals.

Similar amounts of root coverage were obtained with both procedures. When the acellular dermal matrix was used, the mean root coverage was $61.33\% \pm 5.67\%$, and when a connective tissue graft was used, the mean root coverage was $55.67\% \pm 5.67\%$. Those rates of mean root coverage imply that acellular dermal matrix may be a suitable substitute for autogenous connective tissue grafts in clinical practice.

The reported root coverage in this study is lower than that from other studies, in a comparative study between CT and ADM grafts used in a bilaminar techniques^{16,20,21,33-37}, but well within the range of

reported root coverage.^{8,10,20,21,38-44} Harris²⁰ reported comparable percentage root coverages from both treatments (CT:96.2%, ADM:95.8%). The connective tissue graft produced a great mean probing reduction and mean keratinized tissue increase than the acellular dermal matrix. However, this did not appear to be clinically significant. Similarly, no significant differences were reported between CT and ADM grafts by Aichelmann-Reidy et al.²¹ These authors²¹ observed mean root coverages of 74.1%(CT) and 65.9%(ADM). Paolantonio¹⁶ reported mean percentage of root coverages were 88.80% and 83.33 % in the CT and ADM groups. No significant differences were observed between the two techniques for gingival recession, clinical attachment level.

Relatively lower percentage of root coverage was due to the lack of postsurgical care with possible graft mobility and inadequate oral hygiene. In order to obtain more predictable results, careful surgical technique and meticulous postsurgical care might be required. During the postsurgical maintenance period, all patients were routinely instructed not to touch or brush surgical areas and daily chlorhexidine rinse several times a day is critical in human. However, it is impossible to put a routine oral hygiene regimen for the experimental animals. As a result, the graft material could not be maintained intact over the surgical sites. Some part of the graft material was necrotized and gone away. This event might have contributed relatively low percentage of root coverage.

Another issue to mention is how much

time is needed to heal the root coverage surgery in these experimental animals. Rami Guiha et al³⁰ who studied histological healing of subepithelial connective tissue grafts in dogs, reported that demarcation zones were not at all visible and could not be detected at 28 days. This is in agreement with the findings of Garguilo and Arrocha et al⁴⁵ who studied the histological healing of free gingival grafts in human. In addition, the microvasculature of the flap and the graft was almost normal. In the present study, biopsy and clinical measurement were performed after 28 days according to the previous study³⁰. In the present study, light microscopical observations show the epithelium area contain more chronic inflammatory cell infiltrate in the specimens of ADM groups than that of CT groups. These suggest that healing of the ADM have been generally retarded compared to autograft. There are some reports, which have described the retarded healing of the ADM like Wei et al's studies^{26, 27}. In their studies^{26, 27}, the clinical healing of the ADM was generally retarded by approximately 2 weeks when compared to free gingival tissue graft. At the present, there is no report to describe about the complete healing time when ADM graft is applied for root coverage in dogs. Therefore, further study will be followed to find out the exact time necessary to obtain a mature tissue structure using acellular dermal matrix graft placed underneath a pedicle flap.

V. Conclusion

The experimental studies on the healing of the ADM disclosed that:

1. As comparison with the preoperative measurements, reduction in recession height and increase in keratinized tissue, improvement in clinical attachment level were observed in all groups. ($p \leq 0.05$)
2. The mean root coverage was $61.33 \pm 5.67\%$ ($n=3$) for ADM group and $55.67 \pm 5.67\%$ ($n=3$) for CT group.
3. No statistically significant differences were observed between ADM group and CT group in the parameters evaluated. ($p > 0.05$)
4. In histologic evaluation, all graft materials were well incorporated with recipient sites. Also similar healing appearances were observed in two groups.
5. The acellular dermal matrix can be a suitable for autogenous connective tissue grafts for root coverage in the treatment of gingival recession.

References

1. Miller PD Jr. Root coverage grafting for regeneration and aesthetics. *Periodontol* 2000. 1993;1:118-27.
2. Miller PD. Root coverage using a free soft tissue autograft following citric acid application. part 1: technique. *Int J Periodontics Restorative Dent*. 1982;2(1):65-70
3. Wennstrom JL, Lang NP. Proceedings of the 1st European Workshop on Periodontology. London, Quintessence

- Publishing Co.Ltd: 1994. p. 193-209.
4. Cummings LC, Kaldahl WB, Allen EP. Histologic evaluation of autogenous connective tissue and acellular dermal matrix grafts in humans. *J Periodontol.* 2005;76(2):178-86.
 5. Gottlow J, Karring T, Nyman S. Guided tissue regeneration following treatment of recession-type defects in the monkey. *J Periodontol.* 1990;61(11):680-5.
 6. Cortellini P, DeSanctis M, Pini Prato G, Baldi C, Clauser C. Guided tissue regeneration procedure using a fibrin-fibronectin system in surgically induced recession in dogs. *Int J Periodontics Restorative Dent.* 1991;11(2):150-63.
 7. Cortellini P, Clauser C, Prato GP. Histologic assessment of new attachment following the treatment of a human buccal recession by means of a guided tissue regeneration procedure. *J Periodontol.* 1993;64(5):387-91.
 8. Parma-Benfenati S, Tinti C. Histologic evaluation of new attachment utilizing a titanium-reinforced barrier membrane in a mucogingival recession defect. a case report. *J Periodontol.* 1998;69(7):834-9.
 9. Sbordone L, Ramaglia L, Spagnuolo G, De Luca M. A comparative study of free gingival and subepithelial connective tissue grafts. *Periodontal Case Rep.* 1988; 10(1):8-12.
 10. Paolantonio M, Di Murro C, Cattabriga A, Cattabriga M. Subpedicle connective tissue graft versus free gingival graft in the coverage of exposed root surfaces. a 5-year clinical study. *J Clin Periodontol.* 1997 ;24(1):51-6.
 11. Langer B, Langer L. Subepithelial connective tissue graft technique for root coverage. *J Periodontol.* 1985;56(12):715-20.
 12. Raetzke PB. Covering localized areas of root exposure employing the "envelope" technique. *J Periodontol.* 1985;56(7):397-402.
 13. Nelson SW. The subpedicle connective tissue graft. a bilaminar reconstructive procedure for the coverage of denuded root surfaces. *J Periodontol.* 1987;58(2):95-102.
 14. Harris RJ. A comparative study of root coverage obtained with guided tissue regeneration utilizing a bioabsorbable membrane versus the connective tissue with partial-thickness double pedicle graft. *J Periodontol.* 1997;68(8):779-90.
 15. Rateitschak KH, Egli U, Fringeli G. Recession: a 4-year longitudinal study after free gingival grafts. *J Clin Periodontol.* 1979;6(3):158-64.
 16. Paolantonio M, Dolci M, Esposito P, Archivio D, Lisanti L, Di Luccio e. Subpedicle acellular dermal matrix graft and autogenous connective tissue graft in the treatment of gingival recessions: a comparative 1-year clinical study. *J Periodontol.* 2002; 73(11):1299-307.
 17. Muller HP, Eger T. Gingival phenotypes in young male adults. *J Clin Periodontol.* 1997;24(1):65-71.
 18. Muller HP, Eger T, Schorb A. Gingival dimensions after root coverage with free connective tissue grafts. *J Clin Periodontol.* 1998;25(5):424-30.
 19. Cortes Ade Q, Martins AG, Nociti FH Jr, Sallum AW, Casati MZ, Sallum EA. Coronally positioned flap with or without acellular dermal matrix graft in the treatment of Class I gingival recessions: a randomized controlled clinical study. *J*

- Periodontol. 2004;75(8):1137-44.
20. Harris RJ. A comparative study of root coverage obtained with an acellular dermal matrix versus a connective tissue graft: results of 107 recession defects in 50 consecutively treated patients. *Int J Periodontics Restorative Dent.* 2000;20(1):51-9.
 21. Aichelmann-Reidy ME, Yukna RA, Evans GH, Nasr HF, Mayer ET. Clinical evaluation of acellular allograft dermis for the treatment of human gingival recession. *J Periodontol.* 2001;72(8):998-1005.
 22. Tal H. Subgingival acellular dermal matrix allograft for the treatment of gingival recession: a case report. *J Periodontol.* 1999;70(9):1118-24.
 23. Henderson RD, Greenwell H, Drisko C, Regennitter FJ, Lamb JW. Predictable multiple site root coverage using an acellular dermal matrix allograft. *J Periodontol.* 2001;72(5):571-82.
 24. Wainwright DJ. Use of the AlloDerm in the management of full-. 1995;21(4):243-8.
 25. Wei PC, Laurell L, Geivelis M, Lingen MW, Maddalozzo D. Acellular dermal matrix allografts to achieve increased attached gingiva. part 1. a clinical study. *J Periodontol* 2000;71(8):1297-1305.
 26. Batista EL Jr, Batista FC, Novaes AB Jr. Management of soft tissue ridge deformities with acellular dermal matrix. clinical approach and outcome after 6 months of treatment. *J Periodontol.* 2001;72(2):265-73.
 27. Oliver RC, Loe H, Karring T. Microscopic evaluation of the healing and revascularization of free gingival grafts. *J Periodontal Res.* 1968;3(2):84-95.
 28. Janson WA, Ruben MP, Kramer GM, Bloom AA. Development of the blood supply to split-thickness free gingival autografts. *J Periodontol.* 1969;40(12):707-16.
 29. Barros RR, Novaes AB, Grisi MF, Souza SL, Taba MJ, Palioto DB. A 6-month comparative clinical study of a conventional and a new surgical approach for root coverage with acellular dermal matrix. *J Periodontol.* 2004; 75(10):1350-6.
 30. Guiha R, Khodeiry S, Mota L, Caffesse R. Histological evaluation of healing and revascularization of the subepithelial connective tissue graft. *J Periodontol.* 2001; 72(4):470-8.
 31. Bernimoulin JP, Luscher B. Coronally repositioned periodontal flap. clinical evaluation after one year. *J Clin Periodontol.* 1975; 2(1):1-13.
 32. Dodge JR, Henderson RD. Root coverage without a palatal donor site, using an acellular dermal graft. *Periodontal Insights* 1998; 5(4):5-9.
 33. Novaes AB, Grisi DC, Molina GO, Souza SL, Taba M. Comparative 6-month clinical study of a subepithelial connective tissue graft and acellular dermal matrix graft for the treatment of gingival recession. *J Periodontol* 72(11):1477-84.
 34. Harris RJ. The connective tissue and partial thickness double pedicle graft: a predictable method of obtaining root coverage. *J Periodontol.* 1992; 63(5): 477-86.
 35. Harris RJ. The connective tissue with partial thickness double pedicle graft: the results of 100 consecutively-treated defects. *J Periodontol.* 1994; 65(5):448-61.
 36. Levine RA. Covering denuded maxillary

- root surfaces with the subepithelial connective tissue graft. *Compendium*. 1991; 2(8):568-572.
37. Wennstrom JL. Increased gingival dimensions. A significant factor for successful outcome of root coverage procedures? a 2-year prospective clinical study. *J Clin Periodontol*. 1996; 23(8):770-7.
 38. Baldi C, Pini-Prato G, Pagliaro U, Nieri M, Saletta D, Muzzi L et al. Coronally advanced flap procedure for root coverage. Is flap thickness a relevant predictor to achieve root coverage? a 19-case series. *J Periodontol*. 1999; 70(9):1077-84.
 39. Borghetti A, Louise F. Controlled clinical evaluation of the subpedicle connective tissue graft for the coverage of gingival recession. *J Periodontol*. 1994; 65(12):1107-12.
 40. Borghetti A, Glise JM, Monnet-Corti V, Dejou J. Comparative clinical study of a bioabsorbable membrane and subepithelial connective tissue graft in the treatment of human gingival recession. *J Periodontol*. 1999; 70(2):123-30.
 41. Bouchard P, Etienne D, Ouhayoun JP. Subepithelial connective tissue grafts in the treatment of gingival recessions. a comparative study of 2 procedures. *J Periodontol*. 1994; 65(10):929-36.
 42. Bouchard P, Nilveus R, Etienne D. Clinical evaluation of tetracycline HCl conditioning in the treatment of gingival recessions. a comparative study. *J Periodontol*. 1997; 68(3):262-9.
 43. Jahnke PV, Sandifer JB, Gher ME, Gray JL, Richardson AC. Thick free gingival and connective tissue autografts for root coverage. *J Periodontol*. 1993; 64(4):315-22.
 44. Ricci G, Silvestri M, Tinti C, Rasperini G. A clinical/statistical comparison between the subpedicle connective tissue graft method and the guided tissue regeneration technique in root coverage. *Int J Periodontics Restorative Dent*. 1996; 16(6):538-45.
 45. Gargiulo AW, Arrocha R. Histo-clinical evaluation of free gingival grafts. *Periodontics*. 1967; 5(6):285-91.

성견에서 ADM(acellular dermal matrix)의 치근피개 효과에 관한 실험적 연구

조민영¹, 이승호^{2,3}, 한금아³, 이준영³, 전해란^{1,3}, 강나라¹, 김명래¹

이화여자대학교 임상치의학대학원 임플란트학과¹,
이화여자대학교 임상치의학대학원 치주과학교실²,
이화여자대학교 의과대학/이화의료원 목동병원 치주과³

결합조직이식을 이용한 치근피개 술식에 많은 관심이 집중되고 있다. 최근에는 acellular dermal matrix 가 자가 결합조직 이식편의 대체물로써 소개되었다. 본 실험의 목적은 치근피개를 위해 acellular dermal matrix을 사용시, 그 임상 효과 및 조직 치유 양상을 평가하고, 이를 자가 결합조직 이식시의 결과와 비교하기 위함이다.

3마리의 성견에 인위적인 치은 퇴축부 형성을 위해서, 상악 좌우견치의 협측에서 각화치은을 모두 제거하고, 법랑백악경계부로부터 12mm 정도 치조골을 삭제한 후에 판막을 봉합하였다. 그 후 35일을 치유 기간으로 부여하였다. 총 6 부위의 결손부가 실험에 포함되었고, 각각 3 부위씩이 대조군과 실험군으로 분류되었다. 실험군에서는 acellular dermal matrix 이식과 치관측 변위 판막을 시행하였고, 대조군에서는 치은 퇴축부위에 자가 결합조직 이식과 치관측 변위 판막을 시행하였다.

치주낭 깊이, 임상적 부착 수준, 치은 퇴축 높이, 각화조직 높이 등을 인위적 결손부 형성전, 치은 피개술 시행 직전, 피개술 시행후 4주 경과시에 각각 측정하였다. 술후 4주시에, 상악 좌우 견치 부위에서 시편을 얻어 조직학적으로 관찰하고 Wilcoxon signed rank test 와 Mann-Whitney U test으로 통계처리하였다.

임상결과 관찰시, 대조군과 실험군 모두에서, 술전과 비교시 치은 퇴축 감소와 각화조직의 증가, 임상 부착 수준의 개선이 나타났다.(p (0.05) 평균 치근 피개율은 실험군에서 61.33(5.67%(n=3), 대조군에서 55.67(5.67%(n=3) 이었고, 대조군과 실험군에서 임상결과에서는 통계학적으로 유의성 있는 차이는 없었다.(p (0.05). 조직학상으로는, 두 군 모두에서 이식편이 수여부에 잘 융화되어 있었고 비슷한 치유 양상을 보였다.

이상의 실험결과에 의하면, Acellular dermal matrix은 치근피개술 시행시에 결합조직 이식편의 대용품으로 사용할 수 있고 비슷한 피개 결과를 얻을수 있었다.

