



**University of Dundee**

**Avascular necrosis of the hip and diffuse idiopathic skeletal hyperostosis during long-term isotretinoin treatment of epidermolytic ichthyosis due to a novel deletion mutation in KRT10**

Lamb, R. C.; Lang, J.; Terron-Kwiatowski, A.; Baty, D.; McLean, W. H. I.; Zamiri, M.

*Published in:*  
British Journal of Dermatology

*DOI:*  
[10.1111/bjd.13049](https://doi.org/10.1111/bjd.13049)

*Publication date:*  
2014

*Document Version*  
Publisher's PDF, also known as Version of record

[Link to publication in Discovery Research Portal](#)

*Citation for published version (APA):*  
Lamb, R. C., Lang, J., Terron-Kwiatowski, A., Baty, D., McLean, W. H. I., & Zamiri, M. (2014). Avascular necrosis of the hip and diffuse idiopathic skeletal hyperostosis during long-term isotretinoin treatment of epidermolytic ichthyosis due to a novel deletion mutation in KRT10. *British Journal of Dermatology*, 171(4), 913-915. <https://doi.org/10.1111/bjd.13049>

**General rights**

Copyright and moral rights for the publications made accessible in Discovery Research Portal are retained by the authors and/or other copyright owners and it is a condition of accessing publications that users recognise and abide by the legal requirements associated with these rights.

- Users may download and print one copy of any publication from Discovery Research Portal for the purpose of private study or research.
- You may not further distribute the material or use it for any profit-making activity or commercial gain.
- You may freely distribute the URL identifying the publication in the public portal.

**Take down policy**

If you believe that this document breaches copyright please contact us providing details, and we will remove access to the work immediately and investigate your claim.

- 6 Ghoshal UC, Ghoshal U, Jain M et al. *Strongyloides stercoralis* infestation associated with septicemia due to intestinal transmural migration of bacteria. *J Gastroenterol Hepatol* 2002; **17**:1331–3.
- 7 Newberry AM, Williams DN, Stauffer WN et al. *Strongyloides* hyperinfection presenting as acute respiratory failure and gram-negative sepsis. *Chest* 2005; **128**:3681–4.
- 8 Buonfrate D, Requena-Mendez A, Angheben A et al. Severe strongyloidiasis: a systematic review of case reports. *BMC Infect Dis* 2013; **13**:78.
- 9 Corsini AC. Strongyloidiasis and chronic urticaria. *Postgrad Med J* 1982; **58**:247–8.
- 10 Asato R. [Result report of the project for control of the endemic infection (*Strongyloides Stercoralis*) in Okinawa prefecture (1987–1992)]. *Infect Agents Surveillance Rep* 1993; **14**:158 (in Japanese).

Funding sources: none.

Conflicts of interest: none declared.

## Avascular necrosis of the hip and diffuse idiopathic skeletal hyperostosis during long-term isotretinoin treatment of epidermolytic ichthyosis due to a novel deletion mutation in *KRT10*

DOI: 10.1111/bjd.13049

DEAR EDITOR, Epidermolytic ichthyosis (EI; OMIM 113800), previously termed bullous congenital ichthyosiform erythroderma or epidermolytic hyperkeratosis, is a clinically heterogeneous disorder of keratinization. It is usually characterized by severe neonatal erythroderma, blistering and fragile skin, with the subsequent development of hyperkeratosis, predominantly in flexural areas. It is caused by mutations in either the *KRT1* or *KRT10* genes encoding the suprabasal keratins K1 and K10, respectively.<sup>1</sup> Mutations are usually missense substitutions in the highly conserved alpha-helical rod domains of these keratins, which play a critical role in filament formation.<sup>2</sup> We report a multigeneration kindred with EI due to a novel mutation in *KRT10*.

The proband was a 32-year-old woman from Shetland. She presented with widespread fine scale and erythema of her trunk and limbs, with a history of scaling and redness since birth but no blistering, erosions or collodion membrane reported. Clinical examination revealed widespread ichthyosis and erythema affecting the trunk and all four limbs, with more significant hyperkeratosis at the elbows, knees and ankles but relative sparing of palmoplantar skin (Fig. 1). Her father, uncle and grandmother were affected, and four further generations were reported to be affected. She had been maintained on oral isotretinoin 20–40 mg daily, thus modifying the clinical appearance, from the age of 13 years, but had recently developed lower back and hip pain. Radiographs of the lumbar spine and left hip demonstrated bridging osteophytes from T11 to L1, suggestive of diffuse

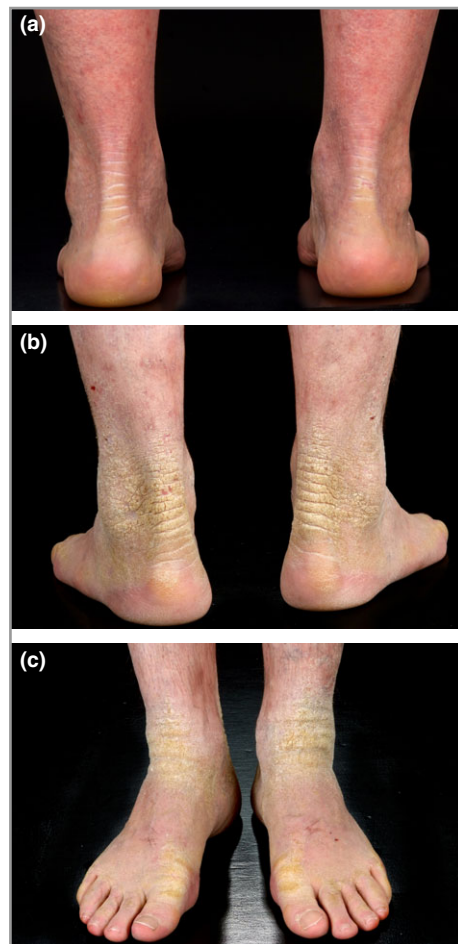

Fig 1. Family with epidermolytic ichthyosis. (a) Clinical picture of the proband: hyperkeratosis of nonplantar sites modified by oral retinoid therapy; (b, c) photographs of her father.

idiopathic skeletal hyperostosis (DISH), and magnetic resonance imaging confirmed the presence of avascular necrosis of the left hip. This was successfully treated with core decompression of the left hip with improvement in the patient's pain.

A biopsy of affected skin of the upper limb was obtained from the proband and processed for light microscopy by standard methods. Structural analysis demonstrated acanthosis, marked overlying hyperkeratosis and vacuolar change of the upper epidermal cells with prominent clumping of keratohyaline granules.

Following informed consent, genomic DNA samples were obtained from blood samples from the proband and her father. Mutation analysis of the coding regions and splice sites of the *KRT1* and *KRT10* genes was performed by standard polymerase chain reaction (PCR) and Sanger sequencing methods using specific primers. Sequence analysis of *KRT10* revealed a previously unreported heterozygous deletion of 167 base pairs extending from intron 5 into exon 6 (c.1156–79\_1243del), abolishing the intron 5 acceptor splice site (Fig. 2). This mutation was also present in the proband's affected father.

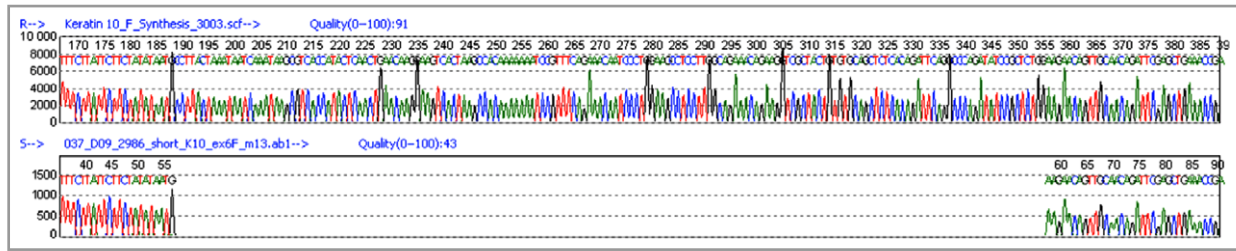


Fig 2. DNA sequencing of the KRT10 gene in the proband. Sequencing reveals a novel heterozygous deletion extending from intron 5 into exon 6 (K10 c.1156–79\_1243del), abolishing the exon 6 acceptor splice site resulting in a shorter aberrant keratin 10 (K10) protein lacking a sequence motif critically important for keratin filament assembly. The mutation was present in the proband's affected father but not in unaffected control samples.

RNA was obtained from the proband's skin biopsy. Following reverse transcription by standard methods, reverse-transcriptase PCR was performed using primers flanking the deletion on exons 5 and 6 of KRT10. RNA analysis demonstrated that the KRT10 c.1156–79\_1243del deletion activates a cryptic splice site 96 base pairs downstream from the consensus intron 5–exon 6 splice site, resulting in an in-frame deletion of 32 amino acids, p.Lys386\_Gln417, in the K10 protein. This truncated K10 protein, lacking the conserved helix termination motif, is likely to exert a dominant-negative effect on K1/K10 filament formation.

The keratin intermediate filament network is the main stress-bearing structure within the cytoplasm of epithelial cells. EI is caused by mutations in the keratin genes KRT1 and KRT10, which confer structural integrity to suprabasal keratinocytes, with most reported mutations being heterozygous missense mutations.<sup>3</sup> Approximately half of all cases of EI occur sporadically due to a spontaneous mutation.<sup>2</sup> In inherited cases of EI, it is inherited mostly in a dominant mode, as in this pedigree, although recessive inheritance has been reported.<sup>4</sup> Severe EI has been associated with mutations in the highly conserved helix boundary motifs, the helix initiation and termination peptides and the nonhelical H1 domain of K1 and K10.<sup>3</sup> Mutations in the L1–2 linker of K1 or outside the helix boundary motifs, similar to those seen in mild epidermolysis bullosa simplex, have been described.<sup>5</sup> A small number of insertion/deletion mutations and splice-site defects leading to larger in-frame deletions or rare dinucleotide alterations in KRT10, leading to substitution of two adjacent amino acids, have been described.<sup>6</sup> Genotype–phenotype correlations in EI are very complex, and it is suggested that both the position of the mutation within K1 or K10 and the nature of the amino acid substitution specifically influence the phenotypic expression of the disease.<sup>7</sup> Systemic retinoids should be used with caution in EI due to a risk of increased fragility and a tendency to blistering, although both topical and oral retinoids are thought to be more effective in those patients with EI with K10 mutations compared with K1. It is postulated that this may be due to the ability of patients with K10 mutations to tolerate better the downregulation of K2 caused by retinoids.<sup>8</sup>

To our knowledge, avascular necrosis of the femoral head has not previously been reported secondary to isotretinoin,

and it is unclear whether this contributed to the findings in the proband. Avascular necrosis of the femoral head occurs due to interruption of the microcirculation of the femoral head resulting in ischaemia, and may occur spontaneously or in relation to treatment with glucocorticoids, hypertension, sickle cell disease, trauma or other causes. Avascular necrosis of the hip has been reported with retinoids (all-trans-retinoic acid) used to treat haematological conditions; however, affected cases have often received concomitant glucocorticoids.<sup>9</sup> The long-term effects of oral retinoids remain under debate; however, experience of exposure to isotretinoin at this dose and for this length of time has been reported in the literature only rarely in comparison with other retinoids.<sup>10</sup> Previously reported skeletal abnormalities with retinoid therapy include periosteal thickening, premature epiphyseal closure in children, osteoporosis, extraspinal tendon and ligament calcification, osteophytes and bony bridges between vertebrae as in the proband, in addition to DISH characterized by anterior spinal ligament calcification. However, there are few prospective studies on the skeletal effects of long-term systemic retinoids, and many of the bony changes reported are also prevalent in the general population. This finding adds to the evidence that KRT10 mutations are the principal cause of autosomal dominant EI with palmoplantar sparing. It also highlights the possible side-effects of long-term oral retinoid treatment in these inherited conditions.

## Acknowledgments

We would like to thank the patients, their family members and control subjects for their cooperation in this study.

<sup>1</sup>Department of Dermatology, and

R. C. LAMB<sup>1</sup>

<sup>2</sup>Department of Pathology, University

J. LANG<sup>2</sup>

Hospital Crosshouse, Kilmarnock, U.K.

A. TERRON-KWIATOWSKI<sup>3</sup>

<sup>3</sup>East of Scotland Genetics Service, Ninewells

D. BATY<sup>3</sup>

Hospital, Dundee, U.K.

W. H. I. MCLEAN<sup>4</sup>

<sup>4</sup>Centre for Dermatology and Genetic

M. ZAMIRI<sup>1,5</sup>

Medicine, Division of Molecular Medicine,

University of Dundee, Dundee, U.K.

<sup>5</sup>Alan Lyell Centre for Dermatology,

Glasgow, U.K.

E-mail: rlamb@nhs.net

## References

- Oji V, Tadini G, Akiyama M et al. Revised nomenclature and classification of inherited ichthyoses: results of the First Ichthyosis Consensus Conference in Sorèze 2009. *J Am Acad Dermatol* 2010; **63**:607–41.
- Irvine AD, McLean WHI. Human keratin diseases: the increasing spectrum of disease and subtlety of the phenotype–genotype correlation. *Br J Dermatol* 1999; **140**:815–28.
- Lane EB, McLean WHI. Keratins and skin disorders. *J Pathol* 2004; **204**:355–66.
- Covaciu C, Castori M, De Luca N et al. Lethal autosomal recessive epidermolytic ichthyosis due to a novel donor splice site mutation in KRT10. *Br J Dermatol* 2010; **162**:1384–7.
- Bolling MC, Bladergroen RS, van Steensal MA et al. A novel mutation in the L12 domain of keratin 1 is associated with mild epidermolytic ichthyosis. *Br J Dermatol* 2010; **162**:875–9.
- Szeverenyi I, Cassidy AJ, Chung CW et al. The human intermediate filament database: comprehensive information on a gene family involved in many human diseases. *Hum Mutat* 2008; **29**:351–60.
- Arin MJ, Oji V, Emmert S et al. Expanding the keratin mutation database: novel and recurrent mutations and genotype–phenotype correlations in 28 patients with epidermolytic ichthyosis. *Br J Dermatol* 2011; **164**:442–7.
- Vahlquist A, Gånemo A, Virtanen M. Congenital ichthyosis: an overview of current and emerging therapies. *Acta Derm Venereol* 2008; **88**:4–14.
- Sakakura M, Nishii K, Usui E et al. Bilateral osteonecrosis of the head of the femur during treatment with retinoic acid in a young patient with acute promyelocytic leukemia. *Int J Hematol* 2006; **83**:252–3.
- Ellis CN, Pennes DR, Hermann RC et al. Long-term radiographic follow-up after isotretinoin therapy. *J Am Acad Dermatol* 1988; **18**:1252–61.

Funding sources: The Centre for Dermatology and Genetic Medicine at the University of Dundee is supported by a Wellcome Trust Strategic Award (098439/Z/12/Z to W.H.I.M.).

Conflicts of interest: None declared.

## Short- to intermediate-term follow-up in patients treated with the combination of 311-nm ultraviolet B phototherapy and biological agents

DOI: 10.1111/bjd.12992

DEAR EDITOR, Previous studies<sup>1–4</sup> have indicated that ultraviolet (UV) B phototherapy may increase the therapeutic response to biologics (see also citations in refs 1–4). Most recently, Calzavara-Pinton et al. reported that combined treatment with 311-nm UVB and etanercept had a synergistic effect for clearing chronic plaque-type psoriasis that was previously unresponsive to either form of monotherapy alone.<sup>5</sup> However, UVB phototherapy is potentially carcinogenic (although this has not yet been shown for 311-nm UVB in humans), and there are safety concerns, particularly in combination with biological agents.<sup>4</sup> We therefore analysed all available follow-up data to detect nonmelanoma skin cancer (NMSC) or melanoma in patients with psoriasis treated with 311-nm UVB phototherapy in combination with various biologics in different trials at our institution.<sup>1–4</sup>

From 29 patients with chronic plaque psoriasis who had been treated by combining 311-nm UVB with at least one biological agent at our department,<sup>1–4</sup> 28 (10 women, 18 men) were included in the follow-up analysis. One patient was excluded from the risk analysis because of a history of multiple grenz (Bucky) X-ray irradiation-related basal cell carcinomas before the start of combination treatment, but was included in the statistical analysis of therapeutic efficacy shown in Table 1. One patient, who was discontinued from the half-body comparison study with ustekinumab<sup>4</sup> because of a circumscribed herpetic eruption on the thigh on the UV-exposed body half, was excluded from the statistical analysis

**Table 1** Results on the efficacy of 311-nm ultraviolet (UV) B plus biologic combination therapy

Biologic, ref./NCT no.	Number of patients treated in a study	Percentage PASI reduction			
		Week 6		Week 12	
		UV	No UV	UV	No UV
Etanercept <sup>3</sup>	5	85.0	55.2	90.7	81.0
Adalimumab <sup>2</sup> , NCT00638469	6	83.5	46.1	67.7	51.2
Golimumab <sup>1</sup> , NCT01088698	2	82.9	69.3	n.a.	n.a.
Ustekinumab <sup>4</sup>	9	81.6	54.1	84.6	78.9
Alefacept <sup>1</sup>	14	72.6	31.5	82.7	63.7
All biological agents	36 <sup>a</sup>	81.1	51.2*	81.4	68.7 <sup>†</sup>

Data are mean values calculated from the results of 311-nm UVB half-side comparison studies, previously reported in refs 1–4 and two registered clinical trials. PASI, Psoriasis Area and Severity Index; n.a., not available. <sup>a</sup>Certain patients participated in more than one trial; therefore the total number for treatment with biological agents is higher than the total patient number (i.e. 28). \* $P = 0.003$ ; <sup>†</sup> $P = 0.0255$  by two-tailed paired Student's *t*-test comparing the UV-irradiated body halves vs. the nonirradiated body halves, based on intention to treat as in the first 6 weeks. Note that a portion of the patients ( $n = 6$ ) were also treated between weeks 7 and 12 with total-body 311-nm UVB (including the previously nonirradiated body half).