



# UNIVERSITÀ DI PARMA

## ARCHIVIO DELLA RICERCA

University of Parma Research Repository

Are mast cells implicated in asphyxia?

This is the peer reviewed version of the following article:

*Original*

Are mast cells implicated in asphyxia? / Cecchi, Rossana; C., Ciallella; L., Cipolloni; C., Sestili; C., Terranova; B., Muciaccia. - In: INTERNATIONAL JOURNAL OF LEGAL MEDICINE. - ISSN 1437-1596. - 126(2016), pp. s110-s111. [10.1007/s00414-015-1211-5]

*Availability:*

This version is available at: 11381/2824146 since: 2022-01-21T19:56:12Z

*Publisher:*

Springer Verlag

*Published*

DOI:10.1007/s00414-015-1211-5

*Terms of use:*

openAccess

Anyone can freely access the full text of works made available as "Open Access". Works made available

*Publisher copyright*

(Article begins on next page)

# International Journal of Legal Medicine

## Are mast cells implicated in asphyxia?

--Manuscript Draft--

<b>Manuscript Number:</b>	IJLM-D-15-00110R1
<b>Full Title:</b>	Are mast cells implicated in asphyxia?
<b>Article Type:</b>	Original Article
<b>Corresponding Author:</b>	Rossana Cecchi, M.D. University Rome, Rome ITALY
<b>Corresponding Author Secondary Information:</b>	
<b>Corresponding Author's Institution:</b>	University
<b>Corresponding Author's Secondary Institution:</b>	
<b>First Author:</b>	Barbara Muciaccia, PhD
<b>First Author Secondary Information:</b>	
<b>Order of Authors:</b>	Barbara Muciaccia, PhD Cristina Sestili, MD Stefania De Grossi Annarita Vestri Luigi Cipolloni, PhD Rossana Cecchi, M.D.
<b>Order of Authors Secondary Information:</b>	
<b>Funding Information:</b>	
<b>Abstract:</b>	<p>In a previous immunohistochemical (IHC) study, we documented the reaction of lung tissue vessels to hypoxia through the immunodetection of HIF1-<math>\alpha</math> protein, a key regulator of cellular response to hypoxic conditions. Findings showing that asphyxia deaths are associated with an increase in the number of mast cell (MC)-derived tryptase enzymes in the blood suggests that HIF1-<math>\alpha</math> production may be correlated with MC activation in hypoxic conditions. This hypothesis prompted us to investigate the possible role of pulmonary MC in acute asphyxia deaths.</p> <p>Lung of 47 medico-legal autopsy cases (35 asphyxia/hypoxia deaths, 11 controls and 1 anaphylactic death) were processed by IHC analysis using anti-CD117 (c-Kit) antibody to investigate peri-airway and peri-vascular MC together with their counts and features. Results showed a significant increase in peri-vascular c-kit+ MC in some asphyxia deaths, such as hanging, strangulation and aspiration deaths. A strong activation of MC in peri-airway and peri-vascular areas was also observed in lung samples from the anaphylaxis case, which was used as a positive control.</p> <p>Our study points to the potential role of MC in hypoxia and suggests that an evaluation of MC in the lungs may be a useful parameter when forensic pathologists are required to make a differential diagnosis between acute asphyxia deaths and other kinds of death.</p>
<b>Author Comments:</b>	<p>The present study was inspired by a previous one, published on IJLM 128(1):117-125, that investigated possible markers of acute mechanical asphyxia deaths using an immunohistochemical analysis (IHC). The results obtained have encouraged us to seek other possible markers of asphyxia, which are of great importance in forensic pathology. In the present study, in which we worked also with double immunostaining merged with confocal microscopy, we try to explain the role of mastcells in acute asphyxia, assuming that recently these cells are considered to have many unexplored functions.</p> <p>We hope that the topic will be of interest for your journal, and that the paper could be</p>

	<p>the second published in IJLM of many others dealing with the problem of asphyxia deaths.</p>
<p><b>Response to Reviewers:</b></p>	<p>Dear Editor and Reviewers,  Thank you very much for your valuable comments and suggestions, which have been very useful for improving the paper.  We are pleased to submit the revised manuscript entitled "Are mast cells implicated in asphyxia?".  Below you will find the list of corrections made to the manuscript, highlighted below by "...", and in red in the text, and a rebuttal against each of the points raised by the Reviewers.  Kind regards,  Rossana Cecchi</p> <p>Reviewer #1</p> <p>1) Due to the division in several subgroups the case number is rather low for a reliable interpretation  In the original text we specified in the conclusions that : These findings highlight the potential role played by MC in acute hypoxic conditions, which deserves further investigation as a pathognomonic histological event.  In the reviewed text we added at the end of the discussion: "Although the case number for each subgroup is low", it is noteworthy that hanging deaths, "which were all complete hangings", yield "statistically" significant results as regards the number of both HIF1-<math>\alpha</math>+ pulmonary vessels and perivascular CD117+ MC, which further highlights the importance of the role played by both vessels and MC in acute asphyxia death.</p> <p>2) The study group should be described in detail:  - what kind of hanging / strangulation  Hangings were all complete, please see answer 1)</p> <p>3) information on the estimated duration of asphyxia/ischemia  In the Discussion we added: Our results confirm that even short periods "(few minutes)" of lack of oxygen in humans (acute asphyxia/hypoxia)</p> <p>4) The control group should be described in detail: the question arises, whether e.g. cardiac deaths are included, which can also be accompanied by terminal hypoxia.  In Material and methods we added: head trauma "due to gunshot or traffic accident in which the death occurred rapidly" (n=3) or natural death "without agony and signs of lung and cardiac involvement" (n=8).</p> <p>3) It lacks a detailed presentation of the results.  It is not clear what the reviewer intend with "detailed presentation". We reported all information available from the observation of the histological slides.</p> <p>4) Figure 1 is of poor quality. The different distribution of the MC cells (small vessels, medium vessels, large vessels)is not visible.  We improved the quality of figure 1</p> <p>4) In several references the term "MC" needs to be written out.  We wrote out all MCs. Sorry!</p> <p>Reviewer #2</p> <p>1) the fixation time of the lung samples in buffered formaldehyde should be added  In Histology and immunohistochemistry we added: Lung tissue samples from each case, taken from the central and subpleural areas of each lobe, were fixed in 10% neutral-buffered formalin solution "for 3 to 5 days"</p> <p>2) what means "acute"? Is it possible to conclude 1 or 2 minutes, or 5 minutes, or more minutes? It would be helpful if this question could be answered more precisely.  In the Discussion we added: Our results confirm that even short periods "(few minutes)" of lack of oxygen in humans (acute asphyxia/hypoxia)"</p>

## **Are mast cells implicated in asphyxia?**

Barbara Muciaccia, Cristina Sestili, Stefania De Grossi, Annarita Vestri, Luigi Cipolloni, Rossana Cecchi

### **Abstract**

In a previous immunohistochemical (IHC) study, we documented the reaction of lung tissue vessels to hypoxia through the immunodetection of *HIF1- $\alpha$*  protein, a key regulator of cellular response to hypoxic conditions. Findings showing that asphyxia deaths are associated with an increase in the number of mast cell (MC)-derived tryptase enzymes in the blood suggests that HIF1- $\alpha$  production may be correlated with MC activation in hypoxic conditions. This hypothesis prompted us to investigate the possible role of pulmonary MC in acute asphyxia deaths.

Lung of 47 medico-legal autopsy cases (35 asphyxia/hypoxia deaths, 11 controls and 1 anaphylactic death) were processed by IHC analysis using anti-CD117 (c-Kit) antibody to investigate peri-airway and peri-vascular MC together with their counts and features.

Results showed a significant increase in peri-vascular c-kit<sup>+</sup> MC in some asphyxia deaths, such as hanging, strangulation and aspiration deaths. A strong activation of MC in peri-airway and peri-vascular areas was also observed in lung samples from the anaphylaxis case, which was used as a positive control.

Our study points to the potential role of MC in hypoxia and suggests that an evaluation of MC in the lungs may be a useful parameter when forensic pathologists are required to make a differential diagnosis between acute asphyxia deaths and other kinds of death.

Key words: asphyxia death, mast cell, CD117, HIF1- $\alpha$ , forensic pathology, lungs

Authors followed accepted principles of ethical and professional conduct. No sources of funding were given for the study, and no informed consent has to be given.

Disclosure of potential conflict of interest is given in a separate file.

## Introduction

A previous study investigated possible markers of acute mechanical asphyxia deaths using an immunohistochemical analysis (IHC). The immunodetection of hypoxia-induced factor-1 $\alpha$  (HIF1- $\alpha$ ) protein proved to be the most reliable marker. High numbers of vessels expressing HIF1- $\alpha$  in autoptic lung samples from individuals who died of asphyxia indicate that pulmonary vessels play an important role in the reaction to O<sub>2</sub> deprivation [1]. Moreover, following evidence in the literature showing that asphyxia deaths are associated with an increase in the blood of the mast cell (MC)-derived tryptase enzyme [2], we decided to investigate the possible role of mast cells (MC) in acute asphyxia deaths and to assess whether this role is connected to vessel reaction to O<sub>2</sub> deprivation.

MC reside in several tissues, in which they are involved in innate and acquired immunity [3]. Moreover, they play a role in various physiological and pathological processes, such as tissue remodelling, angiogenesis and tumor growth [4 – 5], anaphylaxis and allergic inflammation [6-7]. Studies indicate that they are also involved in various conditions not related to hypersensitivity [8], including those associated with local hypoxia, such as asthma, rheumatic diseases, arthritis [9-10] and some types of cancer [11].

Although it is not clear how hypoxia affects MC function and activation, the literature contains reports supporting a role of MC in the development of hypoxia-induced inflammation [12-13]. Pulmonary vasoconstriction induced by hypoxia is a physiological mechanism that optimizes the imbalance between ventilation and perfusion in the lungs during acute hypoxia [14]. Hypoxia in tissues leads to a marked MC activation and to the release of proteolytic enzymes, such as serine proteases [tryptase, chymase and metalloproteases, angiogenic factors and growth factors that mediate the destruction and remodelling of tissues [15]. In animal models and in humans this happens in a plethora of physiological and pathological conditions [16], such as airway remodelling in asthma [17], myocardial hypertrophy [18], chronic liver diseases [19], chronic pancreatitis [20], and pulmonary vascular remodelling in chronic hypoxia [21].

The role of MC in the remodelling of lung vessels exposed to chronic hypoxia as well as in pulmonary hypertension has been investigated in previous experimental studies [16, 22-25]. Hypoxia produces oxidative stress [26], which plays a critical role in the pathogenesis of hypoxic pulmonary hypertension [27]. Administration of antioxidants in the early stages of exposure to hypoxia attenuates the structural remodelling of peripheral lung vessels and the development of hypoxic pulmonary hypertension [28]. A high number of MC containing collagenase is found in the artery walls of remodeled lungs [29]. These findings point to a potential correlation between the reaction of vessels and MC in the lung response to hypoxia, which may prove useful in the field of forensic pathology.

Lastly, the typical distribution of MC in areas affected by chronic hypoxia (e.g. fibrotic areas of lungs), as well as their involvement in various inflammatory reactions, indicates that MC activation is induced by an insufficient oxygen supply.

Few studies have investigated the role of MC in acute asphyxia. Edston et al. [2] found an increase in MC tryptase haematic levels in the femoral blood of subjects who died as a result of acute mechanical asphyxia, and Fineschi et al. [30] documented a similar increase in heroin-related deaths in which acute hypoxia was believed to be involved.

On the basis of these observations, we decided to investigate, by means of an immunohistochemical analysis, the presence, number and distribution of pulmonary MC in deaths due to acute asphyxia. If confirmed, the correlation between MC and acute asphyxia may be of

help to forensic pathologists when a differential diagnosis between acute asphyxia and other kinds of death is requested by the court.

The CD117 (c-Kit) is a tyrosine kinase transmembrane receptor expressed, in its full-length form, on the surface of MC, melanocytes, some hematopoietic stem cell progenitors, [31-32] and germ cells, and in its truncated form (TR-Kit), in the haploid male germ cells during spermatogenesis, in ejaculated human sperm cells [33] and by several human cancer cell types [34]. Metz [13] demonstrated the potential involvement of c-kit positive cells in idiopathic pulmonary arterial hypertension (IPAH) by promoting the accumulation and degranulation of perivascular MC in the lungs. The tyrosine kinase inhibitor (imatinib) may therefore be a good therapeutic target in pathological conditions characterized by pulmonary hypertension (chronic obstructive pulmonary disease, idiopathic pulmonary fibrosis, idiopathic pulmonary arterial hypertension) [35-36].

## Materials and methods

### *Cases*

Forty-seven medico-legal autopsy cases examined at the Department of Anatomical, Histological, Legal Medical and Orthopaedic Sciences of the Sapienza University of Rome, Italy, between 24 and 72 hours post-mortem or, in cases of drowning, between 24 and 72 hours after the discovery of the corpse, were examined. Primary pulmonary diseases were excluded by histological investigations. Causes of death were based on routine macromorphological, histological and toxicological findings. The cases were divided into two groups as follows: group 1 which included cases who had died of asphyxia/hypoxia (AHC) [total n=35: drowning (n=11), hanging (n=5), strangulation (n=4), smothering (n=3), aspiration (n=6), carbon monoxide (CO) intoxication (n=3), pneumonia (n=3)], and group 2, which served as a control group (CC) and contained the remaining 11 cases who had died of either **head trauma due to gunshot or traffic accident in which the death occurred rapidly (n=3) or natural death without agony and signs of lung and cardiac involvement (n=8)**. One anaphylactic death was used as a positive control case. The cases of pneumonia were included in the AHC group on the assumption that there could be a reaction to hypoxia in the areas presenting parenchymal exudates.

### *Histology and immunohistochemistry*

Lung tissue samples from each case, taken from the central and subpleural areas of each lobe, were fixed in 10% neutral-buffered formalin solution **for 3 to 5 days**, dehydrated by alcohol and paraffin-embedded; 5µm-thick paraffin-embedded sections were cut from each lung specimen, mounted on polylysine-coated slides and processed for morphological evaluation using hematoxylin-eosin (HE) staining and for immunohistochemistry analysis (IHC) using the polyclonal rabbit anti-human CD117 c-Kit (1:400 by Dako) and or human anti-hypoxia-induced factor 1α (HIF1-α:400 clone ESEE122 by Abnova), as previously described [37, 1]. Briefly, de-waxed and re-hydrated sections from all lung samples were subjected to the antigen retrieval procedure using Tris-EDTA citrate buffer pH 7.8 for 15 minutes in microwave and, after quenching endogenous peroxidase and blocking non-specific binding sites, incubated with the primary antibody for 1 hour at room temperature (RT). After washing, sections were processed using the avidin-biotin peroxidase complex (ABC) procedure, according to the manufacturer's instructions (UltraTek HRP Anti-Polyvalent kit, ScyTek Laboratories). Negative control experiments were performed using

rabbit IgG isotype or by omitting the primary antibodies. Peroxidase activity was revealed by using 3,3-diaminobenzidine tetrahydrochloride (Roche, Milan, Italy), after which nuclei were quickly counterstained with Mayer's hematoxylin (Sigma-Aldrich, St. Louis, MO, USA). Slides were permanently mounted in DPX Mountant for histology (BDH, Milan, Italy) and observed by light microscopy (Zeiss, Axioskop 2 Plus) at low (10-20x) and higher (40x) magnification.

#### *Analysis of immunohistochemical staining*

Five random microscopic fields of 1.76 mm<sup>2</sup> for each immunostained tissue section were assessed by an observer, using ×10 and ×40 original magnification. Total MC count was performed by considering the position of each MC, whether peri-bronchial, peri-alveolar and peri-vascular. Peri-vascular MC were counted by dividing vessels in pre-capillary arterioles/post-capillary venules (defined as small-caliber vessels), arterioles/venules (defined as medium-caliber vessels) and arteries/veins (defined as large-caliber vessels). Fibrotic areas were not considered because MCs are abundant in fibrotic lungs in both animal models of fibrosis and in diseased humans [38-42]. The hematoxylin/eosin-stained sections for each case were also examined.

#### *Immunofluorescence analysis*

For the double immunofluorescence analysis at laser scanning confocal microscopy, 5µ-thick sections from two representative lung tissue samples (one from a hanging and one from smothering case) were de-waxed twice by toluene immersion, hydrated through a descending alcohol scale and treated in microwave for antigen retrieval using citrate-EDTA buffer pH 7.8, as described in the previous paragraph. Briefly, after cooling at room temperature (RT), sections were rinsed in 1x PBS buffer, incubated in 1M glycine for 30 min and permeabilized for 30 min using 1x PBS/1% BSA /0.1% Triton X-100 solution, as previously reported [43]. In order to perform non-specific binding blocking of primary antibodies, sections were then pre-incubated in PBS containing 5% pre-immune donkey and goat serum, 1% BSA, 0.1% Triton X-100 at room temperature for 1 hour under constant shaking. Sections were then incubated at RT for 2 hours with the two following primary antibodies: 1:300 diluted polyclonal rabbit-anti human CD117 (by Dako) and 1:400 diluted mouse anti-human hypoxia-induced factor 1-α (HIF-α) monoclonal antibody (1:1000 clone ESEE122 by Abnova). After washing, sections were incubated with donkey anti-mouse Cy3-conjugated (Jackson Immuno research Laboratories, Newmarket, UK) and goat anti-rabbit AlexaFluor 488-conjugated (Jackson Laboratories) secondary antibodies. Nuclei were stained with 1:5000 diluted TOTO-3 dye (Molecular Probes T-3604, Invitrogen) and slides mounted using Vectashield mounting medium (Vector). Parallel immunostaining reactions were performed using two lung samples from the CC group (1 head trauma and 1 natural death); negative control experiments were performed by omitting primary antibodies. Specimens were observed under a Leica laser scanning microscope TCS SP2 and images were acquired with Leica Confocal Software (Leica, Milano, Italy).

#### *Statistical analysis*

Data were summarized by mean, median, standard deviation. We used Mann Whitney test to compare the two groups. The p values are 2-sided; a p value <0.05 was considered statistically significant. All computations were carried out using STATA v.12.

## Results

### *Statistical analysis*

A Mann Whitney test performed on the whole group (regardless of the cause of death, but divided in cases or controls) (Table 1) was statistically significant for the MC of peri-medium-caliber vessels.

Mean values of peri-vasal c-kit<sup>+</sup> MC for each cause of death reveal a statistically significant increase in the AHC group, particularly in hanging, strangulation and aspiration (Table 2).

### *Morphological analysis*

Local atelectasis and/or local emphysema and alveolar capillary congestion were found in the lung samples of both controls and asphyxia deaths. Varying degrees of intra-alveolar hemorrhage associated with intralveolar edema and intra- and interstitial alveolar edema were detected in the asphyxia, CO intoxication and pneumonia cases (data not shown).

### *Immunohistochemical analysis*

In all cases, c-kit<sup>+</sup> MC were typically present in the peri-bronchial and fibrotic areas. In the anaphylactic case, used as positive control, c-kit<sup>+</sup> MC were, as expected, particularly abundant in peri-vascular and peri-bronchial regions, thus attesting to the good specificity and sensitivity of the IHC reaction.

The statistical analyses comparing the AHC and CC groups revealed a higher number of c-kit<sup>+</sup> MC in peri-vascular, subpleural and peri-alveolar regions in the AHC than in the CC group. Moreover, the number of perivasal c-kit<sup>+</sup> MC was significantly higher in hanging, aspiration and strangulation cases than in the CC group (table 2) (Fig. 1). Lastly, the number of peri-bronchial c-kit<sup>+</sup> MC was significantly higher in aspiration and pneumonia cases than in other deaths.

### *Immunofluorescence analysis*

Double immunofluorescence analysis for the c-Kit receptor and HIF1- $\alpha$  factor performed in two representative lung samples (i.e. one from a hanging and one from a smothering death case) revealed that pulmonary MC, identified by their positivity for the c-Kit transmembrane receptor, always displayed a strong fluorescence for HIF1- $\alpha$  protein. In most of the MC, the two immunofluorescence colours co-localized well, as shown in Figures 2 and 3. As expected, double positive MC were observed in peri-vascular and peri-airway areas, which were often located near blood vessels displaying HIF1- $\alpha$  positive endothelial cells or adjacent to other HIF1- $\alpha$  positive cell types. This finding demonstrated the presence of a severe and strongly widespread hypoxic/acute-asphyxia stimulus. The MC from the lung samples of two control cases in the CC group did not test positive for HIF1- $\alpha$  (fig. 4), while specific signals were never detected in negative control reactions, which were performed by omitting primary antibodies.



## DISCUSSION

The mechanisms that take place in the lungs following an asphyxia stimulus are of great importance for differential diagnostic purposes in forensic pathology. Although alveolar macrophages were the protagonists of a long-lasting dispute concerning protracted asphyxiation [44-48], MC have never captured the interest of forensic doctors for reasons other than their obvious role in anaphylaxis and their presumed role in drug-related deaths. The growing body of knowledge on the role that MC play in numerous clinical conditions (16-21), including pulmonary pathologies and even asphyxiation, has been attracting an increasing amount of interest.

However, evidence is still lacking regarding the role played by MC in acute hypoxic pulmonary vasoconstriction. Some investigators have found a higher number of MC in the lungs of chronically hypoxic rats. Kay et al. [24] reported that MC do not differ morphologically in chronic hypertension, but that their distribution is altered if compared with healthy lungs. Tucker et al. [25] determined the influence of chronic hypoxia on MC in six species. They described significant changes in the density of MC in lungs of chronically hypoxic pigs, rats and sheep. Moreover, Nadziejko et al. [22] demonstrated the effects of alveolar hypoxia on perivascular and peri-airway MC populations in cats. After exposure to localized alveolar hypoxia, they observed a 12% decrease in the granule content of peri-vascular MC, which was due to alveolar hypoxia rather than to systemic hypoxemia. Indeed, airway MC, which are frequently located adjacent to either an airway lumen or alveolar space, did not display any response to alveolar hypoxia.

Our results confirm that even short periods (few minutes) of lack of oxygen in humans (acute asphyxia/hypoxia) result in large quantities of MC being rapidly recruited in the lungs; moreover, upon being recruited, there are not distributed evenly throughout the tissue, with a higher number of MC being observed in peri-vascular areas than in control cases. The increase in the number of perivascular MC following acute asphyxia/hypoxia may be triggered by a hypoxic stimulus that originates from the vessel walls rather than from the blood.

Increases in the number of peri-airway MC were only found in deaths due to anaphylaxis and aspiration. It may be argued that contact with the alveolar and bronchial walls of antigens in the former cases and of foreign material in the latter act as a stimulus that draws MC to this area.

In addition, chronic hypoxia increases the production of proteolytic enzymes in MC, enabling them to split collagen more easily and thereby facilitating the growth of vascular smooth muscle cells. Administration of a serine protease inhibitor or MC degranulation blockers, at the onset of exposure to chronic hypoxia, attenuates the development of hypoxic pulmonary hypertension in experimental animals. Therefore, MC degranulation as well as the release and activation of soluble mediators involved in tissue remodelling processes appear to be fundamental in the early phase of hypoxia [16].

Resident cells within the vessel wall were once considered responsible for the increase in the thickness of the wall. This role has, however, more recently been ascribed to a population of bone marrow cells that differentiate into endothelial cells and c-kit<sup>+</sup> smooth muscle cells, which are likely to be recruited by the hypoxia-induced mitogenic factor (HIMF/FIZZ1/RELM $\alpha$ ), a chemotactic agent for bone marrow cells [49-52].

Marrow progenitor cells (c-kit<sup>+</sup>, tryptase<sup>-</sup>) and MC (c-kit<sup>+</sup>, tryptase<sup>+</sup>) are found in the wall of the vasa vasorum of the arteries when idiopathic pulmonary arterial hypertension is present [52]. These findings are in keeping with the results of our study, which suggest that the vascular system responds to the activation and recruitment of MC following hypoxia by increasing the number of peri-vascular MC.

What remains unclear is how MC reach the pulmonary vessels so rapidly in acute asphyxia/hypoxia? It has been reported that the marked increase in lung MC progenitors (MCp) is due above all to recruitment, and that diapedesis can only occur when  $\alpha 4\beta 7$  integrins are expressed on MCp and interact with endothelial VCAM-1 [53]. In this regard, the migration of MCp appears to be mediated by adhesion molecules, and in particular by  $\beta 7$  integrin present on MC and MAdCAM-1 and VCAM-1 expressed by the endothelium [54]. The recruitment of MCp in the lungs is exclusively dependent on VCAM-1 binding or function [55].

In mice exposed to hypoxia, alveolar macrophages secrete MCP-1/CCL2 (monocyte chemoattractant protein-1/Chemokine CC motif ligand 2), which activates MC and triggers an inflammatory response that promotes microvascular endothelial migration of circulating leukocytes [56]. MCP-1/CCL2 is also involved in the recruitment of bone marrow progenitors, which adhere to the endothelium by binding to the  $\alpha 4\beta 7$ -integrin, which is in turn expressed on the surface of the MC progenitors (MCp)[55], i.e. on the VCAM-1 adhesion molecule, whose expression in the endothelium is promoted by the interaction between CCL2 and CCR2 [54] (Fig. 5). After one day of exposure to an aerosolized allergen, the number of lung MC in CCR2<sup>-/-</sup> mice is significantly lower than in CCR2<sup>+/+</sup> mice [55].

A key regulator to hypoxia response in MC is believed to be HIF-1 $\alpha$ , whose expression in human MC is increased by hypoxia; this observation lends further support to the hypothesis of a molecular network between HIF1- $\alpha$  and MC [57]. It is also noteworthy that a statistically significant association between HIF1- $\alpha$  expression, tryptase expression and the presence of brain edema has been demonstrated in brain tissue in hypoxic conditions [58].

Histamine released by MC appears to stimulate HIF1- $\alpha$ , which in turn triggers neo-synthesis in MC of many mediators of remodelling processes and neo-angiogenesis [59]. Lastly, increased expression of HIF1- $\alpha$  activates human MC in hypoxic conditions [60]. The results of the double immunofluorescence analysis in our study further suggest that there is a correlation between HIF1- $\alpha$  and MC. Indeed, two representative lung samples from the AHC group showed that the peri-vascular c-kit<sup>+</sup> MC were also HIF1- $\alpha$  positive at confocal microscopy.

After showing that HIF1- $\alpha$  is expressed on pulmonary vessels in subjects who died of asphyxia in a previous paper [1], in the present study we show that c-kit<sup>+</sup> MC are in some cases also located around HIF1- $\alpha$ <sup>+</sup> vessels.

It may be argued that the secretion of alveolar macrophage MCP-1/CCL2 following acute asphyxia attracts MC progenitors that bind to the endothelium of pulmonary vessels. In hypoxic conditions, the HIF1- $\alpha$  factor increases in both MC and endothelial cells. These mechanisms may explain both the quantitative increase in MC that emerges from the present paper as well as the increase in HIF1- $\alpha$  expression observed in pulmonary vessels of varying calibre reported in our previous paper [1].

Although the case number for each subgroup is low, It is noteworthy that hanging deaths, which were all complete hangings, yield statistically significant results as regards the number of both HIF1- $\alpha$  pulmonary vessels and perivascular CD117+ MC, which further highlights the importance of the role played by both vessels and MC in acute asphyxia death.

## CONCLUSION

Hypoxia in animal models induces the mobilization and recruitment of c-kit<sup>+</sup> cells in remodelled pulmonary arteries. In the present study, we observed that the number of c-kit<sup>+</sup> MC was higher in subjects who had died of asphyxia than in controls, particularly in the proximity of vessels in pulmonary samples. Our results suggest asphyxia is followed by an immediate, large-scale recruitment of perivascular MC in the lungs that is mediated by HIF1- $\alpha$  activation, as well as by other specific chemotactic soluble macropaghe-derived molecules. These findings highlight the potential role played by MC in acute hypoxic conditions, which deserves further investigation as a pathognomonic histological event that may prove useful in the differential diagnosis of acute asphyxia deaths.

## BIBLIOGRAPHY

1. Cecchi R, Sestili, Prosperini G., Cecchetto G., Vicini E, Viel G, Muciaccia B (2014) Markers of mechanical asphyxia: immunohistochemical study on autoptic lung tissues. *Int J Legal Med* 128(1):117-125
2. Edston E, Eriksson O, van Hage M (2007) Mast cell tryptase in postmortem serum-reference values and confounders. *Int J Legal Med* 121(4):275-80
3. Mekori YA, Metcalfe DD (2000) Mast-cells in innate immunity. *Immunol Rev* 173:131-40
4. Norrby K, Jakobsson A, Sörbo J (1986) Mast-cell-mediated angiogenesis: a novel experimental model using the rat mesentery. *Virchows Arch B Cell Pathol Incl Mol Pathol* 52(3):195-206
5. Maltby S, Khazaie K, McNagny KM (2009) Mast-cells in Tumor Growth: Angiogenesis, Tissue Remodeling and Immune-modulation. *Biochim Biophys Acta* 1796(1): 19–26
6. Taylor ML, Metcalfe DD (2001) Mast-cells in allergy and host defense. *Allergy Asthma Proc.* 22(3):115-9
7. Koshino T, Arai Y, Miyamoto Y, Sano Y, Itami M, Teshima S, Hirai K, Takaishi T, Ito K, Morita Y (1996) Airway basophil and mast cell density in patients with bronchial asthma: relationship to bronchial hyperresponsiveness. *J Asthma* 33(2):89-95
8. Anand P, Singh B, Jaggi AS, Singh N (2012) Mast-cells: an expanding pathophysiological role from allergy to other disorders. *Naunyn-Schmiedeberg's Arch Pharmacol* 385:657–670

9. Mican JM, Metcalfe DD (1990) Arthritis and mast cell activation. *J Allergy Clin Immunol* 86: 677-683
10. Nigrovic PA, Lee DM (2005) Mast-cells in inflammatory arthritis. *Arthritis Res Ther* 7(1):1-11
11. Yano H, Kinuta M, Tateishi H, Nakano Y, Matsui S, Monden T, Okamura J, Sakai M, Okamoto S (1999) Mast cell infiltration around gastric cancer cells correlates with tumor angiogenesis and metastasis. *Gastric Cancer*. 2(1):26-32
12. Steiner DR, Gonzalez NC, Wood JG (2003) Mast-cells mediate the microvascular inflammatory response to systemic hypoxia. *J Appl Physiol* 94(1):325-34
13. Metz M, Grimaldeston MA, Nakae S, Piliponsky AM, Tsai M, Galli SJ (2007) Mast-cells in the promotion and limitation of chronic inflammation. *Immunol Rev* 217:304-28
14. Herget J, Ježek V (1989) Pulmonary hypertension in chronic lung disease. In: *Pulmonary Hypertension Problems and Controversies*. Denolin H, Wagenvoort Ca (eds) Elsevier Publ Co, Amsterdam, pp 142-62
15. Norrby K (2002) Mast-cells and angiogenesis. *APMIS* 110(5):355-71
16. Maxová H, Herget J, Vízek M (2012) Lung mast-cells and hypoxic pulmonary hypertension. *Physiol Res Mar* 61(1):1-11
17. Karakiulakis G, Papakonstantinou E, Aletras AJ, Tamm M, Roth M (2007) Cell type-specific effect of hypoxia and platelet-derived growth factor-BB on extracellular matrix turnover and its consequences for lung remodeling. *J Biol Chem* 282: 908-15
18. Levick SP, Melendez GC, Plante E, Mclarty JL, Brower GL, Janicki JS (2011) Cardiac mast-cells: the centrepiece in adverse myocardial remodelling. *Cardiovasc Res* 89(1) : 12-9
19. Franceschini B, Ceva-Grimaldi G, Russo C, Dioguardi N, Grizzi F (2006) The complex functions of MASTCELLS in chronic human liver diseases. *Dig Dis Sci* 51(12): 2248-56
20. Esposito I, Friess H, Kappeler A, Shrikhande S, Kleeff J, Ramesh H, Zimmermann A, Buchler MW (2001) Mast cell distribution and activation in chronic pancreatitis. *Hum Pathol* 32(11): 1174-83
21. Banasova A, Maxova H, Hampel V, Vizek M, Povysilova v, Novotna j, Vajnerova O, Hnilickova O, Herget J (2008) Prevention of mast cell degranulation by disodium cromoglycate attenuates the development of hypoxic pulmonary hypertension in rats exposed to chronic hypoxia. *Respiration* 76(1): 102-7
22. Nadziejko CE, Loud AV, Kikkawa Y (1989) Effect of alveolar hypoxia on pulmonary mast-cells in vivo. *Am Rev Respir Dis* 140(3):743-8

23. Migally NB, Tucker A, Greenlees K, Wright M, Zambarnard J (1983) Density and ultrastructure of mast-cells in lung vessels of aging rats exposed to and recovering from chronic hypoxia. *Cell Tissue Res* 232(3):601-8
24. Kay JM, Waymire JC, Grover RF (1974) Lung mast cell hyperplasia and pulmonary histamine-forming capacity in hypoxic rats. *Am J Physiol* 226(1): 178-84
25. Tucker A, Mc Murtry I, Alexander AF, Reeves JT, Grover RF (1977) Lung mast cell density and distribution in chronically hypoxic animals. *J Appl Physiol* 42(2) : 174-78
26. Nakanishi I, Tajima F, Nakamura A, Yagura SY, Ookawara T, Yamashita H, Suzuki K, Taniguchi N, Ohno H (1995) Effects of hypobaric hypoxia on antioxidant enzymes in rats. *J Physiol* 489(Pt 3): 869- 76
27. Hampl V, Herget J (2000) Role of nitric oxide in the pathogenesis of chronic pulmonary hypertension. *Physiol Rev* 80(4): 1337-72
28. Lachmanova V, Hnilickova O, Povysilova V, Hampl V, Herget J (2005) N-acetylcysteine inhibits hypoxic pulmonary hypertension most effectively in the initial phase of chronic hypoxia. *Life Sci* 77(2) : 175-82
29. Vajner L, Vytasek R, Lachmanova V, Uhlik J, Konradova V, Novotna J, Hampl V, Herget J (2006) Acute and chronic hypoxia as well as 7-day recovery from chronic hypoxia affects the distribution of pulmonary mast-cells and their MMP-13 expression in rats. *Int J Exp Pathol* 87(5) : 383-91
30. Fineschi V, Cecchi R, Centini F, Pagliacci Reattelli L, Turillazzi E (2001) Immunohistochemical quantification of pulmonary mast cell and post mortem blood dosage of tryptase and eosinophil cationic protein in 48 heroin- related deaths. *Forensic Sci Int* 120 :189-194
31. Arber DA, Tamayo R, Weiss LM (1998) Paraffin section detection of the c-kit gene product (CD117) in human tissues: value in the diagnosis of mast cell disorders. *Hum Pathol* 29(5):498-504
32. Fukuda T, Kamishima T, Tsuura Y, Suzuki T, Kakihara T, Naito M, Kishi K, Matsumoto K, Shibata A, Seito T (1995) Expression of the c-kit gene product in normal and neoplastic mast-cells but not in neoplastic basophil/mast cell precursors from chronic myelogenous leukaemia. *J Pathol* 177(2):139-46
33. Muciaccia B, Sette C, Paronetto MP, Barchi M, Pensini S, D'Agostino A, Gandini L, Geremia R, Stefanini M, Rossi P (2010) Expression of a truncated form of KIT tyrosine kinase in human spermatozoa correlates with sperm DNA integrity. *Hum Reprod* 25:2188 -2202
34. Lennartsson J, Rönstrand L (2012) Stem cell factor receptor/c-Kit: from basic science to clinical implications. *Physiol Rev* 92(4):1619-49
35. Gambaryan N, Perros F, Montani D, Cohen-Kaminsky S, Mazmanian GM, Humbert M (2010) Imatinib inhibits bone marrow-derived c-kit+ cell mobilisation in hypoxic pulmonary hypertension. *Eur Respir J* 36(5):1209-11

36. Gambaryan N, Perros F, Montani D, Cohen-Kaminsky S, Mazmanian M, Renaud JF, Simonneau G, Lombet A, Humbert M (2011) Targeting of c-kit<sup>+</sup> haematopoietic progenitor cells prevents hypoxic pulmonary hypertension. *Eur Respir J* 37(6):1392-9
37. Ferranti F, Muciaccia B, Ricci G, Dovere L, Canipari R, Magliocca F, Stefanini M, Catizone A, Vicini E (2012) Glial cell line-derived neurotrophic factor promotes invasive behaviour in testicular seminoma cells. *Int J Androl* 35: 758-68
38. Hunt LW, Colby TV, Weiler DA, Sur S, Butterfield JH (1992) Immunofluorescent staining for MASTCELLS in idiopathic pulmonary fibrosis: quantification and evidence for extracellular release of mast cell tryptase. *Mayo Clin Proc* 67(10):941-8
39. Hawkins RA, Claman HN, Clark RA, Steigerwald JC (1985) Increased dermal mast cell populations in progressive systemic sclerosis: a link in chronic fibrosis. *Ann Intern Med* 102(2):182-6
40. Cha SI, Chang CS, Kim EK, Lee JW, Matthay MA, Golden JA, Elicker BM, Jones K, Collard HR, Wolters PJ (2012) Lung mast cell density defines a subpopulation of patients with idiopathic pulmonary fibrosis. *Histopathology* 61: 98-106
41. Van der Veer WM, Bloemen MC, Ulrich MM, Molema G, Van Zuijlen PP, Middelkoop E, Niessen FB (2009) Potential cellular and molecular causes of hypertrophic scar formation. *Burns* 35: 15-29
42. Inoue Y, King TE Jr, Tinkle SS, Dockstader K, Newman LS (1996) Human mast cell basic fibroblast growth factor in pulmonary fibrotic disorders. *Am J Pathol* 149: 2037-54
43. Corallini S, Fera S, Grisanti L, Falciatori I, Muciaccia B, Stefanini M, Vicini E (2006) Expression of the adaptor protein m-Numb in mouse male germ cells. *Reproduction* 132: 887-97
44. Du Chesne A, Cecchi R, Püschel K, Brinkmann B (1996) Macrophage subtype patterns in protracted asphyxiation. *Int J Legal Med* 109, 163-166
45. Betz P, Nerlich A, Penning R, Eisenmenger W (1993) Alveolar macrophages and the diagnosis of drowning. *Forensic Sc Int* 63: 217-24
46. Betz P, Beier G, Eisenmenger X W (1994) Pulmonary giant cells and traumatic asphyxia. *Int J Legal Med* 106: 258-61
47. Vacchiano G, D'Armiento F, Torino R (2001) Is the appearance of macrophages in pulmonary tissue related to time of asphyxia? *Forensic Sci Int* 115: 9-14
48. Vacchiano G (2002) Letter to the Editor. Role of pulmonary macrophages and giant cells in fatal asphyxia. *Forensic Sci Int* 127: 245

49. Wilcox JN, Okamoto EI, Nakahara KI, Vinten-Johansen J (2001) Perivascular responses after angioplasty which may contribute to postangioplasty restenosis: a role for circulating myofibroblast precursors? *Ann NY Acad Sci* 947: 68–90 discussion 90-2
50. Reyes M, Dudek A, Jahagirdar B, Koodie L, Marker PH, Verfaillie CM (2002) Origin of endothelial progenitors in human postnatal bone marrow. *J Clin Invest* 109(3) : 337–46
51. Angelini DJ, SU Q, Kolosova IA, Fan C, Skinner JT, Yamaji-Kegan K, Collector M, Sharkis SJ, Johns RA (2010) Hypoxia-Induced Mitogenic Factor (HIMF/FIZZ1/RELMa) recruits Bone Marrow-Derived Cells to the murine pulmonary vasculature *PLoS ONE* 5(6): e11251
52. Montani D, Perros F, Gambaryan N, Girerd B, Dorfmueller P, Price LC, Huertas A, Hammad H, Lambrecht B, Simonneau G, Launay JM, Cohen-Kaminsky S, Humbert M (2011) C-kit-positive cells accumulate in remodeled vessels of idiopathic pulmonary arterial hypertension. *Am J Respir Crit Med* 184(1):116-23
53. Dahlin J.S., Hallgren J. (2015) Mast cell progenitors: Origin, development and migration to tissue. *Mol Immunol.* 63: 9-17
54. Hallgren J, Gurish MF (2011) Mast cell progenitor trafficking and maturation. *Adv Exp Med Biol* 716: 14–28
55. Hallgren J, Jones TG, Abonia JP, Xing W, Humbles A, Austen KF, Gurish MF (2007) Pulmonary CXCR2 regulates VCAM-1 and antigen-induced recruitment of mast cell progenitors. *Proc Natl Acad Sci U S A* 104(51):20478-83
56. Chao J, Donham P, Van Rooijen N, Wood JG, Gonzalez NC (2011) Monocyte chemoattractant protein-1 released from alveolar macrophages mediates the systemic inflammation of acute alveolar hypoxia. *Am J Respir Cell Mol Biol* 45(1):53-61
57. Walczak-Drzewiecka A, Ratajewski M, Wagner W, Dastyk J (2008) HIF-1 $\alpha$  is up-regulated in activated mast-cells by a process that involves calcineurin and NFAT. *J Immunol* 181(3):1665-72
58. Reszec J, Hermanowicz A, Rutkowski R, Bernaczyk P, Mariak Z, Chyczewski L (2013) Evaluation of mast cells and hypoxia inducible factor-1 expression in meningiomas of various grades in correlation with peritumoral brain edema. *J Neurooncol* 115(1):119-25
59. Jeong HJ, Oh HA, Nam SY, Han NR, Kim YS, Kim JH, Lee SJ, Kim MH, Moon PD, Kim HM, Oh HA (2013) The critical role of mast cell-derived hypoxia-inducible factor-1 $\alpha$  in human and mice melanoma growth. *Int J Cancer* 132(11): 2492- 501
60. Gulliksson M, Carvalho RF, Ulleras E, Nilsson G: (2010) Mast cell survival and mediator secretion in response to hypoxia. *PLoS One* 5: e12360

Fig. 1 Respect to anaphylactic death, were c-kit<sup>+</sup> MC were abundant in peri-vascular and peri-bronchial regions (1A), in hanging (1B) and aspiration (1C) the number of perivascular c-kit<sup>+</sup> MC was significantly higher than in the CC group (CD 117, 20 x)

Fig. 2. Double immunofluorescence analysis for the c-Kit receptor and HIF1- $\alpha$  factor, merged with confocal microscopy, performed in a representative lung sample of a smothering death and 2B hanging death). Pulmonary c-kit + MC (green) always display a strong fluorescence for HIF1- $\alpha$  protein (red). Double positive MC (yellow) are observed in peri-vascular and peri-airway areas, located near blood vessels displaying HIF1- $\alpha$  positive endothelial cells or adjacent to other HIF1- $\alpha$  positive cell types.

Fig. 3. As in figure 2, a representative lung sample of a hanging death shows double positive MC (yellow).

Fig. 4. In a control case (cardiac death) a c-kit<sup>+</sup> MC (green) does not express HIF1- $\alpha$ . Lung parenchyma does not express HIF1- $\alpha$ .

Fig. 5. Hypothesis for the rapid increase of MC in lungs after acute hypoxia stimulus. The secretion of alveolar macrophage MCP-1/CCL2 following acute asphyxia activates MC, and attracts MC progenitors that bind through  $\alpha 4\beta 7$ -integrin to VCAM-1+ endothelium of pulmonary vessels.

Table 1: Mann-Whitney Test ( \* = statistically significant value) performed on both cases and control groups.

Table 2: Mean values of peri-vascular c-kit<sup>+</sup> MC for each cause of death using Mann-Whitney test (NS = not statistically significant). Mean values of peri-vascular c-kit<sup>+</sup> MC for each cause of death reveal a statistically significant increase in the AHC group, particularly in hanging, CO intoxication and aspiration.



Figure 1

[Click here to download Figure: Figure 1.jpg](#)

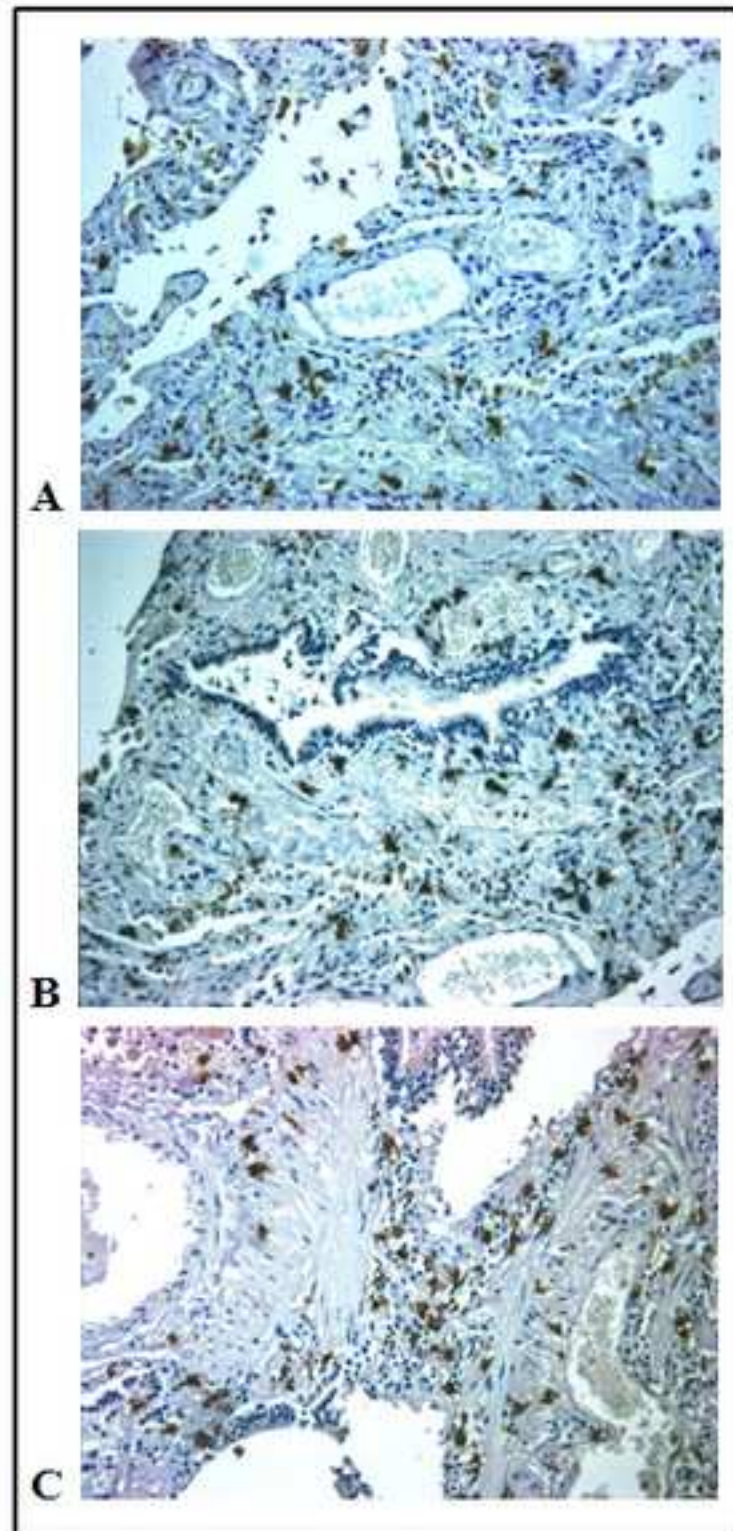


Figure 2

[Click here to download Figure: Figure 2.tif](#)

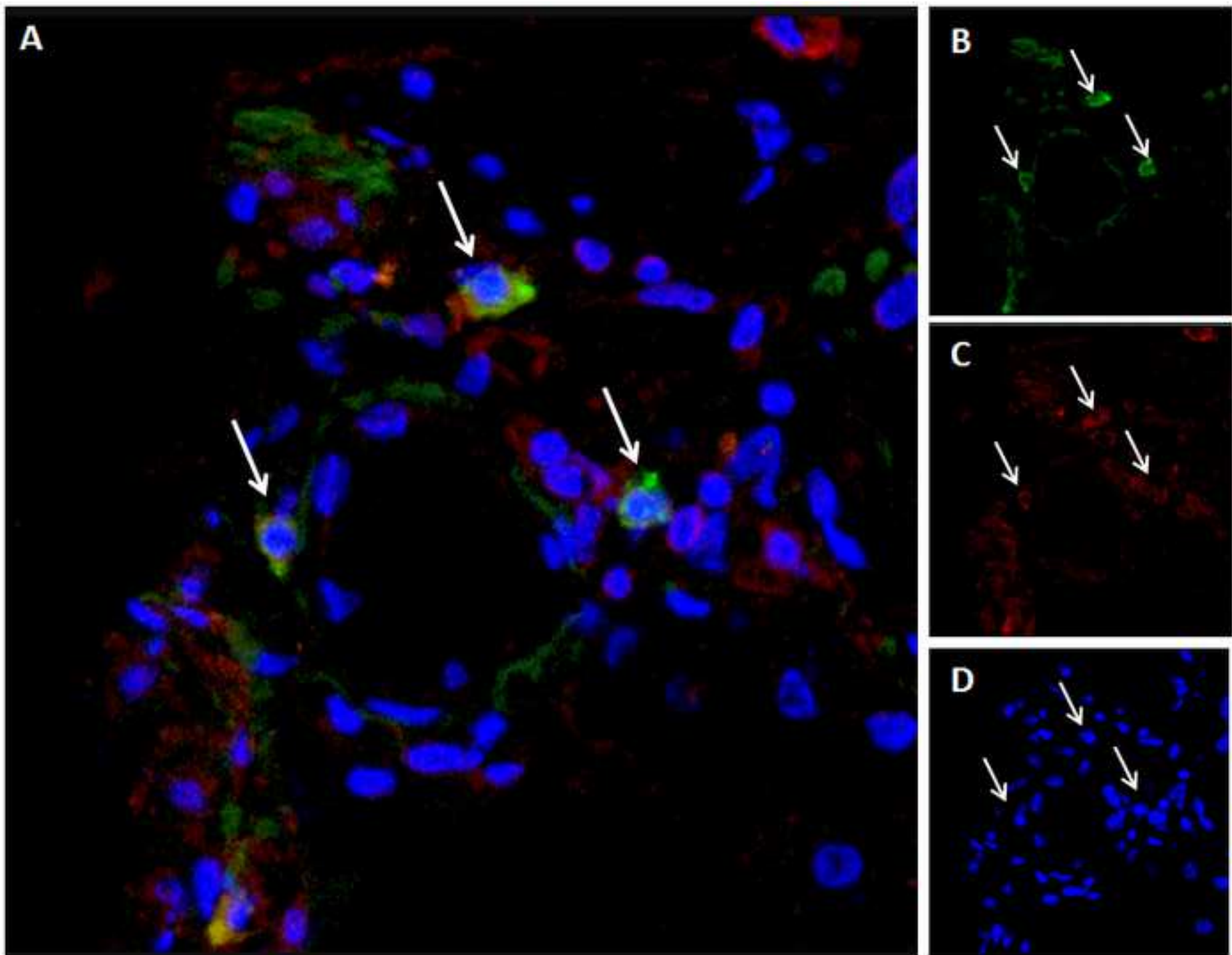




Figure 3  
[Click here to download Figure: Fig 3.tif](#)

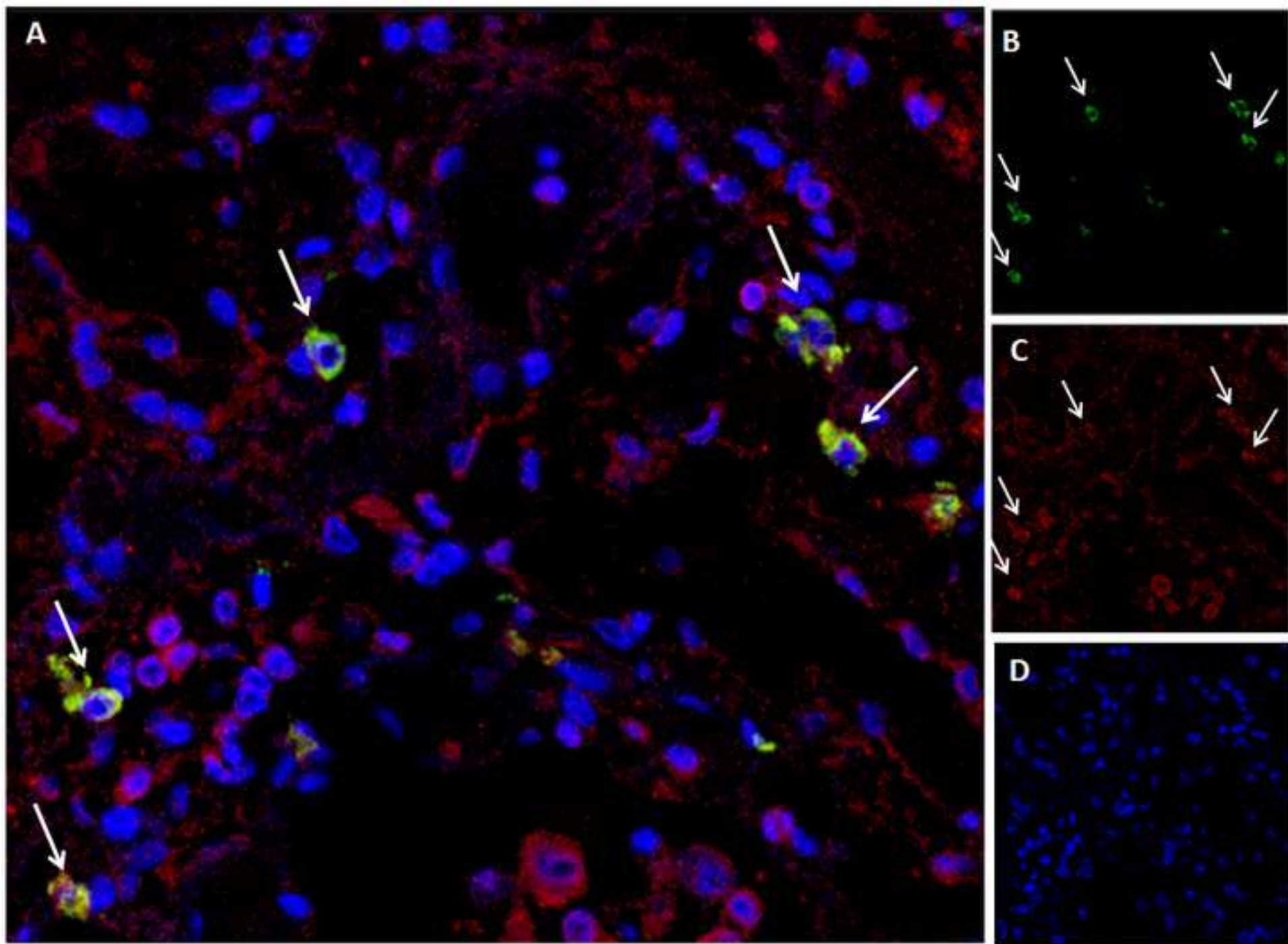


Figure 4  
[Click here to download Figure: Fig 4.tif](#)

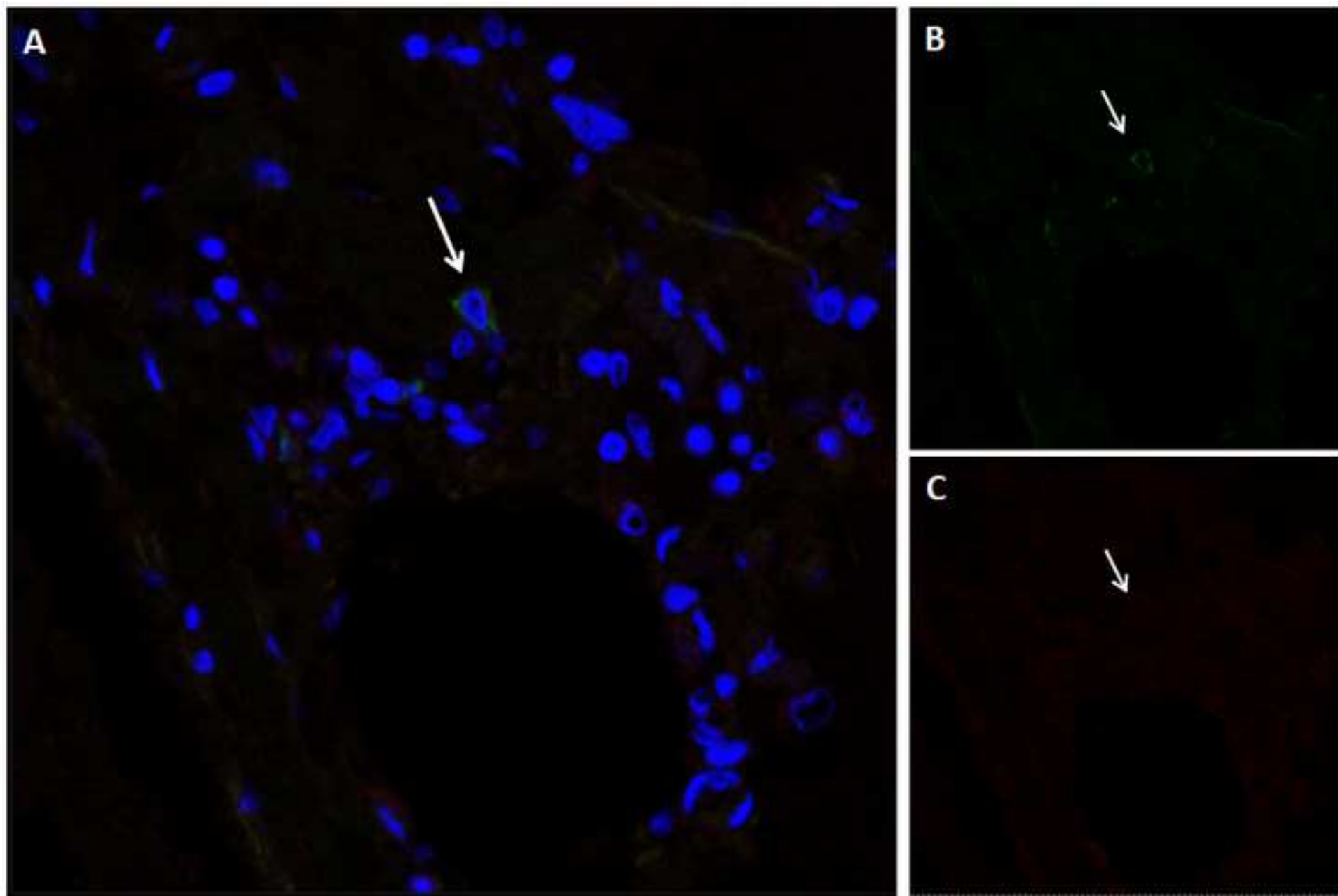


Figure 5

[Click here to download Figure: Figure 5.jpg](#)

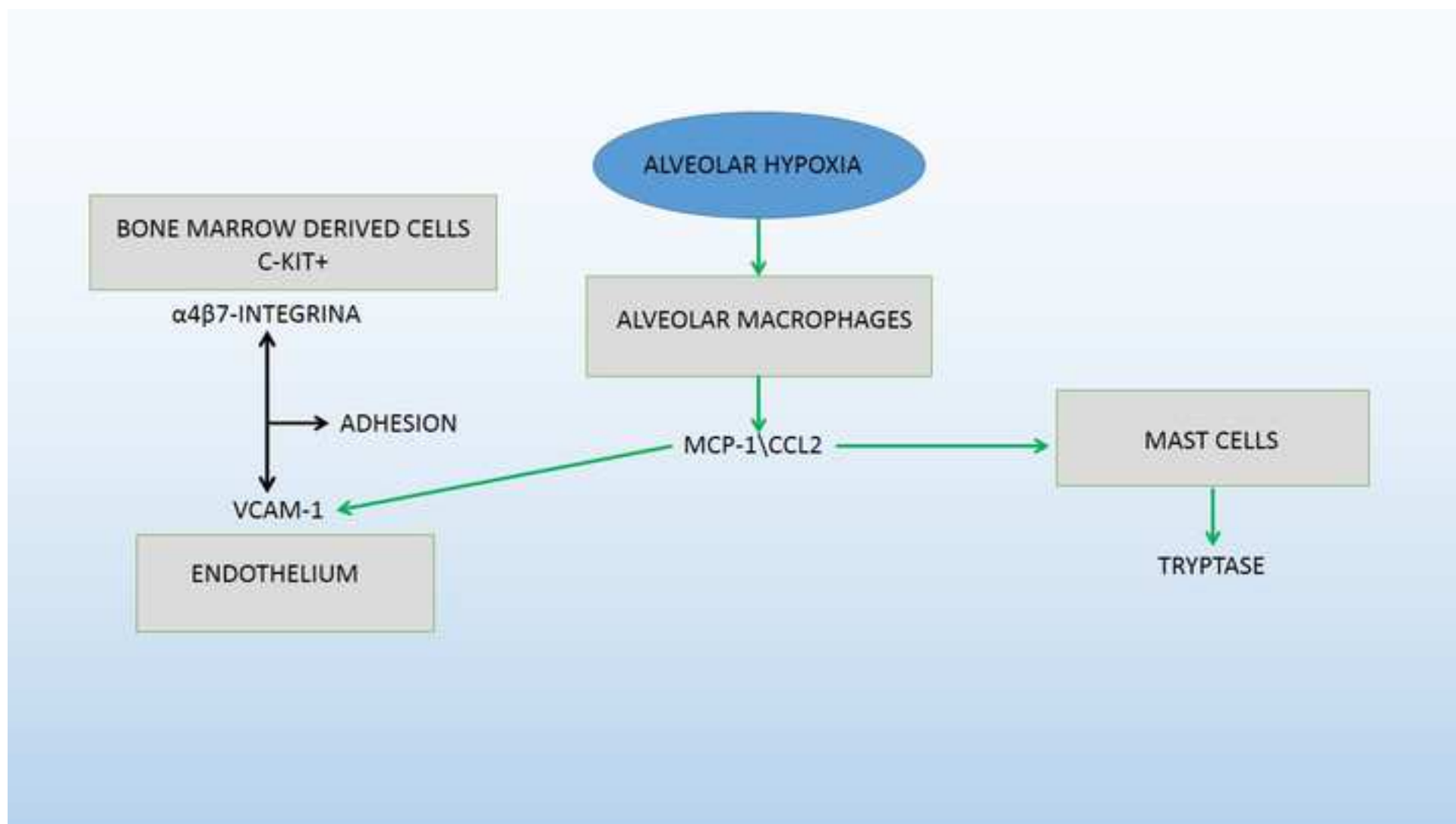


Table 1

	<b>Cases: median value</b>	<b>Controls: median value</b>	<b>P value</b>
<b>Peri-small-caliber vessel MC</b>	7	5	0.483
<b>Peri-medium-caliber vessel MC</b>	2	0	0.016*
<b>Peri-large-caliber vessel MC</b>	0	0	0.240
<b>Total peri-vessel MC</b>	17	7.5	0.140
<b>Peri-alveolar MC</b>	2	1	0.444
<b>Peri-bronchial MC</b>	0	0	0,113

Table 2

	<b>Small vessels</b>	<b>Medium vessels</b>	<b>Large vessels</b>	<b>Air cell</b>	<b>Bronchi</b>	<b>All vessels</b>
<b>HANGING</b>						
p value	NS	<i>0.001</i>	<i>0.025</i>	NS	NS	<i>0.007</i>
<b>ASPHYXIA</b>						
p value	NS	NS	NS	NS	NS	NS
<b>ASPIRATION</b>						
p value	NS	<i>0.023</i>	NS	NS	<i>0,003</i>	NS
<b>INTOX CO</b>						
p value	NS	NS	NS	NS	NS	NS
<b>DROWNING</b>						
p value	NS	NS	NS	NS	NS	NS
<b>STRANGULATION</b>						
p value	<i>0.042</i>	NS	NS	NS	NS	NS
<b>PNEUMONIA</b>						
p value	NS	NS	NS	NS	NS	NS
<b>CONTROL CASES</b>						
p value	NS	NS	NS	NS	NS	NS

[Click here to download Supplementary Material: Conflict of interest.pdf](#)