



Case Report

Clinical usefulness of automated cellular analysis of synovial fluids: a paradigmatic case report for diagnosing peri-prosthetic infections

Andrea Baldini^{1#}, Fiamma Balboni^{2#}, Giovanni Balato³, Sabrina Buoro⁴, Paola Pezzati⁵, Massimo Quercioli⁵, Vanni Strigelli⁶, Cristiano De Franco³, Vincenzo De Matteo³, Giuseppe Lippi⁷

¹UO Ortopedia Istituto Fiorentino Cura e Assistenza IFCA, Florence, Italy; ²Laboratorio Analisi Istituto Fiorentino Cura e Assistenza IFCA, Florence, Italy; ³Dipartimento di Sanità Pubblica, Scuola di Medicina e Chirurgia, Università Federico II, Napoli, Italy; ⁴SMEL Generale di Base, Analisi Chimico Cliniche, Azienda Socio Sanitaria Territoriale Papa Giovanni XXIII, Bergamo, Italy; ⁵Centro Regionale di Riferimento Sicurezza e Qualità, AOU Careggi, Florence, Italy; ⁶Dipartimento di Ortopedia, Fondazione Policlinico Universitario A. Gemelli, IRCCS Roma, Rome, Italy; ⁷Sezione di Biochimica Clinica, Università degli Studi di Verona, Verona, Italy

[#]These authors contributed equally to this work.

Correspondence to: Giuseppe Lippi, MD. Section of Clinical Biochemistry, University Hospital of Verona, Piazzale LA Scuro, 37134 Verona, Italy. Email: giuseppe.lippi@univr.it

Abstract: We describe here the case of an 18 years old male patient who underwent osteosynthesis surgery with a plate and screws for multi-fragment fracture of his right femur, in December 2000. The patient developed a series of complications up to May 2017, when he was readmitted with severe functional impairment and inability to walk without crutches. Physical examination revealed erythema, swelling at surgical site and leakage of pus from sinus-tract. An arthrocentesis was hence performed, followed by white blood cell count and differential in synovial fluid with Sysmex XN 2000 body fluid mode. The final leukocyte count was $38 \times 10^9/L$, with 95% polymorphonuclear leukocytes (PMN), thus compatible with peri-prosthetic infection. The patient underwent additional surgery to remove the knee replacement, accurate debridement and antibiotic impregnated static cement spacer implantation. Three months after surgery, the patient was readmitted for removing the spacer, replaced by a new static device. In May 2018, surgical debridement and removal of the spacer was scheduled with resection arthroplasty. In November 2018 the patient presented again a sinus tract, and underwent another arthrocentesis for physical and microbiological examination of synovial fluid. The leukocyte count in the synovial fluid was again performed with Sysmex XN 2000 body fluid mode, and revealed the presence of $44.5 \times 10^9/L$ cells, with 90% PMN. The synovial fluid was positive for *Van-A Enterococcus faecalis*, so that right hip disarticulation was urgently planned. In conclusions, this case provides clear evidence that automated leukocyte count and differential in synovial fluid shall now be considered an unavoidable part of the diagnostic approach to patients with suspected peri-prosthetic infections.

Keywords: Synovial fluid; peri-prosthetic infection; osteosynthesis; leukocytes

Received: 14 March 2019; Accepted: 27 May 2019; Published: 13 June 2019.

doi: [10.21037/amj.2019.05.03](https://doi.org/10.21037/amj.2019.05.03)

View this article at: <http://dx.doi.org/10.21037/amj.2019.05.03>

Introduction

Bone surgery site infections after osteosynthesis, conventionally known as osteosynthesis-associated infection, is a relative rare but extremely severe complication (1). The cumulative

frequency of osteosynthesis-associated infection can be as high as 30% in certain categories of patients, especially those with wound contamination of third-degree open fractures (2). The diagnosis of osteosynthesis-associated

infection is frequently challenging, and encompasses an integration of many diagnostic investigations such as laboratory and microbiological testing, diagnostic imaging and histopathology. Notably, recent evidence suggests that the diagnostic performance of periprosthetic tissue cultures is considerably low and may generate a consistent number of false negative test results (i.e., up to one-third) (2). Delayed or inaccurate diagnoses are major determinants of adverse clinical outcomes after osteosynthesis, which may then predispose the patients to severe complications such as retarded bone union and debridement, up to the possibility of amputation (2). In these potential unfavorable scenarios, diagnostic tools enabling rapid rule in or rule out of osteosynthesis-associated infections become pivotal.

The differential diagnosis between infectious and non-infectious joint diseases typically entails arthrocentesis with subsequent morphological analysis of synovial fluid, thus including cell count and differential (3). Although this approach is universally validated, there is still uncertainty surrounding the diagnostic cut-offs. A number of leukocytes $>2 \times 10^9/L$ with as many as 75% polymorphonuclear leukocytes (PMN) is usually diagnostic of an inflammatory condition, whilst a leukocyte count $>50 \times 10^9/L$ with $>85\%$ PMN is suggestive for septic arthritis (4). Unlike these thresholds, the diagnostic cut-offs for diagnosing periprosthetic infection remains controversial. The current availability of diagnostic techniques for morphological analysis of synovial fluids is another major drawback. As endorsed by the Clinical and Laboratory Standards Institute (5), optical microscopy remains the gold standard for leukocyte count and differential in synovial fluid. Nevertheless, this technique has many well-known drawbacks, such as poor standardization, high inter-operator variability, long turnaround time, low throughput and need for trained and skilled personnel. Recent evidence has been provided that automated cellular analysis of synovial fluids may represent a valuable perspective for improving both accuracy and timeliness in diagnosing periprosthetic infections (6). We describe here a paradigmatic case, documenting the important role of automated morphological analysis of synovial fluids in peri-prosthetic infections diagnostics.

Case presentation

An 18 years old male patient underwent osteosynthesis surgery with a plate and screws for a multi-fragment fracture of his right femur, in December 2000. The patient

developed non-union of femoral fracture and serum biomarkers were elevated. Erythrocyte sedimentation rate (ESR) (Roller 20, Alifax, Padova, Italy) was 45 mm/h, whilst C-reactive protein (CRP) (immunoturbidimetric assay on AU480, Beckman Coulter, Brea, CA, USA) was 20 mg/L, respectively. A leukocyte scintigraphy showed an increased uptake at site of pseudarthrosis. The patient underwent additional surgical procedure to remove the metal plate and screws in his right femur. Tissue samples culture for aerobic and anaerobic bacteria were obtained and methicillin-resistant *Staphylococcus aureus* was isolated from cultured specimens. In February 2003, after multiple antibiotic treatment courses, the patient developed knee joint stiffness and degenerative arthritic changes, and then underwent total knee replacement surgery with a constrained long-stemmed implant due to associated non-union at metaphyseal level. The postoperative period was immediately complicated by appearance of sinus tract in the knee and quadriceps strength deficiency. The patient underwent chronic suppressive antibiotic therapy with minocycline 100 mg bid and trimethoprim/sulfamethoxazole tid. The patient developed extreme knee joint stiffness and ankylosis and intermittent output from the fistula, alternatively suppressed by multiple antibiotic treatment courses. On May 2017, the patient was admitted with severe functional impairment and inability to walk without crutches. Physical examination revealed extensive erythema, swelling at surgical site and pus leakage from a sinus-tract. The patient was afebrile, but laboratory tests revealed an ESR of 32 mm/h and a CRP of 27.8 mg/L. An arthrocentesis was hence performed, followed by white blood cell count (SF-WBC) and differential in synovial fluid. Cellular analysis was carried out using Sysmex XN 2000 body fluid mode (Sysmex Corporation, Kobe, Japan) after addition of hyaluronidase (Sigma Chemical Co., St. Louis, MO, USA) at final concentration of 0.5 mg/mL, as for validated practice (6). The final WBC count was $38 \times 10^9/L$, with 95% PMN, thus compatible with periprosthetic infection. The appearance of the synovial fluid on cytopsin is shown in *Figure 1*, confirming the massive amount of PMN already identified by automated cell count and differential in the synovial fluid. The patient underwent additional surgery to remove the knee replacement, accurate debridement and antibiotic impregnated static cement spacer implantation. Three months after the operation, due to infection persistence, the patient underwent another surgery to remove the spacer, replaced by a new static device. In May 2018, considering the severe condition of

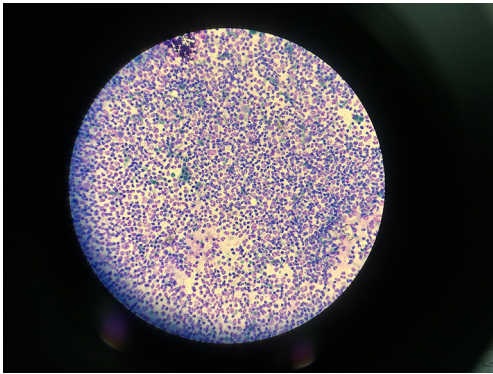


Figure 1 Morphological analysis of synovial fluid, showing massive amount of polymorphonuclear cells, highly suggestive of ongoing peri-prosthetic infection. Sample was stained with May-Grünwald Giemsa and read at 40x magnification.

the surgical area, surgical debridement and removal of the spacer was scheduled with resection arthroplasty. All the tissue samples collected for microbiological testing were positive for *Escherichia coli*, and *Enterococcus faecalis*. In June 2018 the patient received another antibiotic impregnated static cement spacer. In November 2018 the patient presented a sinus tract, and underwent another arthrocentesis for physical and microbiological examination of synovial fluid. The leukocyte count and differential in the synovial fluid were again performed with Sysmex XN 2000 body fluid mode (Sysmex Corporation), and revealed the presence of $44.5 \times 10^9/L$ cells, with 90% PMN. The synovial fluid was also positive for *Van-A Enterococcus faecalis*, so that right hip disarticulation was urgently planned. The patient was then discharged and no further complications have been reported so far.

Discussion

Albeit the diagnostic cut-offs remain still to be defined, a recent systematic review and meta-analysis of the literature concluded that an increased leukocyte count in synovial fluid is highly suggestive of peri-prosthetic joint infections, displaying 0.89 sensitivity and 0.86 specificity (7). Notably, the percentage of PMN in synovial fluid had virtually identical diagnostic performance, but a slightly higher area under the curve (i.e., 0.93 versus 0.91). Shortly afterwards, a second independent systematic review and meta-analysis has confirmed that a leukocyte count $>3 \times 10^9/L$ in synovial fluid is characterized by 0.89 sensitivity and 0.85 specificity for diagnosing peri-prosthetic hip and knee

infections (8). Even in such case the diagnostic performance of percentage PMN in synovial fluid was comparable to that of the leukocyte count, exhibiting 0.88 sensitivity and 0.82 specificity. Irrespective of the final cut-offs, which are usually comprised between $>1.7 \times 10^9/L$ and $>4.5 \times 10^9/L$, the leukocyte count in synovial fluid shall hence be regarded now as a cornerstone in peri-prosthetic infections diagnostics, thus reinforcing the crucial role played by laboratory diagnostics in modern medicine, always at the center of both the diagnostic reasoning and clinical decision making (9). Despite optical microscopic analysis is still considered the reference method for cell analysis in synovial fluid, the new generation of hematological analyzers is characterized by specific features enabling rapid, accurate and reliable measures. Therefore, their use in routine laboratory practice is increasingly described as a valid alternative to the manual technique, as also shown in this paradigmatic case report of peri-prosthetic infection.

Conclusions

In conclusions, this case provides clear evidence that automated leukocyte count and differential in synovial fluid shall now be considered an unavoidable part of the diagnostic approach to patients with suspected peri-prosthetic infections.

Acknowledgments

None.

Footnote

Conflicts of Interest: The authors have no conflicts of interest to declare.

Informed Consent: Written informed consent was obtained for publication of this Case Report and any accompanying images.

References

1. Fang C, Wong TM, Lau TW, et al. Infection after fracture osteosynthesis - Part I. *J Orthop Surg (Hong Kong)* 2017;25:2309499017692712.
2. Yano MH, Klautau GB, da Silva CB, et al. Improved diagnosis of infection associated with osteosynthesis by use of sonication of fracture fixation implants. *J Clin Microbiol*

- 2014;52:4176-82.
3. Margaretten ME, Kohlwes J, Moore D, et al. Does this adult patient have septic arthritis? *JAMA* 2007;297:1478-88.
 4. Shah RP, Plummer DR, Moric M, et al. Diagnosing Infection in the Setting of Periprosthetic Fractures. *J Arthroplasty* 2016;31:140-3.
 5. Clinical and Laboratory Standard Institute. *Body Fluid Analysis for Cellular Composition; Approved Guidelines (CLSI document H56-A)*. Wayne, PA, 2006.
 6. Seghezzi M, Buoro S, Manenti B, et al. Optimization of Cellular analysis of Synovial Fluids by optical microscopy and automated count using the Sysmex XN Body Fluid Mode. *Clin Chim Acta* 2016;462:41-8.
 7. Lee YS, Koo KH, Kim HJ, et al. Synovial Fluid Biomarkers for the Diagnosis of Periprosthetic Joint Infection: A Systematic Review and Meta-Analysis. *J Bone Joint Surg Am* 2017;99:2077-84.
 8. De Fine M, Giavaresi G, Fini M, et al. The role of synovial fluid analysis in the detection of periprosthetic hip and knee infections: a systematic review and meta-analysis. *Int Orthop* 2018;42:983-94.
 9. Plebani M, Laposata M, Lippi G. A manifesto for the future of laboratory medicine professionals. *Clin Chim Acta* 2019;489:49-52.

doi: 10.21037/amj.2019.05.03

Cite this article as: Baldini A, Balboni F, Balato G, Buoro S, Pezzati P, Quercioli M, Strigelli V, De Franco C, De Matteo V, Lippi G. Clinical usefulness of automated cellular analysis of synovial fluids: a paradigmatic case report for diagnosing periprosthetic infections. *AME Med J* 2019;4:29.