

Recommendations of the International Society of Intraoperative Neurophysiology for intraoperative somatosensory evoked potentials



D.B. MacDonald^{a,*}, C. Dong^b, R. Quatralo^c, F. Sala^d, S. Skinner^e, F. Soto^f, A. Szelényi^g

^a Section of Clinical Neurophysiology, Department of Neurosciences, King Faisal Specialist Hospital & Research Center, MBC 76, PO Box 3354, Riyadh, Saudi Arabia

^b Intraoperative Neurophysiologic Monitoring Program, Department of Surgery, University of British Columbia, Vancouver, British Columbia, Canada

^c Neurology Section, Ospedale dell'Angelo, Venice, Italy

^d Department of Neurosurgery, University Hospital, Verona, Italy

^e Department of Neurophysiology, Abbott Northwestern Hospital, Minneapolis, MN, United States

^f Dept. of Neurology, Las Condes Clinic, Santiago, Chile

^g Dept. of Neurosurgery, Ludwig Maximilians University, Munich, Germany

See Editorial, pages 155–156

ARTICLE INFO

Article history:

Accepted 21 October 2018

Available online 14 November 2018

Keywords:

Somatosensory evoked potentials

Intraoperative monitoring

Intraoperative mapping

Optimization

Warning criteria

Recommendations

HIGHLIGHTS

- This article reviews and forms recommendations for intraoperative SEPs.
- It endorses SEP optimization to enhance surgical feedback speed and accuracy.
- It supports an adaptive warning criterion to adjust for baseline drift and variability.

ABSTRACT

Intraoperative somatosensory evoked potentials (SEPs) provide dorsal somatosensory system functional and localizing information, and complement motor evoked potentials. Correct application and interpretation require in-depth knowledge of relevant anatomy, electrophysiology, and techniques. It is advisable to facilitate cortical SEPs with total intravenous propofol–opioid or similarly favorable anesthesia. Moreover, SEP optimization is recommended to enhance surgical feedback speed and accuracy by maximizing signal-to-noise ratio (SNR); it consists of selecting highest-SNR peripheral and cortical derivations while omitting low-SNR channels. Confounding factors causing non-surgical SEP reduction should be excluded before issuing a warning. It is advisable to facilitate their identification with peripheral SEP controls and cortical SEP systemic controls whenever possible. Warning criteria should adjust for baseline drift and reproducibility. The recommended adaptive warning criterion is visually obvious amplitude reduction from recent pre-change values and clearly exceeding trial-to-trial variability, particularly when abrupt and focal. Acquisition and interpretation should be done by qualified technical and professional level personnel. Indications for SEP monitoring include intracranial, posterior fossa, and spinal neurosurgery, as well as orthopedic spine, cerebrovascular, and descending aortic surgery. Indications for SEP mapping include sensorimotor cortex and dorsal column midline identification. Future advances could modify current recommendations.

© 2018 International Federation of Clinical Neurophysiology. Published by Elsevier B.V. This is an open access article under the CC BY-NC-ND license (<http://creativecommons.org/licenses/by-nc-nd/4.0/>).

Contents

| | |
|--|-----|
| 1. Introduction | 162 |
| 2. Anatomical considerations | 162 |

* Corresponding author.

E-mail addresses: dbmacdon@icloud.com (D.B. MacDonald), Charles.Dong@vch.ca (C. Dong), quatralo@iol.it (R. Quatralo), francesco.sala@univr.it (F. Sala), Andrea.Szelényi@med.uni-muenchen.de (A. Szelényi).

<https://doi.org/10.1016/j.clinph.2018.10.008>

1388-2457/© 2018 International Federation of Clinical Neurophysiology. Published by Elsevier B.V.

This is an open access article under the CC BY-NC-ND license (<http://creativecommons.org/licenses/by-nc-nd/4.0/>).

| | | |
|---------|--|-----|
| 2.1. | Dorsal somatosensory pathway | 163 |
| 2.2. | Indirect proprioception pathways | 163 |
| 2.3. | Nondecussation | 163 |
| 2.4. | Blood supply | 164 |
| 3. | Electrophysiology | 164 |
| 3.1. | Peripheral responses | 164 |
| 3.2. | Segmental potentials | 164 |
| 3.3. | Dorsal column volley | 165 |
| 3.4. | Subcortical potentials | 165 |
| 3.5. | Cortical responses | 165 |
| 4. | Electrodes | 165 |
| 4.1. | Surface electrodes | 165 |
| 4.2. | Needle electrodes | 165 |
| 4.3. | Invasive electrodes | 165 |
| 5. | Stimulation | 165 |
| 5.1. | Sites | 165 |
| 5.2. | Parameters | 166 |
| 5.3. | Interleaving | 167 |
| 6. | Recording | 167 |
| 6.1. | Technical aspects | 167 |
| 6.2. | Reproducibility | 167 |
| 6.3. | Signal-to-noise ratio | 167 |
| 6.4. | Rapid surgical feedback | 168 |
| 6.5. | Anesthesia | 168 |
| 6.6. | Traditional derivations | 169 |
| 6.7. | Optimal derivations | 170 |
| 6.8. | Peripheral SEP controls | 171 |
| 6.8.1. | Cubital and popliteal fossa | 171 |
| 6.8.2. | Erb's point | 171 |
| 6.9. | Cortical SEP monitors | 171 |
| 6.9.1. | Lower limb | 171 |
| 6.9.2. | Upper limb | 171 |
| 6.9.3. | Sitting position | 171 |
| 6.10. | Other potentials | 171 |
| 6.10.1. | Subcortical SEPs | 172 |
| 6.10.2. | Segmental SEPs | 172 |
| 6.11. | Optimization benefits | 172 |
| 7. | Warning criteria and interpretation | 172 |
| 7.1. | Confounding factors | 172 |
| 7.2. | Traditional warning criteria pitfalls | 172 |
| 7.3. | Recommended adaptive warning criterion | 173 |
| 7.4. | Interpretation | 174 |
| 8. | Personnel | 174 |
| 9. | Safety | 175 |
| 10. | Indications | 175 |
| 10.1. | Peri-Rolandic brain surgery | 175 |
| 10.2. | Cerebrovascular surgery | 175 |
| 10.3. | Posterior fossa surgery | 176 |
| 10.4. | Orthopedic spine surgery | 176 |
| 10.5. | Spinal neurosurgery | 176 |
| 10.6. | Descending aortic procedures | 176 |
| 11. | Conclusion | 176 |
| | Funding | 177 |
| | References | 177 |

1. Introduction

Somatosensory evoked potentials (SEPs) are an important part of intraoperative neurophysiologic monitoring (IONM) because they provide functional and localizing information about the dorsal somatosensory system and complement motor evoked potentials (MEPs). This document reviews relevant anatomy, physiology, methodology, interpretation and applications and forms recommendations of the International Society of Intraoperative Neurophysiology for intraoperative SEPs. It is also endorsed by the International Federation of Clinical Neurophysiology. This is not a clinical practice guideline as defined by the [Institute of Medicine \(2011\)](#) because the absence of randomized controlled trials

precludes formal systematic review. Nevertheless, it is based on currently available scientific evidence and consensus expert opinion. It also recognizes that alternative methods exist, that standards of care vary with resources in different regions, and that future advances could modify subsequent recommendations. An analysis of evidence for outcome benefit is beyond the scope of this article.

2. Anatomical considerations

As somatosensory anatomy and blood supply are important for intraoperative SEP interpretation, this section summarizes relevant information from several sources ([Basbaum and Jessell, 2000](#); [Gardner and Kandel, 2000](#); [Gardner et al., 2000](#); [Pearson and](#)

Gordon, 2000; Ropper and Adams, 2005a, 2005b; Crossman and Neary, 2008; Kiernan, 2009a, 2009b). The dorsal somatosensory system conveys discriminative touch, vibration, and proprioception, while the anterolateral somatosensory system carries pain, light touch, and temperature sensation. Practitioners should understand that SEPs elicited by electrical peripheral nerve stimulation and recorded in ≤ 100 ms sweeps selectively test the dorsal system because its abundant thick peripheral axons have low thresholds and fast, uniform conduction. These techniques do not assess the anterolateral system because its thinner axons have higher thresholds and slower, more variable conduction.

2.1. Dorsal somatosensory pathway

The dorsal system has cutaneous discriminative touch and vibration receptors as well as muscle spindle and other deep receptors for limb proprioception. The primary afferents travel up peripheral nerves, plexuses and sensory roots. Cervicothoracic roots have an approximately horizontal trajectory from their neural foramen to the cord, while lumbosacral roots ascend the spinal canal in the cauda equina to reach the cord that ends at the L1–L2 vertebrae. The afferent fibers pass by their pseudo-unipolar cell bodies in the dorsal root ganglia, reach the dorsal root entry zone and then bifurcate up and down and rebranch within the spinal cord (Niu et al., 2013).

Some branches ascend the entire ipsilateral dorsal column, with leg fibers in the medial gracile fasciculus and arm fibers in the lateral cuneate fasciculus. These long afferents terminate in the gracile and cuneate nuclei of the medulla, from which second-order axons decussate as the internal arcuate fibers and then ascend the contralateral medial lemniscus to synapse in the ventral posterolateral thalamic nucleus. Third-order axons ascend the posterior limb of the internal capsule and then fan out in the thalamocortical radiation to synapse in the primary sensory gyrus (S1), with arm fibers going to its lateral convexity and leg fibers to its mesial parasagittal region.

Other branches synapse in spinal cord gray matter. These include muscle spindle afferent collateral branches that form the sensory arc of tendon stretch reflexes (Niu et al., 2013). Some branches terminate in the dorsal horn, from which second-order axons reenter and ascend the dorsal column. The dorsal columns

also contain descending axons involved in sensory modulation, and propriospinal axons (Fitzgerald, 1992).

2.2. Indirect proprioception pathways

The traditional view that proprioception afferents projecting to cortex directly ascend the dorsal columns is controversial. One alternative based on animal evidence proposes that they synapse in the dorsal horn, with second-order axons ascending the dorsolateral funiculus just behind the corticospinal tract (Gilman, 2002). Another proposes that they terminate in Clarke's column, with second-order axons ascending the dorsolateral funiculus in the spinocerebellar tract just superficial to the corticospinal tract (Landgren et al., 1971; Gilman, 2002; Niu et al., 2013).

The extent of these indirect pathways in humans is uncertain (Ross et al., 1979; Lockard and Kempe, 1988; Ross, 1991) and the issue is relevant to SEP interpretation. For example, it is thought that dorsolateral funiculus conduction generates lower limb spinal epidural SEP components (Jones et al., 1982; Halonen et al., 1989). It has also been proposed that dorsolateral funiculus conduction generates lower limb scalp SEPs (York, 1985). However, recordings during intramedullary spinal cord tumor surgery indicate dorsal column conduction (Fig. 1). Consequently, if indirect proprioceptive pathways exist then lower limb scalp SEPs could represent mostly cutaneous afferents. Furthermore, there is unresolved uncertainty about proprioceptive contributions to mixed-nerve SEPs in general (Burke et al., 1981; Gandevia et al., 1984; Halonen et al., 1988; Fukuda et al., 2007). Thus, practitioners should understand that scalp SEPs involve dorsal column conduction and cutaneous afferents, but that the contribution of proprioceptive afferents is unclear.

2.3. Nondecussation

Practitioners should also be aware that some rare brainstem malformations cause dorsal sensory system and corticospinal tract nondecussation due to absence of the internal arcuate and pyramidal decussations, so that the dorsal columns project to ipsilateral cortex (MacDonald et al., 2004a; Vulliamoz et al., 2005). Horizontal gaze palsy and progressive scoliosis is the most relevant of these conditions for IONM. This autosomal recessive disorder is more likely in regions with prevalent consanguinity, such as the

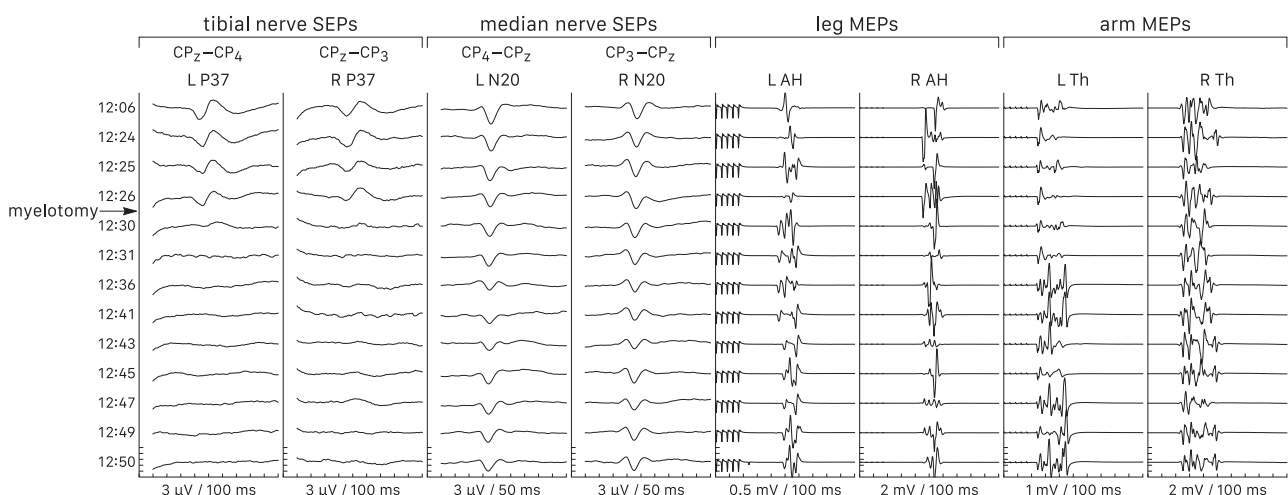


Fig 1. Tibial nerve scalp SEP disappearance after cervical dorsal midline myelotomy for intramedullary spinal cord tumor surgery. This recurring observation suggests dorsal column conduction of scalp SEPs. Disruption of indirect dorsolateral funiculus sensory pathways is an unlikely explanation for SEP deterioration since the immediately adjacent corticospinal tracts are unaffected as evidenced by MEP preservation. L, left; R, right; P37 and N20, tibial and median nerve cortical SEPs; AH, abductor hallucis; Th, thenar.

Middle-East where it comprised 2.3% of a series of scoliosis surgery patients (MacDonald et al., 2007). However, it also arises sporadically in other regions, including North America, Europe, and Japan. As the anomaly requires reversed-lateralization scalp monitoring derivations and will be missed unless sought, this document includes methods to routinely screen for and rarely adapt to non-decussation, without implying that it is common.

2.4. Blood supply

The anterior cerebral artery supplies the mesial S1 gyrus and subcortical sensory fibers for the lower limb, while the middle cerebral artery supplies the lateral S1 gyrus and subcortical sensory fibers for the upper limb. Thus, tibial and median nerve SEPs are relevant monitors for anterior and middle cerebral artery ischemia, respectively.

Lenticulostriate branches of the middle cerebral and anterior choroidal arteries supply thalamocortical sensory axons. Posterior cerebral artery branches supply thalamic sensory nuclei. Basilar and vertebral artery branches supply the medial lemniscus.

The left and right posterior spinal arteries supply the dorsal columns and outer dorsal horns, while the anterior spinal artery supplies the remaining gray matter and inner white matter, including the anterior horns and corticospinal tracts (Mawad et al., 1990; Connolly, 1998). These longitudinal arteries also form pial anastomoses supplying the outer white matter, and receive collateral supply from cervical, aortic, and iliac radicular arteries.

Autoregulation adjusts brain and spinal cord blood flow to metabolic need across a range of blood pressure and persists under anesthesia. Due to higher metabolic rate, spinal gray matter receives four times more blood flow than white matter and is more sensitive to ischemia (Marcus et al., 1977). Consequently, acute cord ischemia causes rapid muscle MEP disappearance due to anterior horn cell failure but delayed or no deterioration of SEPs conducted through the relatively resistant dorsal columns (MacDonald and Dong, 2008). Thus, very abrupt SEP deterioration during spinal cord monitoring may suggest another pathophysiology, such as compression.

3. Electrophysiology

Correct intraoperative SEP interpretation requires knowledge of the underlying electrophysiology. Peripheral nerve stimulation triggers a time-locked sequence of travelling action potentials and stationary postsynaptic potentials along the dorsal somatosensory pathway. Temporo-spatial summation and volume conduction enable surface SEP recording.

Travelling SEP latencies increase with stimulus–recording distance and stationary SEP latencies increase with stimulus–generating structure distance. Near-field SEP amplitudes increase with the proximity of the recording electrode to the generator, while far-field SEP amplitudes do not depend on electrode proximity.

Amplitudes increase with stimulus intensity up to a supramaximal level that is lower for cortical than peripheral responses, implying ‘central amplification’ (Fig. 2A) (Eisen et al., 1982; Gandevia and Burke, 1984). Thus, supramaximal peripheral response intensity ensures supramaximal cortical SEP monitoring. Also, peripheral nerve or dorsal column conduction failure has to involve a substantial proportion of axons before causing an appreciable scalp SEP decrement, which might partly explain lower SEP than MEP sensitivity for intraoperative spinal cord compromise.

3.1. Peripheral responses

Mixed-nerve sensory and motor axon action potentials propagate up and down from the stimulation point. Ascending sensory and antidromic motor impulses produce traveling near-field compound peripheral nerve action potentials typically recorded at the cubital fossa medial to the biceps tendon just above the fossa crease, Erb’s point 2 cm above the mid-clavicle, and the popliteal fossa just above the fossa crease.

3.2. Segmental potentials

Spinal cord gray matter postsynaptic potentials in the segments where the stimulated nerve’s axons enter produce a stationary near-field SEP that is negative behind and positive in front of the

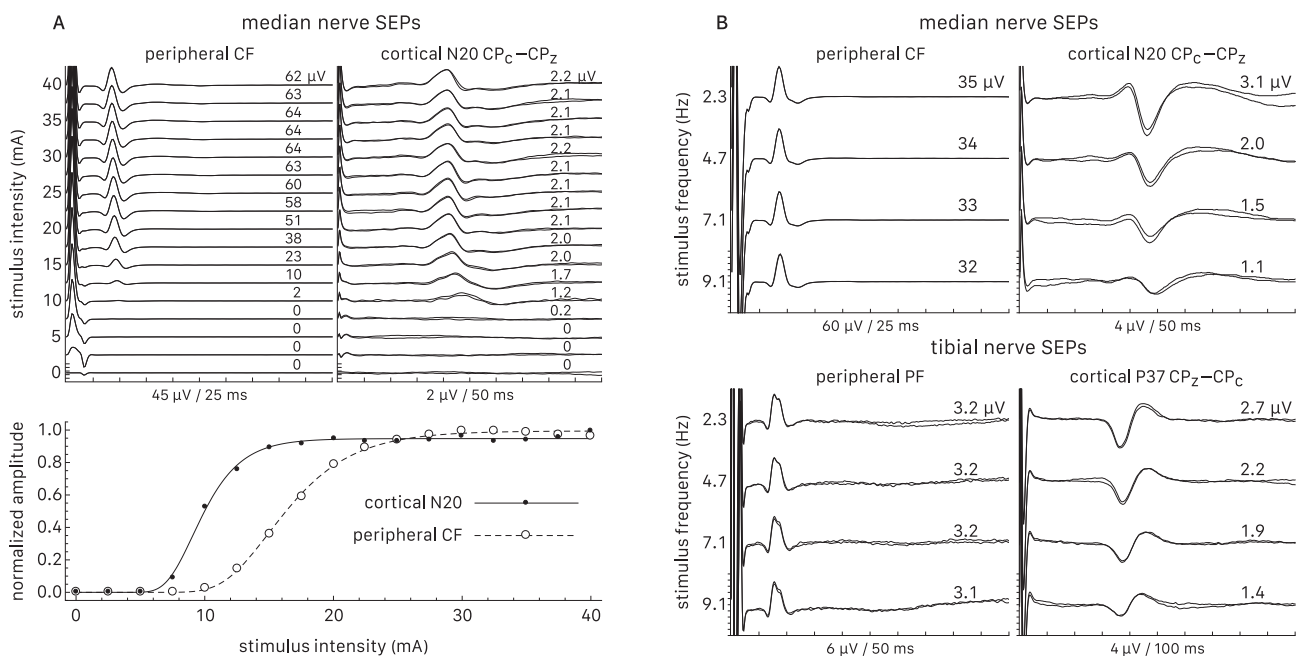


Fig 2. Stimulus intensity and frequency. CF and PF, cubital and popliteal fossa; propofol–remifentanyl anesthesia. A: Cortical SEPs appear and saturate at lower stimulus intensity than peripheral responses. B: The inverse relationship between stimulus frequency and cortical SEP amplitude.

cord (Lee and Seyal, 1998; American Clinical Neurophysiology Society, 2006). One usually records the upper limb N13 over the 5th cervical spine (C5S) and the lower limb N22 over the 12th thoracic spine (T12).

3.3. Dorsal column volley

Ascending dorsal column and possibly dorsolateral funiculus action potentials generate a polyphasic travelling near-field dorsal column volley (Hahn et al., 1981; Jones et al., 1982; Halonen et al., 1989; Lee and Seyal, 1998). It is larger with proximal than distal nerve stimulation and is readily obtained in spinal subdural, epidural, or interspinous ligament recordings, but small and inconsistent at the skin. A few programs monitor these potentials with invasive spinal electrodes (Forbes et al., 1991; Burke et al., 1992; Sutter et al., 2007).

3.4. Subcortical potentials

The brainstem dorsal column nuclei and medial lemniscus generate stationary far-field subcortical SEPs consisting of a positive peak followed by a negative peak that decays slowly (Desmedt and Cheron, 1980, 1981a, 1981b; Lee and Seyal, 1998; American Clinical Neurophysiology Society, 2006). Their broad fields project about equally over the scalp and with low amplitude at basal ear or mastoid (M) sites. Consequently, they cancel out in scalp bipolar derivations, partially cancel in scalp to basal reference channels, and have greatest amplitude in scalp to noncephalic reference derivations.

The upper limb P14 and N18 are usually recorded from centroparietal scalp ipsilateral to the stimulated nerve to separate them from contralateral cortical SEPs (Desmedt and Cheron, 1981b; American Clinical Neurophysiology Society, 2006). With nondecussation they would be recorded from contralateral scalp instead. The lower limb P31 and N34 are usually recorded from the forehead midline to separate them from centroparietal cortical responses.

3.5. Cortical responses

The S1 gyrus generates stationary near-field early cortical SEPs exhibiting dipolar fields (Desmedt and Cheron, 1981b; Lee and Seyal, 1998; American Clinical Neurophysiology Society, 2006). Bipolar scalp derivations separate them from subcortical potentials and display largest signal amplitude when inputs 1 and 2 are at the field's opposite maxima.

Upper limb direct cortical SEP recordings from subdural electrodes reveal a tangential response dipole from the anterior bank of S1 that shows a 'phase reversal', being negative (N20) behind and positive (P20) in front of the central sulcus; there may also be a radial positive response (P25) on the S1 crest (Wood et al., 1988; Allison et al., 1989, 1991; Nuwer et al., 1992; Cakmur et al., 1997; Romstöck et al., 2002). The dipole projects to the scalp as a centroparietal N20 contralateral to the stimulated nerve and a bifrontal P22. With nondecussation the N20 is ipsilateral instead.

Lower limb direct cortical SEP recordings disclose a mesial P37 generated by the S1 crest with no consistent central sulcus phase reversal (Allison et al., 1996). The P37 most often projects maximally to the centroparietal midline and its field paradoxically spreads over the scalp ipsilateral to the stimulated nerve because of its mesial source (Rossini et al., 1981; Cruse et al., 1982; Lesser et al., 1987). However, it may be maximal at the vertex, parietal midline, or ipsilateral scalp (MacDonald, 2001; Miura et al., 2003; MacDonald et al., 2004b, 2005). An N37 pole usually projects to the contralateral scalp but may be unapparent or at the parietal

midline when the P37 is maximal at the vertex. Nondecussation reverses P37 and N37 lateralization.

4. Electrodes

4.1. Surface electrodes

Some programs prefer surface electrodes that are safe and effective for stimulation and recording and have <2 k Ω impedance with proper skin preparation. Attaching them before the operating room shortens intraoperative setup and enables early postinduction SEP recording and optimization.

Standard ECG or other adhesive electrodes self-secure on smooth skin. Rigid bar stimulating electrodes are inadvisable for IONM because they risk pressure necrosis (Stecker et al., 2006; Netherton et al., 2007; MacDonald and Deletis, 2008). Reusable EEG cup electrodes filled with conductive paste or gel firmly secure to the scalp with collodion. They are cleaned and disinfected after use; flammable collodion and acetone for its removal must not be in open use during electrosurgery.

4.2. Needle electrodes

Programs doing postinduction setups often choose needle electrodes for quickness. These electrodes are also effective and have <5 k Ω impedance, but risk needle-stick and other infections, subcutaneous or intramuscular hemorrhages, pneumothorax with excessively deep insertion, and intraoperative burns because their small surface area generates high current density when electrosurgery current accidentally passes through them (Stecker et al., 2006; Netherton et al., 2007; Patterson et al., 2007; MacDonald and Deletis, 2008).

Tape secures straight needles at smooth skin and corkscrew needles self-secure in the scalp. Special caution is advisable for infants and patients with ventriculo-peritoneal shunts in order to avoid piercing open fontanels or damaging shunt systems. It is important to handle needles by their stems and discard them into a sharps box after use; flammable antiseptics must be dry before draping.

4.3. Invasive electrodes

Invasive subdural or epidural electrodes for cortical or spinal cord recording carry a small but potentially serious risk of infection, hemorrhage, or trauma. Consequently, they are generally reserved for special indications and are strictly single use.

5. Stimulation

5.1. Sites

For median nerve stimulation, the anode is between the flexor carpi radialis and palmaris longus tendons at the wrist crease and the cathode is 3 cm proximal. The ulnar nerve may be preferred or added for low cervical procedures because its cutaneous afferents enter lower spinal cord segments (C8–T1) than median nerve cutaneous afferents (C6–C7).

For posterior tibial nerve stimulation, the cathode is between the medial malleolus and Achilles tendon and the anode is 3 cm distal. Alternative lower limb stimulation sites for peripheral neuropathy or other distal obstacles include the peroneal nerve at the fibular head and the tibial nerve in the popliteal fossa; SEP latencies are shorter with these sites.

5.2. Parameters

The stimuli are rectangular 0.2–0.3 ms constant-current pulses. Supramaximal intensity can be determined from single-sweep peripheral responses, or estimated as 3 times sensory or 2 times

motor threshold. These levels are safe for distal nerves and are recommended to avoid spurious amplitude changes due to fluctuating stimulus efficacy. However, supramaximal intensity is inadvisable for proximal nerves at the knee because strong tibialis anterior muscle contractions could cause anterior tibial compartment

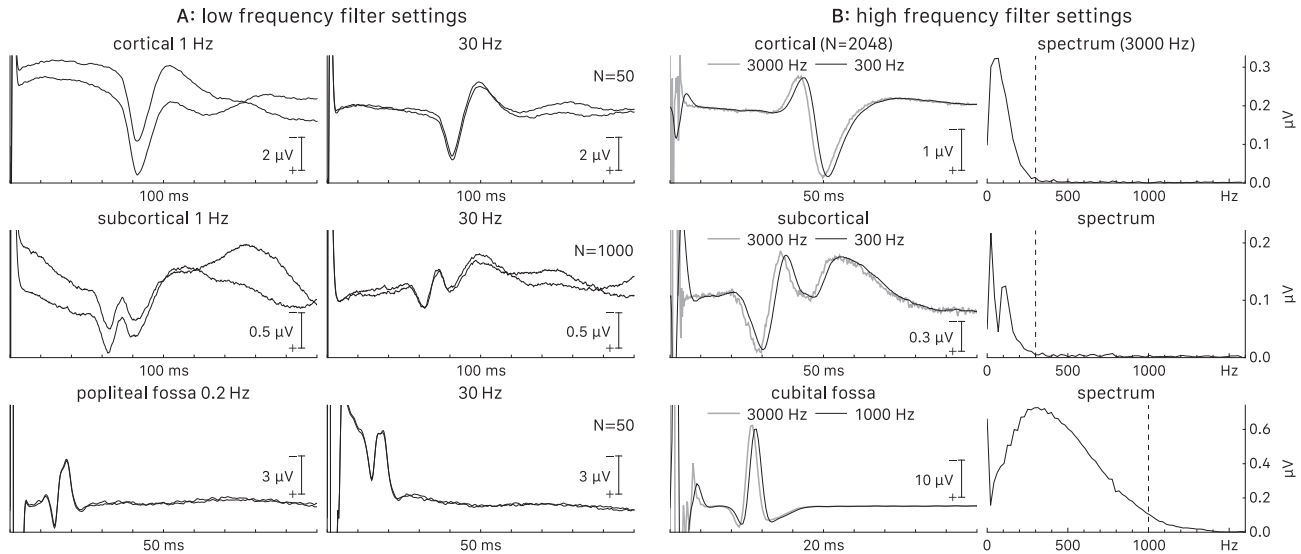


Fig 3. Filter settings. Propofol and remifentanyl anesthesia; N, number of averaged sweeps. A: A 30 Hz low frequency filter enhances scalp (cortical and subcortical) SEP reproducibility but distorts peripheral (popliteal fossa) potentials that show better stimulus artifact separation with an open 0.2 Hz filter. Note the large N needed for subcortical SEPs. B: Spectra of grand average (N = 2048) SEPs recorded with a 3000 Hz high frequency filter (gray traces) show nearly all frequency content below 300 Hz for scalp and below 1000 Hz for peripheral (cubital fossa) potentials. Thus, 300 and 1000 Hz scalp and peripheral high frequency filters smooth signals with negligible latency shift (black traces).

Table 1
Reproducibility classification and detectable pathological decrements.

| Reproducibility | Amplitude variation | Waveform superimposition | Detectable decrement |
|------------------|---------------------|--------------------------|----------------------|
| High | <20% | nearly exact | >≈30% |
| Medium | 20–30% | approximate | >≈40% |
| Low | 30–50% | loose | >≈50% |
| Non-reproducible | >50% | divergent | disappearance |

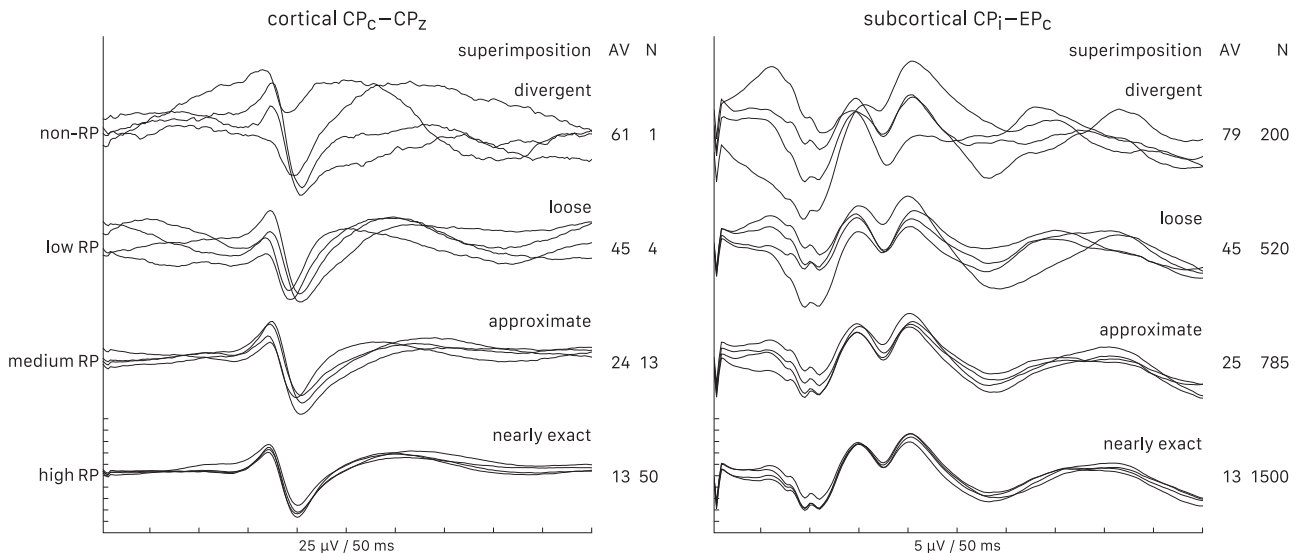


Fig 4. Reproducibility (RP) classification exemplified by median nerve SEPs during propofol and remifentanyl anesthesia (30–300 Hz bandwidth). AV, trial-to-trail signal amplitude variation (%); N, number of averaged sweeps. Note much lower N for cortical than subcortical SEPs to reach comparable reproducibility.

syndrome (Weston, 2002); neuromuscular blockade or motor threshold intensity would be safer. There is no evidence that repetitive stimulation wears down or damages nerves.

Stimulus frequency must not divide evenly into 50 or 60 to avoid time-locked artifacts at power line frequency. Faster stimulation speeds acquisition but decreases cortical SEP amplitude (Fig. 2B). Around 4.7 or 5.1 Hz is generally a satisfactory balance but adjustments may help optimize results (Nuwer and Packwood, 2008).

5.3. Interleaving

One should interleave stimuli to speed acquisition. Left–right interleaving halves acquisition time by enabling concurrent bilateral recording. Four-limb interleaving also halves but may not further speed acquisition because frequency must be reduced to accommodate four sweeps. Nevertheless, this technique enhances cortical SEP amplitudes due to slower stimuli and enables concurrent four-limb recording. Simultaneous bilateral tibial nerve stimulation to boost scalp SEP amplitude is inadvisable because it could mask unilateral decrements.

6. Recording

6.1. Technical aspects

Low impedance and tight lead braiding are essential to reduce extraneous electromagnetic interference. Notch filters are off to avoid ‘ringing’ that could distort or simulate SEPs. Suitable low–high filter settings are 30–300 Hz for scalp and 0.2–1000 Hz for cubital and popliteal fossa SEPs (Fig. 3) (Nuwer and Dawson, 1984; Nuwer and Packwood, 2008). The sampling rate must be more than twice the high frequency filter to prevent aliasing and 16-bit 3–4 kHz sampling is adequate with the above settings.

Amplifier gains and rejection levels are set to utilize dynamic range without clipping biologic signals and exclude sweeps with higher amplitude artifacts while avoiding excessive rejections. Upper and lower limb recording sweeps of 50 and 100 ms are appropriate; pathologically delayed responses occasionally need longer sweeps and peripheral sweeps may be shorter.

6.2. Reproducibility

Averaged SEPs are estimates distorted by residual noise. One assesses their accuracy with reproducibility classified by visual

inspection as high, medium, low or non-reproducible according to trial-to-trial amplitude variation and trace superimposability (Table 1, Fig. 4) (MacDonald et al., 2009). It is advisable to average to medium–high reproducibility rather than to a fixed sweep number that may be smaller (inaccurate) or larger (delayed feedback) than needed. It is also advisable to record sequential self-contained averages to detect abrupt decrements that running averages could mask.

6.3. Signal-to-noise ratio

The signal-to-noise ratio (SNR) in decibels determines how quickly an SEP reproduces. Where *SP* and *NP* are signal and noise power and *rmsSA* and *rmsNA* are root mean square signal and noise amplitude, $SNR_{dB} = 10 \log(SP/NP) = 10 \log(rmsSA^2/rmsNA^2)$.

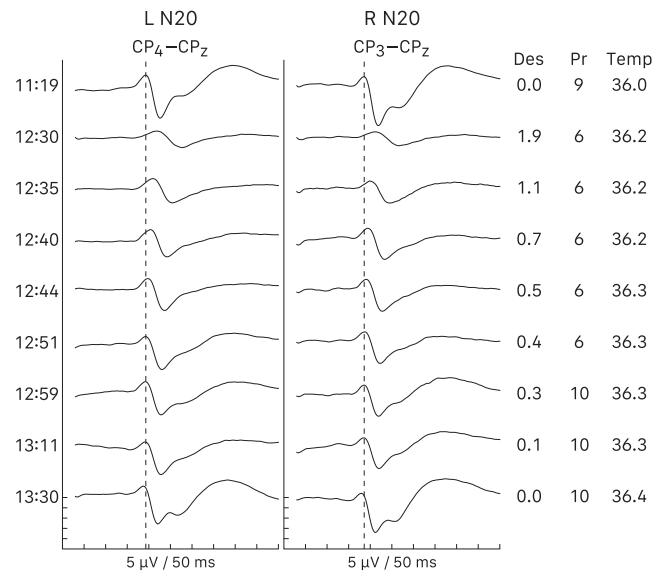


Fig 6. Inhalational anesthetic effects. L, left; R, right; N20, median nerve cortical SEP; Des, desflurane (vol. %); Pr, propofol (mg/kg/h); Temp, temperature (C). Remifentanyl was constant at 0.2 µg/kg/min. Adding low-dose 1.9% desflurane (0.3 minimal alveolar concentration) depressed N20 amplitude and increased latency despite reduced propofol, so it was discontinued. Its concentration and effects took an hour to dissipate.

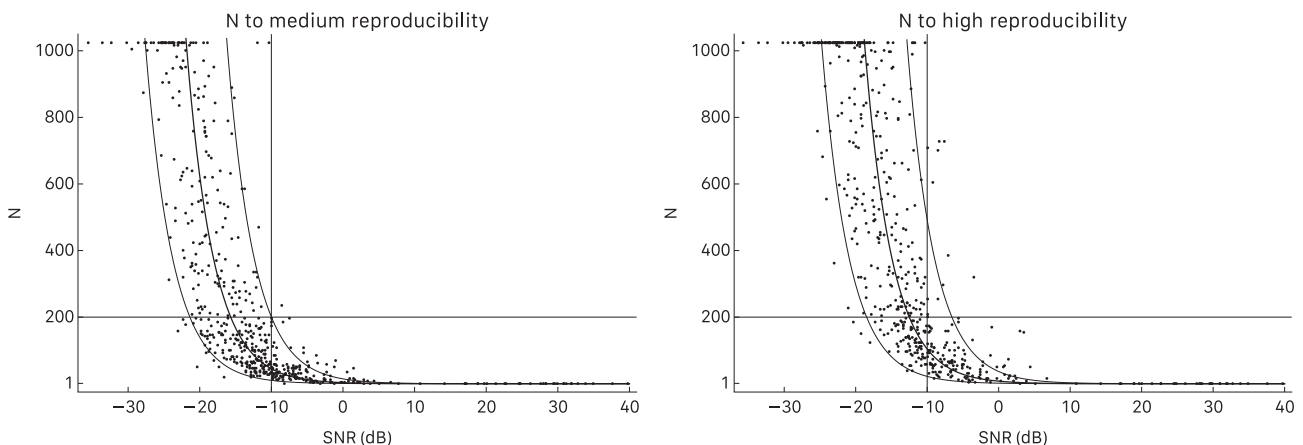


Fig 5. Signal-to-noise ratio (SNR) and number averaged sweeps (N) to reproducibility. Intraoperative data from 16 derivations in 35 patients. The row of points at the top are potentials that failed to reproduce by 1024 sweeps and are excluded from regression. The thick and thin curves are the mean and 90% confidence interval. Derivations with ≥ -10 dB SNR consistently reach medium to high reproducibility within 1–200 sweeps, while lower SNR derivations risk dramatically slower or non-reproducibility. Modified from MacDonald et al. (2009), with permission.

Rapid 1–200 sweep reproducibility occurs with SNR ≥ -10 dB, while sweep number increases dramatically toward lower SNRs (Fig. 5).

6.4. Rapid surgical feedback

By closely tracking surgical events, rapid feedback clarifies the likely cause of a pathologic decrement and therefore guides appropriate intervention. It also affords time to react, which may enhance the likelihood of success. Thus, rapid acquisition is critical

to monitoring efficacy. Although external events such as electro-surgery cause monitoring interruptions, averaging consumes most of the time between updates. Therefore, high-SNR (≥ -10 dB) SEP derivations are advisable to enhance efficacy.

6.5. Anesthesia

This section limits itself to major points since it is beyond its scope to detail the complex field of anesthesia. Comprehensive reviews are available elsewhere (Sloan, 1998, 2010; Sloan and

Table 2
Traditional SEP monitoring derivations.

| | Decussation | Peripheral | Segmental | Subcortical | Cortical |
|------------|-------------|-------------------|-------------------|-------------|-----------------------------|
| Upper limb | Assumed | Epi-EPc or Epi-Fz | C5S-EPc or C5S-Fz | CPi-EPc | CPc-Fz, CPc-Fpz, or CPc-CPi |
| Lower limb | Assumed | PF | T12-IC | Fpz-C5S | CPz-Fpz, CPz-Fz, or CPi-CPc |

EP, Erb's point; PF, popliteal fossa; i and c, ipsilateral and contralateral to the stimulated nerve; C5S and T12, 5th cervical and 12th thoracic spine; IC, iliac crest.

Table 3
Optimal SEP monitoring derivations.

| | Decussation | Peripheral | Cortical – highest SNR of (bold , most frequent): |
|------------|--------------------------|------------|--|
| Upper limb | Normal Nondecussation | CF CF | CPc-CPz , CPc-CPi, or CPc-Fz CPi-CPz , CPi-CPc, or CPi-Fz |
| Lower limb | Normal Nondecussation | PF PF | CPz-CPc , Cz-CPc, Pz-CPc, iCPi-CPc, CPi-CPc, or Cz-Pz CPz-CPi , Cz-CPi, Pz-CPi, iCPc-CPi, CPc-CPi, or Cz-Pz |

CF and PF, cubital and popliteal fossa; trailing i and c, ipsilateral and contralateral to the stimulated nerve; iCP, intermediate centroparietal (CP1 or CP2).
Optional: upper limb Epi-M (mastoid), C5S-M.
Fallback subcortical (normally omitted): upper limb CPi-M (CPC-M for nondecussation), lower limb Fpz-M.

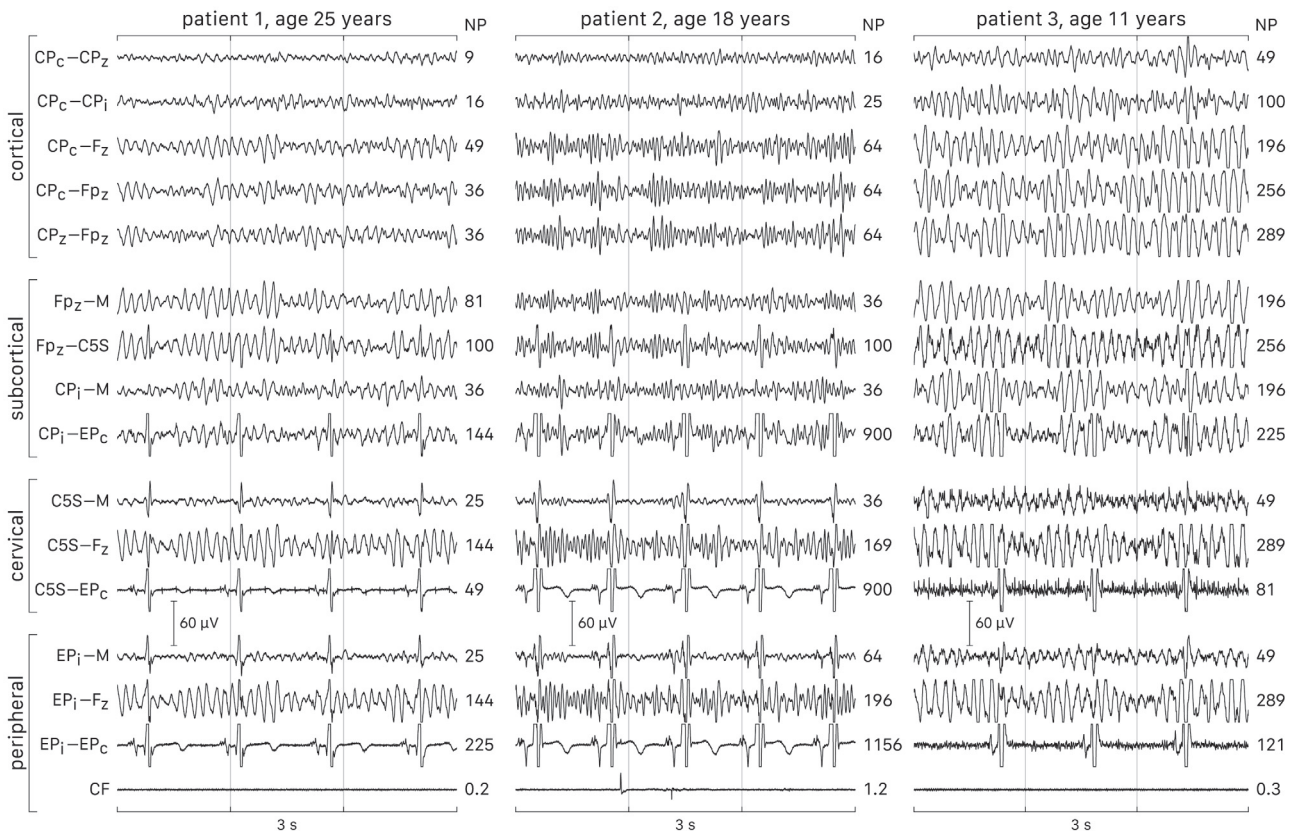


Fig 7. Biological noise in SEP derivations (30–300 Hz bandwidth, propofol–opioid anesthesia). NP, noise power (μV^2). Channels with a scalp electrode contain frontal dominant EEG noise that is least in CPc–CPz and larger in children (patient 3). Derivations with Erb's point (EP), cervical (C5S), or mastoid (M) electrodes contain ECG and sometimes EMG (patient 3) noise. Subcortical, cervical and EP derivations have less noise with a mastoid than other references. The cubital fossa (CF) and popliteal fossa have very low noise. Selecting lowest-noise derivations (e.g., CF, CPc–CPz) is important for maximizing signal-to-noise ratios.

Heyer, 2002). Polysynaptic cortical SEPs exhibit dose-dependent suppression with inhalational anesthetics including nitrous oxide that are therefore suboptimal (Sloan and Koht, 1985; Bernard et al., 1996; Porkkala et al., 1997a, 1997b). Instead, propofol and opioid total intravenous anesthesia (TIVA) is recommended because of less depression and higher SNR (Kalkman et al., 1991; Taniguchi et al., 1992; Langeron et al., 1999; Chen, 2004). This recommendation does not exclude other favorable protocols. For example, ketamine, etomidate or benzodiazepines may be suitable intravenous alternatives (Koht et al., 1988; Sloan et al., 1988; Schubert et al., 1990). More controversially, <0.5 minimal alveolar concentration halogenated gas with reduced propofol may sometimes be satisfactory (Sloan et al., 2015), but sometimes not (Fig. 6).

Oligosynaptic subcortical SEPs are relatively resistant to inhalational anesthesia (Sebel et al., 1987; Wolfe and Drummond, 1988; Pathak et al., 1989), but this advantage is less important with optimal anesthesia for cortical SEPs. Segmental and non-synaptic dorsal column volleys and peripheral SEPs are relatively immune to anesthesia.

6.6. Traditional derivations

Table 2 summarizes traditional monitoring derivations that were naturally adopted from the diagnostic laboratory. However, most of them have suboptimal intraoperative SNRs (MacDonald et al., 2005, 2009). Consequently, traditional methods generally

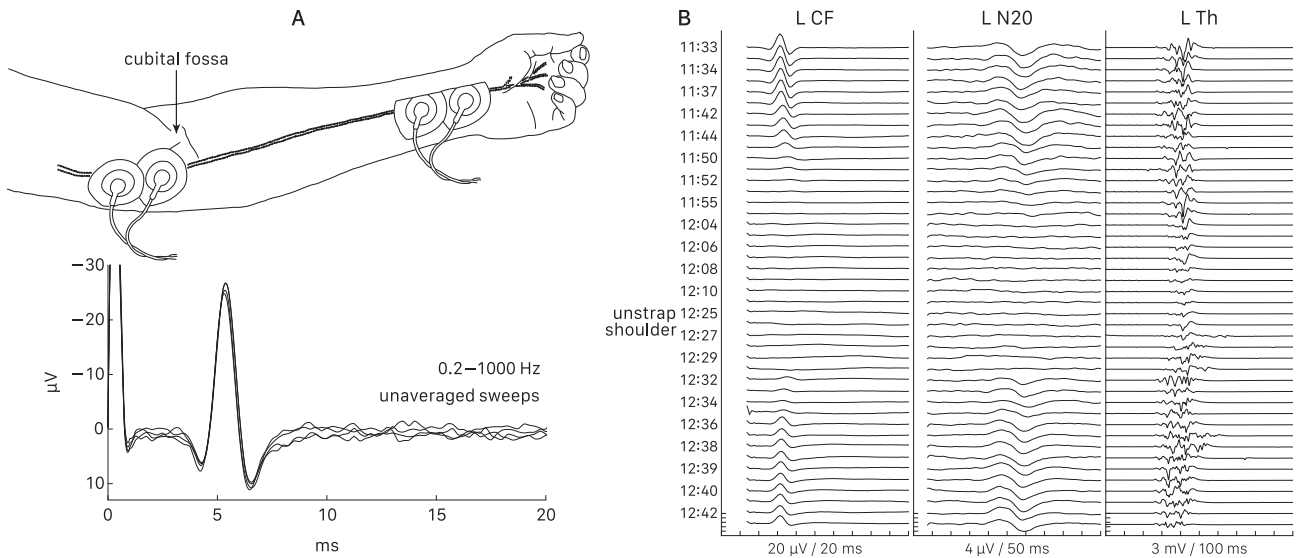


Fig 8. Cubital fossa (CF) recording and utility. A: Electrode location and single-sweep reproducibility due to very high SNR. B: Left CF disappearance during anterior cervical discectomy indicated distal conduction failure causing cortical N20 SEP loss and thenar (Th) MEP deterioration. Signal restoration after shoulder release corroborated suspected arm ischemia due to thoracic outlet vascular compression from downward shoulder strapping. There was no surgical alarm or deficit. Conversely, peripheral SEP preservation excludes distal conduction failure. Modified from MacDonald et al. (2009), with permission.

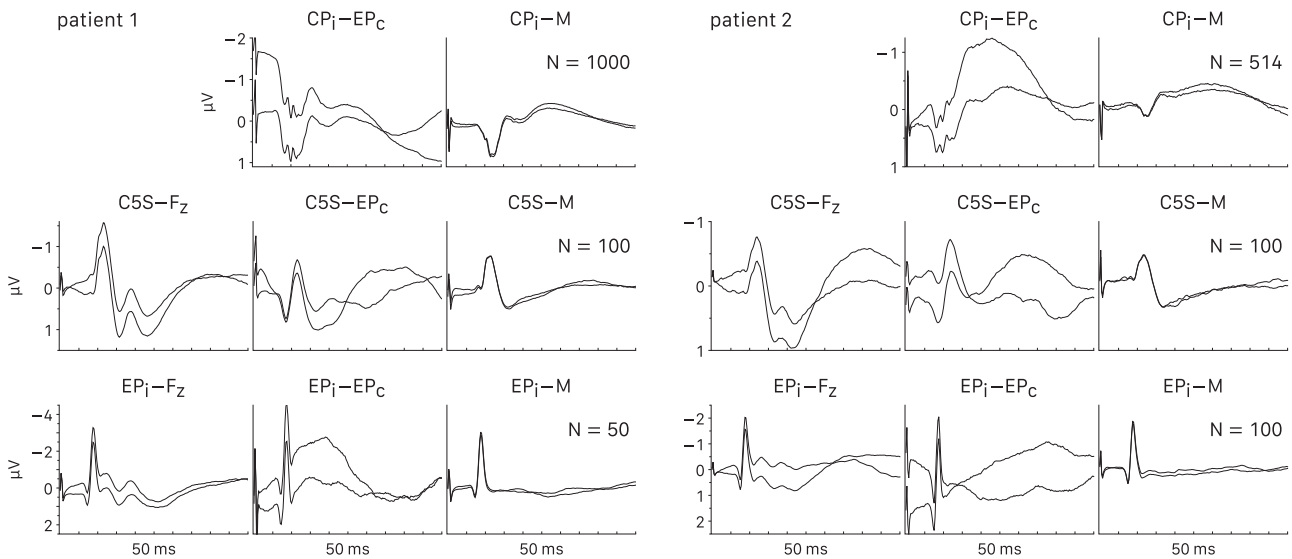


Fig 9. Median nerve subcortical (top row), cervical (C5S, middle row), and Erb's point (EP, bottom row) derivations. Propofol and remifentanyl anesthesia; N, number of averaged sweeps; i and c, ipsilateral and contralateral to the stimulated nerve. These potentials reproduce in fewer sweeps with -M (mastoid) than noisier traditional -Fz or -EPc references. Even so, CPi-M still requires excessive N and optimization therefore normally omits subcortical SEPs. C5S-M and EPi-M may reproduce in <200 sweeps, but are optional.

accept >200 sweep averaging and/or low reproducibility. In addition, they assume decussation and fail to detect nondecussation. Furthermore, non-cephalic reference channels may require neuromuscular blockade to eliminate EMG interference, but this conflicts with MEP/EMG monitoring and partial relaxation is a controversial compromise.

6.7. Optimal derivations

Table 3 summarizes optimal derivations. They are based on SEP optimization that was developed through a series of investigations

including prospective study (MacDonald, 2001; MacDonald and Janusz, 2002; MacDonald et al., 2003, 2004a, 2004b, 2005, 2007, 2009). Optimization minimizes surgical feedback time by selecting highest-SNR derivations while omitting low-SNR channels to gain 1–200 sweep medium–high reproducibility, and includes decussation assessment. It also permits omitting neuromuscular blockade since optimal derivations contain no EMG with adequate anesthesia. It is important to appreciate that biological EEG, ECG and EMG noise is the major obstacle to high SNR (Fig. 7). This is why optimization emphasizes low-noise peripheral and bipolar centroparietal derivations.

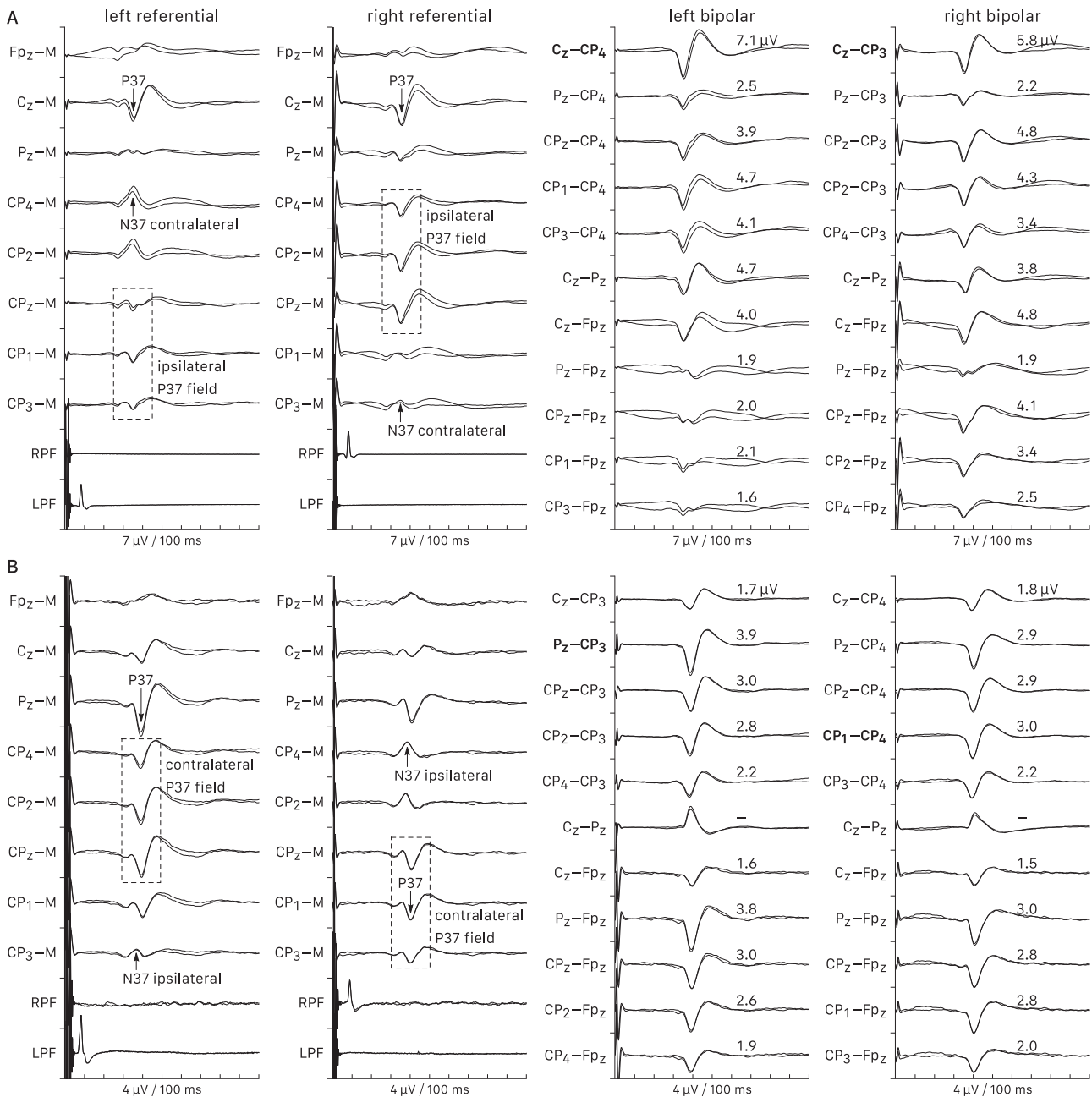


Fig 10. Tibial nerve cortical SEP optimization. M, mastoid; LPF and RPF, left and right popliteal fossa. A: Ipsilateral P37 fields and contralateral N37 potentials confirm decussation. On each side, the P37 is maximal at Cz and Cz–CPC (bold) is optimal. B: Contralateral P37 fields and ipsilateral N37 potentials disclose nondecussation. The left and right P37 maxima are at Pz and CP1, and the optimal derivations are Pz–CP3 and CP1–CP4 (bold). Normally the bipolar centroparietal derivation with largest signal yields greatest SNR, while noisier –Fpz derivations are suboptimal. Thus, recording the top six bipolar derivations along with CPI–M and CPC–M should be sufficient for optimization and decussation screening. Partial optimization could be done with a subset of electrodes.

Of course, practitioners may choose more familiar albeit slower or less reproducible traditional methods, but optimization is encouraged and further explained below.

6.8. Peripheral SEP controls

6.8.1. Cubital and popliteal fossa

Upper and lower limb SEP optimization includes cubital and popliteal fossa recordings to control for stimulus failure or distal nerve conduction failure due to limb ischemia or pressure (Fig. 8). These potentials normally have high or very high SNRs and reproduce in few or single sweeps, although peripheral neuropathy can degrade them and the popliteal fossa response is occasionally too small to see in unaveraged sweeps.

6.8.2. Erb's point

Erb's point recording may additionally control for brachial plexus conduction failure due to shoulder malpositioning. However, this can be deduced without Erb's point by noticing gradual median nerve cortical SEP deterioration out of the surgical context, cubital fossa response preservation, and shoulder malpositioning; repositioning usually restores the cortical response. In addition, Erb's point alone cannot distinguish between brachial plexus and distal nerve conduction failure. Furthermore, it needs more averaging than the cubital fossa. Consequently, optimization normally omits Erb's point but considers it optional if it does not delay feedback. If recorded, EPI–M is advisable due to higher SNR and faster reproducibility than traditional Erb's point derivations (Fig. 9).

6.9. Cortical SEP monitors

Scalp cortical SEPs are widely applicable noninvasive monitors. Proper scalp measurement and expanded international 10–10 system (Nuwer et al., 1998) centroparietal (CP) recording sites midway between C and P coordinates are advisable for accuracy and consistency. One specifies CP3 and CP4 ipsilateral or contralateral to the stimulated nerve with CPi and CPc; intermediate CP1 and CP2 sites are iCPi or iCPc.

6.9.1. Lower limb

Traditional lower limb CPz–Fpz or Fz derivations suffer from frontal EEG noise that reduces SNR. CPz–Fz also suffers from anterior spread of the P37 field causing partial signal cancellation that further reduces SNR.

Fig. 10 illustrates 42-channel tibial nerve SEP optimization with decussation screening. With decussation confirmed by ipsilateral P37 fields and contralateral N37 potentials, CPz–CPc is optimal for 40% of tibial nerves and would be advisable were a single routine derivation desired. However, any of the six normal decussation candidates in Table 3 may be optimal, so the best approach is to compare them and choose the one with highest SNR. Since they have similarly low noise, the one with largest signal is usually optimal and reproduces in substantially fewer sweeps (median 128) than CPz–Fpz (median 512). The technique could be simplified to 16 or 8 channels by recording each side's six candidates with CPc–M and CPi–M to check decussation. Rarely, contralateral P37 fields and ipsilateral N37 potentials disclose nondecussation and then one reverses candidate derivation lateralization as in Table 3.

Occasionally a gradual unilateral change of an optimal derivation causes asymmetric amplitude reduction, but rarely enough to risk a false positive (MacDonald, 2001). One could monitor additional derivations to guard against this, but they might not include the newly optimal one. Reoptimization after gradual asymmetric amplitude reduction out of the surgical context is a more flexible approach, but is rarely necessary.

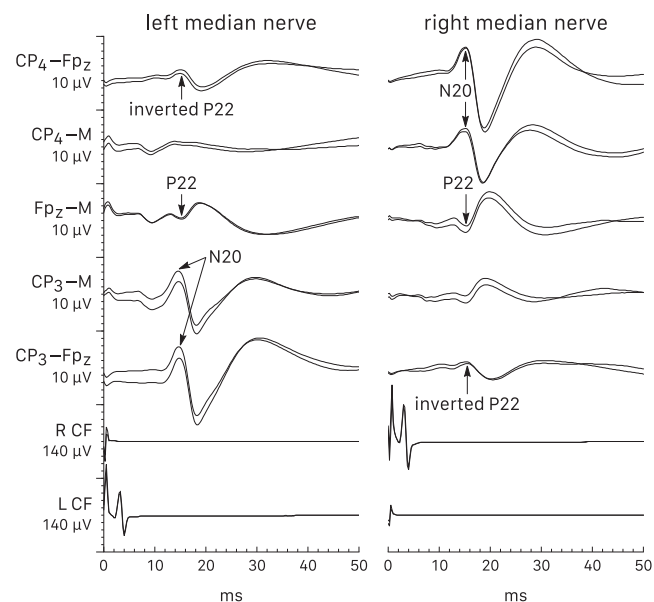


Fig. 11. Median nerve SEPs with nondecussation. M, mastoid; L CF and R CF, left and right cubital fossa. The cortical N20 is abnormally ipsilateral. Traditional CPc-frontal derivations assume decussation and would cause the inverted frontal P22 to be mistaken for a small N20, resulting in suboptimal and inaccurate monitoring. Optimization routinely assesses decussation to ensure correct derivations for this rare anomaly.

6.9.2. Upper limb

Of traditional upper limb cortical SEP derivations, CPc–Fz has largest signal because the inverted P22 maximal at Fz adds to the N20, but this advantage is usually overwhelmed by even greater frontal EEG noise that reduces SNR. Routine CPc-frontal derivations also miss nondecussation because the inverted frontal P22 mimics a small N20 (Fig. 11).

If not already done with tibial nerve optimization, CPc–M and CPi–M recording checks decussation. With confirmed decussation, the optimal derivation for 75% of median nerves is CPc–CPz, which has –9 dB mean SNR and substantially faster reproducibility than traditional median nerve derivations (Fig. 12). Either CPc–CPi or CPc–Fz is optimal for the remainder. Thus, one can use CPc–CPz routinely and check the other two if it seems possibly suboptimal, or initially compare the three and select the fastest reproducing one. Nondecussation candidates are the same, but with reversed lateralization.

6.9.3. Sitting position

Sitting position posterior fossa surgery is an exception because intracranial air over the hemispheric convexities after dural opening can reduce centroparietal SEPs (Watanabe et al., 1989; MacDonald, 2001; Acioly et al., 2011). The effect may be quick or delayed by up to an hour (Wiedemayer et al., 2002). Plain skull x-ray shows the air.

Because midline sites are usually spared due to bridging veins between the cortex and sagittal sinus, the optimal lower limb SEP derivation is CPz–Fpz that is usually unaffected. For the upper limb, recording from CP5/CP6 or T3/T4 instead of CP3/CP4 may avoid the effect of intracranial air (Watanabe et al., 1989; Wiedemayer et al., 2003).

6.10. Other potentials

Other SEPs could be controls or monitors depending on the surgical site, but are not essential because peripheral and cortical SEPs already serve these functions.

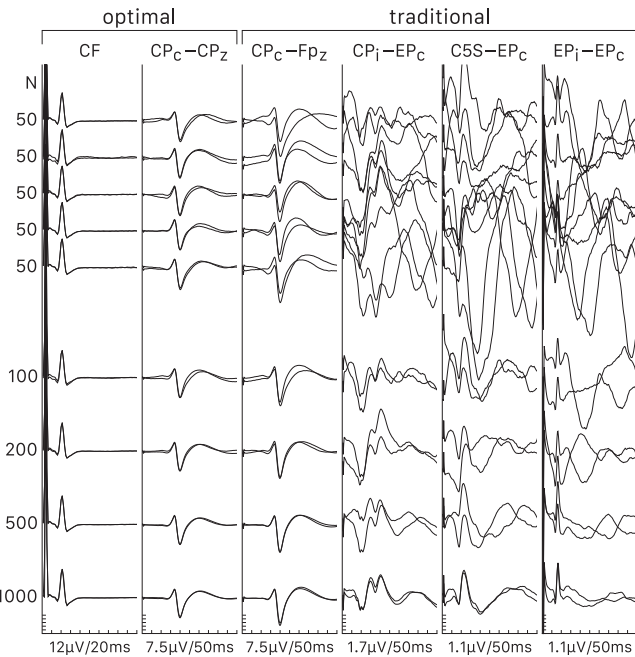


Fig 12. Optimal and traditional median nerve SEP derivations. N, number of averaged sweeps; propofol and remifentanyl anesthesia. Optimal cubital fossa (CF) and CPc–CPz cortical derivations reproduced in only 50 sweeps due to high SNRs. A traditional CPc–Fz scalp derivation had a larger signal than CPc–CPz, but needed 200 sweeps for comparable reproducibility because even larger EEG noise from Fz reduced its SNR. The other traditional derivations required much more averaging because of very low SNRs.

6.10.1. Subcortical SEPs

Inhalational anesthetic resistance is the main reason for traditionally including subcortical SEPs, but this is less relevant with TIVA. Furthermore, due to very low SNRs these potentials frequently require 500–1000 sweep averaging, and then may still lack reproducibility (Figs. 3, 4, 9 and 12). This is true even with neuromuscular blockade that may modestly facilitate their recording.

Consequently, optimization normally omits subcortical SEPs and instead reserves them as fallback potentials for spinal cord monitoring in the case of poor cortical SEPs due to excessive inhalational anesthetics, suboptimal derivations, or antecedent brain pathology. Of course, some practitioners may still choose to routinely include them but would generally attain slower and/or less reproducible feedback.

When recorded, lower limb Fpz–M and upper limb CPI–M (CPc–M for nondecussation) are advisable because of somewhat better SNR and reproducibility than traditional non-cephalic reference channels due to modestly lower biological noise (Figs. 7 and 9).

6.10.2. Segmental SEPs

Optimization normally omits segmental SEPs, but the upper limb N13 could be optionally included if it does not delay feedback. Were this done, C5S–M would be advisable because of higher SNR and faster reproducibility than traditional derivations (Fig. 9). The lower limb N22 generally has low SNR and is usually omitted.

6.11. Optimization benefits

The principal benefit of SEP optimization is fastest possible surgical feedback. This commonly means about one minute between four-limb SEP/MEP sets when there are no external interruptions, and such rapid updates enable quick diagnosis and intervention that likely enhances efficacy (Fig. 13).

Of course, sometimes even optimized SNRs are lower and feedback is slower than desired. This is more likely in young children whose high amplitude EEG noise reduces SNR (e.g., patient 3, Fig. 7) and in patients with pathologically reduced SEPs due to peripheral nerve, spinal cord or brain diseases that become more prevalent with aging. Occasionally one may omit very slow SEPs to speed MEP updates. External interruptions also deter rapid feedback, but optimization still makes best use of available acquisition time.

7. Warning criteria and interpretation

7.1. Confounding factors

Confounding factors are nonsurgical causes of SEP deterioration that one must exclude before issuing a warning. To facilitate their identification, peripheral and rostral or contralateral cortical SEPs are advisable as limb and systemic controls.

Generalized factors cause generalized central SEP deterioration including systemic controls. Deepening anesthesia or boluses are common causes of cortical SEP reduction. Mean arterial pressure below the lower limit of autoregulation may cause central nervous system ischemia and SEP deterioration. However, an increase of anesthesia that reduces both cortical SEPs and blood pressure should be ruled out. Scalp edema from massive fluid administration may reduce scalp SEPs. Mild to moderate hypothermia mainly prolongs latency while deep hypothermia also reduces scalp SEP amplitude (Markand et al., 1990).

Focal factors cause localized deterioration affecting one or two limbs. Peripheral SEPs readily detect stimulus failure or distal conduction failure due to limb pressure or ischemia. Brachial plexus conduction failure due to shoulder malpositioning may be deduced with or without Erb's point recording. Focal antecedent brain or spinal cord pathology can impair autoregulation and lead to localized ischemia and SEP deterioration with modest blood pressure reduction.

Correcting confounding factors by reestablishing stimulation, relieving limb disturbances, adjusting anesthesia, or raising blood pressure can restore SEPs. It may be appropriate to notify surgeons about some of these conditions while specifying that they are not directly related to the surgery.

7.2. Traditional warning criteria pitfalls

Traditional SEP warning criteria developed in the 1970s consist of >50% amplitude reduction or >10% latency prolongation from baseline. Unfortunately, they overemphasize latency and fail to consider baseline drift or reproducibility. To explain, intraoperative pathology causes acute neuronal or axonal failure that mainly reduces SEP amplitude with less effect on latency. Demyelination mainly increases SEP latency with less effect on amplitude but is a subacute–chronic process that does not develop during surgery. Thus, amplitude is the primary monitoring consideration.

In addition, benign systemic influences manifest various patterns of gradual and generalized baseline amplitude drift (MacDonald and Janusz, 2002; MacDonald et al., 2003, 2007). Thus, it is an error to fix an earlier baseline no longer representing the current systemic state. For example, downward drift falls below 50% of initial baseline in up to 20% of scoliosis surgeries (MacDonald et al., 2003, 2007). Conversely, with rising drift an obvious decrement may not fall below 50% of initially lower baseline amplitude. Thus, traditional criteria taken literally risk technical false positives or negatives that do not arise when possible decrements are compared to recent pre-change amplitudes instead.

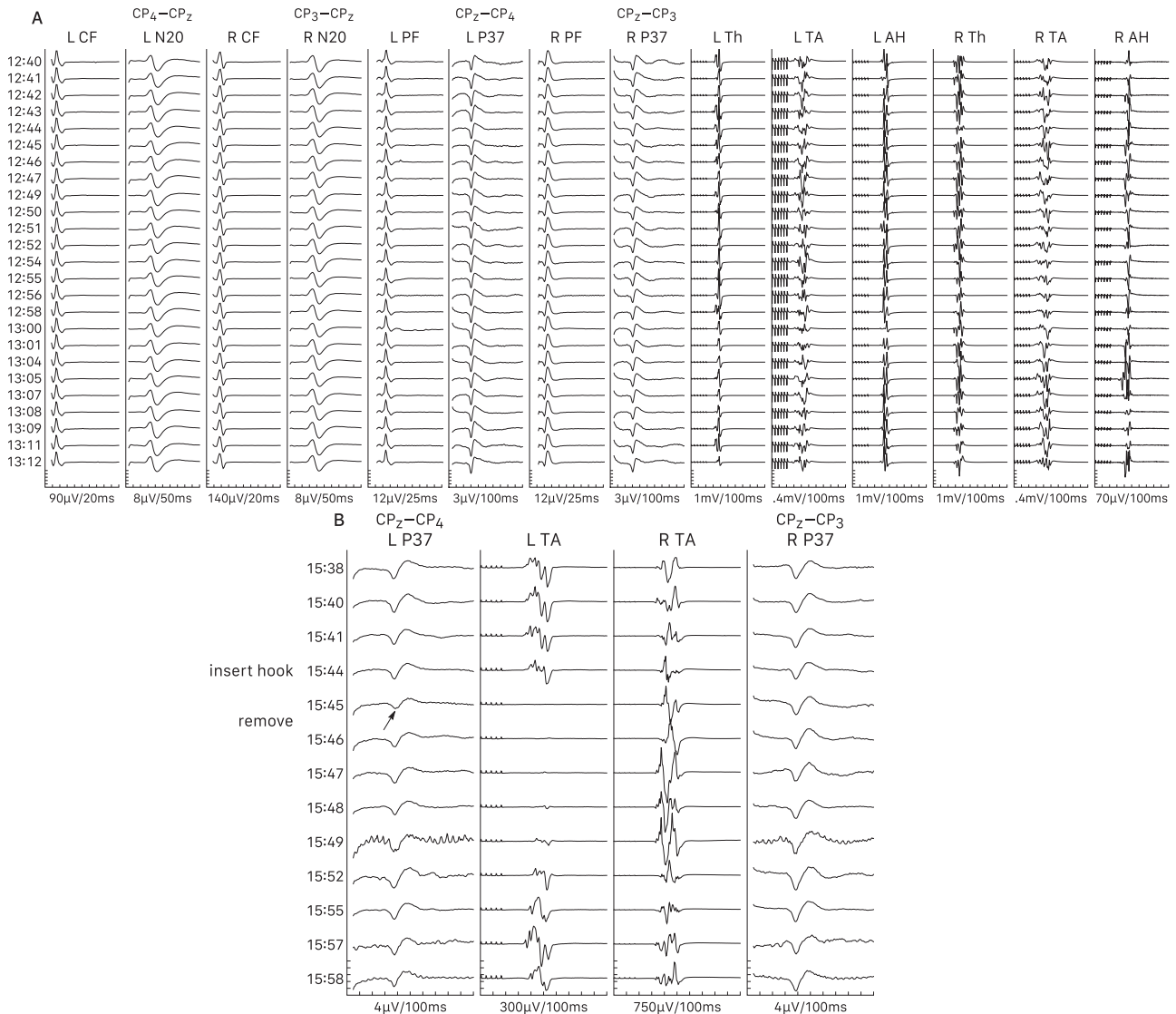


Fig 13. SEP optimization benefits. L and R, left and right; CF and PF, cubital and popliteal fossa; N20 and P37, median and tibial nerve cortical SEPs; Th, TA and AH, thenar, tibialis anterior and abductor hallucis MEPs; propofol–remifentanyl anesthesia. A: Typical rapid high-quality feedback with about one minute between evoked potential sets. B: Quick diagnosis and intervention. One minute after sublaminar hook insertion, an abrupt $\approx 30\%$ L P37 decrement (arrow) made evident by high reproducibility and corroborated by L TA MEP disappearance suggested cord compression. Restoration followed immediate hook removal, with no deficit.

Furthermore, the magnitude of reduction needed to be clearly non-random varies with established reproducibility (Table 1). Thus, while $>50\%$ is appropriate for low reproducibility, it risks false negatives with smaller decrements made obvious by greater reproducibility, or false positives with non-reproducible signals that have to disappear.

In fact, experienced practitioners do adjust for baseline drift and reproducibility. Of course, one may choose to continue with traditional criteria in name (while actually adjusting for the above caveats). However, it seems more reasonable to replace them with a logically adaptive criterion matching actual practice and complexity.

7.3. Recommended adaptive warning criterion

The recommended adaptive criterion is visually obvious amplitude reduction from recent pre-change values and clearly exceeding variability, particularly when abrupt and focal. This approach may reduce the likelihood of technical false results, based on com-

parisons to traditional criteria (MacDonald et al., 2003, 2007). Further warning criteria research would be welcome and could modify this recommendation.

Table 1 provides a rough guide for judging possible decrements relative to established reproducibility. Obviously, warnings based on smaller than 50% reduction must be justified by true medium-high reproducibility to avoid excessive sensitivity. An emphasis on abrupt and focal is pertinent because pathological decrements typically appear in one or a few trials and affect one or two limbs (e.g., Fig. 13B). An initially borderline decrement may be corroborated by concordant MEP loss or more definite SEP deterioration in subsequent trials. Fig. 14 illustrates these principles.

There are exceptions to typical patterns of systemic and pathologic change, such as gradually evolving pathologic deterioration or abrupt anesthetic changes. In addition, bilateral pathologic deterioration may appear generalized when rostral systemic controls are unavailable due to the surgical site (e.g., posterior fossa, cervical). These can be identified by considering the surgical and systemic contexts.

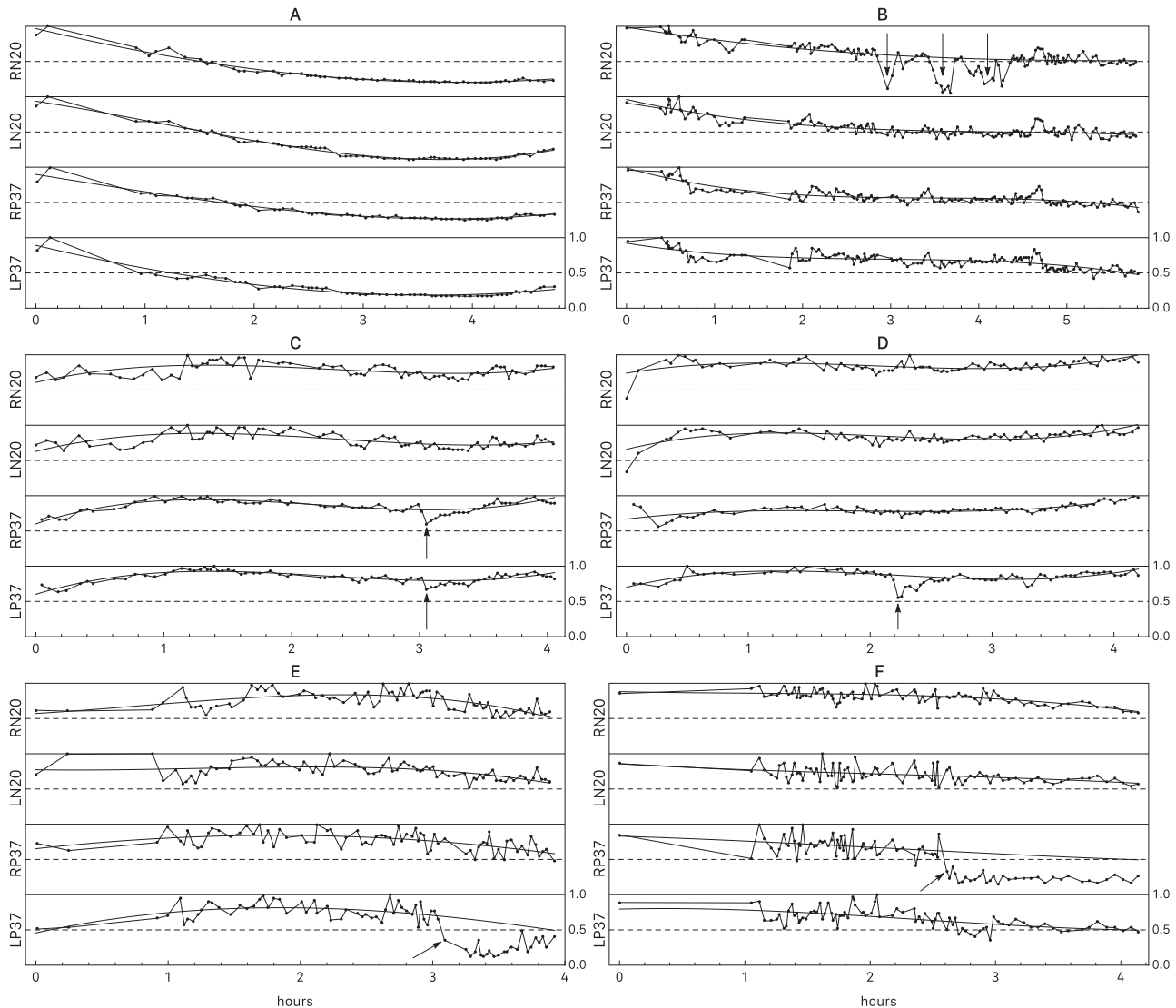


Fig 14. Interpretive principles illustrated by normalized cortical SEP amplitude plots with polynomial trendlines. L and R, left and right; N20 and P37, median and tibial nerve cortical SEPs. The plots exemplify assessment of gradual generalized baseline drift, reproducibility, and pathological abrupt focal decrements (arrows) from recent pre-change amplitudes and exceeding variability. A: High reproducibility and downward drift to <20% of early amplitudes with no alarm or deficit. B: Medium reproducibility and downward drift to <50% of initial amplitudes with RN20 decrements restored after intervention, with no deficit. C: Rising–falling–rising drift with a bilateral 20–30% P37 decrement made evident by high reproducibility; MEPs were unaltered. Despite spontaneous restoration, bilateral leg sensory disturbance lasted weeks (possible dorsal column contusion). D: Rising–falling–rising drift and a 40% LP37 decrement made evident by high reproducibility; MEPs were unaltered. Restoration followed intervention with no deficit. E: Rising–falling drift and 40–50% LP37 decrement made borderline by low reproducibility but corroborated by MEP loss (not shown) and further SEP reduction. Gradual restoration followed intervention with no deficit. F: Downward drift and a 40–50% RP37 decrement made borderline by low reproducibility but corroborated by MEP loss (not shown) and further SEP reduction. Irreversibility despite intervention predicted Brown-Sequard cord injury.

The risk of a clinical deficit with a pathologic decrement varies with its reversibility. Quickly reversible (<30–40 min) decrements usually, but not always predict the absence of new postoperative deficits that become more likely with protracted (>40–60 min) and especially irreversible decrements (Holdefer et al., 2015).

7.4. Interpretation

Interpretation is the action of explaining meaning and for IONM also extends to recommending action when appropriate. Thus, it is not enough to simply issue a warning. Instead, the neurophysiologist tries to determine and convey the most likely cause of SEP deterioration, considering all relevant factors including anesthesiologist and surgeon input. When the determination implicates a confounding factor, the neurophysiologist negotiates toward possible correction. When it implicates surgical neurological compro-

mise, the neurophysiologist gives a warning and negotiates toward possible intervention.

In some cases, because of deeper understanding of the surgery, the surgeon primarily decides whether or not and how to intervene. In other cases, because of better physiologic understanding, the neurophysiologist recommends an intervention (e.g., rod release) and the primary team surgeon then decides on its execution, considering all relevant issues. In any case, the warning mandates a decision. Consequently, neurophysiologists are clinically responsible for their interpretation and its impact on surgical decisions.

8. Personnel

Monitoring personnel should have relevant training, experience, and qualification (Isley and Pearlman, 2006; Sutter et al.,

2007). In accordance with section 7.4, SEP interpretation requires an IONM-competent professional level individual able to assume clinical responsibility. Consequently, some jurisdictions define it as a physician activity. For example, the American Medical Association (2008) asserts that “supervision and interpretation of intraoperative neurophysiologic monitoring constitutes the practice of medicine”. However, other jurisdictions may also recognize IONM-competent PhDs if appropriately licensed, credentialed and privileged. Technical aspects can be delegated to qualified technologists working under professional supervision.

9. Safety

Monitoring devices must comply with national safety standards and should undergo biomedical inspection every 6–12 months and after any malfunction. Personnel should be well versed in electrical safety, be aware of electrode and stimulation safety issues (sections 4 and 5) and follow infection control procedures (MacDonald and Deletis, 2008). Decades of experience have proven SEP monitoring to be safe for clinical use in expert hands using appropriate precautions.

10. Indications

SEP monitoring is indicated for any surgery tangibly risking dorsal somatosensory system injury and complements MEP monitoring of surgeries mainly risking motor injury. The two modalities are frequently combined. The following sections describe some applications, presented in anatomical order from the brain down.

10.1. Peri-Rolandic brain surgery

Cortical SEP mapping with subdural electrodes can localize S1 and by deduction suggest the primary motor gyrus (M1) during peri-Rolandic surgery (Wood et al., 1988; Allison et al., 1989; Nuwer et al., 1992; Cedzich et al., 1996; Cakmur et al., 1997; Romstöck et al., 2002; Kumabe et al., 2005; Jahangiri et al., 2011; Simon, 2013). Its success under general anesthesia and in children

are advantages over traditional 50–60 Hz direct cortical stimulation that works best during awake craniotomy and may fail in children (Alvarez and Jayakar, 1990; Duchowny and Jayakar, 1993; Berger, 1995; Riviello et al., 2001).

Mapping is usually done with median nerve SEPs recorded from subdural strip or grid arrays laid across the putative central sulcus hand area and referenced to the scalp or mastoid. Alternative bipolar recordings require careful interpretation (Kombos, 2008). Localization criteria include the central sulcus N20/P20 phase reversal, sometimes a P25 over S1, and largest response amplitudes at the hand area; M1 should be nearest the pre-central P20 electrode (Fig. 15, patient 1). Ambiguity may arise at a distance from hand cortex or with an electrode directly over the central sulcus; sampling different electrode positions may find the expected pattern. The SEP results appear to be correct in >90% of cases (Romstöck et al., 2002). Nevertheless, when M1 localization is critical it is advisable to follow with direct cortical stimulation MEP mapping because of occasional discrepancies (Fig. 15, patient 2).

Less frequently done tibial or trigeminal nerve cortical SEP mapping relies mainly on maximal response amplitude for localizing leg or face S1 areas (McCarthy et al., 1993; Allison et al., 1996), although phase reversal has also been reported with lip stimulation (Kumabe et al., 2005).

10.2. Cerebrovascular surgery

Cortical SEPs are very sensitive to sensory cortex ischemia, and are therefore useful for monitoring intracranial aneurysm or arteriovenous malformation surgery and endarterectomy (López et al., 1999; Florence et al., 2004; López, 2009; Alcantara et al., 2014; Sahaya et al., 2014; Malcharek et al., 2015; Nwachuku et al., 2015). Median and tibial nerve SEPs for detecting middle and anterior cerebral artery ischemia show close correlation between cortical SEP amplitude and cerebral blood flow. Interventions such as clip removal or repositioning, retractor adjustment, raising blood pressure, or shunting often reverse SEP deterioration. However, ischemia and infarction outside of sensory cortex may go undetected (Szelényi et al., 2003).

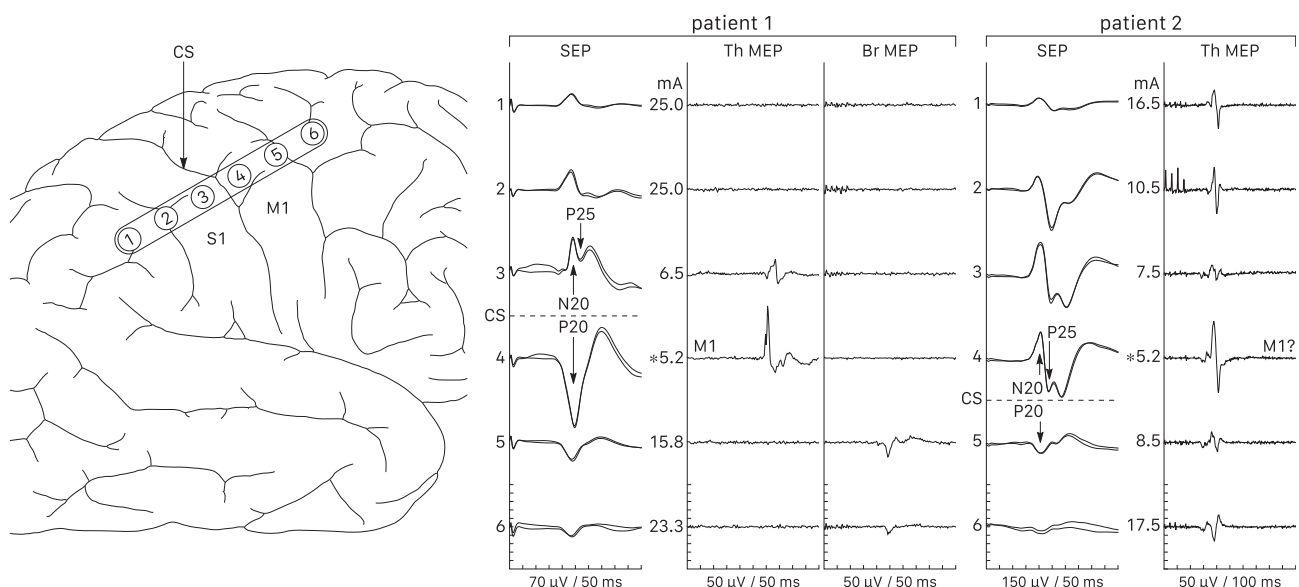


Fig 15. Median nerve cortical SEP mapping. CS, central sulcus; S1 and M1, sensory and motor gyri; Th, thenar; Br, brachioradialis. Patient 1 showed an N20/P20 phase reversal between electrodes 3 and 4 and a P25 at electrode 3. Lowest MEP threshold (*) with direct cortical pulse train stimulation confirmed M1 under electrode 4. Patient 2 showed a phase reversal between electrodes 4 and 5 and P25 at electrode 4, suggesting electrode 5 should be nearest M1. However, the lowest MEP threshold (*) was at electrode 4 and probe stimulation confirmed M1 under this electrode. Thus, it is inadvisable to rely solely on SEP mapping when M1 localization is critical.

For intracranial aneurysm surgery, the duration and extent of recovery of SEP deterioration with temporary clipping correlates with postoperative outcome, and recirculation within 9–10 min after SEP change may minimize deficit likelihood (Mizoi and Yoshimoto, 1993; Schick et al., 2005). However, there is no genuinely safe occlusion time as ischemic tolerance varies between patients. In addition, SEPs may be less reliable outcome predictors during ruptured aneurysm surgery (Wicks et al., 2012).

10.3. Posterior fossa surgery

Posterior fossa operations may risk brainstem injury and SEPs are useful for monitoring medial lemniscus integrity as one of several other monitoring modalities (Neuloh et al., 2008). Upper limb SEPs may be sufficient because lemniscus arm and leg fibers are close together. Reversible injury mechanisms such as compression, traction, or ischemia may cause reversible SEP deterioration. Irreversible injuries, such as hemorrhage or trauma may cause irreversible deterioration. Motor and other brainstem injuries sparing the medial lemniscus can occur without deterioration of SEPs that cover <20% of brainstem area (Fahlbusch and Strauss, 1991; Neuloh et al., 2009; Kodama et al., 2014; Slotty et al., 2017).

10.4. Orthopedic spine surgery

Orthopedic spine surgery is the oldest and most common indication for SEP monitoring even though motor deficits are the main concern. The original rationale was based on motor and sensory pathway proximity: cord compromise might affect both, thereby causing SEP deterioration and prompting intervention. Indeed, SEP monitoring alone halves the risk of motor injury (Nuwer et al., 1995). However, motor deficit without SEP warning or vice versa can occur because small lesions may damage only one or the other pathway (Lesser et al., 1986; Ben-David et al., 1987; Chatrian et al., 1988; Dawson et al., 1991; Nuwer et al., 1995; Minahan et al., 2001; Jones et al., 2003). Today, SEP monitoring mainly provides selective dorsal column assessment to complement MEPs. However, it may still be the major modality when MEPs are omitted, unobtainable, or too intermittent.

Three patterns of evoked potential deterioration due to spinal cord compromise have been reported (MacDonald et al., 2007; Tomé-Bermejo et al., 2014): MEP-only, indicating a unilateral or bilateral anterior cord syndrome; MEP and simultaneous or delayed SEP change, indicating a Brown-Sequard or transverse cord syndrome (e.g., Fig. 13B); and least often, SEP-only, indicating a unilateral or bilateral dorsal column syndrome (e.g., Fig. 14 C and D). Furthermore, unilateral upper limb SEP reduction with or without subsequent MEP deterioration detects peripheral nerve or brachial plexus conduction failure in 2–3% of scoliosis surgeries (e.g., Fig. 8). Thus, combined SEP/MEP monitoring is advisable.

Compression, traction or ischemia are the main spinal cord pathophysiologies of these surgeries and often resolve after intervening before time-dependent damage occurs. Thus, evoked potential deterioration is commonly reversible. Irreversible deterioration may still occur if intervention is delayed or the injury is irreversible.

10.5. Spinal neurosurgery

For intramedullary spinal cord tumor surgery, there are important but limited roles for SEPs. Surgeons use dorsal midline myelotomy to enter the cord with minimal trauma, but the tumor often obscures the anatomy. Consequently, mapping to find the midline may be advisable to reduce the likelihood of injury. This can be done by mapping dorsal column volleys with a small transverse 8-contact electrode if available, or by dorsal column stimulation

with scalp SEP or peripheral nerve recording (Quinones-Hinojosa et al., 2002; Yanni et al., 2010; Mehta et al., 2012; Simon et al., 2012; Nair et al., 2014). While SEP monitoring is also relevant, scalp responses often deteriorate or disappear after myelotomy (Fig. 1), which should not stop surgery at this early stage because it would cause an unsatisfactory oncological result. If SEPs remain stable, they may still be useful dorsal column monitors, but D-wave and muscle MEPs are the critical decision-making modalities (Kothbauer, 2002; Sala et al., 2006).

With extramedullary tumor and other spinal neurosurgeries above the conus, there is no myelotomy or intramedullary dissection. Consequently, SEP and MEP monitoring is similar to orthopedic spine surgery.

With tethered cord or cauda equina surgery, SEPs are an appropriate monitor of dorsal column integrity when surgery risks cord injury. However, many of these surgeries mainly risk L2–S5 root injuries, for which tibial nerve SEPs have a limited role because they are generated by only a few sensory roots, whereas multiple motor roots and sacral reflexes are of primary concern. Thus, triggered EMG mapping, sacral reflexes, and possibly MEPs are more important (Sala et al., 2013). One may consider omitting SEPs for infants or young children having impractically slow reproducibility.

10.6. Descending aortic procedures

Descending aortic procedures include open aneurysm or coarctation repair, and endovascular stenting or angioplasty. They risk spinal cord infarction and paraplegia by temporarily or permanently interrupting spinal cord blood flow. The goal of monitoring is to quickly detect cord ischemia and restore perfusion before infarction sets in (MacDonald and Dong (2008)). Efforts to do this with SEP monitoring may have benefitted some individual patients, but SEPs do not reduce the overall infarction risk. This is because spinal cord ischemia and infarction are centered in and sometimes limited to lumbosacral gray matter, especially the anterior horns. Consequently, SEPs conducted through dorsal white matter may be unaffected or show delayed deterioration. Furthermore, even when affected, subsequent SEP restoration does not exclude gray matter infarction. In contrast, MEPs conducted through lumbosacral anterior horn cells reliably detect cord ischemia that is frequently reversible through various interventions and there is evidence that MEP monitoring reduces infarction risk.

Nevertheless, SEPs facilitate MEP interpretation. Cubital or popliteal fossa response deterioration detects confounding limb ischemia that occurs frequently with open aneurysm repairs. Cortical SEPs can reveal systemic confounding factors or cerebral ischemia, and sometimes more severe transverse spinal cord ischemia. Thus, while a few programs have dispensed with SEPs, it may be advisable to include them.

11. Conclusion

Intraoperative SEPs provide valuable dorsal somatosensory system functional and localizing information, and complement MEP results. Application and interpretation require knowledge of relevant anatomy, blood supply, electrophysiology, and basic techniques. Recommended monitoring methodologies enhance efficacy by achieving fastest possible surgical feedback. They include TIVA or similarly favorable anesthesia to facilitate cortical responses and SEP optimization that employs highest-SNR derivations to enhance reproducibility and minimize averaging. Confounding factors must be excluded before issuing a warning. To adjust for baseline drift and reproducibility, the recommended adaptive warning criterion is visually obvious amplitude reduction

from recent pre-change values and clearly exceeding variability, particularly when abrupt and focal. Acquisition and interpretation require qualified personnel. Established indications include periorolandic, posterior fossa, and spinal neurosurgery, as well as orthopedic spine, cerebrovascular, and descending aortic surgery. Future advances could modify subsequent recommendations.

Funding

This work did not receive any specific grant from funding agencies in the public, commercial, or not-for-profit sectors.

References

- Acioly MA, Ebner FH, Hauser TK, Liebsch M, Carvalho CH, Gharabaghi A, et al. The impact of subdural air collection on intraoperative motor and somatosensory evoked potentials: fact or myth? *Acta Neurochir (Wien)* 2011;153:1077–85.
- Alcantara SD, Wuamett JC, Lantis JC, Ulkatan S, Bamberger P, Mendes D, et al. Outcomes of combined somatosensory evoked potential, motor evoked potential, and electroencephalography monitoring during carotid endarterectomy. *Ann Vasc Surg* 2014;28:665–72.
- Allison T, McCarthy G, Wood CC, Darcey TM, Spencer DD, Williamson PD. Human cortical potentials evoked by stimulation of the median nerve. I. Cytoarchitectonic areas generating short-latency activity. *J Neurophysiol* 1989;62:694–710.
- Allison T, McCarthy G, Wood CC, Jones SJ. Potentials evoked in human and monkey cerebral cortex by stimulation of the median nerve. A review of scalp and intracranial recordings. *Brain* 1991;114:2465–503.
- Allison T, McCarthy G, Luby M, Puce A, Spencer DD. Localization of functional regions of human mesial cortex by somatosensory evoked potential recording and by cortical stimulation. *Electroencephalogr Clin Neurophysiol* 1996;100:126–40.
- Alvarez LA, Jayakar P. Cortical stimulation with subdural electrodes: special considerations in infancy and childhood. *J Epilepsy* 1990;3(Suppl):125–30.
- American Clinical Neurophysiology Society. Guideline 9D: guidelines on short-latency somatosensory evoked potentials. *J Clin Neurophysiol* 2006;23:168–79.
- Basbaum AI, Jessell TM. The perception of pain. In: Kandel ER, Schwartz JH, Jessell TM, editors. *Principles of neural science*. 4th ed. New York: McGraw-Hill; 2000. p. 474–92.
- Ben-David B, Haller G, Taylor P. Anterior spinal fusion complicated by paraplegia. A case report of a false-negative somatosensory-evoked potential. *Spine* 1987;12:536–9.
- Berger MS. Functional mapping-guided resection of low-grade gliomas. *Clin Neurosurg* 1995;42:437–52.
- Bernard JM, Péréon Y, Fayet G, Guihéneuc P. Effects of isoflurane and desflurane on neurogenic motor- and somatosensory-evoked potential monitoring for scoliosis surgery. *Anesthesiology* 1996;85:1013–9.
- Burke D, Skuse NF, Lethlean AK. Cutaneous and muscle afferent components of the cerebral potential evoked by electrical stimulation of human peripheral nerves. *Electroencephalogr Clin Neurophysiol* 1981;51:579–88.
- Burke D, Hicks R, Stephen J, Woodforth I, Crawford M. Assessment of corticospinal and somatosensory conduction simultaneously during scoliosis surgery. *Electroencephalogr Clin Neurophysiol* 1992;85:388–96.
- Cakmur R, Towle VL, Mullan JF, Suarez D, Spire JP. Intra-operative localization of sensorimotor cortex by cortical somatosensory evoked potentials: from analysis of waveforms to dipole source modeling. *Acta Neurochir (Wien)* 1997;139:1117–24.
- Cedzich C, Taniguchi M, Schäfer S, Schramm J. Somatosensory evoked potential phase reversal and direct motor cortex stimulation during surgery in and around the central region. *Neurosurgery* 1996;38:962–70.
- Chatrjian GE, Berger MS, Wirch AL. Discrepancy between intraoperative SSEPs and postoperative function. Case report. *J Neurosurg* 1988;69:450–4.
- Chen Z. The effects of isoflurane and propofol on intraoperative neurophysiological monitoring during spinal surgery. *J Clin Monit Comput* 2004;18:303–8.
- Connolly JE. Hume Memorial lecture. Prevention of spinal cord complications in aortic surgery. *Am J Surg* 1998;176:92–101.
- Crossman AR, Neary D. Spinal cord: internal organization. In: Standring S, editor. *Gray's anatomy: the anatomical basis of clinical practice*. 40th ed. Philadelphia: Churchill Livingstone Elsevier; 2008. Chapter 18.
- Cruse R, Klem G, Lesser RP, Leuders H. Paradoxical lateralization of cortical potentials evoked by stimulation of posterior tibial nerve. *Arch Neurol* 1982;39:222–5.
- Dawson EG, Sherman JE, Kanim LE, Nuwer MR. Spinal cord monitoring. Results of the Scoliosis Research Society and the European Spinal Deformity Society survey. *Spine* 1991;16(8 Suppl):S361–4.
- Desmedt JE, Cheron G. Central somatosensory conduction in man: neural generators and interpeak latencies of the far-field components recorded from neck and right or left scalp and earlobes. *Electroencephalogr Clin Neurophysiol* 1980;50:382–403.
- Desmedt JE, Cheron G. Prevertebral (oesophageal) recording of subcortical somatosensory evoked potentials in man: the spinal P13 component and the dual nature of the spinal generators. *Electroencephalogr Clin Neurophysiol* 1981a;52:257–75.
- Desmedt JE, Cheron G. Non-cephalic reference recording of early somatosensory potentials to finger stimulation in adult or aging normal man: differentiation of widespread N18 and contralateral N20 from the prerolandic P22 and N30 components. *Electroencephalogr Clin Neurophysiol* 1981b;52:553–70.
- Duchowny M, Jayakar P. Functional cortical mapping in children. In: Devinsky O, Beric A, Dogali M, editors. *Electrical and magnetic stimulation of the brain and spinal cord*. New York: Raven Press; 1993. p. 149–54.
- Eisen A, Purves S, Hoirch M. Central nervous system amplification: its potential in the diagnosis of early multiple sclerosis. *Neurology* 1982;32:359–64.
- Fahlbusch R, Strauss C. Surgical significance of cavernous hemangioma of the brain stem. *Zentralbl Neurochir* 1991;52:25–32.
- Fitzgerald M. Spinal cord: ascending pathways. In: Fitzgerald M, editor. *Neuroanatomy: basic and clinical*. 2nd ed. London: Bailliere Tindall; 1992. p. 97–109.
- Florence G, Guerit J-M, Gueguen B. Electroencephalography (EEG) and somatosensory evoked potentials (SEP) to prevent cerebral ischaemia in the operating room. *Neurophysiol Clin* 2004;34:17–32.
- Forbes HJ, Allen PW, Waller CS, Jones SJ, Edgar MA, Webb PJ, et al. Spinal cord monitoring in scoliosis surgery. Experience with 1168 cases. *J Bone Joint Surg Br* 1991;73:487–91.
- Fukuda H, Sonoo M, Ishibashi M. Muscle afferent contributions to tibial nerve somatosensory evoked potentials investigated using knee stimulations. *Clin Neurophysiol* 2007;118:2104–11.
- Gandevia SC, Burke D. Saturation in human somatosensory pathways. *Exp Brain Res* 1984;54:582–5.
- Gandevia SC, Burke D, McKeon B. The projection of muscle afferents from the hand to cerebral cortex in man. *Brain* 1984;107:1–13.
- Gardner EP, Kandel ER, Touch. In: Kandel ER, Schwartz JH, Jessell TM, editors. *Principles of neural science*. 4th ed. New York: McGraw-Hill; 2000. p. 453–73.
- Gardner EP, Martin JH, Jessell TM. The bodily senses. In: Kandel ER, Schwartz JH, Jessell TM, editors. *Principles of neural science*. 4th ed. New York: McGraw-Hill; 2000. p. 431–52.
- Gilman S. Joint position sense and vibration sense: anatomical organisation and assessment. *J Neurol Neurosurg Psychiatr* 2002;73:473–7.
- Hahn JF, Lesser R, Klem G, Lueders H. Simple technique for monitoring intraoperative spinal cord function. *Neurosurgery* 1981;9:692–5.
- Halonon JP, Jones S, Shawkat F. Contribution of cutaneous and muscle afferent fibres to cortical SEPs following median and radial nerve stimulation in man. *Electroencephalogr Clin Neurophysiol* 1988;71:331–5.
- Halonon JP, Jones SJ, Edgar MA, Ransford AO. Conduction properties of epidurally recorded spinal cord potentials following lower limb stimulation in man. *Electroencephalogr Clin Neurophysiol* 1989;74:161–74.
- Holdefer R, MacDonald D, Skinner S. Somatosensory and motor evoked potentials as biomarkers for post-operative neurological status. *Clin Neurophysiol* 2015;126:857–65.
- Graham R, Mancher M, Wolman D, Greenfield S, Steinberg E, editors. *Institute of Medicine. Clinical practice guidelines we can trust*. Washington: The National Academies Press; 2011.
- Isley MR, Pearlman RC. Credentialing and competency policy statement for intraoperative neuromonitoring staff: American society of neurophysiological monitoring position statement. *Synergy* 2006;34:38–41.
- Jahangiri FR, Sherman JH, Sheehan J, Shaffrey M, Dumont AS, Vengrow M, et al. Limiting the current density during localization of the primary motor cortex by using a tangential-radial cortical somatosensory evoked potentials model, direct electrical cortical stimulation, and electrocorticography. *Neurosurgery* 2011;69:893–8.
- Jones SJ, Edgar MA, Ransford AO. Sensory nerve conduction in the human spinal cord: epidural recordings made during scoliosis surgery. *J Neurol Neurosurg Psychiatr* 1982;45:446–51.
- Jones SJ, Buonamassa S, Crockard HA. Two cases of quadriplegia following anterior cervical discectomy, with normal perioperative somatosensory evoked potentials. *J Neurol Neurosurg Psychiatr* 2003;74:273–6.
- Kalkman CJ, ten Brink SA, Been HD, Bovill JG. Variability of somatosensory cortical evoked potentials during spinal surgery. Effects of anesthetic technique and high-pass digital filtering. *Spine* 1991;16:924–9.
- Kiernan JA. Barr's the human nervous system: an anatomical viewpoint. 9th ed. Philadelphia: Lippincott Williams & Wilkins; 2009a. p. 61–78. Chapter 5, Spinal cord.
- Kiernan JA. Barr's the human nervous system: An anatomical viewpoint. 9th ed. Philadelphia: Lippincott Williams & Wilkins; 2009b. p. 283–301. Chapter 19, General sensory systems.
- Kodama K, Javadi M, Seifert V, Szelényi A. Conjoint SEP and MEP monitoring in resection of infratentorial lesions: lessons learned in a cohort of 210 patients. *J Neurosurg* 2014;121:1453–61.
- Koht A, Schütz W, Schmidt G, Schramm J, Watanabe E. Effects of etomidate, midazolam, and thiopental on median nerve somatosensory evoked potentials and the additive effects of fentanyl and nitrous oxide. *Anesth Analg* 1988;67:435–41.
- Kombos T. Somatosensory evoked potentials for intraoperative mapping of the sensorimotor cortex. In: Nuwer MR, editor. *Intraoperative monitoring of neural function. Handbook of clinical neurophysiology* 2008;vol. 8. Amsterdam: Elsevier; 2008. p. 211–7.
- Kothbauer KF. Motor evoked potential monitoring for intramedullary spinal cord tumor surgery. In: Deletis V, Shiels JL, editors. *Neurophysiology in neurosurgery: a modern intraoperative approach*. San Diego: Academic Press; 2002. p. 73–92.

- Kumabe T, Nakasato N, Nagamatsu K, Tominaga T. Intraoperative localisation of the lip sensory area by somatosensory evoked potentials. *J Clin Neurosci* 2005;12:66–70.
- Landgren S, Silfvenius H, Nucleus Z. The medullary relay in the projection path to the cerebral cortex of group I muscle afferents from the cat's hind limb. *J Physiol (Lond)* 1971;218:551–71.
- Langeron O, Vivien B, Paqueron X, Saillant G, Riou B, Coriat P, et al. Effects of propofol, propofol-nitrous oxide and midazolam on cortical somatosensory evoked potentials during sufentanil anaesthesia for major spinal surgery. *Br J Anaesth* 1999;82:340–5.
- Lee EK, Seyal M. Generators of short latency human somatosensory-evoked potentials recorded over the spine and scalp. *J Clin Neurophysiol* 1998;15:227–34.
- Lesser RP, Raudzens P, Lüders H, Nuwer MR, Goldie WD, Morris 3rd HH, et al. Postoperative neurological deficits may occur despite unchanged intraoperative somatosensory evoked potentials. *Ann Neurol* 1986;19:22–5.
- Lesser RP, Lüders H, Dinner DS, Hahn J, Morris H, Wyllie E, et al. The source of 'paradoxical lateralization' of cortical evoked potentials to posterior tibial nerve stimulation. *Neurology* 1987;37:82–8.
- Lockard BI, Kempe LG. Position sense in the lateral funiculus? *Neurol Res* 1988;10:81–6.
- López JR. Neurophysiologic intraoperative monitoring of pediatric cerebrovascular surgery. *J Clin Neurophysiol* 2009;26:85–94.
- Lopéz JR, Chang SD, Steinberg GK. The use of electrophysiological monitoring in the intraoperative management of intracranial aneurysms. *J Neurol Neurosurg Psychiatr* 1999;66:189–96.
- MacDonald DB. Individually optimizing posterior tibial somatosensory evoked potential P37 scalp derivations for intraoperative monitoring. *J Clin Neurophysiol* 2001;18:364–71.
- MacDonald DB, Deletis V. Safety issues during surgical monitoring. In: Nuwer MR, editor. *Intraoperative monitoring of neural function, Handbook of clinical neurophysiology* 2008;vol. 8. Amsterdam: Elsevier; 2008. p. 882–98.
- MacDonald DB, Dong CC. Spinal cord monitoring of descending aortic procedures. Nuwer Intraoperative monitoring of neural function, *Handbook of clinical neurophysiology* 2008;vol. 8. Amsterdam: Elsevier; 2008. p. 815–28.
- MacDonald DB, Janusz M. An approach to intraoperative neurophysiologic monitoring of thoracoabdominal aneurysm surgery. *J Clin Neurophysiol* 2002;19:43–54.
- MacDonald DB, Al Zayed Z, Khoudeir I, Stigsby B. Monitoring scoliosis surgery with combined multiple pulse transcranial electric motor and cortical somatosensory-evoked potentials from the lower and upper extremities. *Spine* 2003;28:194–203.
- MacDonald DB, Streletz LJ, Al-Zayed Z, Abdool S, Stigsby B. Intraoperative neurophysiologic discovery of uncrossed sensory and motor pathways in a patient with horizontal gaze palsy and scoliosis. *Clin Neurophysiol* 2004a;115:576–82.
- MacDonald DB, Stigsby B, Al Zayed Z. A comparison between derivation optimization and Cz-FPz for posterior tibial P37 somatosensory evoked potential intraoperative monitoring. *Clin Neurophysiol* 2004b;115:1925–30.
- MacDonald DB, Al Zayed Z, Stigsby B. Tibial somatosensory evoked potential intraoperative monitoring: recommendations based on signal to noise ratio analysis of popliteal fossa, optimized P37, standard P37, and P31 potentials. *Clin Neurophysiol* 2005;116:1858–69.
- MacDonald DB, Al Zayed Z, Al Saddigi A. Four-limb muscle motor evoked potential and optimized somatosensory evoked potential monitoring with decussation assessment: results in 206 thoracolumbar spine surgeries. *Eur Spine J* 2007;16 (Suppl 2):171–87.
- MacDonald DB, Al-Zayed Z, Stigsby B, Al-Homoud I. Median somatosensory evoked potential intraoperative monitoring: recommendations based on signal-to-noise ratio analysis. *Clin Neurophysiol* 2009;120:315–28.
- Malcharek MJ, Kulpok A, Deletis V, Ulkatan S, Sablotzki A, Hennig G, et al. Intraoperative multimodal evoked potential monitoring during carotid endarterectomy: a retrospective study of 264 patients. *Anesth Analg* 2015;120:1352–60.
- Marcus ML, Heistad DD, Ehrhardt JC, Abboud FM. Regulation of total and regional spinal cord blood flow. *Circ Res* 1977;41:128–34.
- Markand ON, Warren C, Mallik GS, King RD, Brown JW, Mahomed Y. Effects of hypothermia on short latency somatosensory evoked potentials in humans. *Electroencephalogr Clin Neurophysiol* 1990;77:416–24.
- Mawad ME, Rivera V, Crawford S, Ramirez A, Breitbach W. Spinal cord ischemia after resection of thoracoabdominal aortic aneurysms: MR findings in 24 patients. *AJNR Am J Neuroradiol* 1990;11:987–91.
- McCarthy G, Allison T, Spencer DD. Localization of the face area of human sensorimotor cortex by intracranial recording of somatosensory evoked potentials. *J Neurosurg* 1993;79:874–84.
- Mehta AI, Mohrhaus CA, Husain AM, Karikari IO, Hughes B, Hodges T, et al. Dorsal column mapping for intramedullary spinal cord tumor resection decreases dorsal column dysfunction. *J Spinal Disord Tech* 2012;25:205–9.
- Minahan RE, Sepkuty JP, Lesser RP, Sponseller PD, Kostuik JP. Anterior spinal cord injury with preserved neurogenic 'motor' evoked potentials. *Clin Neurophysiol* 2001;112:1442–50.
- Miura T, Sonoo M, Shimizu T. Establishment of standard values for the latency, interval and amplitude parameters of tibial nerve somatosensory evoked potentials (SEPs). *Clin Neurophysiol* 2003;114:1367–78.
- Mizoi K, Yoshimoto T. Permissible temporary occlusion time in aneurysm surgery as evaluated by evoked potential monitoring. *Neurosurgery* 1993;33:434–40.
- Nair D, Kumaraswamy VM, Braver D, Kilbride RD, Borges LF, Simon MV. Dorsal column mapping via phase reversal method: the refined technique and clinical applications. *Neurosurgery* 2014;74:437–46.
- Netherton BL, Stecker MM, Patterson T. Mechanisms of electrode induced injury. Part 3: practical concepts and avoidance. *Am J Electroneurodiagnostic Technol* 2007;47:257–63.
- Neuloh G, Strauss C, Schramm J. Mapping and monitoring for brainstem lesions. In: Nuwer MR, editor. *Intraoperative monitoring of neural function, Handbook of clinical neurophysiology*. Amsterdam: Elsevier; 2008. p. 522–33.
- Neuloh G, Bogucki J, Schramm J. Intraoperative preservation of corticospinal function in the brainstem. *J Neurol Neurosurg Psychiatry* 2009;80:417–22.
- Niu J, Ding L, Li JJ, Kim H, Liu J, Li H, et al. Modality-based organization of ascending somatosensory axons in the direct dorsal column pathway. *J Neurosci* 2013;33:17691–709.
- Nuwer MR, Dawson EC. Intraoperative evoked potential monitoring of the spinal cord. A restricted filter, scalp method during Harrington instrumentation for scoliosis. *Clin Orthop Relat Res* 1984;42–50.
- Nuwer MR, Packwood JW. Somatosensory evoked potential monitoring with scalp and cervical recording. In: Nuwer MR, editor. *Intraoperative monitoring of neural function, Handbook of clinical neurophysiology* 2008;vol. 8. Amsterdam: Elsevier; 2008. p. 180–9.
- Nuwer MR, Banoczi WR, Cloughesy TF, Hoch DB, Peacock W, Levesque MF, et al. Topographic mapping of somatosensory evoked potentials helps identify motor cortex more quickly in the operating room. *Brain Topogr* 1992;5:53–8.
- Nuwer MR, Dawson EG, Carlson LG, Kanim LE, Sherman JE. Somatosensory evoked potential spinal cord monitoring reduces neurologic deficits after scoliosis surgery: results of a large multicenter survey. *Electroencephalogr Clin Neurophysiol* 1995;96:6–11.
- Nuwer MR, Comi G, Emerson R, Fuglsang-Frederiksen A, Guérit JM, Hinrichs H, et al. IFCN standards for digital recording of clinical EEG. International Federation of Clinical Neurophysiology. *Electroencephalogr Clin Neurophysiol* 1998;106:259–61.
- Nwachuku EL, Balzer JR, Yabes JG, Habeych ME, Crammond DJ, Thirumala PD. Diagnostic value of somatosensory evoked potential changes during carotid endarterectomy: a systematic review and meta-analysis. *JAMA Neurol* 2015;72:73–80.
- Pathak KS, Amaddio MD, Scoles PV, Shaffer JW, Mackay W. Effects of halothane, enflurane, and isoflurane in nitrous oxide on multilevel somatosensory evoked potentials. *Anesthesiology* 1989;70:207–12.
- Patterson T, Stecker MM, Netherton BL. Mechanisms of electrode induced injury. Part 2: clinical experience. *Am J Electroneurodiagnostic Technol* 2007;47:93–113.
- Pearson K, Gordon J. Spinal reflexes. In: Kandel ER, Schwartz JH, Jessell TM, editors. *Principles of neural science*. 4th ed. New York: McGraw-Hill; 2000. p. 714–37.
- Porkkala T, Jääntti V, Kaukinen S, Häkkinen V. Nitrous oxide has different effects on the EEG and somatosensory evoked potentials during isoflurane anaesthesia in patients. *Acta Anaesthesiol Scand* 1997a;41:497–501.
- Porkkala T, Kaukinen S, Häkkinen V, Jääntti V. Median nerve somatosensory evoked potentials during isoflurane anaesthesia. *Can J Anaesth* 1997b;44:963–8.
- Quinones-Hinojosa A, Gulati M, Lyon R, Gupta N, Yingling C. Spinal cord mapping as an adjunct for resection of intramedullary tumors: surgical technique with case illustrations. *Neurosurgery* 2002;51:1199–206.
- Riviello JJ, Kull L, Troup C, Holmes GL. Cortical stimulation in children: techniques and precautions. *Tech Neurosurg* 2001;7:12–8.
- Romstöck J, Fahlbusch R, Ganslandt O, Nimsky C, Strauss C. Localisation of the sensorimotor cortex during surgery for brain tumours: feasibility and waveform patterns of somatosensory evoked potentials. *J Neurol Neurosurg Psychiatr* 2002;72:221–9.
- Ropper AH, Brown RH. Adams and Victor's principles of neurology. 8th ed. New York: McGraw-Hill; 2005a. p. 111–28. Chapter 8, Pain.
- Ropper AH, Brown RH. Adams and Victor's principles of neurology. 8th ed. New York: McGraw-Hill; 2005b. p. 129–43. Chapter 9, Other somatic sensation.
- Ross RT. Dissociated loss of vibration, joint position and discriminatory tactile senses in disease of spinal cord and brain. *Can J Neurol Sci* 1991;18:312–20.
- Ross ED, Kirkpatrick JB, Lastimoso AC. Position and vibration sensations: functions of the dorsal spinocerebellar tracts? *Ann Neurol* 1979;5:171–6.
- Rossini PM, Cracco RQ, Cracco JB, House WJ. Short latency somatosensory evoked potentials to peroneal nerve stimulation: scalp topography and the effect of different frequency filters. *Electroencephalogr Clin Neurophysiol* 1981;52:540–52.
- Sahaya K, Pandey AS, Thompson BG, Bush BR, Minecan DN. Intraoperative monitoring for intracranial aneurysms: the Michigan experience. *J Clin Neurophysiol* 2014;31:563–7.
- Sala F, Palandri G, Basso E, Lanteri P, Deletis V, Faccioli F, et al. Motor evoked potential monitoring improves outcome after surgery for intramedullary spinal cord tumors: a historical control study. *Neurosurgery* 2006;58:1129–43.
- Sala F, Squintani G, Tramontano V, Arcaro C, Faccioli F, Mazza C. Intraoperative neurophysiology in tethered cord surgery: techniques and results. *Childs Nerv Syst* 2013;29:1611–24.
- Schick U, Döhnert J, Meyer J-J, Vitzthum H-E. Effects of temporary clips on somatosensory evoked potentials in aneurysm surgery. *Neurocrit Care* 2005;2:141–9.
- Schubert A, Licina MG, Lineberry PJ. The effect of ketamine on human somatosensory evoked potentials and its modification by nitrous oxide. *Anesthesiology* 1990;72:33–9.
- Sebel PS, Erwin CW, Neville WK. Effects of halothane and enflurane on far and near field somatosensory evoked potentials. *Br J Anaesth* 1987;59:1492–6.

- Simon MV. Intraoperative neurophysiologic sensorimotor mapping and monitoring in supratentorial surgery. *J Clin Neurophysiol* 2013;30:571–90.
- Simon MV, Chiappa KH, Borges LF. Phase reversal of somatosensory evoked potentials triggered by gracilis tract stimulation: case report of a new technique for neurophysiologic dorsal column mapping. *Neurosurgery* 2012;70:E783–8.
- Sloan T. Anesthesia and intraoperative neurophysiological monitoring in children. *Childs Nerv Syst* 2010;26:227–35.
- Sloan TB. Anesthetic effects on electrophysiologic recordings. *J Clin Neurophysiol* 1998;15:217–26.
- Sloan TB, Heyer EJ. Anesthesia for intraoperative neurophysiologic monitoring of the spinal cord. *J Clin Neurophysiol* 2002;19:430–43.
- Sloan TB, Koht A. Depression of cortical somatosensory evoked potentials by nitrous oxide. *Br J Anaesth* 1985;57:849–52.
- Sloan TB, Ronai AK, Toleikis JR, Koht A. Improvement of intraoperative somatosensory evoked potentials by etomidate. *Anesth Analg* 1988;67:582–5.
- Sloan TB, Toleikis JR, Toleikis SC, Koht A. Intraoperative neurophysiological monitoring during spine surgery with total intravenous anesthesia or balanced anesthesia with 3% desflurane. *J Clin Monit Comput* 2015;29:77–85.
- Sloty PJ, Abdulazim A, Kodama K, Javadi M, Hänggi D, Seifert V, et al. Intraoperative neurophysiological monitoring during resection of infratentorial lesions: the surgeon's view. *J Neurosurg* 2017;126:281–8.
- Stecker MM, Patterson T, Netherton BL. Mechanisms of electrode induced injury. Part 1: theory. *Am J Electroneurodiagnostic Technol* 2006;46:315–42.
- Sutter M, Deletis V, Dvorak J, Eggspuehler A, Grob D, Macdonald D, et al. Current opinions and recommendations on multimodal intraoperative monitoring during spine surgeries. *Eur Spine J* 2007;16(Suppl 2):S232–7.
- Szelényi A, Bueno de Camargo A, Flamm E, Deletis V. Neurophysiological criteria for intraoperative prediction of pure motor hemiplegia during aneurysm surgery. Case report. *J Neurosurg* 2003;99:575–8.
- Taniguchi M, Nadstawek J, Pechstein U, Schramm J. Total intravenous anesthesia for improvement of intraoperative monitoring of somatosensory evoked potentials during aneurysm surgery. *Neurosurgery* 1992;31:891–7.
- Tomé-Bermejo F, Garrido E, Glasby M, Thinn S. Rare true-positive isolated SSEP loss with preservation of MEPs response during scoliosis correction. *Spine* 2014;39:E60–3.
- Vulliemoz S, Raineteau O, Jabaudon D. Reaching beyond the midline: why are human brains cross wired? *Lancet Neurol* 2005;4:87–99.
- Watanabe E, Schramm J, Schneider W. Effect of a subdural air collection on the sensory evoked potential during surgery in the sitting position. *Electroencephalogr Clin Neurophysiol* 1989;74:194–201.
- Weston P. Anterior tibial compartment syndrome post scoliosis surgery. *Neuromonitoring list, neuromon-1 log0204* [Internet] [Internet]. *neuromon-1 log0204*. 2002. Available from: www.neuromon.com [accessed 11 Nov 2002].
- Wicks RT, Pradilla G, Raza SM, Hadelsberg U, Coon AL, Huang J, et al. Impact of changes in intraoperative somatosensory evoked potentials on stroke rates after clipping of intracranial aneurysms. *Neurosurgery* 2012;70:1114–24.
- Wiedemayer H, Schaefer H, Armbruster W, Miller M, Stolke D. Observations on intraoperative somatosensory evoked potential (SEP) monitoring in the semi-sitting position. *Clin Neurophysiol* 2002;113:1993–7.
- Wiedemayer H, Sandalcioglu IE, Regel J, Armbruster W, Schaefer H, Stolke D. Enhanced stability of somatosensory evoked potentials attained in the median nerve by using temporal electrodes for intraoperative recording in patients in the semi-sitting position. *J Neurosurg* 2003;99:986–90.
- Wolfe DE, Drummond JC. Differential effects of isoflurane/nitrous oxide on posterior tibial somatosensory evoked responses of cortical and subcortical origin. *Anesth Analg* 1988;67:852–9.
- Wood CC, Spencer DD, Allison T, McCarthy G, Williamson PD, Goff WR. Localization of human sensorimotor cortex during surgery by cortical surface recording of somatosensory evoked potentials. *J Neurosurg* 1988;68:99–111.
- Yanni DS, Ulkatan S, Deletis V, Barrenechea JJ, Sen C, Perin NI. Utility of neurophysiological monitoring using dorsal column mapping in intramedullary spinal cord surgery. *J Neurosurg Spine* 2010;12:623–8.
- York DH. Somatosensory evoked potentials in man: differentiation of spinal pathways responsible for conduction from the forelimb vs hindlimb. *Prog Neurobiol* 1985;25:1–25.