

Contents lists available at ScienceDirect

Respiratory Medicine Case Reports

journal homepage: www.elsevier.com/locate/rmcr

Case report

Structured Light Plethysmography (SLP): Management and follow up of a paediatric patient with pneumonia



Michele Ghezzi ^a, Laura Tenero ^b, Michele Piazza ^{b,*}, Alessandro Bodini ^b,
Giorgio Piacentini ^b

^a Paediatric Asthma and Cough Center, Policlinico San Pietro, Bergamo, Italy

^b University of Verona, Department of Surgery, Dentistry, Paediatrics and Gynaecology, Pediatrics Section, Verona, Italy

ARTICLE INFO

Article history:

Received 16 December 2016

Accepted 3 June 2017

Keywords:

Imaging

Pulmonary function testing (PFT)

Respiratory technology

Pulmonary physiology

Pneumonia

ABSTRACT

Structured Light Plethysmography (SLP) is a non-invasive method to study chest and abdominal movement during breathing and can identify abnormal contributions of the different regions of the chest.

M.D hospitalized for pneumonia, underwent SLP and spirometry at admission (T0), after 48 hours (T1), and after one month (T2). SLP parameters showed expiratory flow limitation, information consistent with the spirometric parameters collected, and reduced motion in the area effected by pneumonia, with improvement and normalization at T1 and T2.

This method gave useful information about the contribution to the respiratory movement of the lung area affected by pneumonia so we can speculate a possible use in the follow-up of children affected by pneumonia or other respiratory diseases, and who are not able to perform a spirometric test.

© 2017 The Authors. Published by Elsevier Ltd. This is an open access article under the CC BY-NC-ND license (<http://creativecommons.org/licenses/by-nc-nd/4.0/>).

1. Introduction

Structured Light Plethysmography (SLP) is a new non-invasive method that captures and records real-time functional images of chest and abdominal movement, which may allow a better understanding of patient respiratory function. The system measures breathing motion using a grid of light, tracked by a digital vision system of 2 cameras. Thoraco-abdominal (TA) wall movement during breathing is analyzed and displayed in terms of regional movement parameters as well as a 3D-reconstruction [1].

In addition to showing the breathing pattern of the patient on a TA wall displacement-time graph and in a dynamic 3D-representation, the SLP tidal breathing equivalent of flow/volume graph is available for immediate identification of inspiratory or expiratory flow limitation. It is also possible to subdivide the 3D-representation to provide both graphical curves and numerical parameters for selected regions, to allow examination of

abnormal contribution to the TA displacement of the different regions of the chest.

It has been shown that SLP is able to detect a dynamic change in right compared to left thoracic wall motion [2]. A reduction in chest wall motion was apparent after thoracic surgery on the side of the incision and this was especially marked in patients undergoing a lobectomy rather than a wedge resection [1].

We propose that this new technique could have a potential application, in the follow-up of patients affected by acute pulmonary disease [3].

2. Materials and methods

M.D., 15 years old, was hospitalized in the Paediatric Department of Verona University for left superior lobar pneumonia. At admission, M.D. had persistent fever and cough even though antibiotic therapy (amoxicillin and clavulanic acid) had started 5 days before.

SLP (Thora-3Di, Pneumacare Ltd) was performed for 2 minutes at admission (T0), after 48 hours from the start of therapy with ceftriaxone and clarithromycin (T1), and after one month (T2). Chest radiographies were performed at admission and after one month to assess the parenchymal resolution of the pneumonia.

* Corresponding author.

E-mail address: michele.piazza@univr.it (M. Piazza).

Table 1A
Respiratory function values at T0, T1 and T2.

	T0		T1		T2	
	Pre β 2	Post β 2	Pre β 2	Post β 2	Pre β 2	Post β 2
FEV ₁ %	81.9%	85.2%	80.8%	89.3%	125.2%	123.4%
FVC %	79.7%	77.4%	75.7%	80.5%	112.9%	109.9%
FEV ₁ /FVC %	101.7%	108.9%	105.5%	109.8%	109.7%	111.0%
MMEF ₇₅₋₂₅ %	39.7%	80.8%	73.1%	89.1%	129.0%	126.4%

Table 1B
SLP data collected at time T0, T1 and T2.

	T0	T1	T2
IE50	1.87	1.33	1.10
Relative expired left	44%	46%	52%
Relative expired right	56%	54%	48%
Principal angle (left VS right)	-6.4°	-4.4°	2.0°
Principal angle (upper left VS upper right)	-15.5°	-7.2°	-2.1°

The following SLP parameters were considered:

- IE50: the ratio of inspiratory flow at 50% of tidal volume (VT) to expiratory flow at 50% of VT, where VT is taken to be the exhaled chest wall movement, and flow is taken to be the time-derivative of chest wall movement. Increased value of IE50 suggests expiratory flow limitation;
- Relative Expired Contribution: the ratio of a region's expired movement change to the tidal volume, where VT is taken to be the total exhaled chest wall displacement, averaged over all breaths in the current selection; in this case we have taken into consideration the Relative Expired Contribution between Right and Left side.
- Principal Angle: it is the angle of the dominant axis of the Konno-Mead (KM) loop relative to the 45° line [4]. It provides information similar to Relative Expired Contribution, and show comparison in the contribution of different region. In this case we have taken into consideration the Principal Angle between the Left Side VS Right Side, and between Upper Left Side VS Upper Right Side using the facility in the device software to select and compare a customized regions.

At T0, the patient showed stable general conditions, body temperature 38 °C, respiratory rate 24/min and oxygen saturation 95%. Crackles and rhonchi were noted at the upper left lung field, both front and rear.

Laboratory data revealed mild leukocytosis (white blood cell count 8.680/mm³) and C-reactive protein increased (77 mg/l).

At T0 a spirometry was performed with FEV₁ 81.9% and negative result of the bronchodilation reversibility test (complete results shown in Table 1).

SLP was performed and, for the 3 parameters we took into consideration, the following data were observed: an increased value of the IE50 (1.87) respect to standard normality value around 1.20 suggesting the presence of a condition of expiratory flow limitation; a Relative Expired Contribution of Left 44% and Right 56% showing a difference between the total right and left side that for healthy patients should be equal; a Principal Angle of -6.4° showing a lower activity of the Left side.

In addition, a Principal angle of -15.5° showed a lower activity in the custom area of upper left side, that involved by pneumonia (complete results shown in Table 1, Fig. 1).

Antibiotic therapy with ceftriaxone and clarithromycin was started. M.D. had a progressive resolution of fever, improvement chest objectivity and also the oxygen saturation normalized.

After 48 hours from the start of the therapy (T1) a spirometry was repeated with FEV₁ 80.8% and positive result of the bronchodilation test. At T1, SLP before bronchodilation showed a lower value of IE50 (1.33), suggesting an improvement in the expiratory flow limitation; a more symmetrical Relative Expired Contribution of Left 46% and Right 54% and a Principal Angle of -4.4°, and also between the Upper left side VS Upper right side a Principal Angle of -7.2°, suggesting the improvement of activity of area interested by the pneumonia (Fig. 1).

Because of the normalization of the general conditions and of the oxygen saturation after 3 days the patient was discharged.

At T2 chest X-ray was repeated and showed parenchymal resolution of the pneumonia; a spirometry was repeated with normalization of FEV₁ 125.2%. SLP evaluation indicated normalization of IE50% (1.10); a normalized contribution between Left and Right side (Relative Expired Left 48% Right 52%) and a more balanced activity between the 2 upper sides (Fig. 1).

3. Conclusions

SLP was able to give information consistent with spirometric parameter, i. e, both FEV₁ and IE50 were high at the admission and showed progressive normalization. This method also gave useful information about the contribution to the respiratory movement of the lung area affected by the pneumonia and the normalization

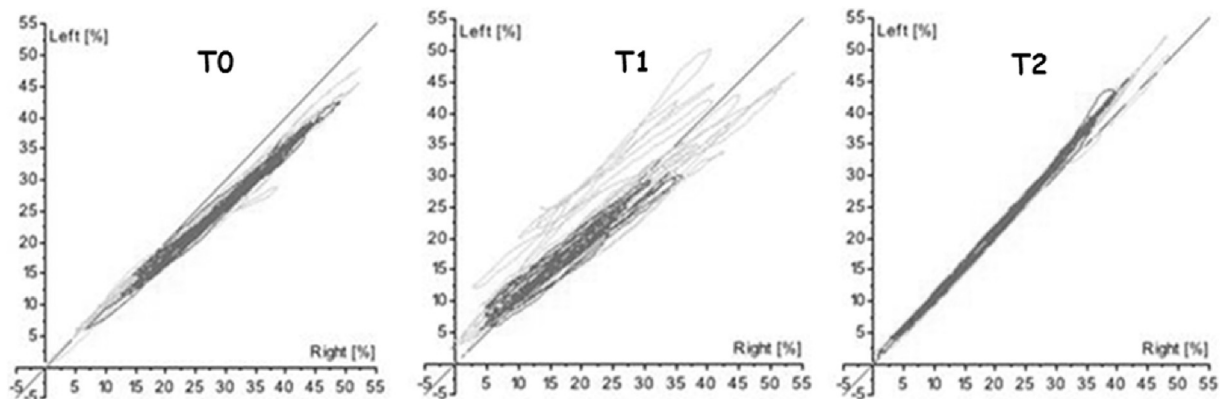


Fig. 1. Komno-Mead plot at T0, T1 and T2.

of this parameter with the therapy managed, through the analysis of the change in left compared to right thoracic motion. The data collected by SLP are consistent with radiological findings. Therefore, it is tempting to speculate a possible use of SLP in the follow up of paediatric patients affected by acute pneumonia, to evaluate the functional improvement of the lung area affected by the disease.

This new method could be proposed to potentially evaluate the effectiveness of the therapeutic procedure in patients affected by pneumonia, reducing RX exposure in the follow-up.

SLP requires minimal patient collaboration and is not invasive, allowing respiratory function analysis in patient populations incapable of performing spirometry, for any reasons (neurological pathologies or age).

The finding from this case report warrants further studies designed to assess normal values in paediatric patients and to evaluate the potential use of SLP in the follow-up of children with pneumonia.

Conflict of interest statement

No conflicts exist for the specified authors. This research did not receive any specific grant from funding agencies in the public, commercial, or not-for-profit sectors.

References

- [1] G. Elshafiea, P. Kumarb, S. Motamedi Fakhrc, R. Ilesc, R.C. Wilson, B. Naidua, Measuring changes in chest wall motion after lung resection using structured light plethysmography: a feasibility study, *Interact. Cardiovasc. Thorac. Surg.* 23 (4) (2016 Oct) 544–547.
- [2] A. Peacock, A. Gourlay, D. Denison, Optical measurement of the change in trunk volume with breathing, *Bull. Eur. Physiopathol. Respir.* 21 (2) (1985 Mar-Apr) 125–129.
- [3] Juliet Usher-Smith, Richard Wareham, J. Lasenby, J. Cameron, P. Bridge, R. Iles, Structured light plethysmography in infants and Children: a pilot study. *RCPCH York 2009, Arch. Dis. Child.* 94 (Suppl) (2009) A38–A40.
- [4] K. Konno, et al., Measurement of separate volume changes of rib cage and abdomen during breathing, *J. Appl. Physiol.* 22 (1967) 407–422.