

# CT-guided radiofrequency ablation of osteoid osteoma using a multi-tined expandable electrode system

Alessandro Costanzo<sup>1</sup>, Andrea Sandri<sup>1</sup>, Dario Regis<sup>1</sup>, Giacomo Trivellin<sup>2</sup>, Silvia Pierantoni<sup>1</sup>, Elena Samaila<sup>1</sup>, Bruno Magnan<sup>1</sup>

<sup>1</sup>Department of Orthopaedic Surgery, AOUI, Polo Chirurgico P. Confortini, Verona, Italy; <sup>2</sup>Department of Orthopaedic Surgery, Casa di Cura Pederzoli (Peschiera Del Garda), Verona, Italy

**Summary.** *Background and aim of the work:* Radiofrequency ablation (RFA) is the gold standard for the treatment of symptomatic osteoid osteoma (OO) as RFA yields both a high success and low complication rate. It has been widely utilized over the years, but recurrences of OO after this treatment have been documented. These recurrences may be the result of various factors, including incomplete tumor ablation, and are significantly higher in lesions greater than 10 mm. Thus, the need to induce thermal ablation in a wider area led us to use a Multi-Tined Expandable Electrode System (MTEES). In this study we examined the efficacy and safety of RFA using a MTEES in symptomatic OO. *Methods:* Between January 2005 and June 2007, 16 patients with symptomatic OO were treated by CT-guided percutaneous RFA using a MTEES. The diameter of OO ranged from 6 to 15 mm (mean  $10\pm 2.6$  mm). Patients were evaluated for clinical outcomes, complications and recurrence. Pain evaluation was assessed preoperatively, 2 weeks postoperatively and at last follow-up. *Results:* Clinical follow-up was available for all patients at a mean of 84.3 months (range 73-96 months). Mean preoperative VAS score was 7.4 (range 5-9), two weeks after the procedure mean VAS score was 0.3 (range 0-1) with a mean change of -7.06 points ( $p < 0.0001$ ). At the last follow-up a complete relief from pain has been observed in all patients. No major and minor complications were observed nor recurrences. *Conclusions:* RFA using a MTEES has been effective, safe and reliable for the treatment of OOs. This system, by increasing the size of the necrosis, could be a viable alternative to the single needle electrode in lesions larger than 10 mm, reducing the risk of recurrence. ([www.actabiomedica.it](http://www.actabiomedica.it))

**Key words:** osteoid osteoma, radiofrequency ablation, multi-tined expandable electrode system

## Introduction

Osteoid osteoma (OO) is a small, benign, osteoblastic lesion that appears primarily in young patients (1-3). Even though OO is a benign lesion, surgical treatment may be necessary if pain is persistent.

In the past, open “en bloc” surgical excision has been considered the gold standard for treatment of OO with an overall success of 88% (4-6). Disadvantages of open surgical procedure include a large bone and soft tissue damage (3). Furthermore, wider resection of the

lesion may cause a bone defect that becomes a zone of lower mechanical resistance which, if subjected to stresses early, may create a fracture (7).

In the last two decades, percutaneous CT-guided procedures have been developed for the treatment of OO's. Some authors reported percutaneous drill resection with a success rate similar to the open techniques, from 84% to 100% (8-10). However, this technique is associated with a high number of complications, up to 24%, represented mainly by fractures and infections (7).

Currently, radiofrequency ablation (RFA) is the gold standard in the treatment of OO with high success and low complication rates. The active electrode needle tip is able to induce thermal coagulative necrosis of the lesion through a controlled increase of the temperature (11-13).

Recurrence rate of the lesion, after open or percutaneous surgery, is related to the presence of residual areas of nidus. In RFA, the main risk factor for recurrence is the non-optimal positioning of the electrode needle and larger OO's. In lesions greater than 10 mm reposition of the electrode needle and multiple ablations are recommended to reduce the risk of recurrence (14-16).

The need to induce thermal ablation in a wider area, especially in lesions larger than 10 mm, led us to use a multi-tined expandable electrode system (MTEES). It consists of a central straight-needle cannula that is used to deploy an array of curved electrode tines from the tip to the adjacent tissue, which allows a wider coagulative necrosis of the lesion.

## Objective

The aim of this retrospective study is to examine the efficacy and safety of RFA using a MTEES in patients with symptomatic OO.

## Methods

Between January 2005 and June 2007, 16 patients (10M, 6F) with symptomatic OO's were treated by CT-guided percutaneous RFA using a MTEES. The average age at surgery was  $19 \pm 3.3$  years (range 14-26 years). We detected 10 lesions in the femur (62.5%) and 6 (37.5%) in the tibia. The side mostly affected was the left (10 cases). The mean duration of pain before the procedure was  $12.5 \pm 5.3$  months (range 6-24 months). Medical records of patients were analyzed retrospectively after ethics committee approval. No histological diagnosis has been performed in our patients due to the typical clinical and radiological findings. The distance from skin to the bone ranged from 4.1 cm to 8.3 cm (mean 6.5 cm, SD 1.8 cm). The di-

ameter of OO ranged from 6 to 15 mm (mean  $10 \pm 2.6$  mm): size greater than 15 mm was considered as exclusion criteria.

As inclusion criteria, we selected patients with a minimum distance of the bone lesion from the skin over 4 cm to prevent the risk of cutaneous and thermal lesions. Patients data is described in Table 1.

All patients had mainly nocturnal pain with positive temporary response to NSAIDs. Plain radiography and computed tomography (CT) scan showed a central radiolucent nidus surrounded by reactive bone sclerosis.

The procedures were performed using CT (Somatom Plus 64, Siemens Medical Solutions, Forchheim, Germany) under general anesthesia.

To perform RFA we used the RITA system (RITA Medical Systems, Mountain View, California, USA) composed of a radiofrequency monopolar generator 150-200W (Rita 1500 X, AngioDynamics Incorporated) and a needle electrode 14G with nine expandable active hooks and five thermocouples (monopolar Rita Starburst XL). The needle electrode allows controlled release of nine metal hooks that represent the active part that transmits energy. The tines are deployed and retracted with a simple helical rotation of the hub. Thermocouples placed at the tips of five prongs of the nine-array needle-electrode enabled continuous real-time monitoring of the actual temperatures at the tips. When deployed, the tines function as antennae, expanding and concentrating the current density and predictably enlarging the lesion.

Before the procedure, prothrombin time and international normalized ratio values were checked. In addition, whole blood count, allergy and anesthesia status were evaluated. All patient received preoperative short-term antibiotic prophylaxis with Cefamezin 2 g.

A CT scan was performed to localize the lesion and identify the optimal entry point. Two adhesive grounding pads were placed on the patient. A sterile field was prepared with povidone-iodine (10%) solution. A 2.2-mm Kirschner wire was inserted into the center nidus and then advanced and anchored about an inch and a half deeply in the bone (Fig. 1a). A 2 cm skin incision and release adjacent soft tissue were performed at the K-wire entry point in order to ease the insertion of a 5 mm cannulated drill with the K-wire as a guide (Fig. 1b). Once verified the position of

**Table 1.** Clinical data

Patient	Age (yrs)	Gender	Side	Location	Size (mm)	Duration of pain (mo)	FU* (mo)
1	15	M	Right	Femur	11	12	74
2	18	M	Right	Femur	9	7	80
3	16	F	Right	Tibia	6	9	86
4	22	M	Left	Tibia	8	6	90
5	19	F	Right	Femur	11	8	75
6	14	F	Left	Femur	9	9	96
7	18	M	Left	Femur	7	11	94
8	22	M	Left	Tibia	13	20	90
9	26	M	Left	Tibia	12	9	88
10	24	M	Left	Femur	7	24	80
11	20	F	Left	Femur	10	15	73
12	22	M	Right	Femur	11	16	81
13	18	M	Right	Tibia	8	12	78
14	17	M	Left	Femur	14	20	94
15	18	F	Left	Femur	15	14	79
16	20	F	Left	Tibia	12	8	91
Minimum	14	M:10	Left:10	Femur: 10	6	6	73
Maximum	26	F:6	Right:6	Tibia: 6	15	24	96
Average	19.3				10.2	12.5	84.3
SD **	3.3				2.6	5.3	7.7

\* FU: follow up; \*\* SD: standard deviation

the cannulated drill on the k-wire and the contact with the bone, a 5-mm diameter hole was drilled through the nidus using an electrical orthopedic drill under CT-guidance to create an optimal cavity to receive the multi-tined expandable electrode (Fig. 1c). After the removal of cannulated drill and k-wire, the dispersive pads were connected to the generator to close the circuit and disperse the heat. The multi-tined expandable electrode was placed in its closed configuration at the center of the previously drilled hole (Fig. 1d). Once connected to the radiofrequency generator, the electrode tines were deployed for about 1-1.5 cm to deliver energy to a wide area of bone lesion (Fig. 1e).

A CT scan was obtained to verify the optimal placement of the electrodes. Afterwards, thermal ablation was performed with a target temperature of 90°C for 4-6 minutes. A laptop computer was used to graphically display, in real time, the curves of the temperatures at the tips, the power of the generator, and the impedance of the tissues over time. Once a rise in impedance was achieved and the thermal ablation ended, a final CT scan was performed.

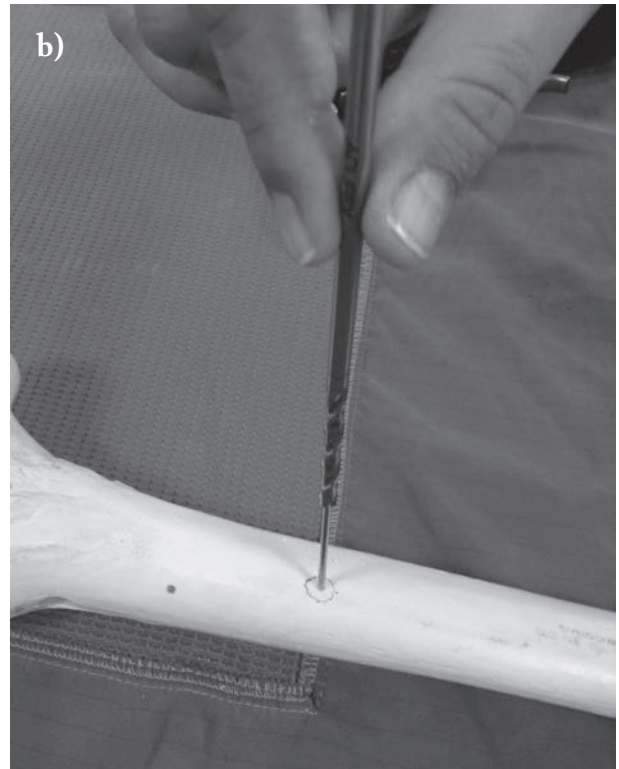


We evaluated the clinical and perioperative course using medical records and patient labels. We ana-

lyzed preoperative, intraoperative and postoperative CT scans. Clinical evaluation was performed using a pain visual analogue scale (VAS) from 0 (no pain) to 10 (unbearable pain), considering a pain between 7 and 10 as severe, between 5 and 6 as moderate, and between 0 and 4 as slight. Pain was assessed preoperatively, 2 weeks postoperatively and at the time of the last follow-up. Complications were classified into major and minor according to the recommendations of the Society of Interventional Radiology (17-18). We defined recurrence as the persistence or return of symptoms after a remission.

Results were evaluated in terms of pain reduction or absence of pain. The difference between pre and postoperative pain was evaluated with paired T-test. Significance was set at a *P value* less than or equal to 0.05.

## Results

All patients were available with an average follow-up of  $84.3 \pm 7.7$  months (range 73-96 months). The results are described in Table 2.



**Figure 1.** **a)** A 2.2-mm Kirschner wire inserted into the center nidus; **b)** Insertion of a 5-mm cannulated drill using the K-wire as a guide; **c)** Drilling of the cortical bone over the nidus; **d)** Insertion of the multi-tined expandable electrode in its closed configuration into the lesion; **e)** RF ablation of the lesion using the multi-tined expandable electrode in its open configuration.

The procedure was technically feasible in all patients. The mean operative time from induction of anesthesia was  $65.5 \pm 11.5$  minutes (range 48-90 minutes). The clinical results according to VAS are summarized in Table 2: VAS pain scores improved at all postoperative time points. Mean preoperative pain score was  $7.4 \pm 1.1$  (range 5-9), two weeks after the procedure mean pain score was 0.3 (range 0-1) with a mean change of 7.06 points ( $p < 0.0001$ ). At the last follow-up all patients reported a VAS score of 0. The percentage of clinical success was 100%. We did not observe any recurrence. No major and minor complications were observed.

## Discussion

The satisfactory clinical results reported in our retrospective study confirm the efficacy of RFA in the treatment of OO, as widely reported in the international literature (12, 13, 19). In our study, RFA using a MTEES was completed successfully in all patients.

Furthermore, in all cases we achieved complete remission of symptoms, without any recurrence of pain at last follow-up.

Several studies on RFA have shown a high safety with a complication rate as low as 3% (12, 13, 15, 20-22). RFA complications are mostly due to cutaneous and thermal burns in the zone of approach (23-25). In this regard, attention should be given in the presence of superficial OOs, in which the distance between the skin and the bone is minimal, to avoid the risk of creating burns from thermal necrosis (24, 26-29). Some authors also recommend using extra care when treating OOs located less than 10 mm from nerve or vascular structures (25, 30). In our study, there were no major or minor complications in intra and postoperative phases. Due to the device design, we choose to select patients in which the minimum distance of the bone lesion from the skin was over 4 cm to prevent the risk of cutaneous and thermal burns and allow an appropriate expansion of the hooks.

None of our patients had a histological diagnosis. The main disadvantage of percutaneous RFA is indeed

**Table 2.** Procedure data and clinical results

Patient	Procedure time (min)	Bone-skin distance (mm)	Major complication	Minor complication	VAS* preop	VAS* 14 days postop	VAS* FU	Recurrence	FU** (mo)
1	65	80	None	None	7	0	0	No	74
2	48	71	None	None	8	1	0	No	80
3	62	42	None	None	7	0	0	No	86
4	55	45	None	None	9	1	0	No	90
5	70	80	None	None	7	1	0	No	75
6	65	78	None	None	6	0	0	No	96
7	72	81	None	None	8	0	0	No	94
8	80	34	None	None	6	0	0	No	90
9	70	41	None	None	5	0	0	No	88
10	80	72	None	None	8	0	0	No	80
11	50	78	None	None	8	1	0	No	73
12	55	83	None	None	7	0	0	No	81
13	68	58	None	None	7	0	0	No	78
14	90	68	None	None	8	1	0	No	94
15	60	66	None	None	9	0	0	No	79
16	58	68	None	None	8	0	0	No	91
Minimum	48	41			5	0			73
Maximum	90	83			9	1			96
Average	65.5	65			7.4	0.3			84.3
SD**	11.5	18			1.1	0.47			7.7

\*VAS: Visual analogue scale; \*\*FU: follow up

the inability to get histological confirmation: the biopsy material is often poor in quality and quantity. Many authors argue that the histological diagnosis of OO before RFA is not needed due to the typical presentation (20), however, others prefer to take a sample of tissue before treatment (31). Furthermore, in case of treatment failure or relapse a histopathological confirmation may be needed (31).

Recurrence of pain after RFA is the result of incomplete tumor ablation (32). Some authors reported a recurrence rate variable from 0 to 35% (14-16, 28, 33). Kjar and co-workers reported that the recurrence rate is significantly higher in OOs with a diameter greater than 10 mm (16). In lesions greater than 10 mm reposition of the electrode needle and multiple ablations are recommended to reduce the risk of recurrence (14-16). In our study, we achieved clinical success without recurrence, even in those cases (7 patients) with a lesion larger than 10 mm. Because of our findings, we concur that the MTEES increases the volume of tissue heated, producing a larger ablation zone compared to a standard monopolar cannula.

Two protocols of RFA for the treatment of OO are usually reported in the literature: 4 minutes at 90°C (12, 13, 23, 24) or 6 minutes at 80°C (34). In our study, we successfully applied a thermal ablation time of 4-6 minutes at 90°C. Moreover, real-time monitoring of the temperatures recorded on thermocouples, placed at the tips of the prongs of this system, and rise in impedance of the tissues over time proved to be effective in controlling the temperature reached during the procedure and in predicting a successful ablation (35).

## Conclusions

RFA using a MTEES has proven to be effective, safe and reliable for the treatment of OOs. We did not report any recurrences despite the presence of a high number of patients with lesions greater than 10 mm. Expandable metal tines allowed to diffuse the RF current density in the target tissue thereby increasing the functional electrode surface area and the size of the necrosis. This device could be a viable alternative to the single needle electrode in the case of larger OOs, reducing the risk of recurrence. However, expandable

needle systems are not suitable for OOs located superficially. Therefore, we recommend its use in lesions at least 4 cm deep, to allow an appropriate expansion of the tines and reduce the risk of skin burns. Further studies related to the use of this device in larger populations of patients are needed for proving its advantage over other currently available RFA systems.

## References

1. Jaffe HL. Osteoid-osteoma. *Proc R Soc Med* 1953; 46: 1007-12.
2. Kransdorf MJ, Stull MA, Gilkey FW, Moser RP Jr. Osteoid osteoma. *Radiographics* 1991; 11: 671-96.
3. Campanacci M, Ruggieri P, Gasbarrini A, Ferraro A, Campanacci L. Osteoid osteoma. Direct visual identification and intralesional excision of the nidus with minimal removal of bone. *J Bone Joint Surg Br* 1999; 81: 814-20.
4. Sluga M, Windhager R, Pfeiffer M, Dominkus M, Kotz R. Peripheral osteoid osteoma. Is there still a place for traditional surgery? *J Bone Joint Surg Br* 2002; 84: 249-51.
5. Ward WG, Eckardt JJ, Shayestehfar S, Mirra J, Grogan T, Oppenheim W. Osteoid osteoma diagnosis and management with low morbidity. *Clin Orthop Relat Res* 1993; 291: 229-35.
6. Yildiz Y, Bayrakci K, Altay M, Saglik Y. Osteoid osteoma: the results of surgical treatment. *Int Orthop* 2001; 25: 119-22.
7. Sans N, Galy-Fourcade D, Assoun J, et al. Osteoid osteoma: CT-guided percutaneous resection and follow-up in 38 patients. *Radiology* 1999; 212: 687-92.
8. Kohler R, Rubini J, Postec F, Canterino I, Archimbaud F. Treatment of osteoid osteoma by CT-controlled percutaneous drill resection. Apropos of 27 cases. *Rev Chir Orthop Reparatrice Appar Mot* 1995; 81: 317-25.
9. Parlier-Cuau C, Champsaur P, Nizard R, Hamze B, Laredo JD. Percutaneous removal of osteoid osteoma. *Radiol Clin North Am* 1998; 36: 559-66.
10. Röderer G, Nelitz M, Puhl W, Huch K. Minimally invasive therapy for osteoid osteoma. *Z Orthop Ihre Grenzgeb* 2004; 142: 456-61.
11. De Palma L, Candelari R, Antico E, et al. Treatment of osteoid osteoma with CT-guided percutaneous radiofrequency thermoablation. *Orthopedics* 2013; 36: e581-7.
12. Barei DP, Moreau G, Scarborough MT, Neel MD. Percutaneous radiofrequency ablation of osteoid osteoma. *Clin Orthop Relat Res* 2000; 373: 115-24.
13. Lindner NJ, Ozaki T, Roedl R, Gosheger G, Winkelmann W, Wörtler K. Percutaneous radiofrequency ablation in osteoid osteoma. *J Bone Joint Surg Br* 2001; 83: 391-6.
14. Asayama Y, Nishie A, Ishigami K, et al. CT-guided radiofrequency ablation of osteoid osteoma in the long bones of the lower extremity. *World J Radiol* 2012; 4: 278-82.

15. Vanderschueren GM, Taminiau AH, Obermann WR, van den Berg-Huysmans AA, Bloem JL. Osteoid osteoma: factors for increased risk of unsuccessful thermal coagulation. *Radiology* 2004; 233: 757-62.
16. Kjar RA, Powell GJ, Schilcht SM, Smith PJ, Slavin J, Choong PF. Percutaneous radiofrequency ablation for osteoid osteoma: experience with a new treatment. *Med J Aust* 2006; 184: 563-5.
17. Sacks D, McClenny TE, Cardella JF, Lewis CA. Society of Interventional Radiology clinical practice guidelines. *J Vasc Interv Radiol* 2003; 14(9 Pt 2): S199-202.
18. Omary RA, Bettmann MA, Cardella JF, et al; Society of Interventional Radiology Standards of Practice Committee. Quality improvement guidelines for the reporting and archiving of interventional radiology procedures. *J Vasc Interv Radiol*. 2003; 14(9 Pt 2): S293-5.
19. Sim FH, Dahlin CD, Beabout JW. Osteoid-osteoma: diagnostic problems. *J Bone Joint Surg Am* 1975; 57: 154-9.
20. Pogliacomi F, Costantino C, Pedrini MF, Pourjafar S, De Filippo M, Ceccarelli F. Anterior groin pain in athletes as a consequence of bone diseases: Etiopathogenesis, diagnosis and principles of treatment. *Medicina dello Sport* 2014; 67(1): 1-26.
21. Rosenthal DI, Hornicek FJ, Torriani M, Gebhardt MC, Mankin HJ. Osteoid osteoma: percutaneous treatment with radiofrequency energy. *Radiology* 2003; 229: 171-5.
22. Woertler K, Vestring T, Boettner F, Winkelmann W, Heindel W, Lindner N. Osteoid osteoma: CT-guided percutaneous radiofrequency ablation and follow-up in 47 patients. *J Vasc Interv Radiol* 2001; 12: 717-22.
23. Rosenthal DI, Hornicek FJ, Wolfe MW, Jennings LC, Gebhardt MC, Mankin HJ. Decreasing length of hospital stay in treatment of osteoid osteoma. *Clin Orthop Relat Res* 1999; 361: 186-91.
24. Finstein JL, Hosalkar HS, Ogilvie CM, Lackman RD. Case reports: an unusual complication of radiofrequency ablation treatment of osteoid osteoma. *Clin Orthop Relat Res* 2006; 448: 248-51.
25. Shinozaki T, Sato J, Watanabe H, et al. Osteoid osteoma treated with computed tomography-guided percutaneous radiofrequency ablation: a case series. *J Orthop Surg (Hong Kong)* 2005; 13: 317-22.
26. Motamedi D, Learch TJ, Ishimitsu DN, et al. Thermal ablation of osteoid osteoma: overview and step-by-step guide. *Radiographics* 2009; 29: 2127-41.
27. Pinto CH, Taminiau AH, Vanderschueren GM, Hogendoorn PC, Bloem JL, Obermann WR. Technical considerations in CT-guided radiofrequency thermal ablation of osteoid osteoma: tricks of the trade. *AJR Am J Roentgenol* 2002; 179: 1633-42.
28. Rosenthal DI, Hornicek FJ, Wolfe MW, Jennings LC, Gebhardt MC, Mankin HJ. Percutaneous radiofrequency coagulation of osteoid osteoma compared with operative treatment. *J Bone Joint Surg Am* 1998; 80: 815-21.
29. Venbrux AC, Montague BJ, Murphy KP, et al. Image-guided percutaneous radiofrequency ablation for osteoid osteomas. *J Vasc Interv Radiol* 2003; 14: 375-80.
30. Yip PS, Lam YL, Chan MK, Shu JS, Lai KC, So YC. Computed tomography-guided percutaneous radiofrequency ablation of osteoid osteoma: local experience. *Hong Kong Med J* 2006; 12: 305-9.
31. Akhlaghpour S, Aziz Ahari A, Ahmadi SA, Arjmand Shabestari A, Gohari Moghaddam K, Alinaghizadeh MR. Histological evaluation of drill fragments obtained during osteoid osteoma radiofrequency ablation. *Skeletal Radiol* 2010; 39: 451-5.
32. Mahnken AH, Bruners P, Delbrück H, Günther RW. Radiofrequency ablation of osteoid osteoma: initial experience with a new monopolar ablation device. *Cardiovasc Intervent Radiol* 2011; 34: 579-84.
33. Rimondi E, Mavrogenis AF, Rossi G, et al. Radiofrequency ablation for non-spinal osteoid osteomas in 557 patients. *Eur Radiol* 2012; 22: 181-8.
34. Sarabia Condes JM, Martínez Martínez J, Villamor Redondo P, Martínez Fernández M, Blanco Barrio A. Treatment of osteoid osteoma by means of CT-guided radiofrequency. *Rev Esp Cir Ortop Traumatol* 2010; 54: 20-26.
35. Ockendon M, Gregory JJ, Cribb GL, Cool WP, Mangham DC, Lalam R. Osteoid osteoma: can impedance levels in radiofrequency thermocoagulation predict recurrence? *Radiol Res Pract* 2011; 2011: 753502.

Received: 18 June 2017

Accepted: 20 July 2017

Correspondance:

Alessandro Costanzo, MD,

Assistant, Department of Orthopaedic Surgery,  
AOUI, Polo Chirurgico P. Confortini, Verona, Italy  
Tel. 045/8123548-2991

E-mail: alecostanzo86@gmail.com