

IMAGES IN HEMATOLOGY

AJH Educational Material



Blood smear, a key diagnostic tool in hematology: Lessons from two cases of acute hemolysis in previously undiagnosed G6PD deficiency



Dino Veneri,¹ Davide Facchinelli,¹ Alice Vianello,² Achille Ambrosetti,¹ Maurizio Cantini,³ Oliviero Olivieri,² Francesco Dima,⁴ and Lucia De Franceschi^{2*}

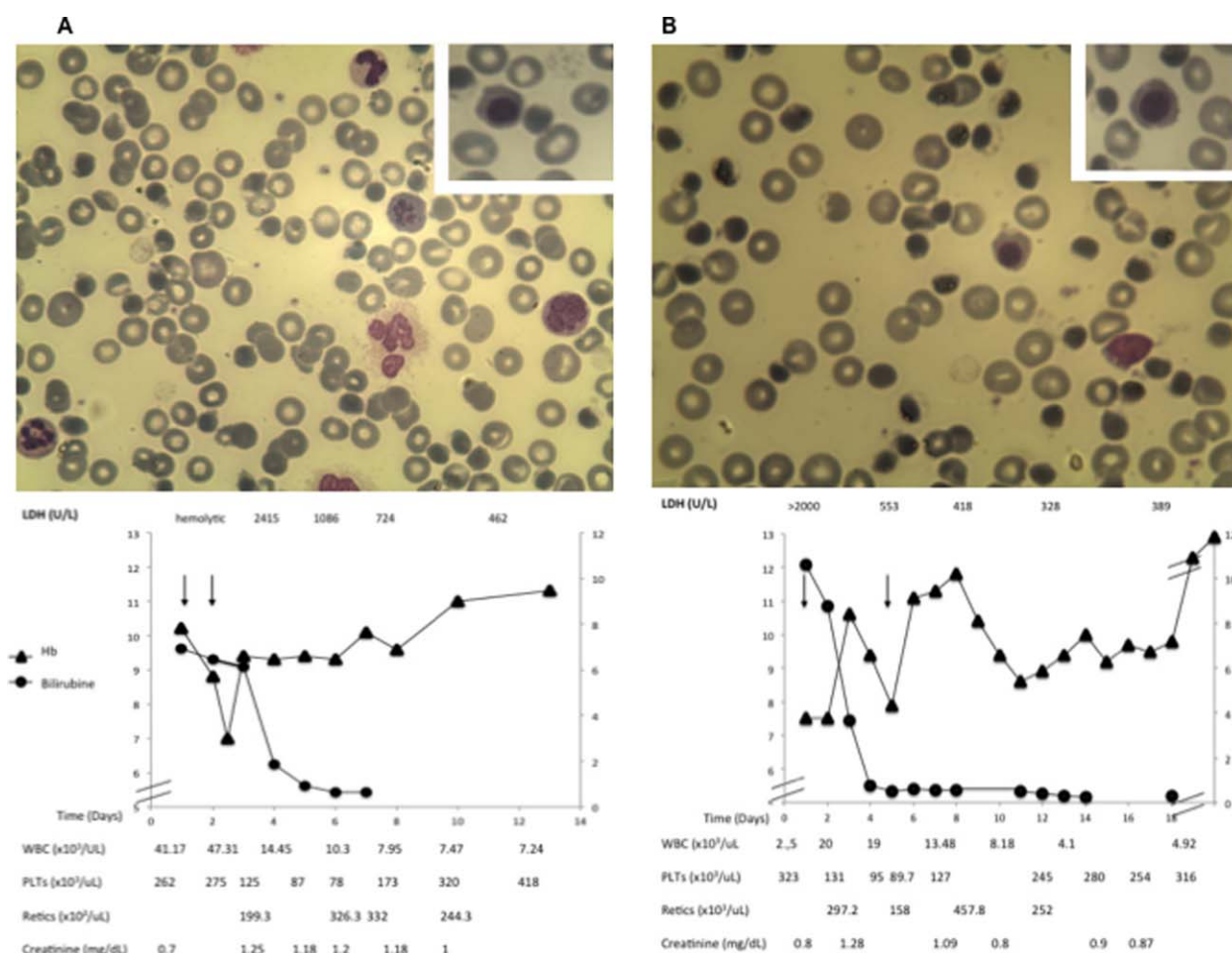


Image 1. Upper panels: Peripheral blood smears of case 1 (A) and 2 (B), showing marked anisopoikilocytosis, with formation of hemi-ghost blister cells (*) and presence of circulating erythroid precursors (insets). Lower panels: Respective values for hemoglobin (Hb), reticulocytes, platelets (PLTs), total white blood cell (WBC) count, bilirubin, lactate dehydrogenase (LDH), and creatinine levels during hospitalization. Black arrows indicate transfusion of packed red cells.

¹Section of Hematology, Department of Medicine, University of Verona and Azienda Ospedaliera Universitaria Integrata Verona, Verona, Italy; ²Section of Internal Medicine, Department of Medicine, University of Verona and Azienda Ospedaliera Universitaria Integrata Verona, Verona, Italy; ³Blood Bank, Azienda Ospedaliera Universitaria Integrata Verona, Verona, Italy; ⁴Laboratory of Clinical Biochemistry, Department of Life and Reproduction Sciences, University of Verona and Azienda Ospedaliera Universitaria Integrata Verona, Verona, Italy

Conflict of interest: Nothing to report.

***Correspondence to:** Lucia De Franceschi, MD, Department of Medicine, Policlinico GB Rossi, University of Verona-AOUI, P.le L. Scuro, 10, Verona, Italy. E-mail: lucia.defranceschi@univr.it

Received for publication: 21 March 2016; **Revised:** 1 April 2016; **Accepted:** 7 April 2016

Am. J. Hematol. 00:00–00, 2016.

Published online: 00 Month 2016 in Wiley Online Library (wileyonlinelibrary.com).

DOI: 10.1002/ajh.24385

Glucose-6-phosphate dehydrogenase (G6PD) deficiency is the most common worldwide distributed hereditary red cells enzymatic defect [1]. The most common life-threatening clinical presentation of G6PD deficiency is acute hemolytic crisis triggered by exposition to oxidative agents such as fava beans, drugs, or infections. Management of acute hemolytic crisis in patients with no previous history of hereditary red cell disorders is particularly challenging for hematologists and emergency department (ED) physicians. We report two cases of acute hemolytic crisis in patients with previously unknown G6PD deficiency, where blood smear analysis played a key role in decision-making process [2]. *Case 1* (Image 1A): A 57-year-old Caucasian man was admitted to ED for fatigue, dyspnea, dizziness, and shivers associated with the appearance of dark-colored urines in the prior two days. History was negative for neurologic disorders, hemolytic anemia, or recent introduction of new drugs. Physical examination revealed jaundice and enlarged spleen. Laboratory tests showed acute hemolytic anemia with intravascular hemolysis (Hb 10.2 g/dL, bilirubin 7.4 mg/dL unconjugated, hemoglobinuria). Patient was admitted to intensive care unit due to worsening of anemia and rapid deterioration of his renal function (Image 1A). Both direct and indirect antiglobulin tests were negative, excluding an immune-mediated acute hemolysis. The peripheral blood smears showed (1) anisopoikilocytosis; (2) reticulocytes as large and round-shaped cells; (3) “hemi-ghost” cells characterized by packed hemoglobin from one side and large vacuum cytoplasm; (4) bite-cells, blister-cells, and schistocytes (2–3%), suggesting a blistering process [3]. Circulating erythroblasts at different stages of maturation, with signs of dyserythropoiesis (binuclearity, nuclear bridges), and

multinucleated erythroblasts were present, indicative of severe bone marrow stress (Image 1A). *Case 2* (Image 1B): A 63-year-old Caucasian woman was admitted to ED for severe fatigue syndrome in the prior five days, jaundiced sclerae/skin, and dark-colored urines in the prior two days. Patient history was negative for anemia, neurologic or immune-rheumatologic diseases. Physical examination was negative. Patient denied recent trips, medications, or infections. Laboratory tests were consistent with severe hemolytic anemia: Hb 7.5 g/dL, hyperbilirubinemia (10.64 mg/dL), increased LDH levels (>2,000 U/L), and reticulocyte count ($297.2 \times 10^3 \mu\text{L}$) (Image 1B). Antiglobulin tests were negative. Blood smears revealed red cell abnormalities, hemi-ghosts, and circulating erythroblasts similar to those described for Case 1 (Image 1B). Thus, morphologic analysis of blood smear is still a gold standard in decision making process of patients with first episode of acute hemolytic crisis and unknown hereditary red cell disorders [2]. G6PD assay was carried out 6 weeks after discharge and confirmed the clinical hypothesis of G6PD deficiency in both cases. The trigger of acute hemolytic crisis was in both cases the recent intake of large amount of fava beans. Although Case 1 typically involved a male subject with unknown G6PD deficiency, Case 2 is of particular interest since the patient is a female with previously unknown G6PD deficiency. A recent study highlights the possible appearance of clinical signs for G6PD deficiency with aging in elder female population [4]. Thus, hematologists should always take into account the possible lyonization effect on G6PD activity for G6PD deficiency inherited red cell disorder in the presence of unexplained acute hemolytic crisis in women with circulating hemi-ghosts [5].

References

1. Cappellini MD, Fiorelli G. Glucose-6-phosphate dehydrogenase deficiency. *Lancet* 2008;371:64–74.
2. Bain BJ. Diagnosis from the blood smear. *N Engl J Med* 2005;353:498–507.
3. Arese P, Gallo V, Pantaleo A, et al. Life and death of glucose-6-phosphate dehydrogenase (G6PD) deficient erythrocytes—Role of redox

stress and band 3 modifications. *Transfus Med Hemother* 2012;39:328–334.

4. Au WY, Lam V, Pang A, et al. Glucose-6-phosphate dehydrogenase deficiency in female octogenarians, nanogenarians, and centenarians. *J Gerontol A Biol Sci Med Sci* 2006;61:1086–1089.
5. Wang J, Xiao QZ, Chen YM, et al. DNA hypermethylation and X chromosome inactivation are

major determinants of phenotypic variation in women heterozygous for G6PD mutations. *Blood Cells Mol Dis* 2014;53:241–245.

