

14. Kim HJ, Lee HK, Seo JJ, et al. MR imaging of solitary fibrous tumors in the head and neck. *Korean J Radiol* 2005;6:136–142
15. Yang XJ, Zheng JW, Ye WM, et al. Malignant solitary fibrous tumors of the head and neck: a clinicopathological study of nine consecutive patients. *Oral Oncol* 2009;45:678–682

## Zygoma Implant-Supported Prosthetic Rehabilitation of a Patient After Subtotal Bilateral Maxillectomy

*D'Agostino Antonio, MD, Procacci Pasquale, MD,  
Francesca Ferrari, MD, DDS, Lorenzo Trevisiol, MD,  
Nocini Pier Francesco, MD, DDS*

**Abstract:** This clinical report describes the successful implant-supported prosthetic rehabilitation of a patient who underwent subtotal bilateral maxillectomy for an oral squamous cell carcinoma with a consequent wide defect interesting the whole hard palate and most of the soft palate, causing a large opening that directly connects the oral cavity to the nasal fossa bilaterally. The innovative aspect of this case is represented by the realization of an obturator prosthesis supported by just 3 zygoma implants.

The maxillary bone had been largely excised by radical surgery. Despite the resection had a complete oncological success and the patient was free of disease after 24 months' follow-up, the patient experienced severe speech and deglutition deficit due to the iatrogenic large oro-antral communication. Three zygoma implants have been positioned, 2 through the right maxillary bone and, owing the wide lack of bone, just 1 on the left side. No mucogingival surgery was necessary around the zygoma implants. The obturator prosthesis was stabilized by the 3 implants and the patient's oral function as well as quality of life widely improved.

The results show that zygoma implants could represent a viable surgical option to obtain a satisfactory oral function rehabilitation even in case of extensive maxillary defect.

**Key Words:** Zygoma implants, maxillectomy, squamous cell carcinoma, implant-supported prosthetic rehabilitation

**R**adical oncological excision of oral neoplastic lesions often leads to a severe impairment of the patient's oral function. Maxillectomy defects result in the formation of an opening between the oral cavity and the nasopharynx. Actually, several surgical reconstructive options exist, including prosthetic obturation,<sup>1–6</sup> nonvascularized

grafts, local flaps, regional flaps, and simultaneous or delayed microsurgical reconstruction.<sup>7–12</sup> In such cases, radical surgery commonly causes large soft and hard tissues defects that seriously impair chewing, speaking, and swallowing abilities. In such cases, conventional dental implants have been widely used to obtain a satisfactory mechanical retention of dental prosthesis or obturators. Dental implants represent a valuable option only when the basal alveolar bone crest is still present, while their use is impossible in case of subtotal bilateral maxillectomy due to the absence of both bone and oral mucosa.<sup>13,14</sup>

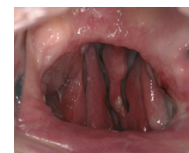Zygoma implants were developed by Prof. Branemark and had been originally conceived in order to obtain a stable retention in those edentulous or oncologic patients with an insufficient bone for conventional dental implants placement.<sup>15</sup> Several studies demonstrated that the mean dimensions of the malar length and width provide an optimal bone anchorage for 1 or 2 zygomatic implants.<sup>16,17</sup> They are inserted cortically through the malar bone achieving a bicortical primary stability even in absence of the whole anterior part of the upper jaw. Zygoma implants are available in several lengths, ranging from 30 to 52.5 mm. Moreover, zygoma implant design offers the maximum bone anchorage with a simple access to the implant head and a consequent easy abutment connection. The implant head allows to develop prosthesis attachment at a 45-degree angle to long axis of the implant.<sup>18</sup> For all these reasons, zygoma implants are suitable in the rehabilitation after oral cancer resection.<sup>19,20</sup>

This clinical report describes the successful management of a patient affected by a squamous oral cell carcinoma who underwent subtotal bilateral maxillectomy, followed by a 3-zygoma-implant-supported prosthetic rehabilitation.

### CLINICAL REPORT

The patient was a 70-year-old man who was referred to our department for oral rehabilitation in March 2010. The patient had a history of a subtotal maxillectomy for resection of a squamous oral cell carcinoma of the hard palate. The surgical resection caused a large defect involving most of the palate, while just the tuberosities and a small part of the posterior soft palate remained. Surgical treatment was complemented by a postoperative radiotherapy protocol of 40 Gy. A maxillary provisional obturator was placed postoperatively. The surgical resection caused a bone defect which corresponded to Class 2c in the classification of maxillary defect by Brown et al.<sup>21</sup> As a direct consequence of the surgery and following radiotherapy, the patient suffered from lip incompetence due to the extreme retraction of all the soft tissues of the upper perioral region.

At the time of the first visit, the resection site appeared to be entirely covered by respiratory mucosa. Only the left upper second molar and the tuberosities were preserved. The defect was extended from the hard palate to the soft palate, causing an opening to the nasal cavity bilaterally (Fig. 1). Extraoral examination revealed a severe loss of upper lip support and left maxillary facial depression with a severe loss of nasal base support (Fig. 2). The nose appeared



**FIGURE 1.** Preoperative intraoral view: a wide defect interests the whole hard and soft palate, causing a large opening that directly connects the oral cavity to the nasal fosse bilaterally.

From the Department of Surgery, Section of Oral and Maxillofacial Surgery, University of Verona, Verona, Italy.

Received August 13, 2012.

Accepted for publication November 4, 2012.

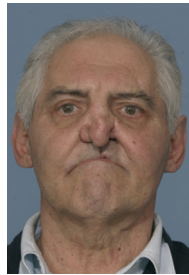Address correspondence and reprint requests to Pasquale Procacci, MD, Department of Maxillo-Facial Surgery and Dentistry, University of Verona, Policlinico "Giovanni Battista Rossi," Piazzale Ludovico Antonio Scuro, 10 37134 Verona, Italy; E-mail: pasquale.procacci@univr.it

The authors report no conflicts of interest.

Copyright © 2013 by Mutaz B. Habal, MD

ISSN: 1049-2275

DOI: 10.1097/SCS.0b013e31827c836e

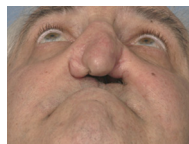

**FIGURE 2.** Preoperative frontal view of the patient: a deep retracting scar is evident in the nasolabial fold, while the left side of the nasal pyramid appears to be deeply depressed due to the absence of any skeletal support.

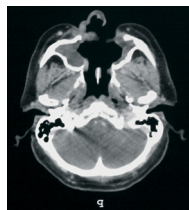
retracted and asymmetrical, while an opening was present between the left nostril and the endonasal cavity (Fig. 3). Radiographic examination revealed a minimal remaining of bone. Owing to the severe periodontal disease affecting the upper second molar, the patient was no longer able to wear the obturator prosthesis that was unstable. Despite the aesthetical appearance which was not satisfactory, the patient just complained about the important functional limitation that had a severe impact to his social and family relationships.

For this case, there were no reconstructive alternatives to implant-supported prosthetic obturator, as reconstructive microsurgery was not considered a viable option due to the age of the patient and his comorbidities. The patient was affected by diabetes type II, hypertension, and ischemic heart disease.

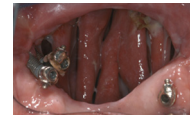Once the upper second molar has been extracted, a conventional obturator was contraindicated due to the absence of a residual alveolar ridge and palatal support. Implant therapy was indicated but nevertheless the extreme bone deficit limited the use of conventional implant placement, leading to the planning of a zygomatic implant-supported obturator and overdenture prosthesis. The surgery was performed in May 2010. The preoperative CT allowed to analyze the anatomy of the remaining maxillary and zygomatic bone and, moreover, to plan the exact location of the zygoma implants. Unfortunately, the malar bone on the left side was so thin to allow for just 1 implant to be placed (Fig. 4). Overall, 3 zygoma implants (Zygoma Fixture; NobelBiocare, Goteborg, Sweden), 2 on



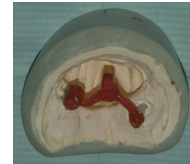**FIGURE 3.** Preoperative view of the nasolabial fold: it is evident that the oncological resection involved the whole premaxilla and most of the hard palate. A large opening through the left nostril represents a second challenging problem to be solved.



**FIGURE 4.** Axial CT scan underlining the poor volume on both maxillary buttress. The left one appears to be thick and not adapted to give a right bone anchorage to 2 implants.



**FIGURE 5.** Custom-made abutments were positioned on the implant heads. Each abutment was designed and produced in order to individuate the right loading pathway through the implant axis.

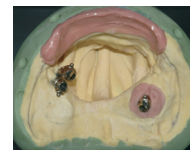

**FIGURE 6.** A multiunit resin jig was created connecting the 3 implants.

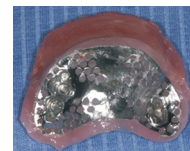the right side and 1 contralaterally (all of them 35-mm long), were inserted. Six months after implant placement, the abutment was installed (Fig. 5). No mucogingival grafts were necessary.

After a 3-month healing period, a multiunit abutment (Nobel-Biocare) was connected to the implant body (Fig. 6). A transfer impression over the implants was made. Wax occlusal rims formed on the acrylic record base were used to make the interocclusal record to transfer the interarch relationship to the articulator, and a facebow registration was also performed. The model was then mounted in an articulator.

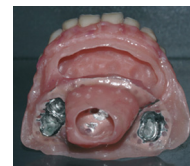Wax-up was performed and phonetic tests made for checking occlusal vertical dimension. Three custom-made noble metal alloy (Skel 80; Fraccari, Verona, Italy) abutments (Gold adapt engaging Branemark system RP; NobelBiocare) were positioned and the overdenture metal framework (Cr\_CO Master C 98; Fraccari) modified in order to allow secondary attachments settling (Ot.Cap strategy 154 PCS; Rhein83, New Rochelle, NY, USA): male on the abutment



**FIGURE 7.** Noble metal abutments with secondary male attachments.



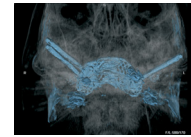
**FIGURE 8.** The framework inside the denture permits an optimal discharge of the masticatory and loading forces through the prosthesis and the implants axis.



**FIGURE 9.** The final upper side of the denture: the prosthesis has a central blob for the palatal opening, while in the anterior profile of the arch a second linear blob has been designed to provide support to the nasolabial region.



**FIGURE 10.** A frontal view of the patient dressing the denture. Although the aesthetical result is not satisfactory, the implant-supported rehabilitation restored a satisfactory speaking and masticatory function.



**FIGURE 11.** At 1-year follow-up, a 3D CT reconstruction underlines the stability of all the implants.

(Fig. 7) and female inside the framework (Fig. 8). Finally, resin obturator (Pro Base; Ivoclar Vivadent, Naturno, Italy) was connected to the internal body of the overdenture (Fig. 9).

The maxillary denture was completed and inserted in the oral cavity in February 2011 (Fig. 10). The definitive obturator prosthesis demonstrated optimal retention and stability during both speech and mastication. Following delivery of the prosthesis, the patient's response was extremely favorable in relation to speech, swallowing, and mastication while the patient's facial appearance poorly improved. Postinsertion instructions were given with a particular focus on insertion, removal, and hygiene of the prosthesis. At 1-year follow-up, the patient confirmed his satisfaction and no significant complaints have been recorded. The masticatory function of the patient was assessed using an evaluation questionnaire for complete denture wearers<sup>22</sup> (Table 1). No complications such as

sinusitis, perimplant mucositis, or implant mobility were detected clinically or radiologically (Fig. 11).

## DISCUSSION

Radical surgical excision of neoplasm of the jaws often leads to a severe deficit of the involved anatomical structures. Extensive surgery for maxillary tumor resection results in severe functional, emotional, and social impacts for patients. Moreover, immediate reconstruction with local pedicled flaps or microsurgical flaps is not always possible, maximizing the postoperative functional impairment.<sup>21</sup>

Although minor maxillectomy defects can be easily repaired by means of a combined surgical and prosthetic rehabilitation, major maxillectomy defects often need a challenging implant-prosthetic rehabilitation. Indeed, major maxillectomy leads to the complete loss of alveolar bone and hard palate with a consequent severe loss of support to the facial soft tissues such as the lip, cheek, and nose. Moreover, in most cases surgery is associated to postoperative radiotherapy that always causes an adjunctive impairment of the elastic properties of the aforementioned anatomical facial structures.<sup>21</sup>

The fabrication of a maxillary obturator is especially challenging in presence of a large maxillary defect. While the obturator is essential for restoring facial contour, functional mastication, articulation, and speech intelligibility, its creation could be actually impossible in wide maxillary defects. The closure of the defect depends on a pressure-resistant seal of the obturator bulb and a prosthetic design that uses all the nearest remaining anatomical structures to obtain a satisfactory stability and retention. In such case of wide bone defects, the obturator prosthesis cannot rely on any anatomical support.

Dental implants positioning represents an optimal option to create a new anatomical support to the obturator prosthesis. Conventional dental implants are the most common option to treat a patient with small and medium-sized defects of the upper jaw: in presence of a well-represented alveolar bone crest, conventional endosseous implants can allow in most cases a stable support to the obturator prosthesis.<sup>13,14,23</sup>

In all those patients that, after a subtotal maxillectomy, cannot be immediately reconstructed with a microsurgical revascularized bone flap, the zygoma implants represent the only available option to obtain a stable support for an obturator prosthesis. The design of zygoma implants allows the surgeons to insert these implants even in case of total maxillary bone defect because they obtain a bicortical stability through the malar bone.<sup>15,18–20</sup> Moreover, zygoma implants are commonly placed at a 30–60-degree angle relative to the occlusal plane<sup>20</sup> in order to minimize the large lever arm and, although no implant fractures have been reported to date, to avoid any possible postoperative mechanical deficit.

In presence of a severe maxillary atrophy or a wide maxillary defect, a “quad” approach—1 or 2 zygoma implants in the posterior maxilla and 1 or more conventional implants in the anterior maxilla—is nowadays considered as the best option. A “quad” approach based on just 4 zygoma implants inserted in the posterior maxilla has been also described as a viable option.<sup>15,24–26</sup>

**TABLE 1.** Chewing Function

Class	Food	Before Treatment	After Treatment
1	Whole apple	×	×
1	Chewing gum	×	×
1	Dried shell ligament	×	×
1	Dried cuttlefish	×	×
2	Fresh ear shell	×	◊
2	Hard pickled radish	×	×
2	Hard cracker	×	◊
2	Hard biscuit	×	○
3	Pickled radish	×	○
3	Peanuts	×	◊
3	Beef steak	×	○
3	Rice-cake cubes	×	○
4	Burdocks	×	○
4	Potato chips	×	○
4	Boiled fish paste	◊	○
4	Artificially grown soybean	×	○
5	Boiled carrot	○	○
5	Boiled potato	○	○
5	Boiled eggplant	◊	○
5	Bean curd	○	○

Assessment of chewing function in complete denture wearers based on the food intake questionnaire method. The present case showed a satisfactory recovery of the masticatory function. In fact, after treatment the patient has a masticatory ability similar to those patients wearing complete dentures with optimal retention, fit, and stability. Open circles indicate easy to chew; open diamonds, difficult to chew; times symbol, impossible to chew. Chewing factor score: number of open circles/20 × 100.

In the present case, it was not possible to place more than 1 implant on the left side because of the lack of thickness of the malar process. Two zygoma implants could not get an effective bone anchorage on that side. Then, it was assumed that the stability of the dentition of the right side, based on 2 well-positioned zygoma implants, is equivalent to a normal one, as already described in the literature.<sup>27,28</sup> Therefore, a single zygoma implant on the other side should not be prone to overload if it has been splinted rigidly to the other implants.<sup>29,30</sup> Due to the wide extension of the palatal defect, it was not possible to create a cross-arch rigid splintation by means of a metal bar. Otherwise, the metal bar would have been crossing the defect and the obturator would not have closing all along the defect's margins. Therefore, 3 single customized abutments were obtained and OKT attachments (Ot.Cap strategy 154 PCS; Rhein83) were connected as more axially as possible to avoid lack of retention. Furthermore, the overload on the single zygoma implant has been avoided by means of a mucosal-implant support of the overdenture.

The excessive leverage forces on the implant have been previously reported as one of the most important causes of zygoma implant failure. Nevertheless, in this case the leverage force on the left implant was counterbalanced by means of an accurate design of the framework connecting the 3 implants and releasing the forces through them.<sup>30</sup>

In the present case, the lack of bone of the anterior maxilla prevented the placement of any conventional dental implant. The prosthetic design was thought to provide just a passive support to the nasolabial fold.

The evolution of osseointegrated implant concepts and design in combination with remote bone anchorage concept has given the surgeon new reconstructive options. The most important effect of the development of zygoma implants is that the possibility of an implant-supported rehabilitation is now available also for patients not susceptible of major surgical reconstruction. Although limited clinical data are available on the long-term performance of zygoma implants, the literature provides evidence that such implants, associated or not to conventional implants, represent a viable and adaptable option to rehabilitate wide maxillary defects.

## REFERENCES

- Desjardins RP. Obturator prosthesis design for acquired maxillary defects. *J Prosthet Dent* 1978;39:424–435
- Desjardins RP. Early rehabilitative management of the maxillectomy patient. *J Prosthet Dent* 1977;38:311–318
- Wu YL, Schaaf NG. Comparison of weight reduction in different designs of solid and hollow obturator prostheses. *J Prosthet Dent* 1989;62:214–217
- Omondi BI, Guthua SW, Awange DO, et al. Maxillary obturator prosthesis rehabilitation following maxillectomy for ameloblastoma: case series of five patients. *Int J Prosthodont* 2004;17:464–468
- Gay WD, King GE. Applying basic prosthodontic principles in the edentulous maxillectomy patient. *J Prosthet Dent* 1980;43:433–435
- Devlin H, Barker GR. Prosthetic rehabilitation of the edentulous patient requiring a partial maxillectomy. *J Prosthet Dent* 1992;67:223–227
- Okay DJ, Genden E, Buchbinder D, et al. Prosthodontic guidelines for surgical reconstruction of the maxilla: a classification system of defects. *J Prosthet Dent* 2001;86:352–363
- Davison SP, Sherris DA, Meland NB. An algorithm for maxillectomy defect reconstruction. *Laryngoscope* 1998;108:215–219
- Brown JS, Jones DC, Summerwill A, et al. Vascularized iliac crest with internal oblique muscle for immediate reconstruction after maxillectomy. *Br J Oral Maxillofac Surg* 2002;40:183–190
- Cordeiro PG, Santamaria E. A classification system and algorithm for reconstruction of maxillectomy and midfacial defects. *Plast Reconstr Surg* 2000;105:2331–2346
- Futran ND. Retrospective case series of primary and secondary microvascular free tissue transfer reconstruction of midfacial defects. *J Prosthet Dent* 2001;86:369–376
- Triana RJ Jr, Uglesic V, Virag M, et al. Microvascular free flap reconstructive options in patients with partial and total maxillectomy defects. *Arch Facial Plast Surg* 2000;2:91–101
- Baqain ZH, Anabtawi M, Karaky AA, et al. Morbidity from anterior iliac crest bone harvesting for secondary alveolar bone grafting: an outcome assessment study. *J Oral Maxillofac Surg* 2009;67:570–575
- Chiapasco M, Biglioli F, Autelitano L, et al. Clinical outcome of dental implants placed in fibula-free flaps used for the reconstruction of maxillo-mandibular defects following ablation for tumors or osteoradionecrosis. *Clin Oral Implants Res* 2006;17:220–228
- Malevez C, Abarca M, Durdu F, et al. Clinical outcome of 103 consecutive zygomatic implants: a 6–48 months follow-up study. *Clin Oral Implants Res* 2004;15:18–22
- Rigolizzo MB, Camilli JA, Francischone CE, et al. Zygomatic bone: anatomic bases for osseointegrated implant anchorage. *Int J Oral Maxillofac Implants* 2005;20:441–447
- Nkenke E, Hahn M, Lell M, et al. Anatomic site evaluation of the zygomatic bone for dental implant placement. *Clin Oral Implants Res* 2003;14:72–79
- Brånemark PI, Adell R, Albrektsson T, et al. An experimental and clinical study of osseointegrated implants penetrating the nasal cavity and maxillary sinus. *J Oral Maxillofac Surg* 1984;42:497–505
- Landes CA. Zygoma implant-supported midfacial prosthetic rehabilitation: a 4-year follow-up study including assessment of quality of life. *Clin Oral Implants Res* 2005;16:313–325
- Schmidt BL, Pogrel MA, Young CW, et al. Reconstruction of extensive maxillary defects using zygomatic implants. *J Oral Maxillofac Surg* 2004;62:82–89
- Brown JS, Shaw RJ. Reconstruction of the maxilla and midface: introducing a new classification. *Lancet Oncol* 2010;11:1001–1008
- Sato Y, Minagi S, Akagawa Y, et al. An evaluation of chewing function of complete denture wearers. *J Prosthet Dent* 1989;62:50–53
- Shirota T, Shimodaira O, Matsui Y, et al. Zygoma implant-supported prosthetic rehabilitation of a patient with a maxillary defect. *Int J Oral Maxillofac Surg* 2011;40:113–117
- Bedrossian E, Stumpel LJ 3rd. Immediate stabilization at stage II of zygomatic implants: rationale and technique. *J Prosthet Dent* 2001;86:10–14
- Bedrossian E, Stumpel L 3rd, Beckely ML, et al. The zygomatic implant: preliminary data on treatment of severely resorbed maxillae. A clinical report. *Int J Oral Maxillofac Implants* 2002;17:861–865
- Vrielinck L, Politis C, Schepers S, et al. Image-based planning and clinical validation of zygoma and pterygoid implant placement in patients with severe bone atrophy using customized drill guides. Preliminary results from a prospective clinical follow-up study. *Int J Oral Maxillofac Surg* 2003;32:7–14
- Roumanas ED, Nishimura RD, Davis BK, et al. Clinical evaluation of implants retaining edentulous maxillary obturator prostheses. *J Prosthet Dent* 1997;77:184–190
- Parel SM, Brånemark PI, Ohnrell LO, et al. Remote implant anchorage for the rehabilitation of maxillary defects. *J Prosthet Dent* 2001;86:377–381
- Malevez C, Daelemans P, Adriaenssens P, et al. Use of zygomatic implants to deal with resorbed posterior maxillae. *Periodontol* 2000 2003;33:82–89
- Kreissl ME, Heydecke G, Metzger MC, et al. Zygoma implant-supported prosthetic rehabilitation after partial maxillectomy using surgical navigation: a clinical report. *J Prosthet Dent* 2007;97:121–128