



UNIVERSITA' DEGLI STUDI DI VERONA

DIPARTIMENTO DI SANITÀ PUBBLICA E MEDICINA DI COMUNITÀ

SEZIONE DI PSICHIATRIA E SEZIONE DI PSICOLOGIA CLINICA

SCUOLA DI DOTTORATO DI SCIENZE INGEGNERIA E MEDICINA

DOTTORATO DI RICERCA IN SCIENZE PSICOLOGICHE E PSICHIATRICHE

XXIII CICLO - 2008

TESI DI DOTTORATO


BRAIN COMMUNICATION IN SCHIZOPHRENIA:

INSIGHT FROM THE *PREVENT* STUDY

S.S.D. MED/25 PSCHIATR

Coordinatore: Prof.ssa MIRELLA RUGGERI

Tutor: Dr. PAOLO BRAMBILLA

A handwritten signature in dark ink, appearing to read 'Paolo Brambilla'.

Dottorando: Dott.ssa MARCELLA BELLANI

Abstract

Brain communication in schizophrenia. Insight from the PREVENT Study

Background: The role of the CC in sustaining inter-hemispheric connectivity is well documented in humans both for simple and more cognitively demanding tasks. Alterations in inter-hemispheric communication have been shown in schizophrenia subjects (Mohr et al., 2000) with few studies investigating interhemispheric information exchange using behavioural tasks. In contrast some studies found no differences between schizophrenia patients and normal controls, but also excessively slow responses involving the left hemisphere were present in schizophrenics (Shelton & Knight, 1984; Florio and colleagues, 2002; Bellani et al., 2010). Moreover, there is some evidence of abnormally long interhemispheric transfer time (IHTT) in schizophrenia showed by evoked related potential studies (Barnett et al., 2005; Barnett and Kirk 2005; Endrass et al., 2002).

Objectives: In the present study, we aimed to study interhemispheric connectivity in a sample of schizophrenia patients and healthy controls using functional Magnetic Resonance Imaging (fMRI) and a visuomotor task named Poffenberger's task .

Methods: A sample of 21 healthy controls and 21 schizophrenia patients underwent a simple visual manual reaction-time (RT) task (Poffenberger's paradigm) during a fMRI session. This paradigm was employed to measure interhemispheric transfer (IT) by subtracting mean reaction times (RT) for the uncrossed hemifield-hand conditions, that is, those conditions not requiring an IT, from the crossed hemifield-hand conditions, that is, those conditions requiring an IT to relay visual information from the hemisphere of entry to the hemisphere subserving the response. The obtained difference is widely believed to

reflect callosal conduction time. fMRI data were acquired using a 3 Tesla Siemens scanner. We performed separate One Sample t-test CUD for patients and controls.

Results: The blood oxygenation level-dependent (BOLD) response was present in the genu of corpus callosum in males and females separately and in the whole group ($p < 0.01$ uncorrected). In the patient group, there is a diffuse hyperactivation in the brain ($p < 0.01$).

Hyper-activations and hypo-activations were found in the schizophrenic patients in comparison to the healthy controls depending on the area of the brain and on the task. The blood oxygenation level-dependent (BOLD) response was higher in the pre-central gyrus (frontal motor cortex), middle frontal gyrus, inferior frontal gyrus, post central gyrus (parietal sensory cortex), and in the putamen for the crossed-uncrossed difference condition. With $p < 0.01$ (uncorrected) activations were wider and also included corpus callosum. Interestingly when females and males are analysed separately, significant hyperactivations persisted only in female SCZ patients excepted for putamen and precentral gyrus that were no more significant.

Conclusions: Our results confirmed previous published studies in humans that tested the implication of corpus callosum in visuo-motor task. In particular our results confirmed the structure-function relationship that involves brain interhemispheric processes in a sample healthy subjects and referred to a specific activation restricted in the genu of corpus callosum. The genu is thought to be associated with the prefrontal cortex to the premotor interhemispheric transfer.

We investigated the role of the CC in regulating functional communication between the hemispheres in schizophrenia patients compared to healthy controls and hyper-activations

and hypo-activations were found. These results may reflect a brain diffuse overwork related to the demanding task that is not present in healthy subjects.

Index

1. <u>Background of the Study</u>	p. 06
1.1 Corpus callosum: anatomy and function	p. 06
1.2 Interhemispheric communication in humans	p. 08
1.3 Interhemispheric communication in schizophrenia	p. 11
2. <u>Objectives</u>	p.14
3. <u>Material and Methods</u>	p. 15
3.1 THE PREVENT STUDY - Prevention on Psychotic and Affective Events	p. 15
3.2 Participants (recruitment and assessment)	p. 16
3.3 MRI Procedures	p. 20
3.4 Behavioural Paradigm	p. 20
3.5 MRI sequences and analysis	p. 22
4. <u>Results</u>	p. 23
4.1 Functional Imaging in healthy controls and schizophrenia patients (Crossed Uncrossed Difference)	p. 26
4.2 Functional Imaging in healthy controls compared to schizophrenia (Crossed Uncrossed Difference)	p. 26
5. <u>Discussion</u>	p. 36
6. <u>References</u>	p. 39

1. Background of the study

1.1 Corpus callosum anatomy and function

The corpus callosum (CC) is the brain's largest white matter tract, mostly composed by both myelinated and unmyelinated fibres, connecting the two cerebral hemispheres. The CC can be divided into different sections: rostrum, genu, body, isthmus and splenium (Aboitiz et al., 1992). Myelinated fibres predominate in the midbody and the splenium while unmyelinated fibres are more numerous in the rostrum and the genu. The callosal fiber disposition approximately reflects brain topography: the anterior sections connect the frontal lobes, the median sections connect temporal and parietal regions, and the posterior sections link occipital areas (Pandya et al., 1971) (Fig 1). This traditional picture, however, which has been obtained mainly through studies in non-human primates, has been partly modified by modern diffusion tensor imaging studies in humans (Fig. 2; Hofer & Frahm, 2006). The CC matures after birth through adolescence and into early adulthood and is involved in different cognitive processes such as sensory-motor integration, attention, language, arousal and memory. Its size has been shown to be associated with handedness, sex (i.e., greater splenium in females and greater genu in males, Dubb et al., 2003) and cerebral laterality (i.e., inverse correlation between callosal connectivity and brain lateralization in males; Luders et al., 2003), and age (Ota et al., 2006). As recently suggested, callosal astrocytes may play a key role in CC activation (Schummers et al., 2008), sustaining callosal activation as detected by fMRI.

In particular, the CC has been shown to be crucial in determining interhemispheric transfer time (IHTT) of visuomotor information. IHTT can be assessed with the Poffenberger

paradigm (Poffenberger 1912, Marzi 1999) or by using cortical evoked related potentials (ERPs). Both techniques are based on the callosal crossing of visual information which is required when simple visual stimuli are presented extra-foveally to the hemifield contralateral to the responding hand in a visuomotor reaction time task. The crossed hemifield-hand conditions produce longer RTs than the uncrossed conditions (for a review, see Marzi et al., 1991). The crossed-uncrossed difference (CUD) measures IHTT, because in the crossed conditions the hemisphere of stimulus entry is different from the hemisphere controlling the motor response and an interhemispheric transfer is needed. In contrast, when stimuli and response are ipsilateral, hence processed by the same hemisphere, transfer is unnecessary. Therefore, by subtracting the mean RT of the two uncrossed combinations from the mean RT of the two crossed combinations, one can infer IHTT from the CUD.

Fig.1. Corpus callosum (3D reconstruction).

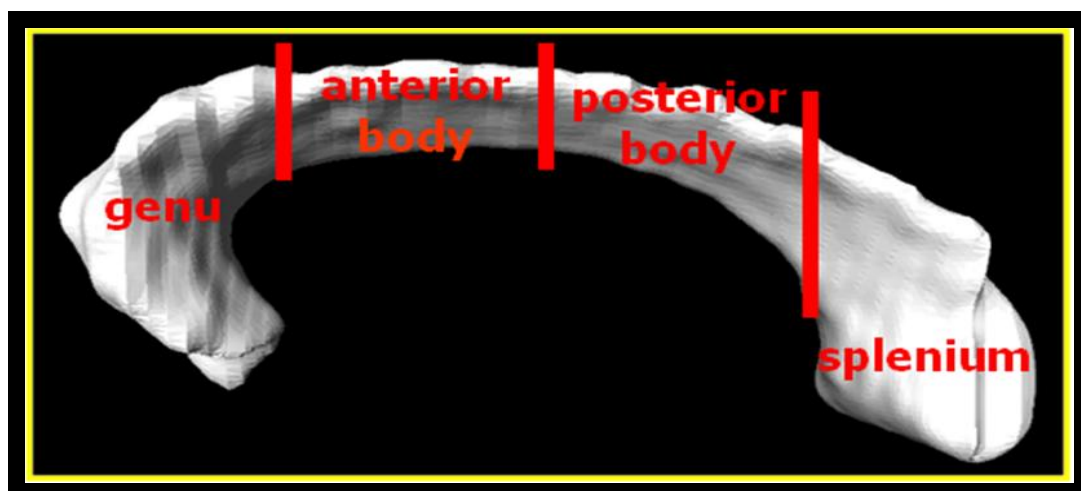
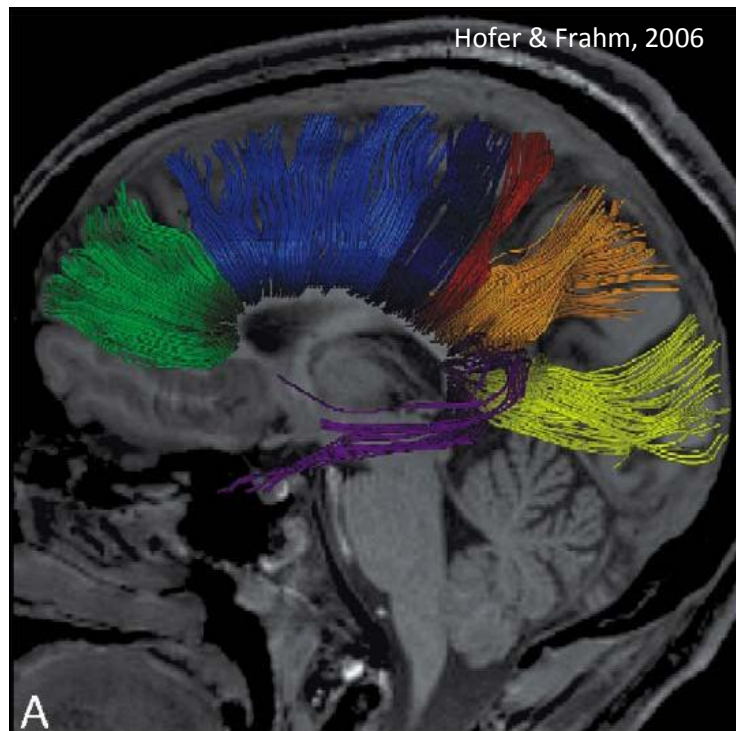


Fig.2. Callosal fibers using tractography (Hofer & Frahm, 2006).



1.2 Inter-hemispheric communication in humans

In normal subjects the IHTT is around 4 msec (Marzi et al., 1991), but it shows a considerable lengthening when the CC is sectioned (i.e., the so called “split brain”, IHTT about 30-60 ms) or absent (i.e., callosal agenesis, IHTT about 15-20ms).

Recent studies suggest that IHTT can be influenced by CC anatomy, i.e. shorter IHTT is related with larger midsagittal cross sectional area and higher microstructural integrity (Schulte et al., 2005). In contrast, Westerhausen and colleagues (2006) did not find significant correlations between IHTT and mid-sagittal areas of CC, except for electrophysiologic measures. The authors concluded that the detected association demonstrates that IHTT of visual information is directly related to the functional integrity of

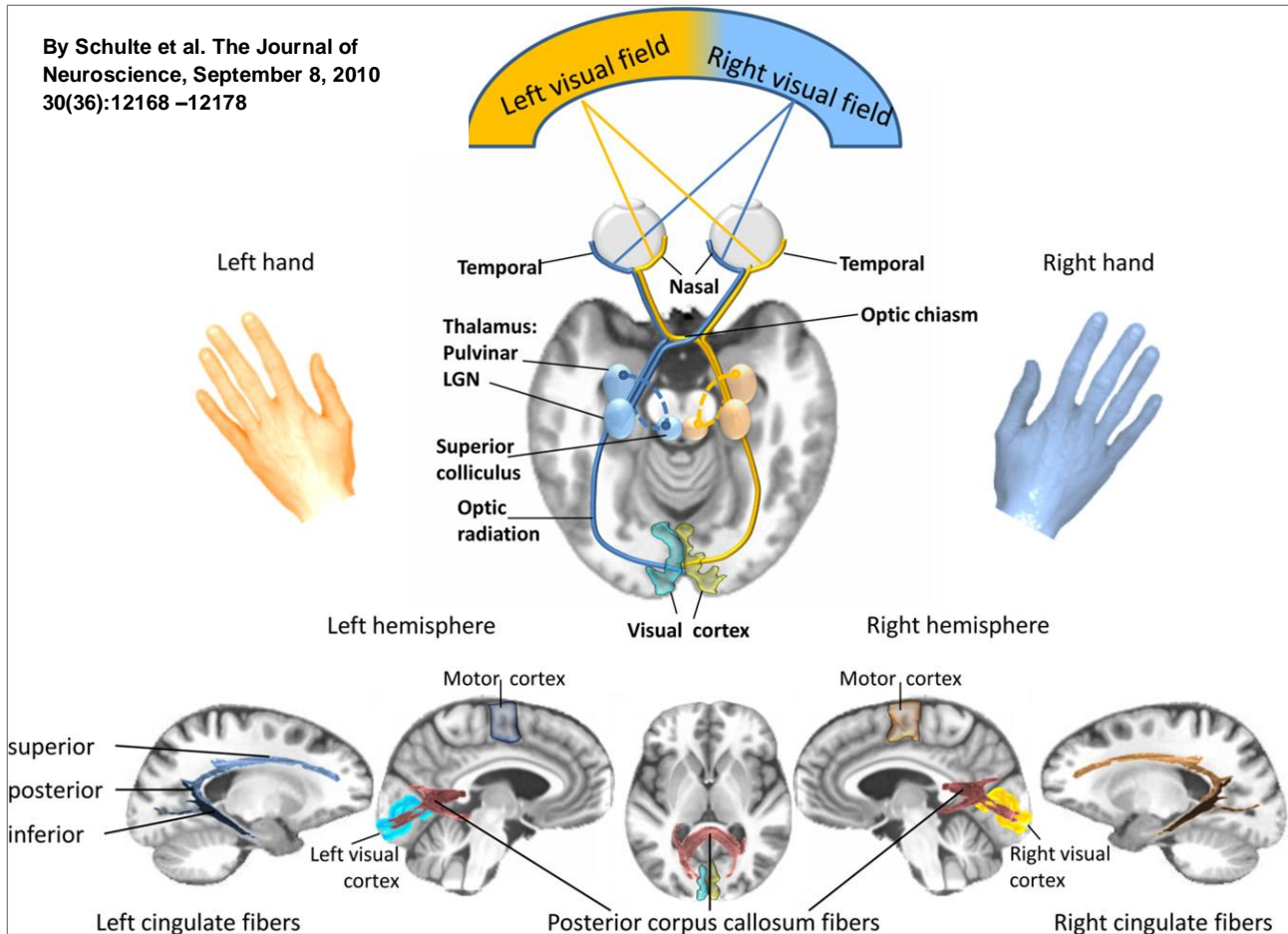
at least the posterior callosal third. IHTT speed can give information about CC integrity and Iacoboni & Zaidel (2004) analyzed inter-hemispheric visuomotor integration in right-handed normal volunteers combining event related functional magnetic resonance imaging (fMRI) and a simple visuomotor behavioural task.

This study showed a greater activity in crossed conditions in bilateral frontal, bilateral dorsal premotor and right superior parietal areas inferring a role of superior parietal cortex in visuo motor integration. In a previous fMRI study, Tettamanti and colleagues (2001) found an activation of the genu of CC during the Poffenberger task in the crossed condition that was confirmed by using a different version of the Poffenberger paradigm (Omura et al., 2004; Weber et al., 2005). Therefore the role of the CC in sustaining inter-hemispheric connectivity is well documented in humans both for simple and more cognitively demanding tasks.

In contrast to simple visuomotor information which can still transfer, although at a slower velocity, between hemispheres despite callosal section, the CC is exclusively responsible for the transfer of cognitive information between the two hemispheres (Gazzaniga 2000).

Therefore, if hemispheres are disconnected (i.e. split brain patients) percepts and memories generated in one hemisphere are excluded from the conscious awareness of the other one.

Figure 3. Schematic representation of the highly lateralized visual projection system (Schulte et al. 2010).



1.3 Inter-hemispheric communication in Schizophrenia

Two different mechanisms causing abnormal connectivity have been proposed, the hyper-connectivity hypothesis, in which synapses are supposed not to be eliminated in development (Feinberg 1982), and the hypo-connectivity hypothesis in which too many synapses are eliminated because of abnormal interactions between neurons (Friston 1995).

Moreover, several connectivity theories have focused on aberrant neural timing in schizophrenia (Andreasen et al., 1999; Bartzokis, 2002; Stephan et al., 2009).

It has been suggested that this aberrant neural timing could be caused by conduction delays arising from structural damage to the white-matter fasciculi that physically connect spatially different populations of neurons (Bartzokis, 2002; Whitford et al., 2010a).

Thus there is reason to suspect that schizophrenia is associated with aberrant interhemispheric transfer. In this regard, David et al. (1993) proposed abnormal interhemispheric integration as a “*plausible model for a range of psychiatric phenomena from alexithymia to delusions and hallucinations*”.

Alterations in interhemispheric communication have also been shown in schizophrenia subjects (Mohr et al., 2000). A post mortem study reported density reduction of myelinated fibers and glial cells in all regions of the CC, except for the rostrum, in female patients with schizophrenia (Highley et al., 1999) but these findings were not confirmed by other studies.

Also, size reduction and microstructural disruption of the CC in schizophrenia have been demonstrated in several imaging studies (Diwadkar et al., 2004).

Diffusion abnormalities detected with MRI in general, and Fractional Anisotropy (FA) abnormalities in particular, have consistently been observed in the white-matter fasciculi that either connect the frontal lobes (e.g., genu of the corpus callosum or project from the frontal lobes, Whitford et al., 2010) and represent a marker of impaired microstructure. A recent meta-analysis by Ellison-Wright and Bullmore (2009) of fifteen voxel-based diffusion tensor imaging DTI studies also reported evidence for abnormalities in frontally-projecting fasciculi in patients with schizophrenia. Interestingly, in a prospective study of childhood-onset schizophrenia an abnormal developmental trajectory for the splenium was shown in patients with schizophrenia during adolescence and early adulthood (Keller et al., 2003). Only few studies have investigated inter-hemispheric information exchange in schizophrenia using behavioural tasks. Shelton & Knight (1984) found no difference in CUD between individuals with schizophrenia and normal controls. Florio and colleagues (2002) using the Poffenberger paradigm found a CUD=0 in schizophrenia patients but also excessively slow responses involving the left hemisphere (both crossed and uncrossed) was present in schizophrenics. In a recent work of our group (Bellani et al., 2010) we replicated this result in bipolar and schizophrenia patients compared with controls. No difference was found in the comparison within the three groups, but schizophrenia patients (22, all right handed) showed a selective slowing down of the right hand in the uncrossed condition. This finding is likely to be related to abnormalities in intrahemispheric cortico-cortical connections in the left hemisphere. There is some evidence of abnormally long IHTTs in schizophrenia showed by ERP (evoked related potential) studies (Barnett et al., 2005; Barnett and Kirk 2005; Endrass et al., 2002). Only one study applied MRI (DTI) coupled with ERP to study schizophrenics and found no difference in IHTT between groups, while DTI images showed a wide disrupted white matter and longer IHTT was linearly associated with lower fractional anisotropy (Whitford et al., 2010b in press).

Moreover hallucinated patients had significantly reduced interhemispheric connectivity in auditory cortex compared with non-hallucinated patients, as shown by a fMRI study (Gavrilescu et al., 2010). *(This text has been partly published in Bellani et al., 2009).*

2. Objectives

- To test the hypothesis that interhemispheric transmission (IT) of visuomotor information requires the corpus callosum and to identify the cortical areas specifically activated during IT using event-related functional magnetic resonance imaging (fMRI), to investigate the neural correlates of basic interhemispheric visuomotor integration in a large cohort of subjects.
- To investigate the role of the CC in regulating functional communication between the hemispheres in schizophrenia patients in order to better delineate the contribute of inter-hemispheric connectivity to the clinical course of the disease.

3. Materials and Methods

3.1 THE PREVENT STUDY - *Prevention on Psychotic and Affective Events*

This experiment is a part of The Prevent study, a longitudinal study, started in 2007 and conducted by the Research Unit of Brain Imaging and Neuropsychology (Rubin) of the Section of Psychiatry and Clinical Psychology at the University of Verona, WHO Collaborating Center. Patients are recruited from the geographically defined catchment area of Verona District (1[^], 2[^], 3[^] & 4[^] Psychiatric Units, and Casa di Cura “Villa Santa Giuliana”). All individuals are asked to perform MRI, neuropsychological tests and blood withdrawal at baseline and after at least 12 months of follow-up.

The Project's main aim is to investigate white matter abnormalities starting from the suggested relationship between the abnormal brain communication and a specific immune gene expression in schizophrenic and bipolar patients in comparison to first-degree relatives and healthy subjects (Uranova et al., 2004; Bartzokis & Altshuler 2005). Altered myelination due to abnormal immune gene expression may result in white matter misconnection in schizophrenia or/and bipolar disorder, representing a common endophenotype shared by individuals susceptible to developing these two disorders. Brain communication and specific immune gene expression are tested as a endophenotype for both diseases. A multimodal MRI (3 Tesla) approach is applied to investigate brain connectivity in these patients integrating psychosocial, immunological and neuropsychological variables. Structural MRI, fMRI, MRS, and DTI along with neuropsychological and neuro-immunological and genetic assessments are conducted to detect the functional and the biochemical maps of these disorders. This integrated

approach is considered appropriate to accurately associate the neural networks of major psychoses with specific psychotic signs and phenotypes.

Brain communication is studied with Structural MRI, functional MRI, spectroscopy (MRS), and diffusion tensor Imaging (DTI) in collaboration with the Department of Neurological and Visual Sciences (Prof. Marzi & Dr. Savazzi) at the University of Verona and the Neuroradiology Section of the Civil Hospital of Verona (Dr. Beltramello, Dr. Zoccatelli, Dr. Alessandrini & Dr. Pizzini). A specific paradigm investigating brain communication (Poffenberger Task, see below) is utilized during the fMRI session.

For the purpose of this paper only data and methods on FMRI comparison between schizophrenia and healthy controls are reported and discussed.

3.2 Participants (recruitment and assessment)

Patients are recruited from the geographically defined catchment area of Verona District and selected from the South-Verona Psychiatric Case Register (PCR) (Amaddeo and Tansella, 2009), a community-based mental health register which refers to the four Psychiatric Services of Verona.

Inclusion criteria:

- a *DSM-IV diagnosis of Schizophrenia*
- age between 18-60 for healthy controls and between 18-45 for schizophrenics.
- less than 10 years of illness duration

Exclusion criteria:

- comorbid Axis I psychiatric disorder,
- current medical problems or neurological diseases,
- alcohol or substance abuse in the prior 6 months,
- ECT during the prior 6 months,
- treatment with immunomodulatory drugs in the prior 6 months,
- pregnancy
- head injury with loss of consciousness,
- family history of hereditary neurologic disorder,
- floating metallic objects in the body
- IQ<70

Diagnoses of Schizophrenia are established according to the DSM-IV criteria, using the Structural Clinical Interview for DSM-IV, SCID I (Spitzer et al., 1994) Italian version (Mazzi et al., 2000-2007) and subsequently confirmed with the clinical consensus of two staff psychiatrists.

Symptoms at the moment of the assessment (in the same day or within one week) were evaluated by administering the PANSS. Moreover a full clinical assessment is administered to better delineate the clinical profile of subjects (see Table 1). Data on the psychotropic treatment were also collected and Chlorpromazine equivalent calculated (see Table 1). Healthy subjects are recruited from the local community using advertisements and word of mouth.

Informed consent was obtained from all participants after they had understood the aims and the procedures of the study and the issues involved in study participation. The study was approved by the Ethics Committee of the Azienda Ospedaliera of Verona.

Table 1a. Full assessment for Schizophrenia subjects.

Full Assessment for Schizophrenia patients
SCID I
Global Assessment Of Functioning (GAF)
Oldfield Questionnaire For Handedness
PANSS
Barratt Impulsivity Scale (BIS)
Premorbid Adjustment Scale (PAS)
Buss Durkee Hostility Inventory (BDHI)
WHO-DAS
SAI-E
Strauss and Carpenter Outcome Scale
Scala UKU
Childhood trauma inventory (ITI)
Socio-economic Status (SES)
Brief intelligence test (TIB)

Table 1b. Full assessment for control subjects.

Full assessment for control subjects
(SCID Non Patient version)
Global assessment of functioning (GAF)
Oldfield Questionnaire For Handedness
SCL-90
Buss Durkee Hostility Inventory (BDHI)
Barratt Impulsivity Scale (BIS)
ECR
Childhood trauma interview (ITI)
Socio-economic Status (SES)
Temperament and Character Inventory (TCI)
Paykel checklist for life adverse events
The Magical Ideation Scale (MIS)
The Perceptual Aberration Scale (PAS)
The Hypomanic Personality Scale (HPS)
Brief intelligence test (TIB)

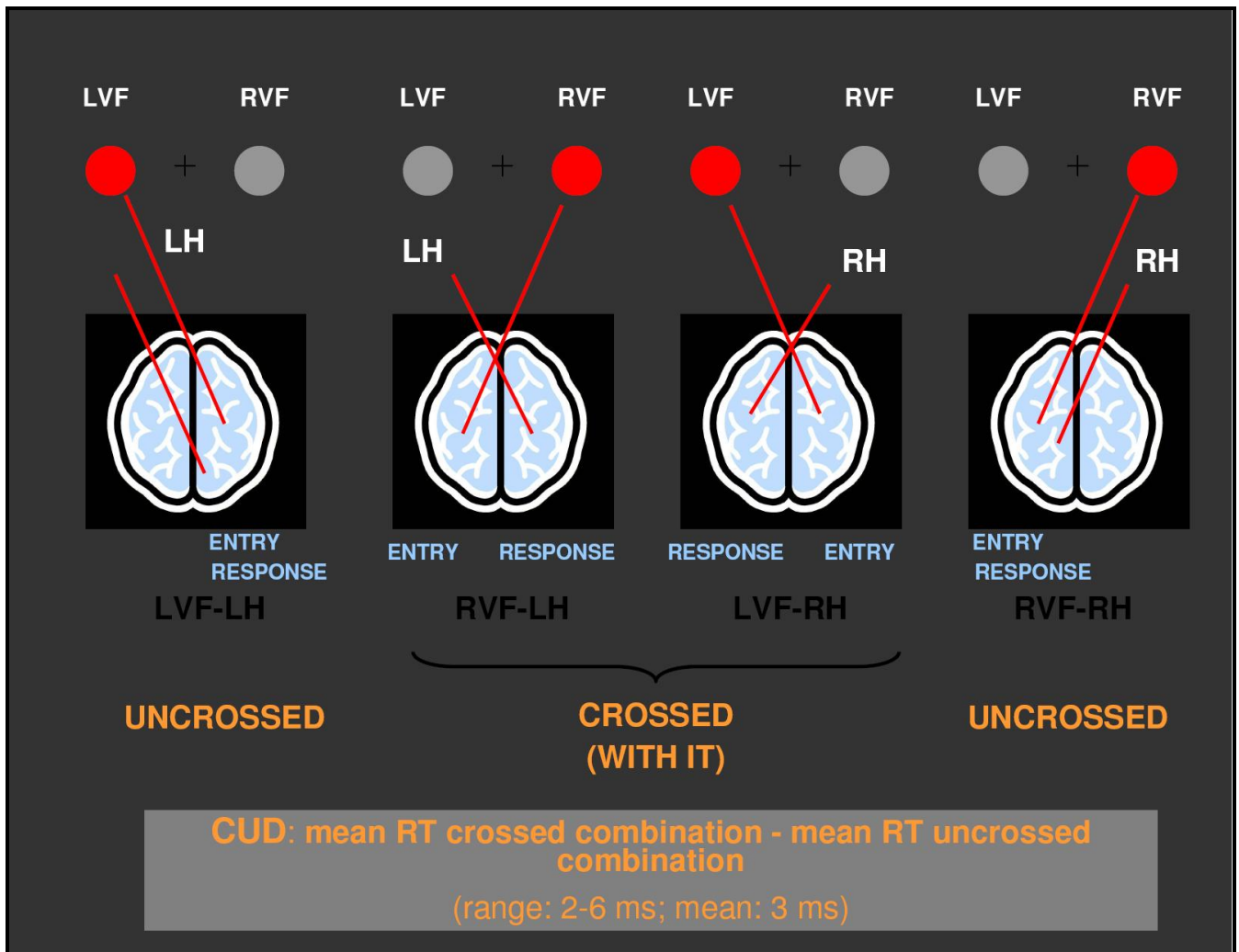
3.3 MRI Procedures

MRI scans are acquired with a 3T Siemens Magnetom Allegra (Brain-dedicated) at the Section of Neuroradiology (Dr. Alberto Beltramello, Dr Franco Alessandrini and Dr Giada Zoccatelli) at the Civil Hospital of Verona (AOUI). A standard head coil is used for RF transmission and reception of the MR signal and restraining foam pads will be utilized for minimizing head motion. To minimize the risk of anxiety reactions research subjects were taken to the MRI centre and assisted throughout the whole MRI session by research assistants (S.C; V.M).

3.4 Behavioural Paradigm

An event-related (ER) design is used for the presentation of stimuli (the Poffenberger paradigm, Poffenberger 1912, see Figure 4). Visual stimuli are back-projected onto a nonmagnetic rear screen positioned into the scanner and subjects respond with the index finger of the right or left hand through a button response unit. Stimuli are randomized and visually displayed using IFIS-SA system (MRI Devices). The subject's head is stabilized with adjustable padded restraints on both sides. Subjects will be told to remain as still as possible throughout the experiment All participants wear earplugs For each condition (right and left hand response; right, left and bilateral visual field presentation) 30 stimuli are presented. The exposure duration of each stimulus is 100 ms and the Inter-Stimulus Interval (ISI), i.e. the temporal interval between the warning signal and the target stimulus, ranged from 2 to 5 seconds with an Inter-Trial Interval (ITI) of 1 second. The so called "Button Response Unit" is used to record Response Time of all subjects simultaneously with the imaging for each condition.

Figure 4. The Poffenberger Paradigm (LVF= left visual field; RVF= right visual field; LH= left hand; RH=right hand; CUD=crossed uncrossed difference).



3.5 MRI sequences and analyses

Functional Magnetic resonance imaging is a neuroimaging technique used to study activity in the brain. It shows which structures are active during particular mental operations and measure hemodynamic signals related to neural activity in the brain. With this technique, it is assumed that an area is relatively more active when it has more oxygenated blood compared to another point in time. This is based on the principle that when a brain region is being used, arterial oxygenated blood will redistribute and increase to this area. This signal difference is known as BOLD contrast.

MRI data are acquired on a 3-Tesla MR imaging unit (MAGNETOM Allegra, Siemens, Erlangen, Germany) with a standard head coil. The T2*-weighted images were obtained using a gradient-echo EPI-BOLD pulse sequence (TR 2000msec, TE 30msec, FOV 192x192, slice thickness 3mm, 31 slices, flip angle 75°, matrix 64x64, volume 364).

Slices are aligned to the anterior and posterior commissure. High-resolution MPRAGE T₁-weighted structural images are then acquired (TR 2300msec, TE 3.93msec, FOV 256x256, slice thickness 1 mm, flip angle 12°, matrix 256x256, 160 slices).

The first two images are discarded to allow for stabilization of the T₂*-weighted signal.

Pre-processing of functional MRI consisted in several phases, as three-dimensional motion correction, slice scan time correction (sin interpolation), linear trend removal by temporal high-pass filtering (3 cycles in time course) and transformation into the Talairach coordinate space. The images were temporally and spatially smoothed using a 8 mm Gaussian filter (FWHM) to allow adequate spatial localization. No subject moved more than 3 mm.

In each subject, activated voxels are identified with a single-subject general linear model (GLM) approach for time series data. Brain activation is detected by comparing BOLD

signal intensities in fMRI images during the stimulation period (visual stimuli) and at rest period (fixation point).

The functional data have been firstly analyzed using Brain Voyager (QX version 1.9 Brain Innovation, Maastricht, The Netherlands) (Dr. G. Zoccatelli) and then data analysis was performed by Dr M. Aztori in MATLAB R2008 (Math Works, Natick, MA) using Statistical Parametric Mapping software (SPM8, Wellcome Department of Cognitive Neurology, London, UK).

First, fMRI scans were realigned within sessions, and the realignment parameters were saved in a text file.

The template included in SPM8 conforms to the space defined by the ICBM, NIH P-20 project, and approximate that of the space described in the Talairach and Tournoux atlas.

The stereotaxically normalized fMRI scans were smoothed through a Gaussian filter of (10 x 10) mm².

Statistical analyses were performed on each subject according to the general linear model for fMRI data devised by Friston et al. (1995). To model the hemodynamic response canonical hemodynamic response function with time and dispersion derivatives were used. The temporal realignment parameters were used as regressors.

Only regional activations significant at $P < 0.05$ corrected with the Family Wise Error and regional activations significant at $P < 0.001$ uncorrected were considered in the evaluation of the two samples t-test results.

In group analysis, fMRI scans were realigned within session and scans normalized into the standard stereotaxic space of Talairach to allow inter-subject data averaging and comparison across tasks.

Pre-processing

- fMRI realignment
- Co-registration
- Normalization
- Smoothing (kernel 8mm)

First level analyses

Generalized Linear model (GLM)

Second level analyses

One sample and two sample t-test

We used a random-effect group analysis and comparison between experimental conditions were performed as main effects according to a subtractive design.

The main effect of right visual field is calculated according to the formula:

$$(RVF/RH) + (RVF/LH) - (LVF/LH) + (LVF/RH)$$

while the main effect of left visual field was calculated as:

$$(LVF/LH) + (LVF/RH) - (RVF/RH) + (RVF/LH).$$

We considered also the main effect of right hand as:

$$(RVF/RH) + (LVF/RH) - (LVF/LH) + (RVF/LH)$$

and the effect of left hand as:

$$(LVF/LH) + (RVF/LH) - (RVF/RH) + (LVF/RH)$$

We also consider the effect of double visual field stimulation as:

$$(DVF/RH) - [(LVF/RH) + (RVF/RH)] \text{ and: } (DVF/LH) - [(LVF/LH) + (RVF/LH)].$$

The statistical threshold is set at $p < 0.001$

The principle effect of crossed condition is calculated by subtractions of crossing conditions $(RVF/LH) + (LVF/RH)$ minus uncrossing conditions $(RVF/RH) + (LVF/LH)$, and vice versa $(RVF/RH) + (LVF/LH) - (RVF/LH) + (LVF/RH)$.

The statistical threshold is set at $p < 0.0001$ (uncorrected).

4. Results

The recruitment is ongoing and 65 control subjects and 26 schizophrenic patients entered the study so far. For this experiment 24 SCZ and 44 HC were included for preliminary analyses. The two groups were then matched to control main confounding variables (gender and age).

The final groups for this preliminary analysis were composed by 21 HC and 21 SCZ (see Table 3 and 4 for sample's features).

4.1 Functional Imaging in HC and SCZ (Crossed Uncrossed Difference)

We performed separate One Sample t-test CUD for controls and for patients. The blood oxygenation level-dependent (BOLD) response was present in the genu of corpus callosum in males and females separately and in the whole group ($p < 0.01$ uncorrected) (Fig 5 a), b), c)) of HC. In the patient group, no clear activation has been shown with $p < 0.001$; with $p < 0.01$ there is a diffuse hyperactivation. (Figure 6).

4.2 Functional Imaging in HC compared to SCZ (Crossed Uncrossed Difference)

The comparison of the entire group of schizophrenic patients and healthy controls is detailed in Table 5 and in Table 6. Hyper-activations and hypo-activations were found in the schizophrenic patients in comparison to the healthy controls depending on the area of the brain and on the task. The blood oxygenation level-dependent (BOLD) response was higher in the pre-central gyrus (frontal motor cortex), in the middle frontal gyrus, inferior

frontal gyrus, post central gyrus (parietal sensory cortex), and in the putamen for the crossed uncrossed difference condition (Fig 7a). With $p < 0.01$ (uncorrected) activations were wider and also included corpus callosum (Fig 7b). Hyper-activation was also obtained for the crossed condition in the precentral gyrus, postcentral gyrus, inferior frontal gyrus and in the insulae.

Interestingly, when females and males are analysed separately, significant hyperactivations persisted only in female SCZ patients (see Table 5) excepted for putamen and precentral gyrus that were no more significant.

Table 3. Subjects recruitment: results.

	SCHIZOPHRENIA PATIENTS (SCZ)	HEALTHY CONTROLS (HC)
ENROLLED	26	68
INCLUDED IN THIS EXPERIMENT	25*	44*
MATCHED**	21	21

*1 excluded for abnormalities in the MRI scan.

**matching for age and gender.

Table 4_Sample's features.

	Healthy controls (N=21)	Patients (N=21)	Statistics	
Age (years)	31.95±5.38	34.86±8.42	t=-1.33	p=0.19
Gender (female/male)	7/14	7/14	$\chi^2=0$	p=1
Age at onset		25.65±6.85		
Length of illness		9.5±8.46		
Hospital admissions		2.57±3.92		
EQ_ATYPICAL		257.08		
EQ_TYPICAL		96.39		
TOT_EQ_AP		234.58		
AP lifetime (years)		5.58±6.65		
GAF	83.87±5.93	45.95±14.12	t=9.77	p=0.00
PANSS (positive scale)		15.6±6.48		
PANSS (negative scale)		18.6±8.02		
PANSS (psychopathology scale)		32.35±9.26		

PANSS (total score)		66.55±19.91		
Handedness (right/not right)	19/1	19/1	$\chi^2=0$	$p=1$
Drug (lifetime)(no/yes)	21/0	17/4	$\chi^2=4.421$	$p=0.107$
Alcohol (lifetime) (no/yes)	21/0	18/3	$\chi^2=3.231$	$p=0.232$
Smoke (lifetime)(no/yes)	14/7	7/14	$\chi^2=4.667$	$p=0.31$
Smoke (no/yes)	15/6	8/13	$\chi^2=4.709$	$p=0.30$

Table 5. Results: patients and Healthy controls. Significant Hyper-Activation for Schizophrenia patients ($p < 0.001$ uncorrected).

	Males and Females	Males	Females
Crossed Uncrossed Difference	Precentral Gyrus		Inferior Frontal Gyrus
	Putamen		Postcentral Gyrus
	Middle Frontal Gyrus		Middle Frontal Gyrus
Crossed	Postcentral Gyrus	Precentral Gyrus	Insulae
	Insulae	Right Insula	Inferior Frontal Gyrus

Table 6. Results: patients and healthy controls. Hypo-Activation of Schizophrenia patients in comparison to healthy controls ($p < 0.001$ uncorrected).

	Males and Females	Males	Females
Crossed			Posterior Cingulate
Uncrossed	Middle Frontal Gyrus	Putamen	Middle Frontal Gyrus
	Middle Temporal Gyrus		Middle Temporal Gyrus
			Posterior Cingulate

Figure 5. Healthy Controls. a) males ; b) females and c) males and females together. All $p < 0.01$. Colored blobs represent activations in the genu of corpus callosum in the CUD.

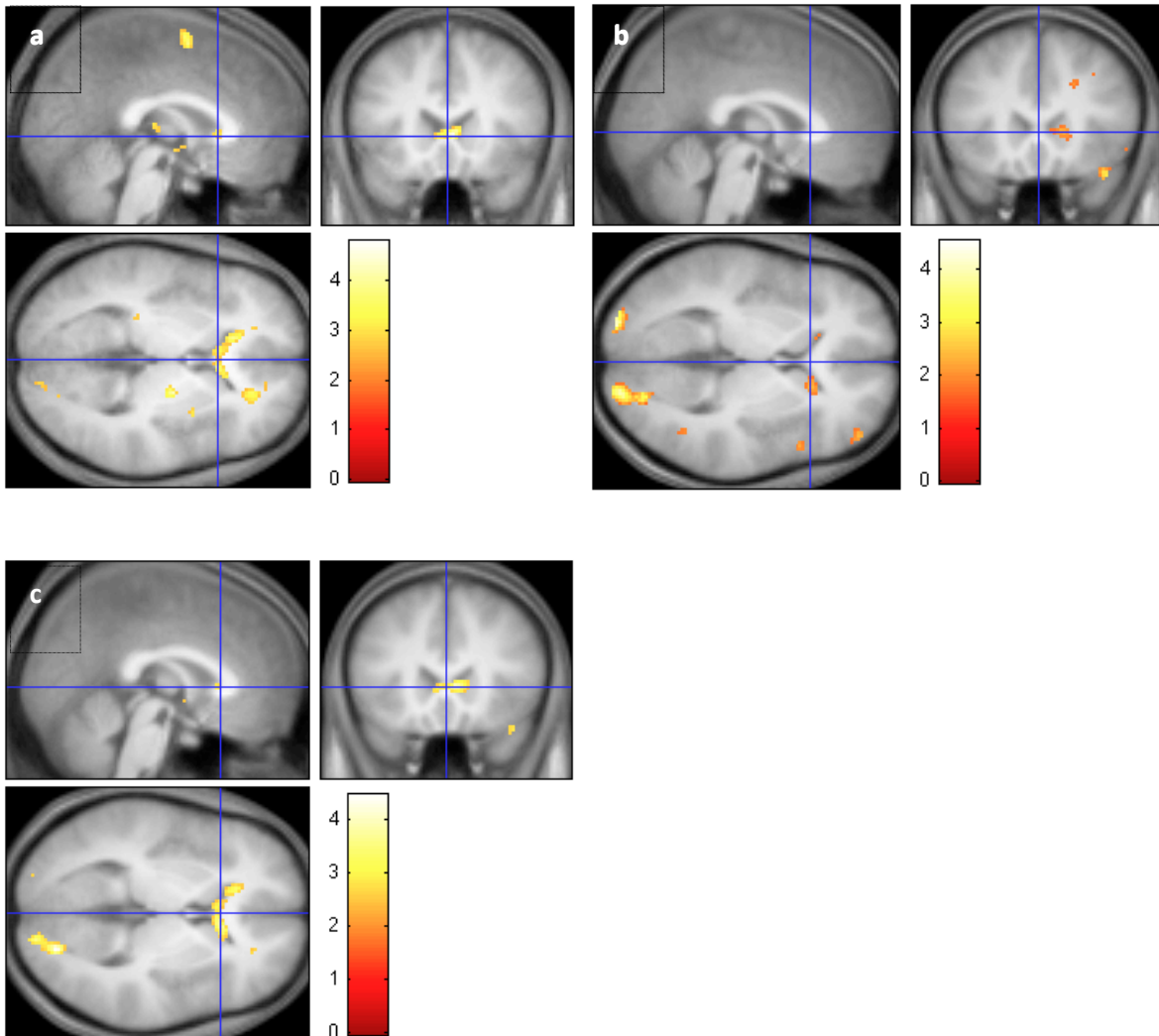


Figure 6. Results: Patients. One Sample t-test for the Crossed Uncrossed Difference ($p < 0.001$).

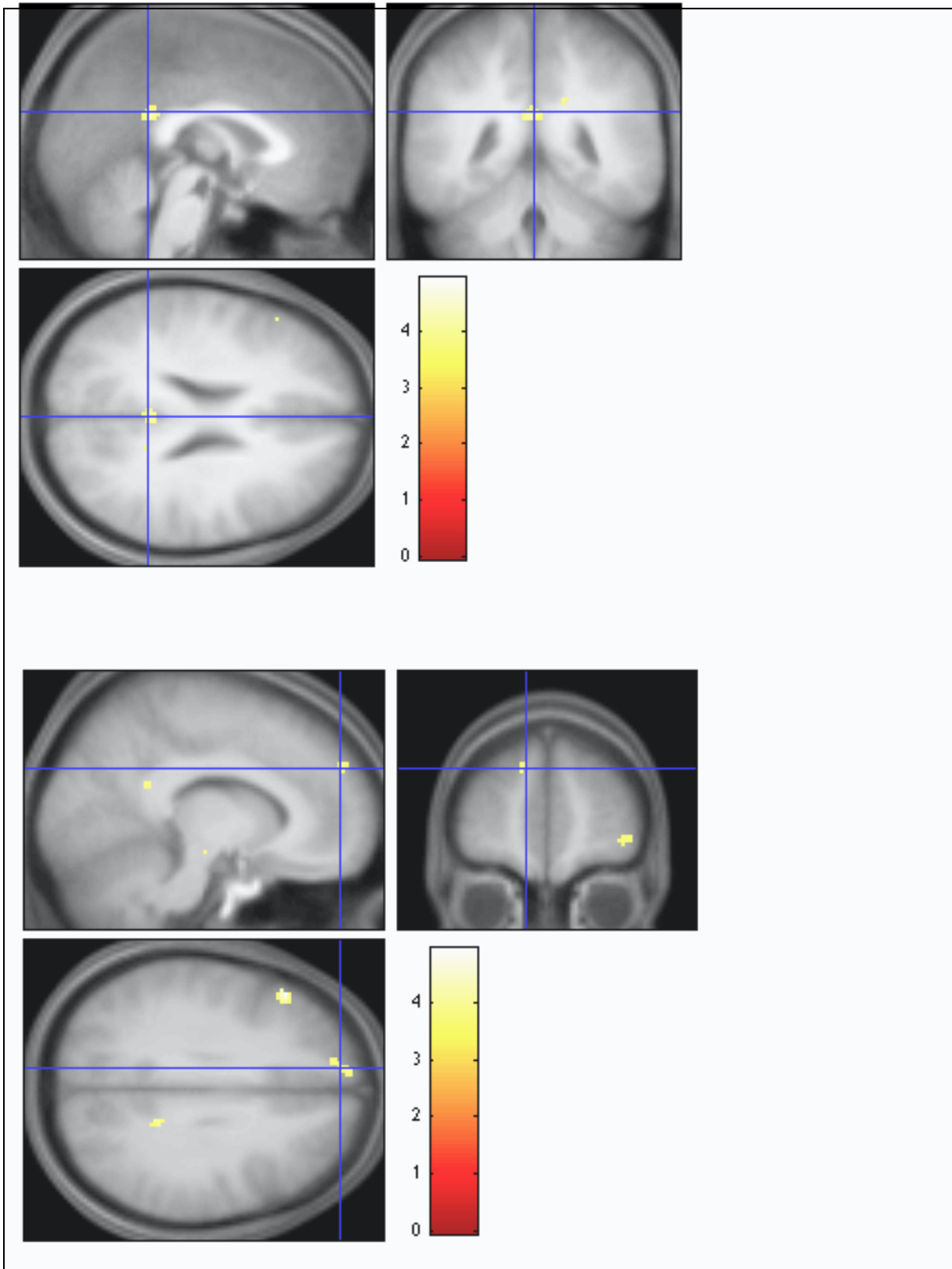


Fig. 7a. Healthy Controls vs Schizophrenia patients, hyperactivations in Schizophrenia patients $p < 0.001$ uncorrected in the CUD condition.

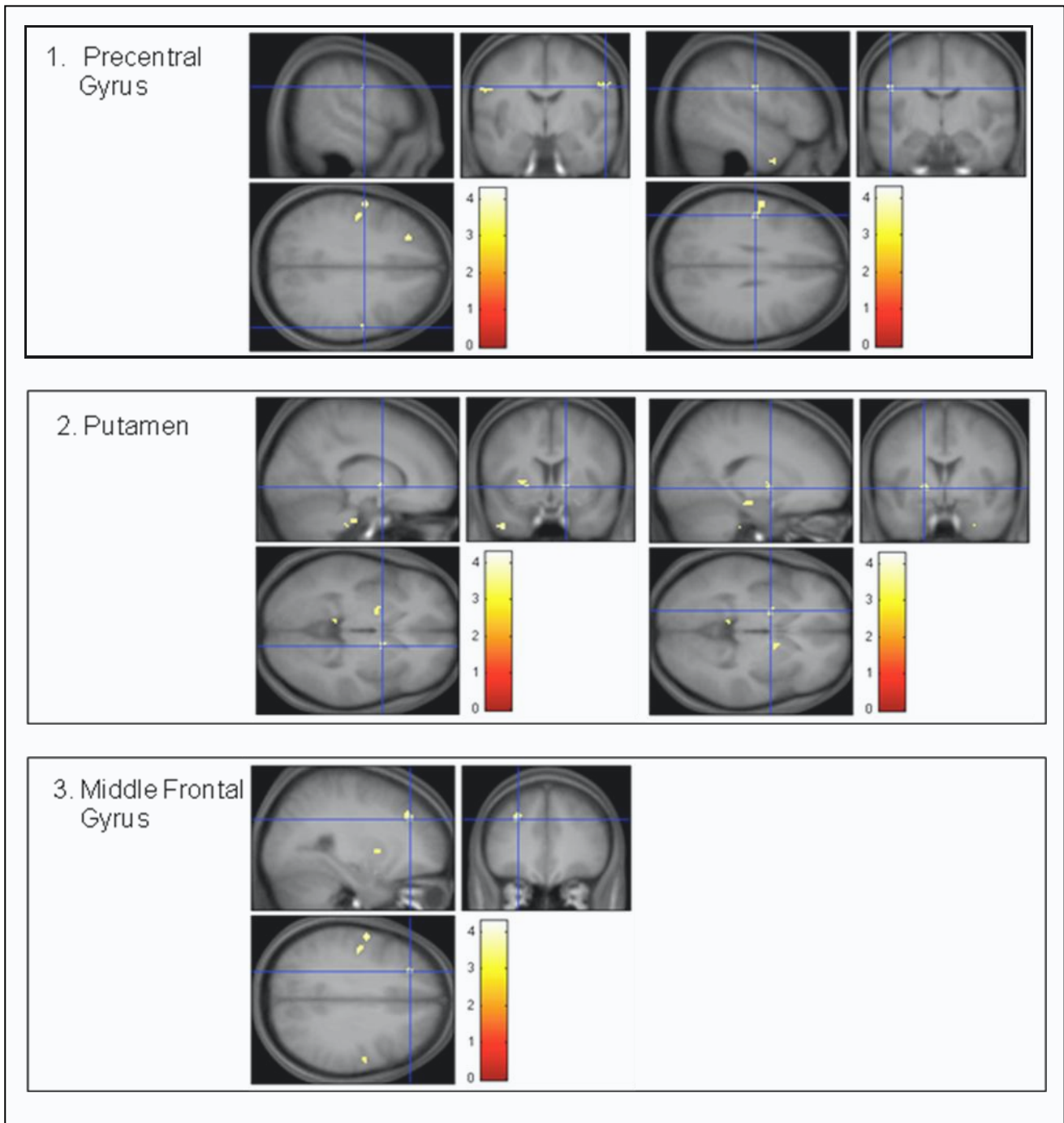
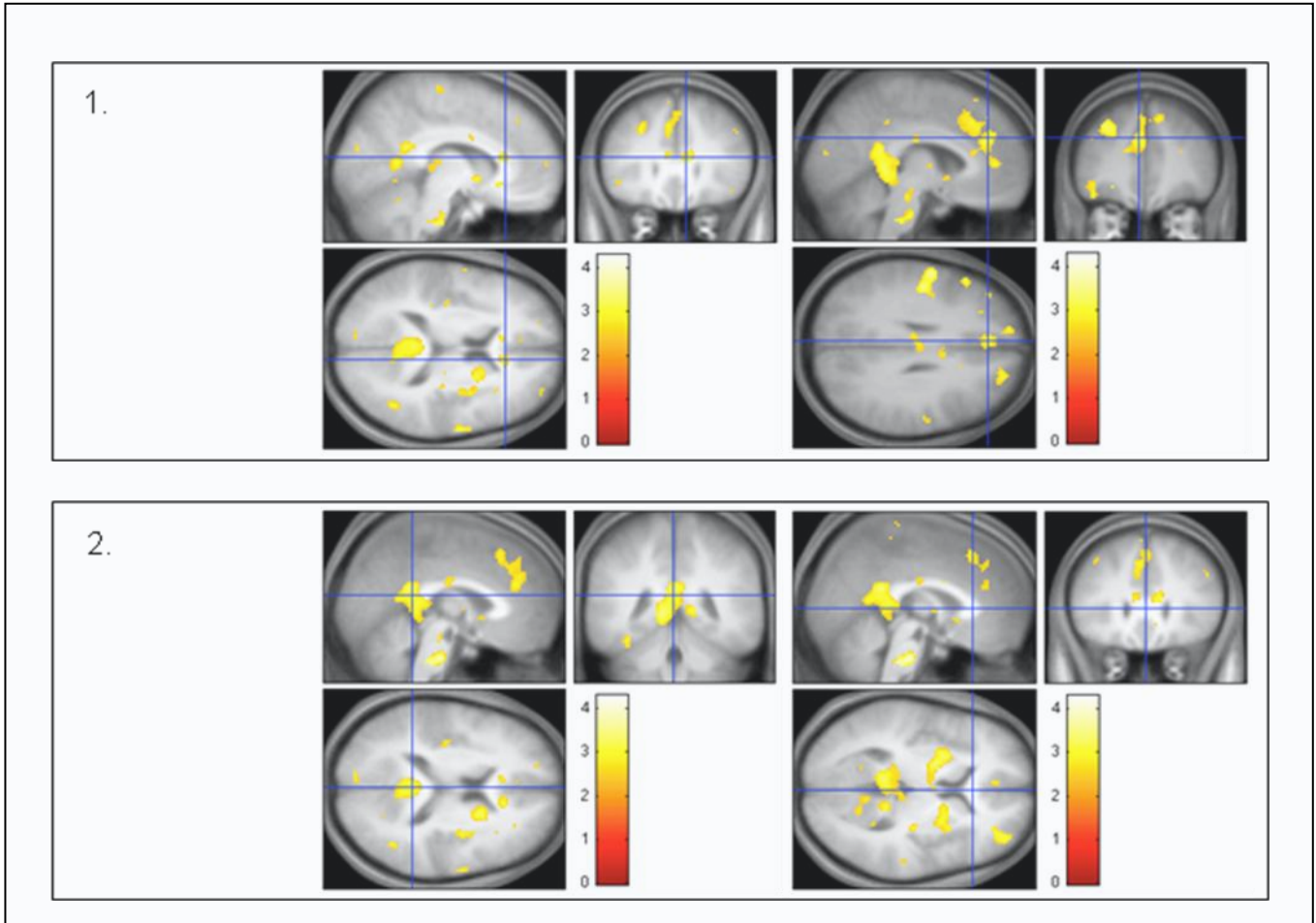


Fig.7b. Healthy Controls vs Schizophrenia patients: hyperactivations in Schizophrenia patients $p < 0.01$ uncorrected in the CUD condition.



5. Discussion

Healthy controls.

We tested the hypothesis that interhemispheric transmission (IT) of visuomotor information requires the corpus callosum using event-related functional magnetic resonance imaging (fMRI), in order to investigate the neural correlates of basic interhemispheric visuo-motor integration in a large cohort of healthy subjects. Our results confirmed previous published studies in humans that tested the implication of corpus callosum in visuo-motor task (Weber et al., Tettamanti et al., 2002; Omura et al., 2004; Mazerolle et al., 2008). In particular, our results confirmed the structure-function relationship that involves brain interhemispheric processes in a large sample of healthy subjects and referred to a specific activation restricted in the genu of corpus callosum. The genu is thought to be associated with the prefrontal cortex and Mazerolle et al. 2008, using tractography, recently linked white matter activation of the genu with the grey matter activation of inferior frontal lobes. Differently, Tettamanti et al. 2002 linked genu activation to the premotor interhemispheric transfer and suggested that the genu transmits visuomotor information to prepare the ipsilateral hemisphere to perform hand movements triggered by the contralateral hemisphere. We will further expand these analyses and explore these relationship including the whole recruited population of healthy controls (67 subjects).

Patients vs Healthy controls.

We investigated the role of the CC in regulating functional communication between the hemispheres in schizophrenia patients to delineate the inter-hemispheric connectivity in this disease. Hyper-activations and hypo-activations were found in the schizophrenic patients in comparison to the healthy controls, depending on the area of the brain and on

the task. The blood oxygenation level-dependent (BOLD) response was higher in frontal and parietal areas and putamen in the crossed uncrossed condition, suggesting that patients need a major effort to perform the task in term of executive and motor functions. Interestingly, also putamen presented hyperactivation, possibly reflecting its major functions in regulating movement and in learning. With $p < 0.01$ (uncorrected) activations were wider and also included corpus callosum.

These results confirmed previous results in humans that tested the implication of corpus callosum in visuo-motor task. In particular these results confirmed the structure function relationship that involves interhemispheric processes.

These results may reflect a brain diffuse overwork related to the demanding task that is not present in healthy subjects. Moreover, schizophrenia is characterized by well described deficits in executive functions and the corresponding area in the corpus callosum white matter (the genu) is probably involved in the pathophysiology of the neurocognitive impairment.

Schulte et al. 2010 demonstrated that subtle white matter fiber degradation attenuated normal pattern of connectivity, and there are growing evidence of reduced Fractional Anisotropy (FA) in corpus callosum, that is a measure of the integrity of myelin fibers. We have very preliminary results of DTI data (Diffusion Tensor Imaging) with TBSS (Tract-Based Spatial Statistics) that demonstrated reduced FA in this sample of schizophrenia patients, confirming the white matter pathology that functional data suggested. Moreover tractography will be applied to some selected white matter fibers, resulted to be significant in the DTI complete TBSS analysis.

Further analyses will be performed in collaboration with the Wayne State University to confirm these preliminary results and to extend the analyses to the bipolar patients.

Further investigations in the context of the PREVENT study will also allow to couple neuropsychological data, multimodal fMRI and specific immune gene expression and test them as possible endophenotypes for schizophrenia.

6. References

- Amaddeo & Tansella (2009). Information systems for mental health. *Epidemiology and Psychiatric Sciences* 18,1-4.
- Aboitiz F. (1992). Brain connections: interhemispheric fiber systems and anatomical brain asymmetries in humans. *Biological Research* 25, 51-61.
- Andreasen, N., Nopoulos, P., O'Leary, D., Miller, D., Wassink, T., Flaum, M., (1999). Defining the phenotype of schizophrenia: cognitive dysmetria and its neural mechanisms. *Biol. Psychiatry* 46, 908–920.
- Barnett, K., Kirk, I., (2005). Lack of asymmetrical transfer for linguistic stimuli in schizophrenia: an ERP study. *Clin. Neurophysiol.* 116, 1019–1027.
- Barnett, K., Corballis, M., Kirk, I., (2005). Symmetry of callosal information transfer in schizophrenia: a preliminary study. *Schizophr. Res.* 74, 171–178.
- Bartzokis, G., (2002). Schizophrenia: breakdown in the well-regulated lifelong process of brain development and maturation. *Neuropsychopharmacology* 27, 672–683
- Bartzokis G. & Altshuler L. (2005). Reduced intracortical myelination in schizophrenia. *American Journal of Psychiatry* 162, 1229-30.
- Bellani M., Marzi C.A. & Brambilla P. (2009). Interhemispheric communication in schizophrenia. *Epidemiologia e Psichiatria Sociale* 18, 19-22.

- Bellani M., Marzi C.A. Savazzi S., Perlini C., Cerruti S., Ferro A., Marinelli V., Sponda S., Rambaldelli G., Tansella M. & Brambilla P. (2010). Laterality effects in schizophrenia and bipolar disorder. *Exp Brain Res.* 201, 339-44.
- Davis K.L., Stewart D.G., Friedman J.I., Buchsbaum M., Harvey P.D., Hof P.R., Buxbaum J. & Haroutunian V. (2003). White matter changes in schizophrenia: evidence for myelin-related dysfunction. *Archives of General Psychiatry* 60, 443-56.
- Diwadkar V.A., De Bellis M.D., Sweeney J.A., Pettegrew J.W. & Keshavan M.S. (2004). Abnormalities in MRI-measured signal intensity in the corpus callosum in schizophrenia. *Schizophrenia Research* 67, 277-282.
- Dubb A., Gur R., Avants B. & Gee J. (2003). Characterization of sexual dimorphism in the human corpus callosum. *Neuroimage* 20, 512-519.
- Ellison-Wright, I., Bullmore, E., (2009). Meta-analysis of diffusion tensor imaging studies in schizophrenia. *Schizophr. Res.* 108, 3–10.
- Endrass, T., Mohr, B., Rockstroh, B., (2002). Reduced interhemispheric transmission in schizophrenia patients: evidence from event-related potentials. *Neurosci. Lett.* 320, 57–60.
- Feinberg I. (1982). Schizophrenia: caused by a fault in programmed synaptic elimination during adolescence? *Journal of Psychiatric Research* 17, 319-334.
- Florio V., Fossella S., Maravita A., Miniussi C. & Marzi C.A. (2002). Interhemispheric transfer and laterality effects in simple visual reaction time in schizophrenics. *Cognitive Neuropsychiatry* 7, 97-111.

- Friston K.J. & Frith C.D. (1995). Schizophrenia: a disconnection syndrome? *Clinical Neuroscience* 3, 89-97.
- Gavrilescu M., Rossell S., Stuart G.W., Shea T.L., Innes-Brown H., Henshall K., McKay C., Sergejew A.A., Copolov D., Egan G.F. (2010). Reduced connectivity of the auditory cortex in patients with auditory hallucinations: a resting state functional magnetic resonance imaging study. *Psychol Med.* 40,1149-58.
- Gazzaniga M.S. (2000). Cerebral specialization and interhemispheric communication: does the corpus callosum enable the human condition? *Brain* 123, 1293-1326.
- Highley J.R., Esiri M.M., McDonald B., Cortina-Borja M., Herron B.M. & Crow T.J. (1999). The size and fibre composition of the corpus callosum with respect to gender and schizophrenia: a post-mortem study. *Brain* 122, 99-110.
- Hofer S. & Frahm J. (2006). Topography of the human corpus callosum revisited—comprehensive fiber tractography using diffusion tensor magnetic resonance imaging. *Neuroimage* 32, 989-994.
- Iacoboni M. & Zaidel E. (2004). Interhemispheric visuo-motor integration in humans: the role of the superior parietal cortex. *Neuropsychologia* 42, 419-425.
- Keller A., Jeffries N.O., Blumenthal J., Clasen L.S., Liu H., Giedd J.N. & Rapoport J.L. (2003). Corpus callosum development in childhood-onset schizophrenia. *Schizophrenia Research* 105-114.
- Luders E., Rex D.E., Narr K.L., Woods R.P., Jancke L., Thompson P.M., Mazziotta J.C. & Toga A.W. (2003). Relationships between sulcal asymmetries and corpus callosum size: gender and handedness effects. *Cerebral Cortex* 13, 1084-1093.

- Marzi C.A., Bisiacchi P., Nicoletti R. (1991). Is interhemispheric transfer of visuomotor information asymmetric? Evidence from a meta-analysis. *Neuropsychologia* 29,1163-77.
- Marzi C.A. (1999). The Poffenberger paradigm: a first, simple, behavioural tool to study interhemispheric transmission in humans. *Brain Research Bulletin* 50, 421-422.
- Mazerolle E.L., D'Arcy R.C., Beyea S.D. (2008). Detecting functional magnetic resonance imaging activation in white matter: interhemispheric transfer across the corpus callosum. *BMC Neuroscience* 9,84.
- Mazzi F., Morosini P., De Girolamo G., Lussetti M. & Guaraldi G.P. (2000, 2007). SCID-I Interviste cliniche strutturate per il DSM-IV, Giunti OS Organizzazioni Speciali, Firenze.
- Mohr B., Pulvermuller F., Cohen R. & Rockstroh B. (2000). Interhemispheric cooperation during word processing: evidence for callosal transfer dysfunction in schizophrenic patients. *Schizophrenia Research* 46, 231-239.
- Omura K., Tsukamoto T., Kotani Y., Ohgami Y., Minami M. & Inoue Y. (2004). Different mechanisms involved in interhemispheric transfer of visuomotor information. *Neuroreport* 15, 2707-11.
- Ota M., Obata T., Akine Y., Ito H., Ikehira H., Asada T. & Suhara T. (2006). Age-related degeneration of corpus callosum measured with diffusion tensor imaging. *Neuroimage* 31, 1445-1452.

- Pandya D.N., Karol E.A. & Heilbronn D. (1971). The topographical distribution of interhemispheric projections in the corpus callosum of the rhesus monkey. *Brain Research* 32, 31-43.
- Poffenberger A.T. (1912). Reaction time to retinal stimulation with special reference to the time lost in conduction through nervous centers. *Archives of Psychology* 23, 1-73.
- Schummers J., Yu H. & Sur M.(2008). Tuned responses of astrocytes and their influence on hemodynamic signals in the visual cortex *Science* 320,1638-43.
- Shelton E.J. & Knight R.G. (1984). Inter-hemispheric transmission times in schizophrenics. *British Journal of Clinical Psychology* 23, 227-228.
- Schulte T., Sullivan E.V., Muller-Oehring E.M., Adalsteinsson E. & Pfefferbaum A. (2005). Corpus callosal microstructural integrity influences interhemispheric processing: a diffusion tensor imaging study. *Cerebral Cortex* 15, 1384-1392.
- Spitzer R.L., Williams J.B., Gibbon M. & First M.B. (1994). Structured Clinical Interview for DSM-III-R (SCID). Washington, D.C., American Psychiatric Press.
- Stephan, K., Friston, K., Frith, C., 2009. Dysconnection in schizophrenia: from abnormal synaptic plasticity to failures of self-monitoring. *Schizophr. Bull.* 35, 509–527.
- Tettamanti M., Paulesu E., Scifo P., Maravita A., Fazio F., Perani D. & Marzi C.A. (2002). Interhemispheric transmission of visuomotor information in humans: fMRI evidence. *Journal of Neurophysiology* 88, 1051-1058.
- Uranova N.A., Vostrikov V.M., Orlovskaya D.D. & Rachmanova V.I. (2004). Oligodendroglial density in the prefrontal cortex in schizophrenia and mood

disorders: a study from the Stanley Neuropathology Consortium. *Schizophrenia Research* 67, 269-75.

Weber B., Treyer V., Oberholzer N., Jaermann T., Boesiger P., Brugger P., Regard M., Buck A., Savazzi S. & Marzi C.A. (2005). Attention and interhemispheric transfer: a behavioral and fMRI study. *Journal of Cognitive Neuroscience* 17, 113-123.

Westerhausen R., Kreuder F., Woerner W., Huter R.J., Smit C.M., Schweiger E. & Wittling W. (2006). Interhemispheric transfer time and structural properties of the corpus callosum. *Neuroscience Letters* 409, 140-145.

Whitford, T.J., Kubicki, M., Schneiderman, J.S., O'Donnell, L.J., King, R., Alvarado, J.L., Khan, U., Markant, D., Nestor, P.G., Niznikiewicz, M., McCarley, R.W., Westin, C.-F., Shenton, M.E., 2010a. Corpus callosum abnormalities and their association with psychotic symptoms in patients with schizophrenia. *Biol. Psychiatry* 68, 70–77.

Whitford, T.J., Kubicki M, Ghorashi S, Schneiderman JS, Hawley KJ, McCarley RW, Shenton ME, Spencer KM, 2011. Predicting inter-hemispheric transfer time from the diffusion properties of the corpus callosum in healthy individuals and schizophrenia. *NeuroImage* 54,2318-29.

