

## *Clinical Report*

# Clinical and Radiographic Delineation of Odontochondrodysplasia

**Sheila Unger,<sup>1,2\*</sup> Franco Antoniazzi,<sup>3</sup> Milena Brugnara,<sup>3</sup> Yasemin Alanay,<sup>4</sup> Ahmet Caglayan,<sup>5</sup> Katherine Lachlan,<sup>6</sup> Shiro Ikegawa,<sup>7</sup> Gen Nishimura,<sup>8</sup> Bernhard Zabel,<sup>1,2</sup> Jürgen Spranger,<sup>1</sup> and Andrea Superti-Furga<sup>1</sup>**

<sup>1</sup>Centre for Pediatrics and Adolescent Medicine, University of Freiburg, Freiburg, Germany

<sup>2</sup>Institute of Human Genetics, University of Freiburg, Freiburg, Germany

<sup>3</sup>Department of Genetics, University of Verona, Verona, Italy

<sup>4</sup>Department of Pediatrics, Division of Clinical Genetics, Hacettepe University, Ankara, Turkey

<sup>5</sup>Department of Medical Genetics, Erciyes University Medical Faculty, Kayseri, Turkey

<sup>6</sup>Wessex Clinical Genetics Service, Princess Anne Hospital, Southampton, UK

<sup>7</sup>Laboratory of Bone and Joint Diseases, SRC, Riken, Japan

<sup>8</sup>Department of Radiology, Tokyo Metropolitan Kiyose Children's Hospital, Tokyo, Japan

Received 3 September 2007; Accepted 2 November 2007

The association of dentinogenesis imperfecta (DI) with a distinct form of chondrodysplasia in a boy was reported by Goldblatt et al. [1991; *Am J Med Genet* 39:170–172] and has been given the name of Goldblatt syndrome or odontochondrodysplasia (ODCD; OMIM#184260). Since the original description, only four further individuals have been reported (one sib pair and two unrelated cases). We report on an additional six individuals, including a second sib pair (brother and sister), with clinical and radiographic features that cluster and thus confirm the nosologic status of this entity. The main radiographic features are congenital platyspondyly with coronal clefts, severe metaphyseal changes particularly of the hands, wrists, and knees, mesomelic limb shortening, and coxa valga. The main physical signs are short stature, joint laxity, narrow chest, scoliosis, and DI. This combination of clinical and radiographic findings allows clear recognition of this syndrome in

early childhood. Of note, the signs that are present in the newborn period are not entirely specific and the differential diagnosis includes spondylometaphyseal dysplasia (SMD) Sedaghatian type or platyspondylic lethal dysplasia (PSLD) Torrance type. The occurrence of two sib pairs in a group of only 11 patients suggests an autosomal recessive inheritance pattern. Overmodification of cartilage-extracted collagen 2 has been reported in two sibs, but mutation analysis of *COL2A1* as well as of *COMP*, *FGFR3*, *RMRP*, and *SBDS* in one or more patients have given negative results, and the molecular etiology is as yet unknown. © 2008 Wiley-Liss, Inc.

**Key words:** odontochondrodysplasia (ODCD); Goldblatt syndrome; dentinogenesis imperfecta (DI); spondylometaphyseal dysplasia

**How to cite this article:** Unger S, Antoniazzi F, Brugnara M, Alanay Y, Caglayan A, Lachlan K, Ikegawa S, Nishimura G, Zabel B, Spranger J, Superti-Furga A. 2008. Clinical and radiographic delineation of odontochondrodysplasia. *Am J Med Genet Part A* 146A:770–778.

### INTRODUCTION

Goldblatt et al. [1991] described a single child with an unusual combination of radiographic and clinical findings. Despite dentinogenesis imperfecta (DI) being a relatively specific sign for osteogenesis imperfecta (OI), Goldblatt et al. [1991], noted that their patient had white sclerae and no fractures or Wormian bones. The pattern of radiographic changes and its evolution over time appeared distinctive. A year later this conclusion was supported by the identification of two further cases

[Bonaventure et al., 1992]. These patients were a sib pair and the possibility of recessive inheritance was raised. A further two sporadic cases with very similar clinical-radiographic features were reported by

\*Correspondence to: Sheila Unger, Institute of Human Genetics, University of Freiburg, Breisacher Strasse 33, Freiburg, Germany.  
E-mail: sheila.unger@uniklinik-freiburg.de

DOI 10.1002/ajmg.a.32214

Maroteaux et al. [1996] and the name odontochondrodysplasia (ODCD) was proposed.

We report on six additional patients (two of which were sibs) with clinical and radiographic findings that are sufficiently homogeneous to confirm the status of ODCD as a distinct entity. At present, the underlying molecular defect is unknown and the mode of inheritance is uncertain and thus genetic counseling is difficult. The purpose in reporting these cases is to provide a more solid basis for recognition and diagnosis of this disorder in order to eventually determine the pattern of inheritance and the molecular pathogenesis.

ODCD can be classified radiographically as a spondylometaphyseal disorder as there is significant neonatal platyspondyly that improves somewhat over time and metaphyseal irregularities affecting all long bones. Most affected babies have prenatal onset of short stature, but there seems to be significant variability in the severity of the disorder with some children dying shortly after birth while others survive without problem. The severe but nonspecific skeletal abnormalities in the third trimester and at birth and the potential lethality in early childhood raise the possibility that some fetuses and young infants (in whom DI cannot be ascertained) are never recognized as having ODCD. It is therefore possible that ODCD is more common than the reported case numbers would suggest.

## CLINICAL REPORT

### Patient 1

This boy was born at term to healthy nonconsanguineous parents of Moroccan origin. He was

admitted to the neonatal intensive care unit because of respiratory distress. He was felt to have normal facial features. An abdominal ultrasound was normal, and an echocardiogram showed only a minimal patent ductus arteriosus. He also had a normal karyotype (46, XY). Unfortunately, he had ongoing respiratory difficulties and died at age 4 months. A diagnosis of severe spondylometaphyseal dysplasia, possibly of the Sedaghatian type, was made.

### Patient 2

This girl is the sister of Patient 1. She was born at 41 weeks gestation following a pregnancy that was uneventful aside from the detection of short long bones on ultrasound. Her Apgar scores were 5 at 1 min and 8 at 5 min. Her birth weight was 2.97 kg (10th centile), her birth length was 44 cm (<3rd centile), and her head circumference was 33 cm (3rd centile). She too suffered from significant respiratory distress requiring intubation. Fortunately, she improved rapidly and mechanical ventilation was discontinued after only a few hours. She had normal abdominal, cardiac, and brain ultrasounds. At last examination, she was 3 years and 9 months old. Her weight was 7.92 kg (<<3rd centile) and her height was 67 cm (<<3rd centile). Her facial features were normal aside from a prominent forehead and retrognathia (Fig. 1). Her thorax was still somewhat hypoplastic and mesomelic limb shortening was present (Fig. 1). She wore glasses for strabismus correction and had DI of the primary dentition. There was joint laxity, especially noticeable at the hands. She was delayed in walking (2 years) but her intellectual functioning was normal. Given the diagnosis of SMD-Sedaghatian type in her deceased

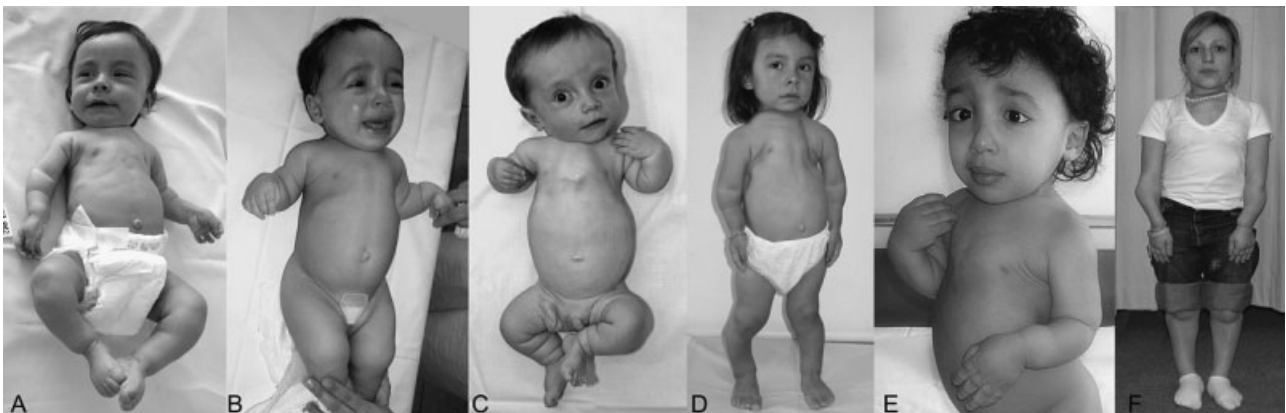


FIG. 1. Clinical photographs: **A:** Patient 3; in this early photograph, redundant skin folds are visible in both the upper and lower limbs but there is no clear mesomelia. The neck is short and the thorax is narrow giving the appearance of a protuberant abdomen. **B:** Patient 2 (at 1 year of age); this is similar to the Patient 3 photograph but the chest size is better preserved. **C:** Patient 6 (at 14 months of age); this patient also has multiple redundant skin folds best appreciated in this photograph in the lower limbs. There is also a narrow chest with prominent sternum and protuberant abdomen. **D:** Patient 3 (at 4 years of age); the thorax remains narrow with a pectus carinatum. The joint laxity is visible in the position of the knees and there is mesomelia. **E:** Patient 2 (at 4 years of age); the mesomelia is now more apparent and there is an exaggerated lumbar lordosis. **F:** Patient 4 (at 17 years of age); at this stage, not only is the mesomelia clear but brachydactyly is also evident. There is still an appearance of short neck. The patient has undergone surgery to correct severe crura vara (see Fig. 6, panel D for varus deformity prior to correction).

brother and the recent report of *SBDS* mutations in some cases of SMD-Sedaghatian type [Nishimura et al., 2007], this gene was analyzed but no alterations were found. The marked metaphyseal changes were reminiscent of metaphyseal enchondromatosis thus the patient's urine was analyzed by gas chromatography-mass spectrometry but no 2-D-hydroxyglutaric acid or other abnormal metabolites were detected [Bayar et al., 2005].

### Patient 3

This girl was the first child of healthy unrelated parents of Turkish origin. Short limbs were noted on third trimester ultrasound and at birth her length was 48 cm (10th centile). She was first examined at 13 months of age and at that time her length was 62 cm (<<3rd centile), her weight was 6 kg (<<3rd centile), and her head circumference was 45 cm (25th centile). She had minor facial dysmorphisms consisting of prominent forehead, depressed nasal bridge, and short nose (Fig. 1). She was noted to have generalized joint hypermobility, especially of both wrists. She had delayed appearance of the primary dentition and when her teeth did erupt there was DI (Fig. 2). Her intellectual development was normal. On last examination at four and a half years of age, her height was 77 cm (<<3rd centile) and her weight was 10 kg (<<3rd centile). At that age, she also underwent spinal surgery to correct the scoliosis.

### Patient 4

This girl was the second child born to healthy nonconsanguineous parents. Birth length was not recorded. She first came to medical attention at age 9 months because of delayed motor development. At age 10 months, her weight was 6.6 kg (3rd centile), her height was 60.8 cm (<<3rd centile), and her head circumference was 44 cm (10–25th centile). She had short limbs with significant bowing of the legs. This girl was originally given a diagnosis of pseudoachondroplasia, but molecular analysis of the *COMP* gene did not reveal any mutations (Manchester lab; Dr. M. Briggs). Given the metaphyseal changes on radiographs, *RMRP* was also sequenced to exclude cartilage-hair hypoplasia (CHH) and no mutations were found (Lausanne lab; Dr. Luisa Bonafé). Her primary dentition was not noted to be abnormal. However, her secondary dentition was discolored, the enamel detached easily and the teeth were prematurely worn (Fig. 2). IQ testing was normal. She underwent surgery for scoliosis at ages 7 and 10 years, as well as repeated osteotomies to correct severe varus deformity at the knees. At last follow-up at age 17,

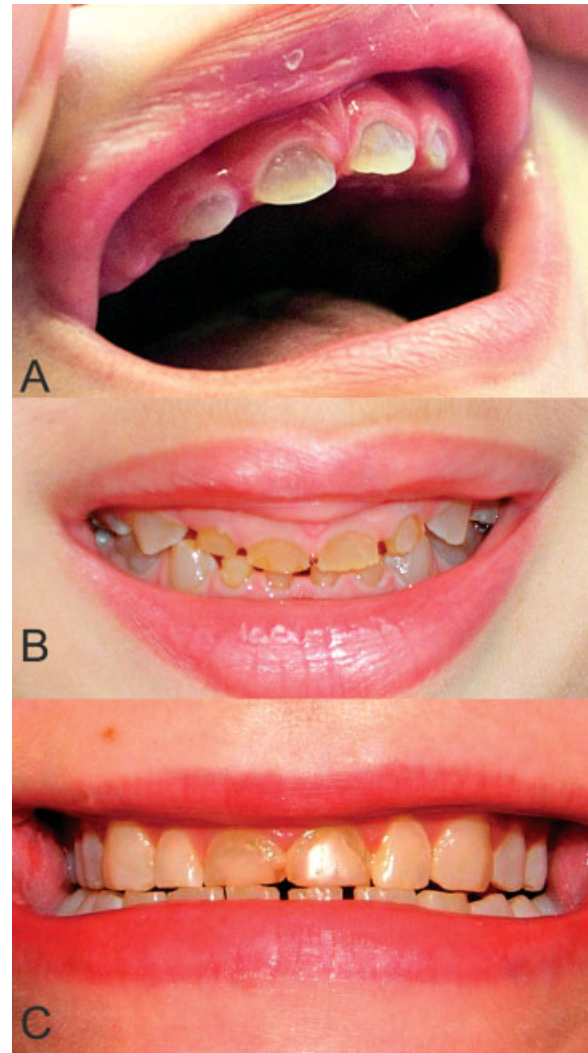


FIG. 2. The appearance of the primary dentition is indistinguishable from DI caused by osteogenesis imperfecta. The teeth are small, brownish, and fragile. DI is also seen in the permanent dentition of Patient 4. **A:** Patient 6, age 15 months; **B:** Patient 2, age 2 years; **C:** Patient 4, age 17 years.

her height was 109 cm (<<3rd centile), her weight was 28 kg (<<3rd centile), and her head circumference was 53.2 cm (10th centile).

### Patient 5

This girl is the first child of healthy unrelated parents of Turkish origin. The father was 22 years old and the mother 21 years old at the time the child was born. Birth length was reported as normal but we do not have the actual measurements. Examination at 4 years of age revealed DI but an otherwise normal facial features. Her height was 70 cm (<<3rd centile) and her head circumference was normal. She had brachydactyly and mesomelia of arms and legs. Her intellect was normal.



### Patient 6

This boy is the first child born to healthy unrelated parents. The mother is of South American origin and the father is German in origin. They were 38 and 35 years old, respectively, at the time of delivery. Short limbs were suspected on prenatal ultrasound and birth length was recorded as 48 cm (3rd centile) with a head circumference of 35 cm (25th centile). The diagnosis of PSLD Torrance type was considered but sequencing of *COL2A1* did not reveal any mutations. *FGFR3* was also sequenced to exclude PSLD San Diego type and this was also normal. The first teeth appeared at age 10 months and there was DI (Fig. 2). He was last seen at age 14 months and at that time his intellectual development was within normal limits but there was a delay in motor milestones. His length was 59 cm (<<3rd centile) and his head circumference was 49 cm (75th centile). There was marked ligamentous laxity particularly notable at the wrists that also had an expanded appearance.

## RADIOLOGICAL FINDINGS

### Patient 1

From this patient, only a babygram is available. All elements of the limbs are short but there is a hint of mesomelia in the lower limbs with the fibula being longer than the tibiae. The metaphyses of the long bones are flared with some cupping best seen in the radii and tibiae. There is also generalized platyspondyly and a small thorax (Fig. 3A).

### Patients 2, 3, 4, 5, and 6

The radiographic findings in all patients show a striking degree of similarity but with a clear evolution over time. From Patient 6, we have radiographs from the neonatal period. Platyspondyly is evident with multiple coronal clefts (Fig. 3B) and a distinctive asymmetry of ossification between the anterior and the posterior parts of the vertebral bodies, the posterior part being even more severely delayed. Radiographs of the knees and wrists show that metaphyseal changes are already present with cupping of the metaphyses of all long bones and increased distance between distal radius and ulna and the metacarpals. There is also a discrepancy between fibular and tibial lengths indicating mesomelia (Fig. 3A and 3D), a distinctive finding that persists through later ages.

**Hands.** Metaphyseal cupping (precursor to cone epiphyses) is visible from a very early age in essentially all metacarpals and the proximal phalanges. The metaphyseal changes worsen overtime to resemble enchondromatous like changes at the wrists (Fig. 4).

**Pelvis.** In the newborn, the pelvis is square in shape with a horizontal acetabulum. There is a mild trident configuration due in large part to the very narrow sacrosciatic notches. Over the first 2 years of life, the iliac wings develop a lacy border reminiscent of Dyggve–Melchior–Clausen syndrome (Fig. 5).

**Lower limbs.** With time, the mesomelia becomes more evident, the fibula is consistently longer than the tibia and genu varus develops. The degree of metaphyseal change at the knees also worsens (in some cases reminiscent of enchondromatosis) while the predominant finding at the hips is

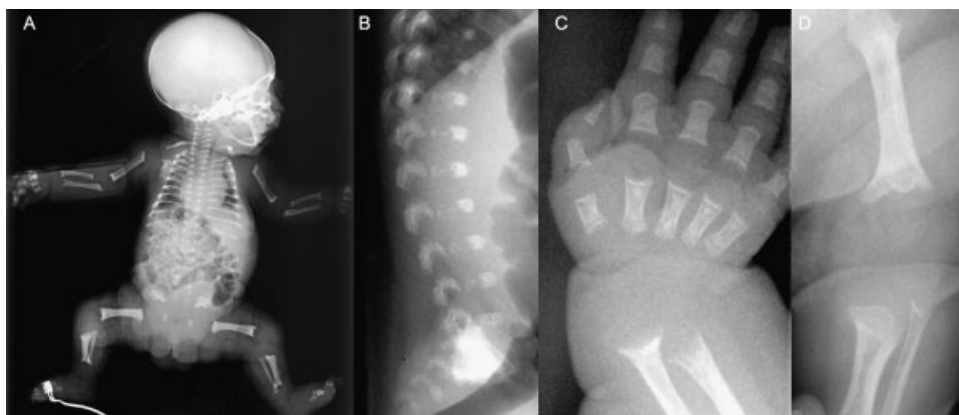


FIG. 3. Early radiographic changes in ODCD. **A:** Patient 1; this babygram taken shortly after birth shows a generalized platyspondyly and spiky metaphyseal changes of all long bones. The pelvis is squat, the iliac wings are small and the inferior part of the ilium is hypoplastic. Note also disproportion between the fibula and the tibia. **B:** Patient 6 at 6 weeks; this X-ray of the lateral lumbar spine reveals wide coronal clefts in all vertebrae and some platyspondyly with increased intervertebral spaces. The posterior halves of the vertebral bodies are much less well mineralized than the anterior halves. **C:** Patient 6 hand at 6 weeks; this radiograph shows the presence of significant metaphyseal cupping of the radius and ulna with an appearance somewhat resembling rickets given the large separation between distal radius and ulna and the wrist crease. Metacarpals and proximal phalanges show cupping as well. **D:** Patient 6 knee at 6 weeks; The distal femoral metaphysis is widened and has an upside-down W appearance. There is increased distance between the distal femur and proximal tibia reflective of a severe metaphyseal abnormality. The proximal fibula extends further than the tibia suggesting disproportionate shortening of the tibia.

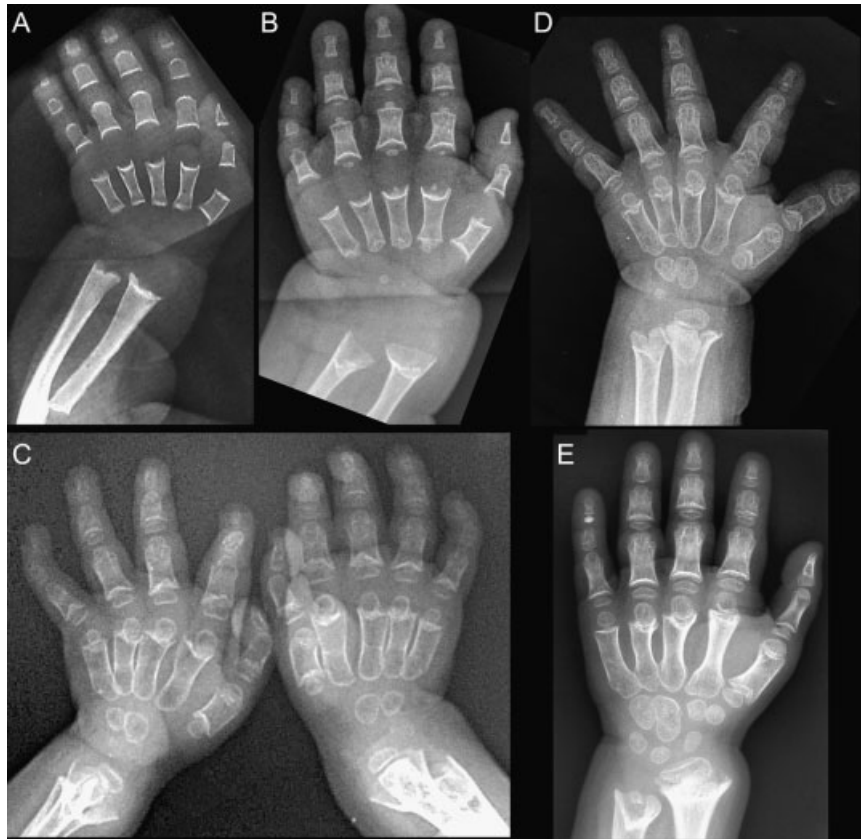


FIG. 4. Radiographs of the hands. **A:** Patient 2 at 3 days of age; one can readily appreciate the metaphyseal changes at both the radius and ulna. There is also smooth cupping of the metaphyses (epiphyseal cones) of all metacarpals and proximal phalanges. The phalanges are short and broad. **B:** Patient 6 at 14 months of age; there is deep cupping of the metaphyses of the radius and ulna and the separation between ossified distal radius/ulna and the wrist crease has enlarged. All bony elements of the hand are short and there is marked cupping of metaphyses at metacarpals, proximal phalanges, and some of the middle phalanges. Carpal ossification is markedly delayed in contrast with early appearance of the metacarpal and phalangeal epiphyses. There are pseudoepiphyses of the first metacarpal and the proximal phalanges. **C:** Patient 3 at two and a half years of age; There are deep metaphyseal incursions at the distal radius and ulna that are radiographically indistinguishable from enchondromas. Metaphyses and epiphyses are similar to those in panel C. All elements have a reduced bone density. **D:** Patient 5 at 4 years of age; There is significant delay in carpal bone ossification. The metaphyseal changes of the radius and ulna now resemble enchondromas. The epiphyses are coning into the cupped metaphyses. **E:** Patient 4 at 7 years of age; The metaphyses of the radius and ulna are disturbed with the distal epiphysis of the ulna sunken into the growth plate. There is brachydactyly with shortening of all elements.

the elongation and valgisation of the femoral neck. Apparent also on these radiographs is mild generalized osteopenia (Fig. 6).

**Vertebral column.** There is markedly delayed ossification of the spine as seen by the presence of multiple coronal clefts that slowly resolve. In childhood, there is mild platyspondyly and often some degree of kyphosis and/or scoliosis (Fig. 7).

## DISCUSSION

To date 11 patients with ODCD have been observed [six this report, Goldblatt et al., 1991; Bonaventure et al., 1992; Maroteaux et al., 1996] (Table I). This cohort includes two sib pairs, supporting the possibility of autosomal recessive inheritance. However, one should recall that recurrence in sibs was also

taken as evidence of recessive inheritance in both campomelic dysplasia and pseudoachondroplasia before the molecular evidence proved them to be dominant [Hall and Spranger, 1980; Wynne-Davies et al., 1986]. None of the families (including those with sib recurrence) are consanguineous [Bonaventure et al., 1992, this report]. Two brothers reported by Crowle et al. [1976] and deceased at age 7 and 23 months showed changes that we consider typical for ODCD; however, since there is no explicit report of DI in the older brother, they do not fulfill inclusion criteria for this report.

The clinical features of ODCD seem to be restricted to the skeleton, ligaments, and teeth. Intellectual development is normal and no eye or ear complications have been seen so far (Table I). As children, ODCD individuals have mesomelic limb shortening, joint laxity, and DI with small,

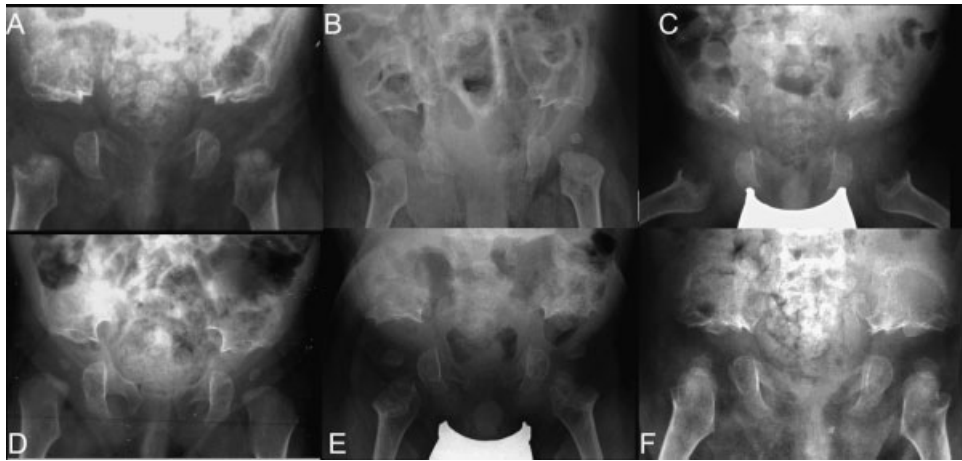


FIG. 5. Radiographs of the pelvis. **A:** Patient 5 at 5 months; the ilia are squat with a lacy superolateral border. The sacrosciatic notch is narrow and V-shaped. **B:** Patient 2 at 5 months; these iliac wings are also foreshortened and the appearance of the trident is most striking in this pelvis strongly resembling the acetabular border of Jeune syndrome. The iliac crests are lacy. **C:** Patient 6 at 6 months; there is a very narrow sacrosciatic notch bilaterally and some delay in pubic bone development. The proximal femoral metaphyses are widened and spiky. **D:** Patient 4 at 10 months; there is less narrowing of the sacrosciatic notch but the acetabular border is irregular with an almost trident appearance. **E:** Patient 6 at 15 months; this pelvis shows a very similar pattern. However, the inferior margin of the ilia has lost the trident appearance and is simply irregular. The beginning of enchondromatous like changes can be seen at the proximal femoral epiphyses. **F:** Patient 3 at 16 months; this pelvis shows all the typical features of odontochondrodysplasia with the lacy iliac borders, narrow sacrosciatic notches with spiky margins, and irregular acetabular margins.

brownish, and fragile primary teeth. Interestingly, in our lone adult patient (Patient 4) the permanent dentition was more severely affected than the primary dentition. The two older patients (Patients 3 and 4) also had progressive scoliosis requiring spinal surgery. One of our patients (Patient 1) died in the first year of life as a result of respiratory insufficiency. The two brothers reported by Crowle et al. [1976] who probably also had ODCD (see above) also died before 2 years of age indicating that thoracic hypoplasia can be clinically relevant in ODCD.

The key radiographic features in infancy are marked spondylar dysplasia with coronal clefts. In childhood, there are significant hand changes with shortening of all elements and round cone shape epiphyses. The differential diagnosis of ODCD in the newborn is with SMD Sedaghatian type because they share platyspondyly and spiked metaphyses. It further includes the phenotype of severe Shwachman–Diamond syndrome, as some of us have reported recently [Nishimura et al., 2007]. One might also consider a type 2 collagen disorder such as PSLD Torrance type because of the platyspondyly with

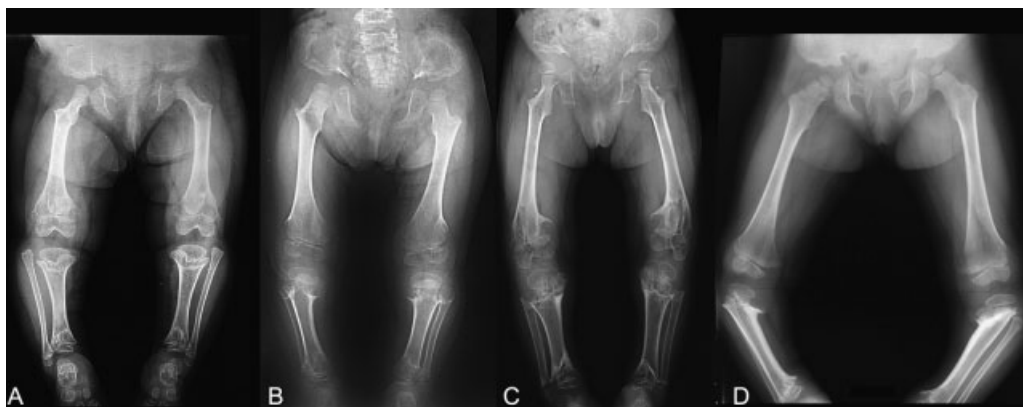

FIG. 6. Radiographs of the lower limbs. **A:** Patient 5 at 3 years 8 months; there are metaphyseal changes (cupping and fraying) at the knees and distal tibias, while the epiphyses are bulky. The tibiae are shorter than the fibulas and quite stocky. The femoral necks are elongated, thin and in valgus position. **B:** Patient 3 at two and a half years; there is shortening of all long bones of the legs but the tibiae are more severely affected (mesomelia). Metaphyseal changes are less pronounced than in panel A. The femoral necks are constricted and in valgus position. **C:** Patient 2 at 3 years and 8 months; there is distinct mesomelia with metaphyseal changes of all long bones. There is a mild varus deformity at the knees. The femoral necks are constricted and in valgus. The changes at the distal femoral metaphyses are reminiscent of enchondromatosis. **D:** Patient 4 at 3 years and 4 months; This patient has the most obvious varus deformity of the knees with an inwardly sloped metaphyses of the proximal tibias. The metaphyseal changes are somewhat less than the other patients but still present.

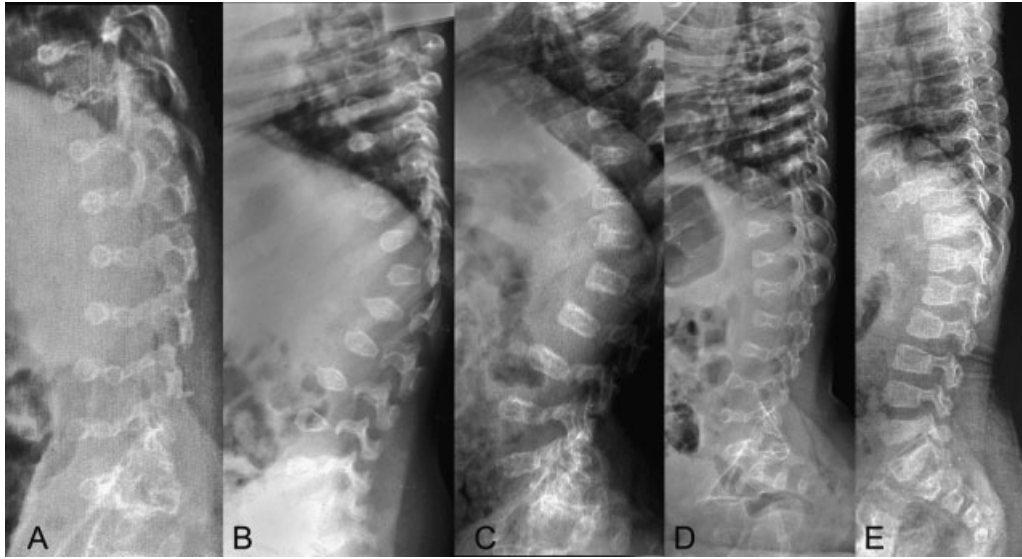


FIG. 7. Radiographs of the lateral thoracolumbar spine. **A:** Patient 2 at 5 months; there is platyspondyly with coronal clefts at all levels. The anterior portions of the vertebral bodies are roughly equal to the posterior resembling an infinity or figure-eight sign ( $\infty$ ). **B:** Patient 4 at 10 months; there are no coronal clefts but there is platyspondyly and an almost pear shaped appearance. At the thoracic-lumbar intersection a kyphosis is beginning to develop. **C:** Patient 3 at 15 months; there is platyspondyly and remnants of coronal clefts can be appreciated at L4 and L5. Intervertebral spaces remain wider than normal. **D:** Patient 2 at 14 months; the vertebral bodies have fused but the remnants of coronal clefts are visible throughout the lumbar spine. **E:** Patient 5 at 4 years; the form of the vertebral bodies suggests that coronal clefts were present at an earlier stage but have since resolved. The platyspondyly is milder than that observed in the younger patients.

coronal clefts. However, the evolution of the radiographic changes in ODCD makes it distinct and distinguishable from these conditions. Particular attention should be paid to the phalangeal shortening and metaphyseal cupping of the long bones seen consistently in children with ODCD. With age, there is progression of both the metaphyseal changes and the degree of disproportion (mesomelia). In the pelvis, the iliac wings have a lacy contour and there is a relatively long and constricted femoral neck with a valgus position. In childhood, the differential diagnosis of ODCD might include metatropic dysplasia (narrow thorax and spondylar changes; Crowle et al. [1976] tentatively reported their patients as metatropic), Dyggve–Melchior–Clausen syndrome (SEMD with lacy iliac crests), or severe Shwachman–Diamond syndrome (narrow thorax and metaphyseal changes), but the mesomelic shortening, the marked degree of metaphyseal changes and the presence of DI makes the distinction between these disorders and ODCD relatively straightforward.

Bonaventure et al. [1992] obtained biochemical evidence of posttranslational over modification of collagen 2 extracted from a cartilage biopsy of one of their patients. However, mutations in *COL2A1* were never reported in those or in other families, and in one of our individuals (Patient 6), in whom PLSD Torrance type was suspected at birth, complete sequencing of *COL2A1* failed to uncover any pathogenic mutation. Also, the relatively high ratio of affected sibs and the distinct radiographic features argue against dominant *COL2A1* mutations. We postulate that the findings of abnormal collagen 2

[Bonaventure et al., 1992] are related to a perturbation of posttranslational modification rather than to primary *COL2A1* mutations, but this remains to be proven. If true, such a perturbation could also affect collagen 1 (at least in developing teeth) explaining the presence of DI as well as the decreased bone density. *FGFR3*, *SBDS*, *COMP*, and *RMRP* were also excluded as causative genes by direct sequencing in one or more of the patients reported here.

The diagnosis of an individual skeletal dysplasia usually relies on recognition of a specific radiographic pattern and thus a single radiographic sign or physical finding should not be trusted as definitive evidence of a disorder. ODCD exemplifies this need to assess both radiographic and physical features, preferably over time, the so-called fourth dimension of the skeletal dysplasias [Giedion, 1994]. The distinctive but consistent combination of findings in a total of 11 individuals confirms that ODCD is a distinct entity whose molecular basis remains to be resolved.

#### ACKNOWLEDGMENTS

Patient 4 was ascertained via the European Skeletal Dysplasia Network (ESDN). We would like to thank Dr. Mike Briggs and Dr. Gail Jackson (Manchester) for performing COMP analysis in Patient 4, Dr. Luisa Bonafe and Dr. Laureane Mittaz-Crettol (Lausanne) for performing the RMRP analysis in Patient 4, and Dr. J.O. Sass (Freiburg) for urine organic acid analysis in Patient 2.

TABLE I. Clinical Features of Odontochondrodysplasia

	Case 1		Case 2		Case 3		Case 4		Case 5		Case 6	
	Sib 1		Sib 2		Sib 1		Sib 2		Sib 1		Sib 2	
Reference	Goldblatt et al. [1991]	Maroteaux et al. [1996], case 1	Maroteaux et al. [1996], case 2	Maroteaux et al. [1996], case 3	Bonaventure et al. [1992] case 1, Maroteaux et al. [1996] case 4	Bonaventure et al. [1992] case 2, Maroteaux et al. [1996] case 4	Present paper	Present paper	Present paper	Present paper	Present paper	Present paper
Gender	M	M	M	M	F	F	M	F	M	M	M	M
Consanguinity	No	No	No	No	No	No	No	No	No	No	No	No
Survival	Alive at 1 year	Alive at 2 years	Alive at 8 years	Alive at 16 years	Alive at age 12 years	Alive at age 12 years	Deceased at age 4 months	Alive at age 3 years	Alive at age 4 years	Alive at age 4 years	Alive at age 17 years	Alive at age 14 months
Skeletal dysplasia recognized at birth	?	?	?	Yes	Yes	Yes	Yes	Yes	Yes	Yes	No	Yes
Short stature (childhood)	Yes	Yes	Yes	Yes	Yes	Yes	Not able to assess	Yes	Yes	Yes	Yes	Yes
Narrow chest	Yes	Yes	Yes	Yes	Yes	Yes	Yes	Yes	Yes	Yes	No	Yes
Mesomelic limb shortening	Yes	?	?	Yes	Yes	Yes	Yes	Yes	Yes	Yes	Yes	Yes
Dentinogenesis imperfecta	Yes	Yes	Yes	Yes	Yes	Yes	Not able to assess	Yes	Yes	Yes	Yes	Yes
Peripheral joint laxity	Yes	?	Yes	Yes	Yes	Yes	?	Yes	Yes	Yes	Yes	Yes
Scoliosis	No	No	?	Yes	Yes	Yes	No	No	Yes	Yes	Yes	No
Mental development	Normal	Normal	?	?	Normal	Normal	Not able to assess	Normal	Normal	Normal	Normal	Normal



## REFERENCES

- Bayar A, Acun C, Dursun A, Verhoeven N, Bonafé L, Keser S, Superti-Furga A. 2005. Metaphyseal enchondrodysplasia with 2-hydroxy-glutaric aciduria: Observation of a third case and further delineation. *Clin Dysmorphol* 14:7–11.
- Bonaventure J, Stanescu R, Stanescu V, Allain JC, Muriel MP, Ginisty D, Maroteaux P. 1992. Type 2 collagen defect in two sibs with the Goldblatt syndrome, a chondrodysplasia with dentinogenesis imperfecta and joint laxity. *Am J Med Genet* 44:738–753.
- Crowle P, Astley R, Insley J. 1976. A form of metatropic dwarfism in two brothers. *Pediatr Radiol* 4:172–174.
- Giedion A. 1994. The weight of the fourth dimension for the diagnosis of genetic bone disease. *Pediatr Radiol* 24:387–391.
- Goldblatt J, Carman P, Sprague P. 1991. Unique dwarfing, spondylometaphyseal skeletal dysplasia, with joint laxity and dentinogenesis imperfecta. *Am J Med Genet* 39:170–172.
- Hall BD, Spranger JW. 1980. Campomelic dysplasia: Further elucidation of a distinct entity. *Am J Dis Child* 134:285–289.
- Maroteaux P, Briscioli V, Lalatta F, Bonaventure J. 1996. L'odontochondrodysplasie. *Arch Pediatr* 3:549–554.
- Nishimura G, Nakashima E, Hirose Y, Cole T, Cox P, Cohn DH, Rimoin DL, Lachman RS, Miyamoto Y, Kerr B, Unger S, Ohashi H, Superti-Furga A, Ikegawa S. 2007. The Shwachman-Bodian-Diamond syndrome gene mutations cause a neonatal form of spondylometaphyseal dysplasia (SMD) resembling SMD Sedaghatian type. *J Med Genet* 44:e73.
- Wynne-Davies R, Hall CM, Young ID. 1986. Pseudoachondroplasia: Clinical diagnosis at different ages and comparison of autosomal dominant and recessive types. A review of 32 patients (26 kindreds). *J Med Genet* 23:425–434.