

2016

## 3D Methods for Medical Education and Clinical Practice

Molly Buynak OMSII  
*Marian University - Indianapolis*

Leonard K. Song OMSII  
*Marian University - Indianapolis*

David Dufeu, PhD  
*Marian University - Indianapolis*

Follow this and additional works at: [https://mushare.marian.edu/mucom\\_rd](https://mushare.marian.edu/mucom_rd)



Part of the [Medicine and Health Sciences Commons](#)

---

### Recommended Citation

Buynak, Molly OMSII; Song OMSII, Leonard K.; and Dufeu, PhD, David, "3D Methods for Medical Education and Clinical Practice" (2016). *MU-COM Research Day*. 40.  
[https://mushare.marian.edu/mucom\\_rd/40](https://mushare.marian.edu/mucom_rd/40)

This Poster is brought to you for free and open access by the College of Osteopathic Medicine at MUShare. It has been accepted for inclusion in MU-COM Research Day by an authorized administrator of MUShare. For more information, please contact [emandity@marian.edu](mailto:emandity@marian.edu).





# 3D Methods for Medical Education and Clinical Practice

Molly Buynak, OMS-II; Leonard K. Song, OMS-II; David L. Dufeu, PhD, MUCOM

[mbuynak070@marian.edu](mailto:mbuynak070@marian.edu); [ksong404@marian.edu](mailto:ksong404@marian.edu); [ddufeu@marian.edu](mailto:ddufeu@marian.edu)



## INTRODUCTION

New imaging technologies and 3D rendering software, in addition to being useful diagnostic tools, allow us to augment patient education and further medical student and physician knowledge. 3D imaging modalities such as CT and MRI expedite the learning process for medical students, allow physicians to better visualize the anatomy and potential pathologies present, and aid in educating patients to help them better understand their conditions.

## METHODS

We present here 3D interpretations from a sample of CT imaging studies of the cerebral vasculature, optic neural pathways, and paranasal sinuses.

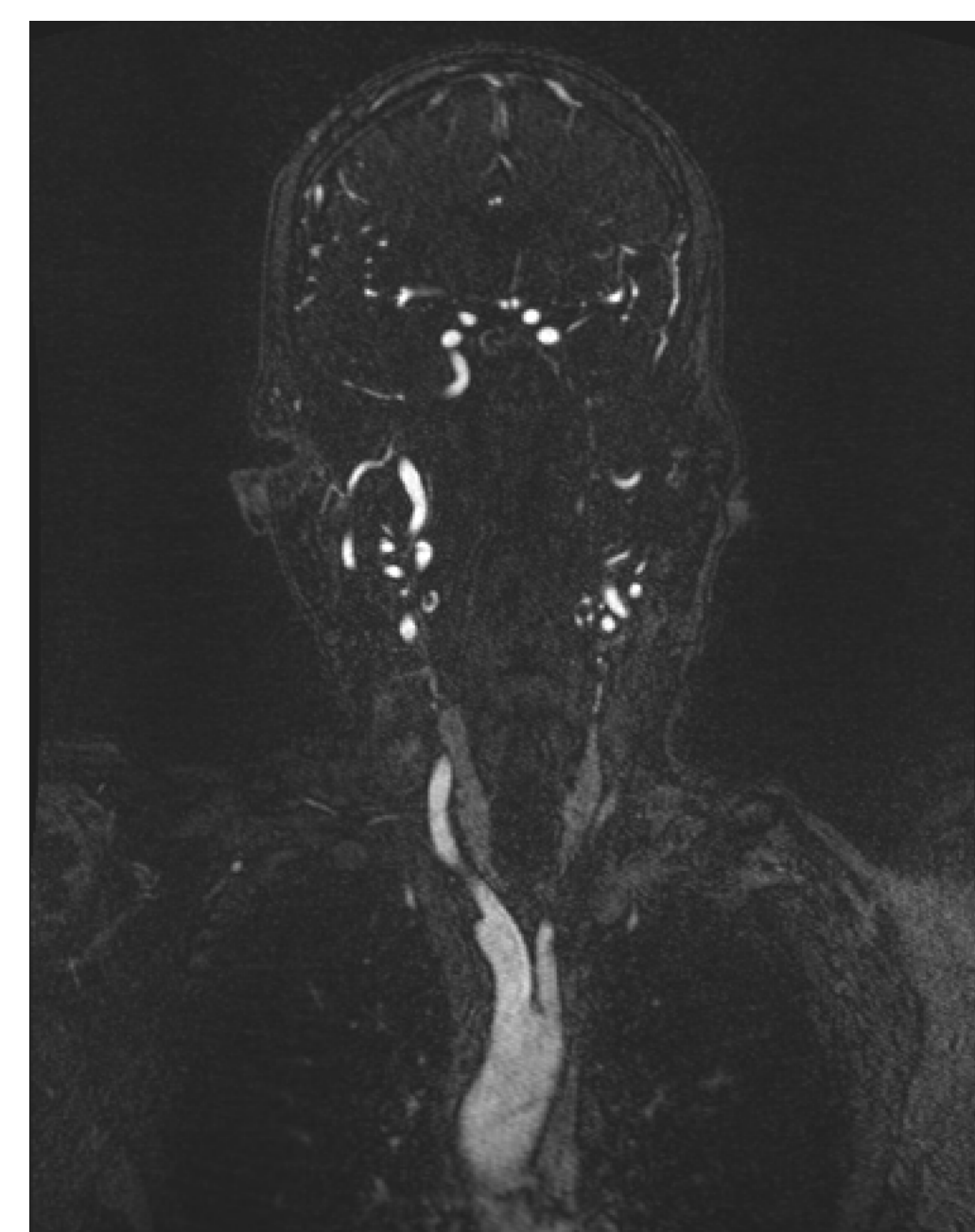

Figure 1: Coronal view of head and neck CTA

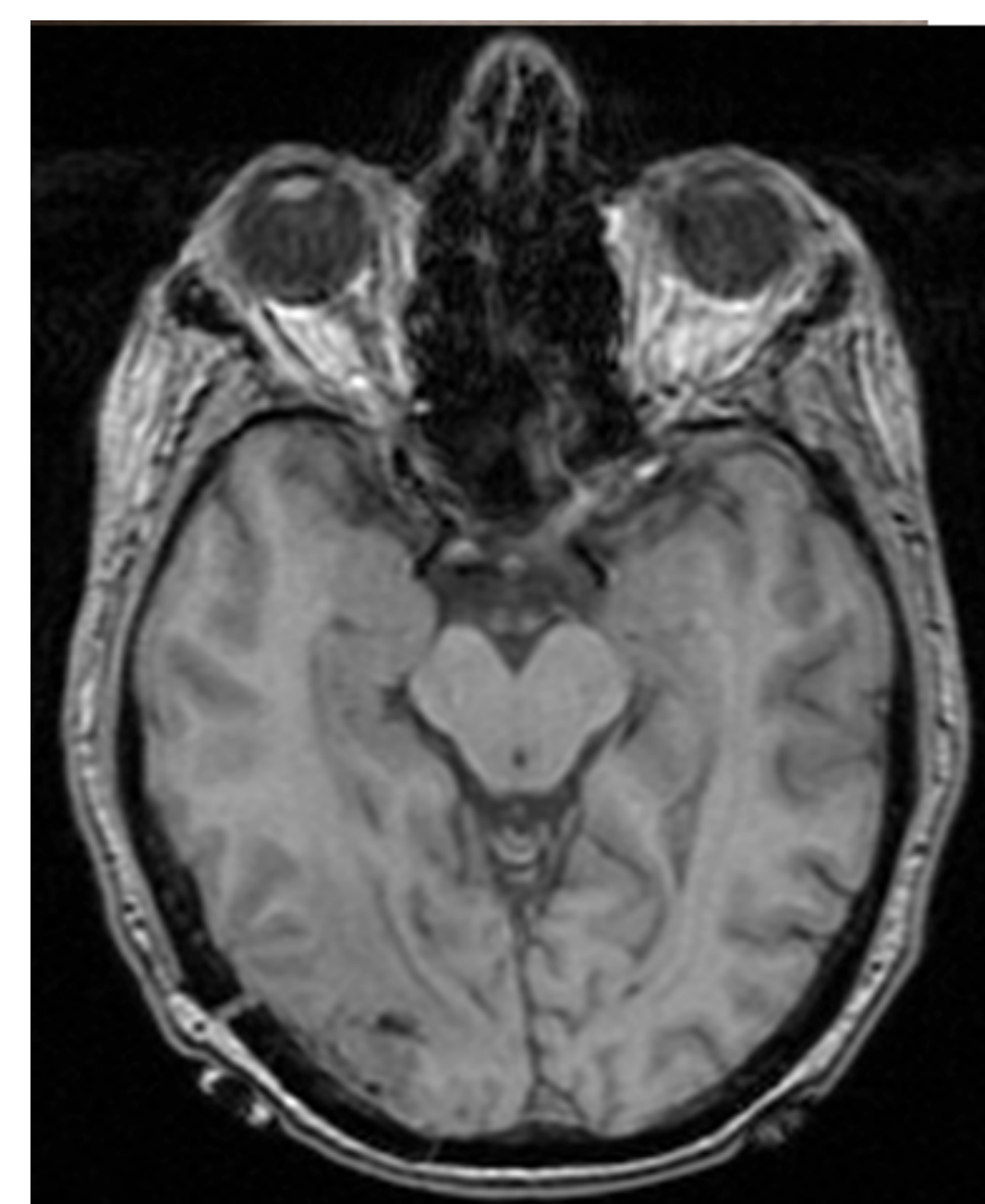


Figure 2: Transverse view of head CT

These data were obtained from the NIH Cancer Database, among other sources. The raw imaging data was imported into a third-party image analysis software called Amira, which was used to primarily facilitate 3D renderings. From there, the project images were further manipulated and enhanced utilizing other third-party programs, including Autodesk, MeshMixer, Adobe 3D Toolkit, and Softwarecasa Camtasia Studio, so that they could be exported as 3D prints, interactive 3D PDFs, and 3D animations. Analysis of data, 3D rendering, and construction of the final products all took place in the Marian University College of Osteopathic Medicine 3D Research Lab.

## ACKNOWLEDGEMENTS

This project was supported by Marian University College of Osteopathic Medicine 3D Research Lab. Special thanks to Dr. Dufeu and Madeline Mackinder OMS-II July 2014 for manipulating the raw data for construction of the 3D visualization of the paranasal sinuses.

## RESULTS

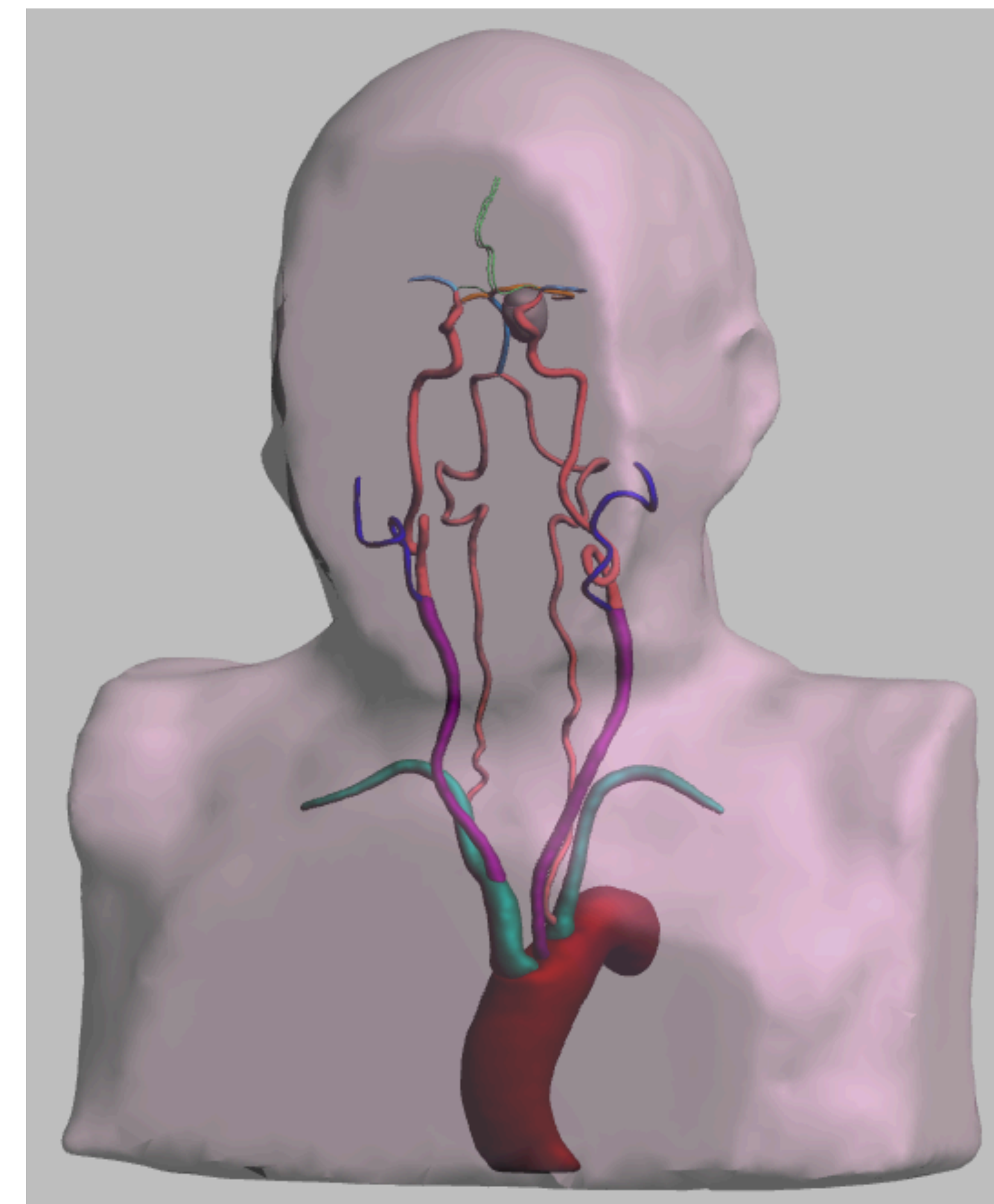


Figure 4: Presented to the right is a 3D visualization of the paranasal sinuses. Highlighted in this figure are the frontal and maxillary sinuses. Other structures included in this representation are the ethmoid and sphenoid sinuses as well as mastoid air cells.

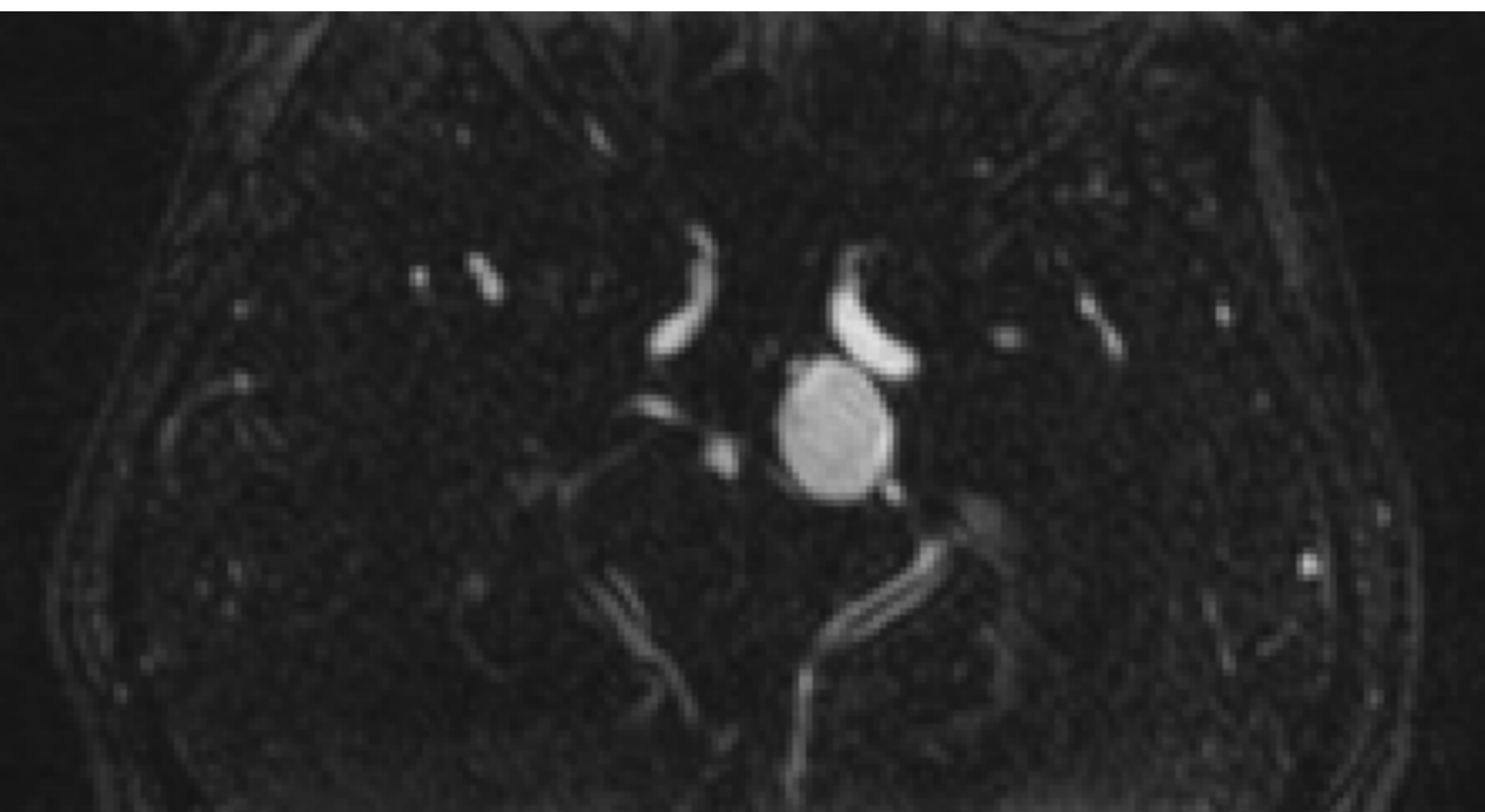
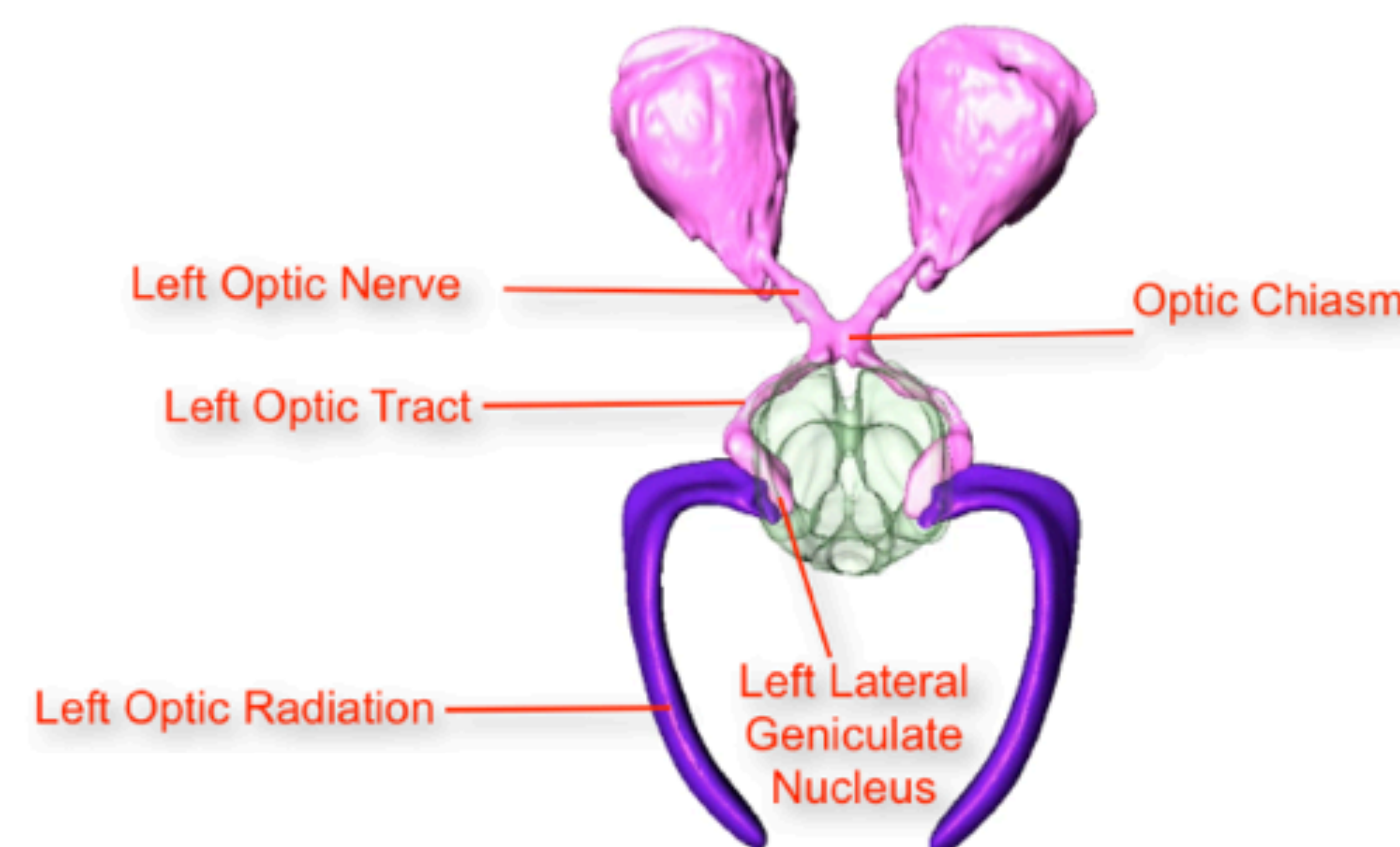
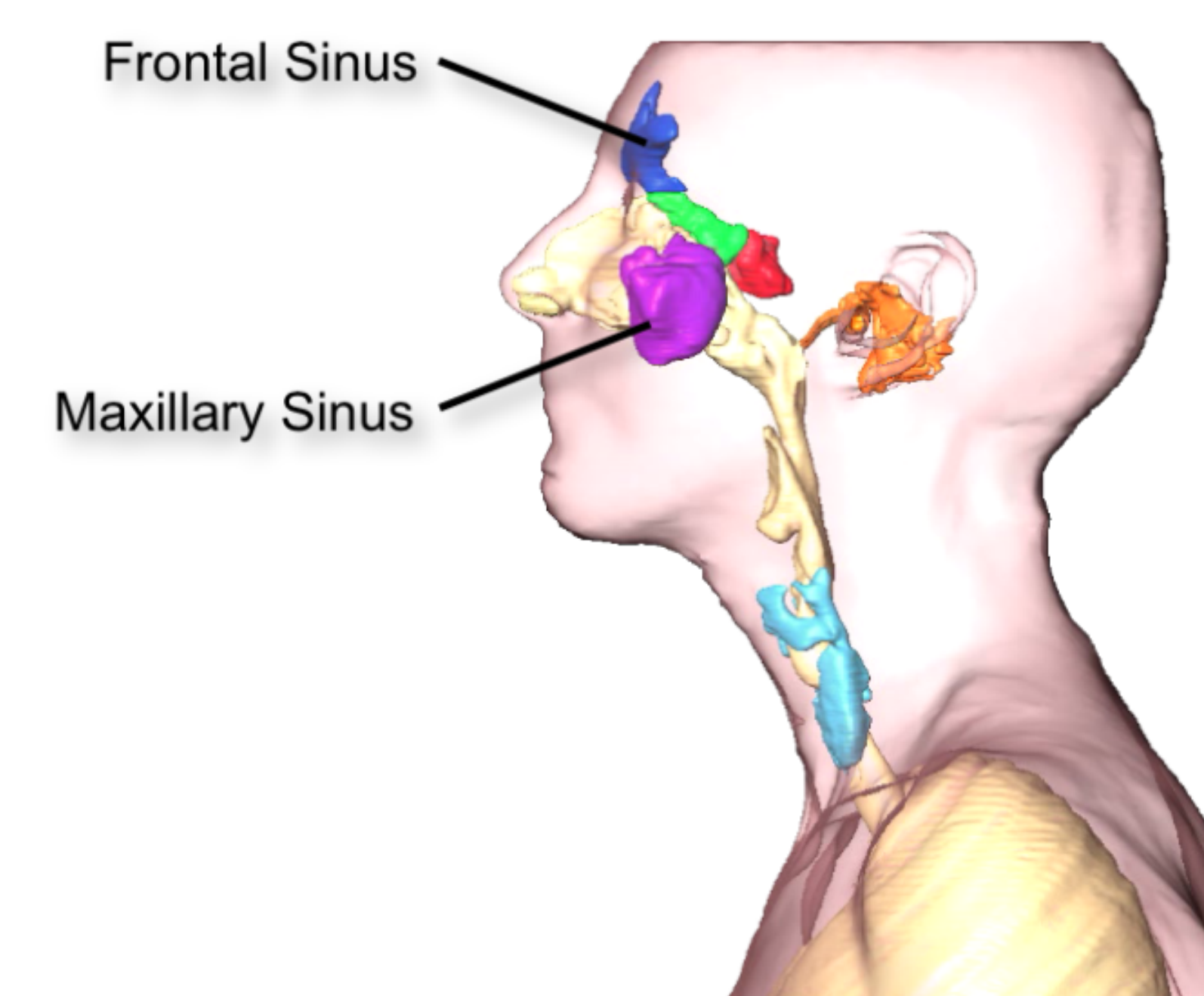


Figure 3: Shown above in the CTA study is a basilar artery aneurysm. This data was manipulated to produce the 3D interpretation as seen on the left.

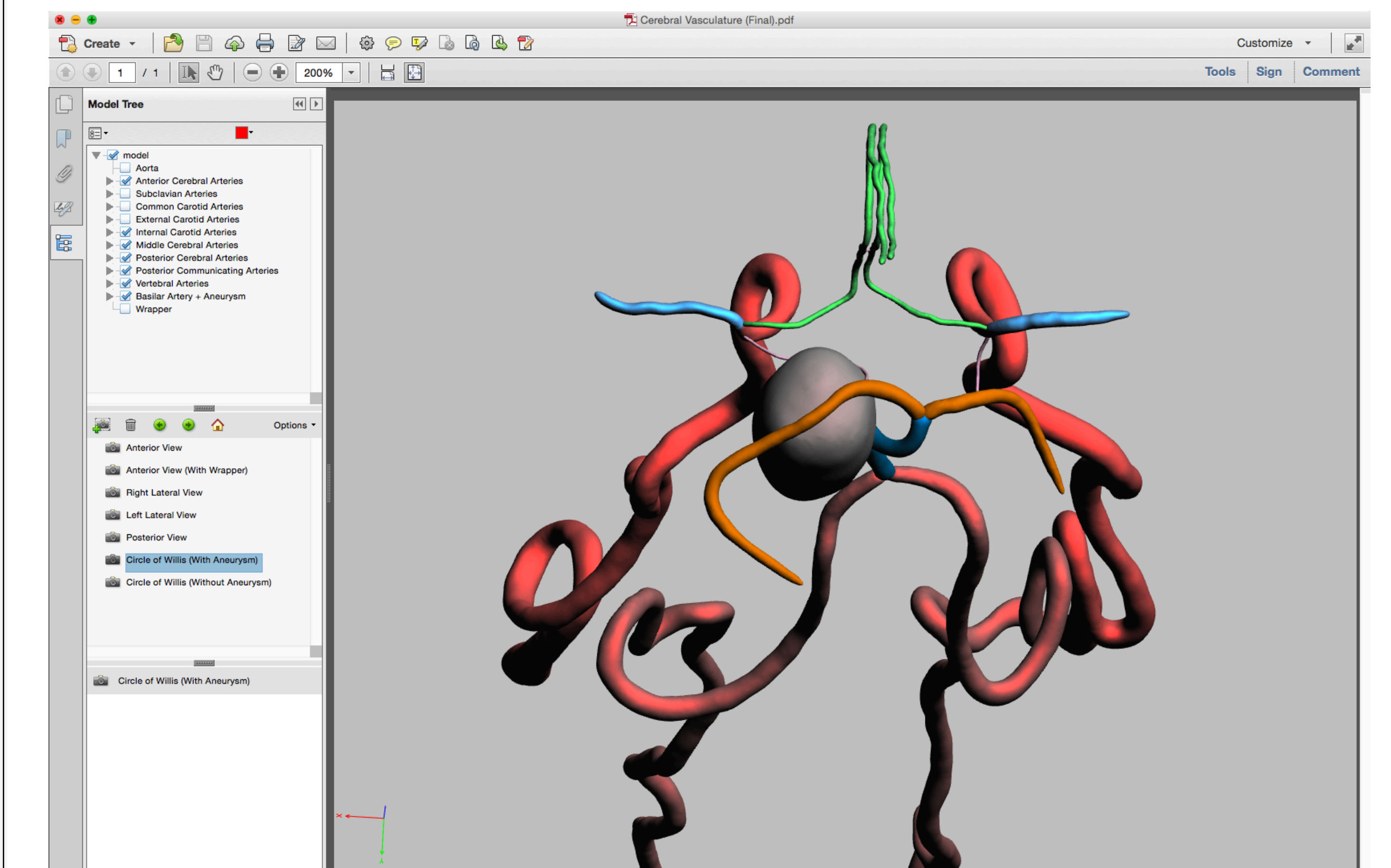


Shown above are the 3D representation (Figure 5; left) and printed image (Figure 6; right) of the optic pathways. Figure 5 is a screenshot from a YouTube video produced by Molly Buynak showing various views of the optic pathways. Figure 6 is a 3D print produced in the MUCOM 3D Research Lab.

## DISCUSSION

Our intent for the first step in using these projects for medical education includes making these 3D models available to first-year gross anatomy curricula, with the goal of helping students better visualize structures that may otherwise be problematic to view in a cadaver. For example, Figure 7 shows the Cerebral Circle of Willis with an interposed basilar artery aneurysm in a 3D interactive PDF, which may be made accessible to students to aid in their understanding of neuroanatomy.

Figure 7: Cerebral Circle of Willis, with basilar artery aneurysm



## CONCLUSION

Our ultimate goal is to have 3D visualization technology incorporated into various facets of medical practice and education: for instance, this technology may help physicians incorporate 3D visualizations of various pathologies (e.g. exact locations of berry aneurysms) into their everyday practice and patient interactions. This technology may be useful in helping patients better understand their pathologies, which may contribute to easing patients' anxieties regarding their conditions and potentially improve treatment outcomes.

## LINKS

3D visualization of the paranasal sinuses: <https://www.youtube.com/watch?v=4quN7vyeLsc>  
3D visualization of the optic pathways: <https://www.youtube.com/watch?v=wq7IP6L0yW0>