

2016

## Cryoglobulinemic Vasculitis in a Patient with Trismus Pseudocamptodactyly

Joseph Aleshaki OMS-III

*Marian University - Indianapolis, jaleshaki093@marian.edu*

Kurt Ashack

*Michigan State University College of Human Medicine; University of Illinois at Chicago, Department of Dermatology*

Anthony Martin

*St. Vincent Hospital - Indianapolis*

Follow this and additional works at: [https://mushare.marian.edu/mucom\\_rd](https://mushare.marian.edu/mucom_rd)



Part of the Dermatology Commons

---

### Recommended Citation

Aleshaki, Joseph OMS-III; Ashack, Kurt; and Martin, Anthony, "Cryoglobulinemic Vasculitis in a Patient with Trismus Pseudocamptodactyly" (2016). *MU-COM Research Day*. 43.

[https://mushare.marian.edu/mucom\\_rd/43](https://mushare.marian.edu/mucom_rd/43)

This Poster is brought to you for free and open access by the College of Osteopathic Medicine at MUShare. It has been accepted for inclusion in MU-COM Research Day by an authorized administrator of MUShare. For more information, please contact [emandity@marian.edu](mailto:emandity@marian.edu).

# Comparison of patient tolerance of photodynamic therapy with zone vs. full face treatment



## Kevin M. Crawford, Joseph S. Aleshaki

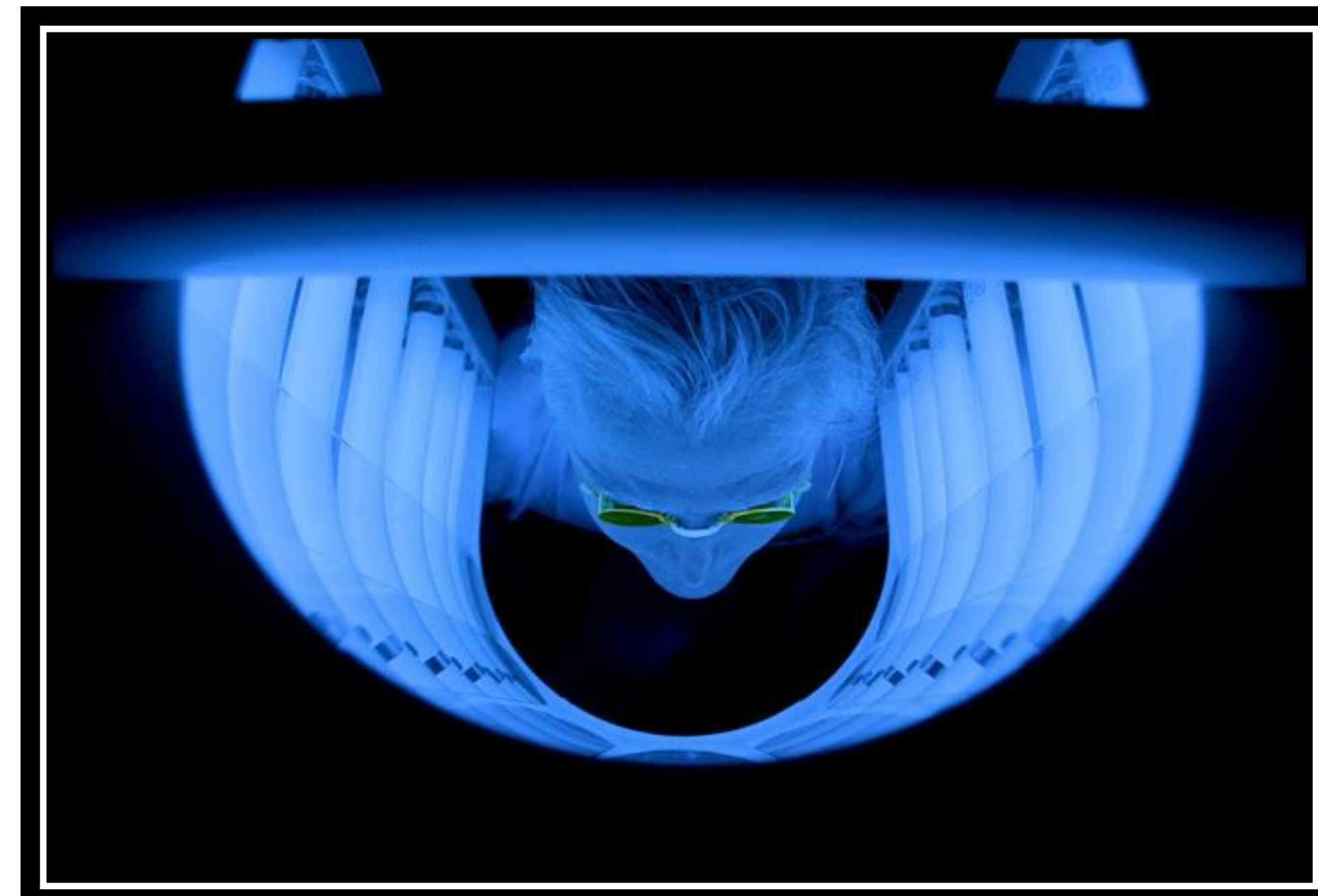
Indiana University Department of Dermatology, Marian University College of Osteopathic Medicine

### Introduction

Photodynamic Therapy (PDT) is a promising treatment option for actinic keratosis, superficial basal cell carcinoma, and in-situ squamous cell carcinoma.

The fundamental basis of PDT lies in the selective destruction of target tissue photochemical reaction when light is absorbed by a photosensitizing agent applied on the affected skin surface. In an effort to increase patient compliance, dermatologists systematically apply photosensitizing agents to smaller, defined treatment areas.

We hypothesize that development of standardized treatment zones for photodynamic therapy would result in improved patient comfort, higher patient retention, and less severe reactions while maintaining the efficacy of full face treatments.



### Methods

Five hundred patients with 12 or more actinic keratosis were selected for the study. Patients were divided into full face (n=250) vs. zone treatments (n=250) for their PDT treatments. Treatments were separated by 3-4 weeks. Full face was defined as the entire forehead, nose, bilateral cheeks, entire chin, and bilateral ears.

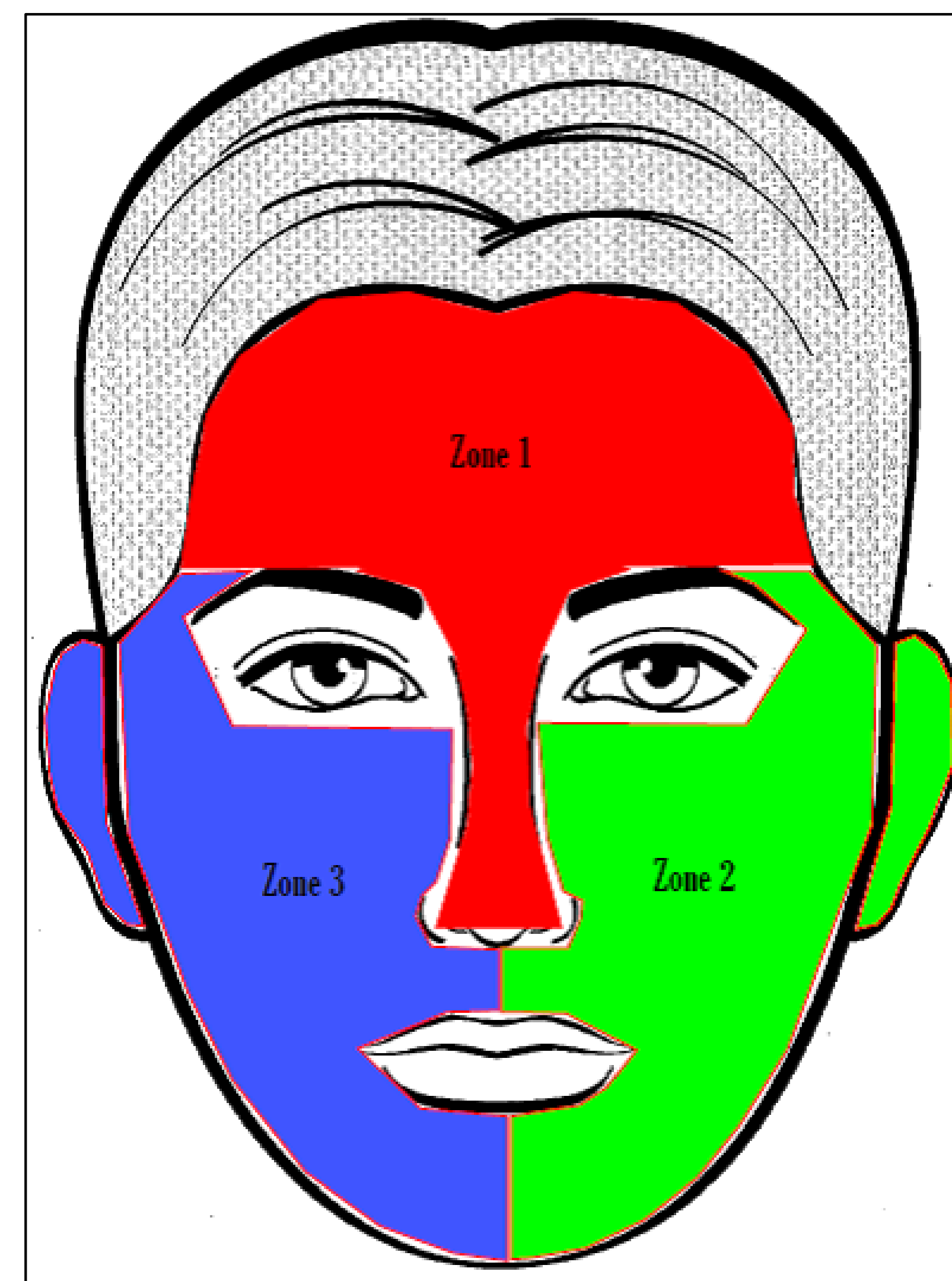
Patients were prepped with acetone and 20% aminolevulinic acid solution (Levulan) and incubated for 60 minutes. They were exposed to narrow band blue fluorescence for 16 minutes and 40 seconds.

After 48-72 hours post-treatment, patients were asked the following questions:

1. Grade their tolerance of the treatment regimen as Excellent, Fair, or Poor
2. Would you have the treatment again (Yes/No/Unsure)

For the Zone Treatment Group, Zones were defined as:

1. Zone A: Forehead, nose
2. Zone B: Left ear, left cheek, left chin
3. Zone C: Right ear, right cheek, right chin



### Results

Zone treatment resulted in a higher number of excellent responses for patient tolerance vs. full face treatment group (85 % vs. 39%, P<0.0001).

More patients would undergo follow up zone treatments versus full face treatment (96% vs. 77.9%, P <0.0001).

There were fewer severe reactions in the zone treatment group (n = 3 vs. n = 34, P <0.0001).

Zone treatments displayed higher patient retention (92.8% vs. 68.0%, P<0.0001).

Table 1 – Patient Tolerance

	Excellent	Fair	Poor	Not able to contact
Zone Treatment:	193 (84.6%)	19 (8.3%)	14(6.14%)	24
Full face treatment:	90 (39.0%)	76 (32.9%)	65 (28.1%)	19
P-value:	<0.0001	<0.0001	<0.0001	

Table 2 – Would Patient Repeat Treatment

	Yes	No	Unsure
Zone Treatment	96.0% (217/226)	2.2% (5)	1.8% (4)
Full Face Treatment	77.9% (180/231)	17.3% (40)	4.8% (11)
P-value	<0.0001		

Table 3 – Complications/Severe Reactions

	Number of patients
Zone Treatment	n=3 (1.2%)
Full Face Treatment	n=34 (13.6%)
P-value	<0.0001

Table 4 – Patient Retention

	Retention Percentage
Zone Treatment	92.8% (232/250)
Full Face	68.0% (170/250)
P-value	<0.0001

### Conclusions

Our study found that zone therapy patients experienced increased comfort, satisfaction, and retention with fewer complications as compared to full face treatment.

A limitation of this study includes that it has been performed at a single, rural clinic in Southern Indiana. Geographic, climate and other differences must be considered before assuming that these results are able to be generalized to other patient populations.

While patient tolerance is improved with zone therapy, the increase in cost of the procedure should not be ignored.

Levulan Kerasticks currently cost approximately \$160. Therefore, reagent cost alone for zone therapy is \$960 vs. \$320 for full face treatment. Additionally, the Medicare reimbursement for PDT treatment itself is approximately \$125. Thus, zone treatment accrues a cost of \$750 vs. \$250 for full face treatments.

Each dermatologist should pose the question whether the benefits of increased patient tolerance, comfort, and retention outweigh the obvious increase in cost of the regimen. 6 Zone treatments also require several weeks more time to complete than 2 full face treatments.

### Bibliography

1. Tappeiner H, Jesionek A. Therapeutische versuche mit fluoreszierenden stoffen. Münch Med Wochenschr. 1903;47:2042-4.
2. Diamond I, Granelli SG, McDonagh AF, Nielsen S, Wilson CB, Jaenicke R. Photodynamic therapy of malignant tumours. Lancet. 1972 Dec 2;2(7788):1175-7.
3. Dougherty TJ, Kaufman JE, Goldfarb A, et al. Photoradiation therapy for the treatment of malignant tumors. Cancer Res. 1978;38:2628-35
4. Tschen EH, Wong DS, Pariser DM, et al. Photodynamic therapy using aminotaevulinic acid for patients with nonhyperkeratotic actinic keratoses of the face and scalp: phase IV multicentre clinical trial with 12-month follow up. Br J Dermatol. 2006;155:1262-9.
5. Piacquadio DJ, Chen DM, Farber HF, et al. Photodynamic therapy with aminolevulinic acid topical solution and visible blue, light in the treatment of multiple actinic keratoses of the face and scalp – investigator-blinded, phase 3, multicenter trials. Arch Dermatol. 2004;140:41-6.
6. Ericson MB, Sandberg C, Stenquist B, et al. Photodynamic therapy of actinic keratosis at varying fluence rates: assessment of photobleaching, pain and primary clinical outcome. Br J Dermatol. 2004;151:1204-12
7. Kurwa HA, Yong-Gee SA, Seed PT, et al. A randomized paired comparison of photodynamic therapy and topical 5-fluorouracil in the treatment of actinic keratoses. J Am Acad Dermatol. 1999;41:414-18.
8. Smith S, Piacquadio D, Morhenn V, et al Short incubation PDT versus 5-FU in treating actinic keratoses. J Drugs Dermatol. 2003 Dec;2(6):629-35
9. Gold MH. Photodynamic therapy. Curr Probl Dermatol. 2011;42:181-92.
10. Iwamoto, Brandon. Photodynamic Therapy. Digital image. Flickr.com, 26 May 2011. Web. 26 Oct. 2015.

#### Further Information

Joseph Aleshaki, OMSII: jaleshaki093@marian.edu  
Kevin M. Crawford, MD: DrCrawford@IndianaSkinDoctor.com