

8-1-2018

## Case Report: Ischial Stress Fracture Non-Union in a College Football Player

Adam C. Shaner  
*New York Medical College*

Andrea M. Spiker

Marci A. Goolsby

Bryan T. Kelly

David L. Helfet

Follow this and additional works at: [https://touro scholar.touro.edu/nymc\\_fac\\_pubs](https://touro scholar.touro.edu/nymc_fac_pubs)



Part of the [Medicine and Health Sciences Commons](#)

---

### Recommended Citation

Shaner, A. C., Spiker, A., Goolsby, M., Kelly, B., & Helfet, D. (2018). Case Report: Ischial Stress Fracture Non-Union in a College Football Player. *Journal of Hip Preservation Surgery*, 5 (3), 312-318. <https://doi.org/10.1093/jhps/hny019>.

This Case Report is brought to you for free and open access by the Faculty at Touro Scholar. It has been accepted for inclusion in NYMC Faculty Publications by an authorized administrator of Touro Scholar. For more information, please contact [touro.scholar@touro.edu](mailto:touro.scholar@touro.edu).

# Case report: ischial stress fracture non-union in a college football player

Adam C. Shaner<sup>1</sup>, Andrea M. Spiker<sup>2\*</sup>, Marci A. Goolsby<sup>3</sup>, Bryan T. Kelly<sup>4</sup> and David L. Helfet<sup>4</sup>

<sup>1</sup>Department of Orthopaedic Surgery, Trauma Surgery, Westchester Medical Center, New York Medical College, NY, USA,

<sup>2</sup>Department of Orthopedic Surgery, Sports Medicine and Hip Preservation, University of Wisconsin – Madison, Madison, WI, USA,

<sup>3</sup>Department of Medicine, Sports Medicine and

<sup>4</sup>Department of Orthopaedic Surgery, Hospital for Special Surgery, New York, NY, USA

\*Correspondence to: A. M. Spiker. E-mail: spiker@ortho.wisc.edu

Submitted 9 February 2018; revised version accepted 19 May 2018

## ABSTRACT

Stress fractures are common injuries associated with repetitive high-impact activities, often in high-level athletes and military recruits. Although predominantly occurring in the lower extremities, stress fractures may occur wherever there is a sudden increase in frequency or intensity of activity, thereby overloading the yield point of the local bone environment. Ischial stress fractures are a rarely diagnosed cause of pain around the hip and pelvis. Often, patients present with buttock pain with activity, which can be misdiagnosed as proximal hamstring tendonitis or avulsion. Here, we report a case of a college football player who was diagnosed with an ischial stress fracture which went on to symptomatic non-union after extensive conservative management. We treated his ischial non-union with open reduction internal fixation utilizing a tension band plate and screws. This interesting case highlights an uncommon cause of the relatively common presentation of posterior hip pain and describes our technique for addressing a stress fracture non-union in the ischium.

## INTRODUCTION

Hip pain is a common presentation in the adolescent athletic population [1]. The hip itself has a complex regional anatomy, often exhibiting similar symptoms for different injury patterns originating from intra-articular, extra-articular or intra-pelvic etiologies. Age, sex, sport/activity level, previous injury, genetics and environmental factors all play an important role in determining the type of injury incurred [1–4]. As such, the treating clinician must be able to perform a thorough history and physical examination while maintaining a broad differential of potential diagnoses.

While most injuries such as muscle strain may be treated with rest and analgesics, more serious causes of hip pain such as stress fractures may have similar presentations with negative radiographs, making early diagnosis challenging [5–10]. Common pain presentations which do not resolve in the expected course should alert the treating clinician to

evaluate with more advanced studies such as ultrasound, magnetic resonance imaging (MRI) and/or computed tomography (CT) in select cases [1, 11, 12].

Stress fractures are common injuries associated with repetitive high-impact activities, often occurring in high-level athletes and military recruits. A sudden activity increase resulting in repetitive, cyclical loading on normal bone leads to local cortical disruption and microfracture [5–10]. Female athletes exhibiting the ‘female athlete triad’ of low energy availability (imbalance between nutrition intake and energy expenditure), amenorrhea/oligomenorrhoea and decreased bone mineral density are particularly susceptible [3, 5–9, 13–15]. While stress fractures most commonly occur in the foot or lower leg, fractures of the femoral neck, pelvis and sacrum have all been described in the literature and must be included as potential causes of hip pain [16–23]. Timely diagnosis and treatment is crucial to avoid fracture propagation or development of symptomatic non-

union [7, 23–26]. This was the case in our patient, an otherwise young, healthy, male athlete who presented with pain that was initially thought to be caused by a proximal hamstring tendonitis or strain.

### CASE REPORT

We report a clinical case of a 22-year old male collegiate football player with a 2-year history of left posterior hip and buttock pain in the region of a previously diagnosed proximal hamstring tendon strain. His symptoms were exacerbated during sports and squats and resolved with rest. Physical examination revealed symmetric flexion, internal rotation and external rotation compared with the uninjured extremity. He had no pain with impingement testing or ambulation. Previous treatments were directed toward the presumed diagnosis of proximal hamstring strain and included physical therapy, non-steroidal anti-inflammatory drug medications and cessation of sporting activity. This non-surgical management provided partial relief, but his pain returned during attempts to resume football. While he had been told that prior imaging demonstrated no pathology outside of proximal hamstring tendinosis, upon presentation to our clinic, radiographs and CT scan showed periosteal thickening with a solid black line through the posteromedial cortex at the ischium near the ischial spine. These findings were consistent with chronic stress fracture and non-union. MRI was obtained of the left hip and pelvis which demonstrated increased edema within the non-weight bearing portion of the ischium, extending proximally to involve the posterior column (Fig. 1A–E). As the patient had failed multiple attempts at non-operative management over a prolonged period of time, surgery was indicated and he elected to proceed with surgical intervention.

The patient underwent open reduction, internal fixation of his left ischial stress fracture through a standard Kocher–Langenbeck posterior approach. Our institution routinely utilizes spinal anesthesia with neuromonitoring to assess the sciatic nerve during the approach and fixation [19]. After take-down of the piriformis and short external rotators, the non-union site was identified over the ischium at the lesser sciatic notch adjacent to the ischial spine. An osteotome was used to open the immature woven bone posteriorly and the non-union was debrided back to healthy bleeding bone. The fracture was then fixed using a 7-hole 3.5-mm pelvic reconstruction plate and screws as a tension band, with a 3.5-mm interfragmentary screw placed across the stress fracture site. Demineralized bone matrix graft was placed around the edges of the fracture site (Fig. 2A–C). The piriformis and external rotators were

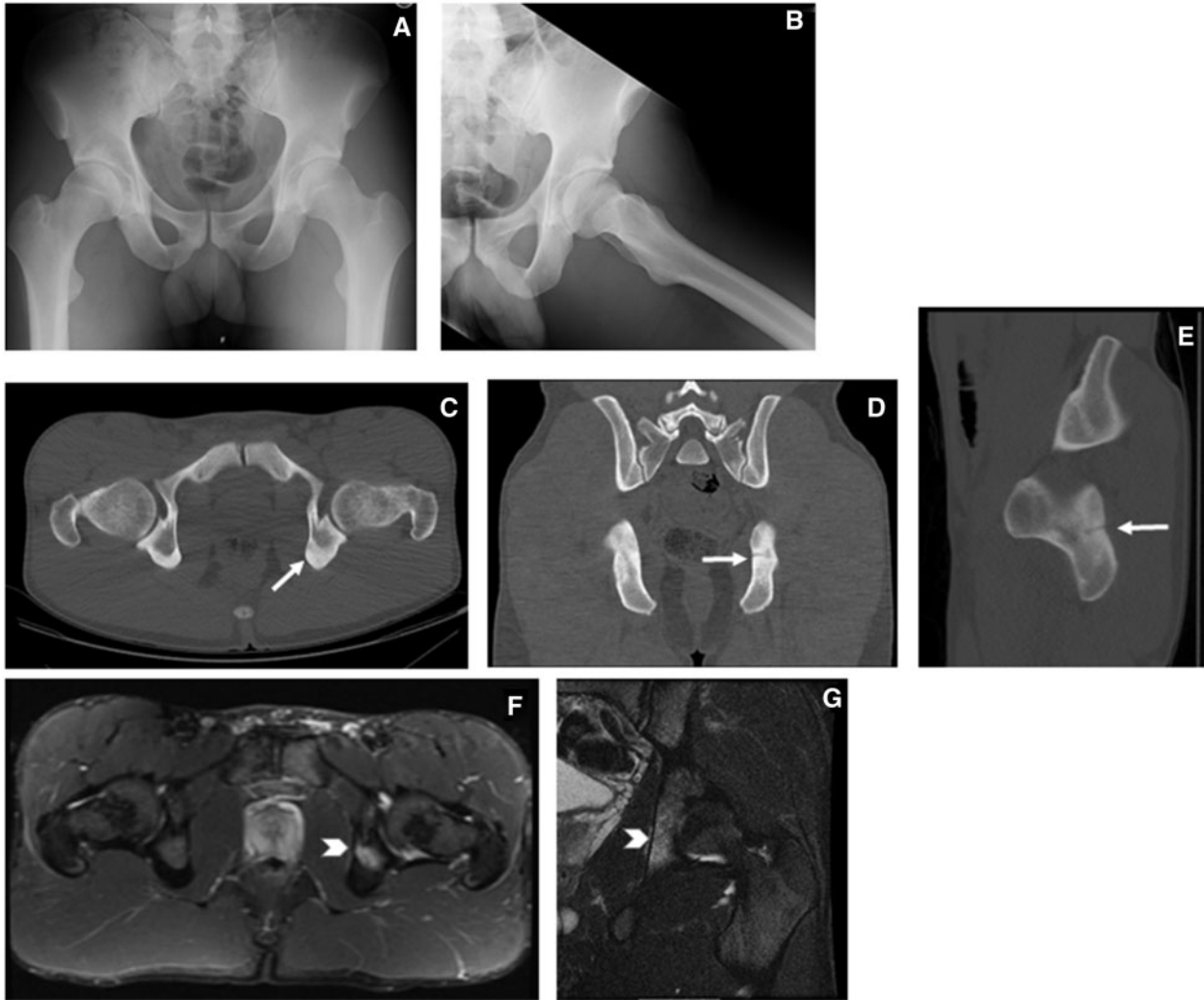
reattached to the posterior aspect of the femur using intra-osseous bone tunnels.

The patient was ambulatory on postoperative day 1 with crutches. He was made foot-flat weight bearing on the operative extremity for a period of 6 weeks, and allowed full range of motion of the hip and lower extremity. After 6 weeks, his weight bearing was progressively advanced to full over the next 4 weeks. Postoperative radiographs obtained at 10 weeks showed maintenance of fixation with evidence of fracture consolidation (Fig. 3). He was cleared for return to summer football workouts at his 10-week post-operative visit, and he played the entire fall season without difficulty. He noted that the operative hamstrings did seem to fatigue easier during his football season, but he was able to play without impairment. At 1 year post-op, he had no complaints, and noted that he had returned to near-symmetric strength. He had plans to play football for one more collegiate season the following year.

### DISCUSSION

The hip can be affected by injuries arising from osseous, ligamentous, muscular and neurologic structures. The interaction and function of these structures overlap such that injuries in one location or layer exhibit similar physical findings to another, which can create a diagnostic challenge in patients presenting with ‘hip’ pain [1–4, 27, 28].

Our patient exhibited posterior hip pain, which had persisted for over 2 years with the diagnosis of proximal hamstring strain. Posterior hip or buttock pain may result from proximal hamstring tendinopathy, bursitis, avulsion or strain of the posterior structures [19, 27, 29, 30]. While the majority of these injuries may be treated conservatively with activity modification, rest and anti-inflammatory medication, refractory pain over a protracted period of time warrants further investigation into the etiology of the pain. Persistent or atypical hip pain may mimic more threatening problems such as nerve compromise or compression. It is important to elicit any associated back pain or neurologic symptoms in the history, as the conditions associated with these findings carry significant morbidity [31]. Additionally, refractory pain may indicate a stress fracture [1–3, 5, 6], which in some cases requires more aggressive management. This is further complicated by the fact that regular imaging studies will often appear normal, delaying the diagnosis. A careful history of the timing and chronicity of symptoms is more useful than location and pain type. Common pain presentations which do not resolve in the expected course should alert the treating clinician to evaluate with more advanced studies such as MRI or CT [11, 12].

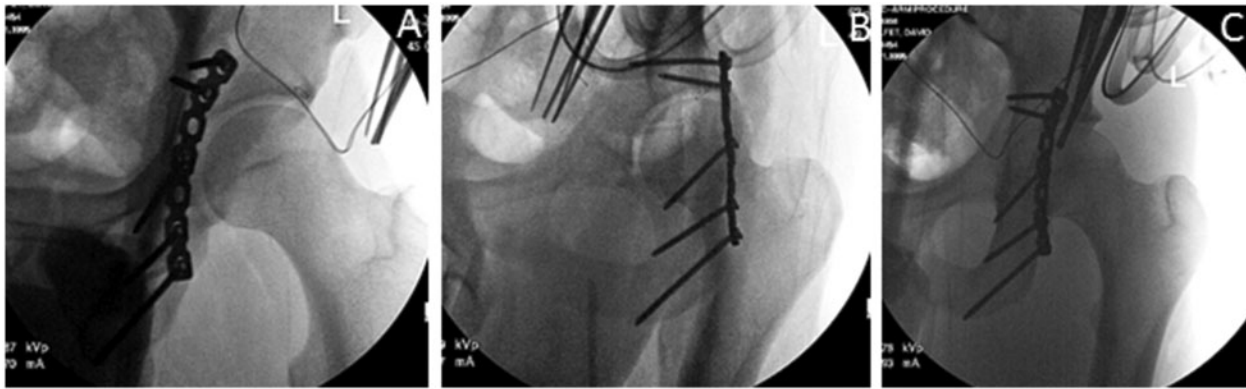


**Fig. 1.** (A) AP pelvis radiograph and (B) left hip Dunn lateral radiograph demonstrating a relatively normal appearing ischium. (C) Axial, (D) coronal and (E) sagittal CT revealing a black line and periosteal thickening (arrow) of the ischium representing the stress fracture non-union. MRI of the left hip and pelvis demonstrate in the (F) axial and (G) coronal plane increased edema (arrow head) in the non-weight bearing portion of the ischium and extending into the posterior column.

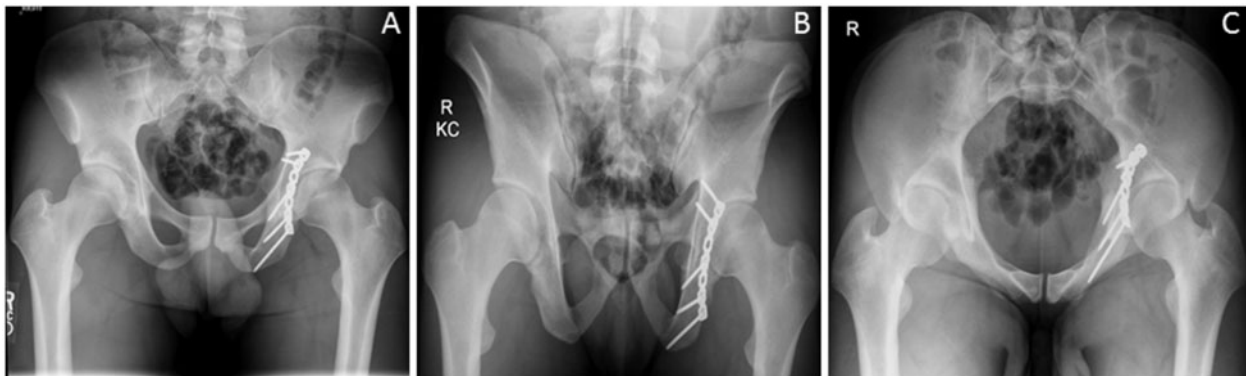Our patient had failed 2 years of conservative management of his posterior hip/buttock pain, and upon presentation in our clinic, he was formally diagnosed with an ischial stress fracture. While stress fractures are a relatively common diagnosis, ischial stress fracture is extremely rare, with only a few reported cases in the literature [16–18, 32]. Previously, ischial stress fractures have been described after acetabular realignment osteotomy, due to narrowing of the posterior column and ischial cut [2, 20].

Stress fractures have numerous causes and can occur nearly anywhere, but most commonly occur in the lower extremities, especially in the foot or lower leg. In a survey by Matheson *et al.* of 320 athletes, tibia fractures were

most common (49.1%) followed by tarsals and metatarsals (34.1%) [5]. A more recent review of high school athletes by Changstrom *et al.* showed stress fractures occurred in 389 injuries out of 51 773 (0.8%). Of these, 40.3% were in the tibia [8]. In the military recruit population, metatarsal stress fractures are more common [6]. Stress fractures have been described in the patellae, ribs, elbow, humerus, sacrum or iatrogenically after bone graft harvest [10, 22, 26, 33–45]. In the hip region, stress fractures can occur in the femoral neck, pelvis or sacrum. Clinical suspicion should be high in high-level athletes, military recruits, and females who exhibit the female athlete triad. A sudden activity increase resulting in repetitive, cyclical loading on



**Fig. 2.** Intraoperative (A) iliac oblique, (B) obdurator oblique and (C) AP fluoroscopy images left hip and ischium of the tension plate construct. The fracture non-union site was cleared of granulation tissue and demineralized bone matrix was placed around the fracture site.



**Fig. 3.** (A) AP, (B) outlet and (C) inlet radiographs from 10 weeks post-operative follow-up demonstrating intact hardware. At the patient's last follow-up, he was pain free and cleared to resume summer football activities.

normal bone leads to local cortical disruption and micro-fracture [5–10]. Female athletes exhibiting the female athlete triad are particularly susceptible to this stress reaction [3, 5–9, 13–15].

The treatment for stress fractures, when promptly diagnosed, is activity modification and limited weight bearing on the affected bone, with full healing expected in most cases [5, 6, 24]. However, chronic injuries often require surgical stabilization. Tension-type anterior tibial stress fractures have an increased propensity to develop chronic non-union due to the poor vascularity of the region and require consistent radiographic monitoring to follow progression of healing [46, 47]. To prevent this complication, surgical treatment with intramedullary reaming and statically locked nail has been advocated once radiographs show evidence of a 'dreaded black line' [48–51]. More recent literature has shown that open treatment with debridement and tension band plating results in successful tibial stress

fracture healing [52–55]. In their series, Zbeda *et al.* treated 12 patients with 13 chronic anterior tibia stress fractures, with a 92% rate of return to preinjury function at an average of 11 weeks after surgery. Five of the 13 (38%) underwent removal of hardware due to plate prominence [55]. In Markolf *et al.*'s biomechanical analysis comparing anterior tension band plating to intramedullary nailing for anterior stress fractures, significantly less fracture gapping was noted with bending stress using an anteriorly positioned plate [56]. There is, however, no consensus on treatment of ischial stress fractures.

In our patient, conservative treatment and delayed diagnosis contributed to a chronic non-healing stress fracture of his ischium. We recommended surgical treatment, and the patient opted to proceed given the significant impact his ongoing pain had on his life. As the location of his stress fracture was similar to an ischial avulsion, a Kocher–Langenbeck approach was used, with visualization and debridement of

the fracture line and placement of a tension band plate construct. [30]. While sciatic nerve monitoring has not definitively been shown to decrease rates of iatrogenic palsy, it is regularly utilized at our institution [57].

Newer research shows improved results for non-union of stress fracture with adjuvant treatments in addition to surgery. This includes addressing underlying nutritional and metabolic deficits, as well as altering the local fracture environment [13–15, 58]. Vitamin D levels correlate highly with quality of local bone micro-environment and reparative ability after repetitive stress. Numerous studies have evaluated the use of vitamin D supplementation in the military and in collegiate athletes. Patients with vitamin D insufficiency and deficiencies show delayed healing; however, vitamin D treatment alone without calcium does not appear to reduce stress fracture risk [59–64]. In our patient, vitamin D levels were drawn and were within normal limits.

Bisphosphonates have not yet been proven to provide a benefit in the treatment of these injuries. In a retrospective study, Simon *et al.* evaluated 25 professional athletes with bone stress reactions (not true fractures) treated with intravenous ibandronate. While those treated with ibandronate showed faster return to competition, the time to definitive diagnosis also played a crucial role in the rate of healing. Furthermore, there was no control group for comparison, and patients also received concurrent vitamin D supplementation [65]. Sloan *et al.* performed a study comparing parathyroid hormone (Forteo) with alendronate in adult rats with induced stress fractures. Rats receiving Forteo had significant increases in bone mineral density, content, bone formation and yield strength compared with those treated with bisphosphonates [66]. There has been an increased interest in using Forteo in the setting of high-risk stress fractures, principally those with tendency for non-union such as fifth metatarsal and femoral neck fractures, though definitive effectiveness has yet to be proven [67–70].

Based on a study by Hernigou and others, bone marrow aspirate concentrate (BMAC) has demonstrated success as an adjuvant in difficult tibial fracture non-unions [71, 72]. Currently, a double-blind randomized trial has been initiated to evaluate the effect of BMAC on time to union of fifth metatarsal stress fractures. This technique has been described previously, utilizing a cannulated screw as the delivery device for injecting the aspirate [73]. However, further research is required to prove the efficacy of BMAC in the setting of non-union.

Finally, low-intensity pulsed ultrasound has shown some evidence of improvement in healing rates with acute fractures but does not appear to play a significant role in reducing time to union in the setting of stress fracture [74–76].

## CONCLUSIONS

Hip pain is common in the adolescent athlete, and while stress fractures may not be the most common etiology, the clinician should maintain a high clinical suspicion throughout examination and workup, especially in those with refractory or atypical pain presentations. Ischial stress fractures are rare but can closely mimic common causes of posterior hip pain and are thus difficult to diagnose. Most are successfully treated with conservative treatment when recognized early. Continued repetitive stress can lead to non-union. Failed conservative management may require open treatment, with debridement of the fracture site and compression plating, as described in our case presentation. Adjuvant treatments such as BMAC and/or BMP may have a role in chronic non-unions where the local bone environment has decreased propensity to heal.

## CONFLICT OF INTEREST STATEMENT

None declared.

## REFERENCES

1. Frank JS, Gambacorta PL, Eisner EA. Hip pathology in the adolescent athlete. *J Am Acad Orthop Surg* 2013; **21**: 665–74.
2. Paluska SA. An overview of hip injuries in running. *Sports Med* 2005; **35**: 991–1014.
3. Blankenbaker DG, De Smet AA. Hip injuries in athletes. *Radiol Clin North Am* 2010; **195**: 605–17.
4. Tibor L, Sekiya J. Differential diagnosis of pain around the hip joint. *Arthroscopy* 2008; **24**: 1407–21.
5. Matheson GO, Clement DB, McKenzie DC. Stress fractures in athletes: a study of 320 cases. *Am J Sports Med* 1987; **15**: 46–58.
6. Waterman BR, Gun B, Bader JO *et al.* Epidemiology of lower extremity stress fractures in the United States Military. *Mil Med* 2016; **181**: 1308–13.
7. Behrens SB, Deren ME, Matson A *et al.* Stress fractures of the pelvis and legs in athletes. *Sports Health* 2013; **5**: 165–74.
8. Changstrom BG, Brou L, Khodae M *et al.* Epidemiology of stress fracture injuries among US high school athletes, 2005–2006 through 2012–2013. *Am J Sports Med* 2015; **43**: 26–33.
9. Mattila VM, Niva M, Kiuru M, Pihlajamaki H. Risk factors for bone stress injuries: a follow-up of 102, 515 person-years. *Med Sci Sports Exerc* 2017; **39**: 1061–6.
10. Heyworth B, Green D. Lower extremity stress fractures in pediatric and adolescent athletes. *Curr Opin Pediatr* 2008; **20**: 58–61.
11. De Paulis F, Cacchio A, Michelini O *et al.* Sports injuries in the pelvis and hip: diagnostic imaging. *Eur J Radiol* 1998; **27 Suppl 1**: S49–59.
12. Wright AA, Hegedus EJ, Lenchik L *et al.* Diagnostic accuracy of various imaging modalities for suspected lower extremity stress fractures: a systematic review with evidence-based recommendations for clinical practice. *Am J Sports Med* 2016; **44**: 255–63.

13. Chen YT, Tenforde AS, Fredericson M. Update on stress fractures in female athletes: epidemiology, treatment, and prevention. *Curr Rev Musculoskelet Med* 2013; **6**: 173–81.
14. Reinking MF, Austin TM, Bennett J *et al*. Lower extremity overuse bone injury risk factors in collegiate athletes: a pilot study. *Int J Sports Phys Ther* 2015; **10**: 155–67.
15. Tenforde AS, Carlson JL, Chang A *et al*. Association of the female athlete triad risk assessment stratification to the development of bone stress injuries in collegiate athletes. *Am J Sports Med* 2017; **45**: 302–10.
16. Smets C, Roos J, Vanlommel E *et al*. Stress fracture of os ischium. *Injury* 1995; **26**: 411–2.
17. Mowat AG, Kay VJ. Case report: ischial stress fracture. *Brit J Sports Med* 1983; **17**: 94–5.
18. Clarke A, Connell D. Case report: bilateral ischial stress fractures in an elite tennis player. *Skel Rad* 2009; **38**: 711–4.
19. Yang B-K, Yi S-R, Ahn Y-J *et al*. Ischial tuberosity avulsion stress fracture after short period of repetitive training. *Hip Pelvis* 2016; **28**: 187–90.
20. Tsuboi M, Hasegawa Y, Fujita K, Kawabe K. Pubic/ischial stress fractures after eccentric rotational acetabular osteotomy. *J Orthop Sci* 2011; **16**: 38–43.
21. Malviya A, Dandachli W, Beech Z *et al*. The incidence of stress fracture following peri-acetabular osteotomy: an under-reported complication. *Bone Joint J* 2015; **97-B**: 24–8.
22. Kahanov L, Eberman L, Alvey T *et al*. Sacral stress fracture in a distance runner. *J Am Osteopath Assoc* 2011; **111**: 585–91.
23. Okamoto S, Arai Y, Hara K *et al*. A displaced stress fracture of the femoral neck in an adolescent female distance runner with female athlete triad: a case report. *Sports Med Arthrosc Rehabil Ther Technol* 2010; **2**: 6.
24. Kaeding CC, Yu JR, Wright R *et al*. Management and return to play of stress fractures. *Clin J Sport Med* 2005; **15**: 442–7.
25. Mabit C, Pécout C. Non-union of a midshaft anterior tibial stress fracture: a frequent complication. *Knee Surg Sports Traumatol Arthrosc* 1994; **2**: 60.
26. Clark RR, McKinley TO. Bilateral olecranon epiphyseal fracture non-union in a competitive athlete. *Iowa Orthop J* 2010; **30**: 179–81.
27. Zibis AH, Fylos AH, Karantanas AH *et al*. Quadratus femoris tear as an unusual cause of hip pain: a case report. *Hip Int* 2016; **26**: e7–9.
28. Draovitch P, Edelstein J, Kelly BT. The layer concept: utilization in determining the pain generators, pathology and how structure determines treatment. *Curr Rev Musculoskelet Med* 2012; **5**: 1–8.
29. Gidwani S, Bircher MD. Avulsion injuries of the hamstring origin – a series of 12 patients and management algorithm. *Ann R Coll Surg Engl* 2007; **89**: 394–9.
30. Kaneyama S, Yoshida K, Matsushima S *et al*. A surgical approach for an avulsion fracture of the ischial tuberosity: a case report. *J Orthop Trauma* 2006; **20**: 363–5.
31. Vasudevan JM, Smuck M, Fredericson M. Evaluation of the athlete with buttock pain. *Curr Sports Med Rep* 2012; **11**: 35–42.
32. Putman S, Rommens PM. A case of hypertrophic ischial tuberosity non-union treated by closed wedge osteotomy and plate and screws fixation. *Arch Orthop Trauma Surg* 2013; **133**: 513–6.
33. Shindle MK, Endo Y, Warren RF *et al*. Stress fractures about the tibia, foot, and ankle. *J Am Acad Orthop Surg* 2012; **20**: 167–76.
34. Menge TJ, Looney CG. Medial malleolar stress fracture in an adolescent athlete. *J Foot Ankle Surg* 2015 Mar-Apr; **54**: 242–6.
35. Thevendran G, Deol RS, Calder JD. Fifth metatarsal fractures in the athlete: evidence for management. *Foot Ankle Clin* 2013; **18**: 237–54.
36. Gross CE, Nunley JA. II. Navicular stress fractures. *Foot Ankle Int* 2015; **36**: 1117–22.
37. Kohyama S, Kanamori A, Tanaka T *et al*. Stress fracture of the scaphoid in an elite junior tennis player: a case report and review of the literature. *J Med Case Rep* 2016; **10**: 8.
38. Emery SE, Heller JG, Petersilge CA *et al*. Tibial stress fracture after a graft has been obtained from the fibula: a report of five cases. *J Bone Joint Surg Am* 1996; **78**: 1248–51.
39. Wolf BR, Buckwalter JA. Tibial stress fracture following fibular graft harvesting: a case report. *Iowa Orthop J* 2001; **21**: 68–72.
40. Chou LB, Mann RA, Coughlin MJ *et al*. Stress fracture as a complication of autogenous bone graft harvest from the distal tibia. *Foot Ankle Int* 2007; **28**: 199–201.
41. Parvataneni H, Nicholas S, McCance S. Bilateral pedicle stress fractures in a female athlete: case report and review of the literature. *Spine (Phila Pa 1976)* 2004; **29**: E19–21.
42. Low S, Kern M, Atanda A. First-rib stress fracture in two adolescent swimmers: a case report. *J Sports Sci* 2016; **34**: 1266–70.
43. Larson CM, Traina SM, Fischer DA *et al*. Recurrent complete proximal tibial stress fracture in a basketball player. *Am J Sports Med* 2005; **33**: 1914–7.
44. Miller TL, Kaeding CC. Upper-extremity stress fractures: distribution and causative activities in 70 patients. *Orthopedics* 2012; **35**: 789–93.
45. Ward WG, Bergfeld JA, Carson WG Jr. Stress fracture of the base of the acromial process. *Am J Sports Med* 1994; **22**: 146–7.
46. Whelan DB, Bhandari M, Stephen D *et al*. Development of the radiographic unions score for tibial fractures for the assessment of tibial fracture healing after intramedullary fixation. *J Trauma* 2010; **68**: 629–32.
47. Cook GE, Bates BD, Tornetta P *et al*. Assessment of fracture repair. *J Orthop Trauma* 2015; **29 Suppl 12**: S57–61.
48. Plasschaert VF, Johansson CG, Micheli LJ. Anterior tibial stress fracture treated with intramedullary nailing: a case report. *Clin J Sport Med* 1995; **5**: 58–61.
49. Chang PS, Harris RM. Intramedullary nailing for chronic tibial stress fractures: a review of five cases. *Am J Sports Med* 1996; **24**: 688–92.
50. Varner KE, Younas SA, Lintner DM *et al*. Chronic anterior midtibial stress fractures treated with reamed intramedullary nailing. *Am J Sports Med* 2005; **33**: 1071–6.
51. Kuntscher G. The intramedullary nailing of fractures. *Clin Orthop Relat Res* 1968; **60**: 5–12.
52. Borens O, Sen MK, Huang RC *et al*. Anterior tension band plating for anterior tibial stress fractures in high-performance athletes: a report of 4 cases. *J Orthop Trauma* 2006; **20**: 425–30.
53. Cruz AS, de Hollanda JP, Duarte A Jr *et al*. “Anterior tibial stress fractures treated with anterior tension band plating in high-performance athletes. *Knee Surg Sports Traumatol Arthrosc* 2013 Jun; **21**: 1447–50.
54. Merriman JA, Villacis D, Kephart CJ *et al*. Tension band plating of a nonunion anterior tibial stress fracture in an athlete. *Orthopedics* 2013; **36**: 534–8.

55. Zbeda RM, Sculco PK, Urch EY *et al.* Tension band plating for chronic anterior tibial stress fractures in high-performance athletes. *Am J Sports Med* 2015; **43**: 1712–8.
56. Markolf KL, Cheung E, Joshi NB *et al.* Plate versus intramedullary nail fixation of anterior tibial stress fractures: a biomechanical study. *Am J Sports Med* 2016; **44**: 1590–6.
57. Helfet DL, Anand N, Malkani AL *et al.* Intraoperative monitoring of motor pathways during operative fixation of acute acetabular fractures. *J Orthop Trauma* 1997; **11**: 2–6.
58. Elliott DS, Newman KJH, Forward DP *et al.* A unified theory of bone healing and nonunion: bHN theory. *Bone Joint J* 2016; **98-B**: 884–91.
59. McCabe MP, Smyth MP, Richardson DR. Current concept review: vitamin D and stress fractures. *Foot Ankle Int* 2012; **33**: 526–33.
60. Gaffney-Stomberg E, Lutz LJ, Rood JC *et al.* Calcium and vitamin D supplementation maintains parathyroid hormone and improves bone density during initial military training: a randomized, double-blind placebo controlled trial. *Bone* 2014; **68**: 46–56.
61. Angeline ME, Gee AO, Shindle M *et al.* The effects of vitamin D deficiency in athletes. *Am J Sports Med* 2013; **41**: 461–4.
62. Lappe J, Cullen D, Haynatzki G *et al.* Calcium and vitamin D supplementation decreases incidence of stress fractures in female navy recruits. *J Bone Miner Res* 2008; **23**: 741–9.
63. Scofield KL, Hecht S. Bone health in endurance athletes: runners, cyclists, and swimmers. *Curr Sports Med Rep* 2012; **11**: 328–34.
64. Tenforde AS, Sayres LC, Sainani KL *et al.* Evaluating the relationship of calcium and vitamin D in the prevention of stress fracture injuries in the young athlete: a review of the literature. *PM R* 2010; **2**: 945–9.
65. Simon MJ, Barvencik F, Luttko M *et al.* Intravenous bisphosphonates and vitamin D in the treatment of bone marrow oedema in professional athletes. *Injury* 2014; **45**: 981–7.
66. Sloan AV, Martin JR, Li S, Li J. Parathyroid hormone and bisphosphonate have opposite effects on stress fracture repair. *Bone* 2010; **47**: 235–40.
67. Baillieux S, Guinot M, Dubois C *et al.* Set the pace of bone healing – treatment of a bilateral sacral stress fracture using teriparatide in a long-distance runner. *Joint Bone Spine* 2017; **84**: 499–500.
68. Raghavan P, Christofides E. Role of teriparatide in accelerating metatarsal stress fracture healing: a case series and review of the literature. *Clin Med Insights Endocrinol Diabetes* 2012; **5**: 39–45.
69. Malhotra R, Meena S, Digge VK. Tensile type of stress fracture neck of femur: role of teriparatide in the process of healing in a high risk patient for impaired healing of fracture. *Clin Cases Miner Bone Metab* 2013; **10**: 210–2.
70. Knobloch K, Schreibermueller L *et al.* Rapid rehabilitation programme following sacral stress fracture in a long-distance running female athlete. *Arch Orthop Trauma Surg* 2017; **127**: 809–13.
71. Schottel PC, Warner SJ. Role of bone marrow aspirate in orthopaedic trauma. *Orthop Clin N Am* 2017; **48**: 311–21.
72. Hernigou P, Desroches A, Queinnee S *et al.* Morbidity of graft harvesting versus bone marrow aspiration in cell regenerative therapy. *Int Orthop* 2014; **38**: 1855–60.
73. Adams SB, Lewis JS Jr, Gupta AK *et al.* Cannulated screw delivery of bone marrow aspirate concentrate to a stress fracture nonunion: technique tip. *Foot Ankle Int* 2013 May; **34**: 740–4.
74. Rue J-PH, Armstrong DW, Frassica FJ 3rd *et al.* The effect of pulsed ultrasound in the treatment of tibial stress fractures. *Orthopedics* 2004; **27**: 1192–5.
75. Gan TY, Kuah DE, Graham KS, Markson G. Low-intensity pulsed ultrasound in lower limb bone stress injuries: a randomized controlled trial. *Clin J Sport Med* 2014; **24**: 457–60.
76. Busse JW, Kaur J, Mollon B *et al.* Low intensity pulsed ultrasonography for fractures: a systemic review of randomized controlled trials. *BMJ* 2009; **338**: b351.